

# TREATMENT OF TIBIAL SHAFT FRACTURES BY INTERLOCKING NAILING

A. HARTH<sup>1</sup>, J. MOERMAN<sup>1</sup>, W. DE GROOTE<sup>2</sup>, B. VANDEKERCKHOVE<sup>2</sup>,  
R. VERBEKE<sup>2</sup>, R. VERDONK<sup>1</sup>, H. CLAESSENS<sup>1</sup>

Between 1982 and 1986, 60 tibial shaft fractures were treated by interlocking nailing. Of these, 10 were complicated by a pseudarthrosis.

The results were assessed after a minimum follow-up of 2 years and were found to be good both in patients with fresh fractures and with pseudarthroses; in only 3 out of 60 cases was the outcome poor. The advantages of the techniques include:

- its suitability for virtually all types of shaft fractures
- ease of surgery
- early mobilization and weightbearing, with a low risk of infection
- rapid consolidation.

Relative drawbacks are:

- radiation exposure
- longer preoperative preparation
- involvement of the entire shaft if infection develops
- irritation of the patellar tendon.

**Keywords** : tibia ; interlocking nail ; fracture ; pseudarthrosis.

**Mots-clés** : tibia ; clou verrouillé ; pseudarthrose.

## INTRODUCTION

Intramedullary nailing was introduced by Küntscher in 1940 for the treatment of closed transverse or slightly oblique fractures involving the midshaft of long bones (9). In 1950, the technique was already successfully applied in the Department of Orthopaedic Surgery of the St. Jan General Hospital in Bruges.

A few years later, Küntscher described reaming of the medullary canal which greatly improved the stability of the osteosynthesis, but also carried a higher risk of infection (10). In 1968 he designed a forerunner of the interlocking nail which considerably expanded the range of indications of intramedullary nailing by providing a means to control rotation and telescoping (11).

We prefer the method devised by Klemm and Schellman in 1972 (5) and modified by Kempf *et al.* in 1974 (3). In 1981 we began treating femoral fractures, and one year later tibial fractures as well by this method. The results of a first series of 60 tibial shaft fractures are presented.

## MATERIAL AND METHODS

Between March 1982 and April 1986, 60 consecutive patients with tibial shaft fractures were treated by interlocking nailing.

Fifty patients presented with a fresh fracture. The fracture type was closed or open, grade I and II. Grade III open fractures were treated by external fixation. Ten patients with a nonunion or a pseudarthrosis of the tibia were also included: for these patients medullary nailing was performed a minimum of 4 months postinjury (longest interval 3 years 2 months). In 4 cases of pseudarthrosis a fibulotomy was also performed.

<sup>1</sup> Department of Orthopaedic Surgery, Ghent University Hospital, B-9000 Ghent, Belgium.

<sup>2</sup> Department of Orthopaedic Surgery, A.Z. St. Jan, B-8000 Bruges, Belgium.

Correspondence and reprints: A. Harth, Ziekenhuis De Bijloke, H. Dumontlaan 2, 9000 Gent.

All patients were followed in a prospective, nonrandomized study ; the period of follow-up ran until May 1988.

The shortest follow-up was 24 months. At the conclusion of our series, 53 patients had a complete clinical and radiological record. Of the remaining 7 patients, one patient died during follow-up of causes unrelated to the initial trauma or treatment, and 6 asked to be transferred to other hospitals and were lost to regular follow-up. Their records were only included in some instances, where it has been stated explicitly. There were 48 men and 12 women, ranging in age from 14 to 91 years (mean 38.5 years).

The left lower leg was fractured 40 times, the right lower leg 20 times. These injuries were the result of traffic accidents (motorcycle 17, pedestrians 10, automobile 9, bicycle 7 = 43 fractures), sports activities (11 fractures sustained in 10 different sports), fall (4 fractures) and industrial accidents (2 crush injuries of the lower leg resulting in a pseudarthrosis).

Thirty-six fractures were closed, 24 were open (grade I or II). In the presence of grade II open fractures, draining catheters were installed (13 cases) after meticulous wound debridement (instillation of rifamycin 2 cc IM via a catheter twice a day for 5 days ; drainage continued for 7 days). After successful healing of the wounds, they could all be treated.

On the day of admission transcalfaneal traction was applied in all patients. All patients received prophylactic heparin 5000 U s.c. t.i.d. Thirty-one patients suffered concomitant injuries (an average of 2.5 major injuries ; range 1-8) which necessitated several operative procedures in 23 of them. Sixteen patients presented fractures and/or ligamentous injuries involving the ipsilateral limb. In 23 cases of tibial fracture, including the 10 pseudarthroses, several interventions were performed (table I).

Static nailing was performed 36 times, dynamic nailing 24 times (9 proximal and 15 distal interlocking nails). The average delay between trauma and interlocking nailing was 10 days for the 50 fresh fractures, 6 days for the closed fractures (0-24 days) and 18 days for the open fractures (0-56 days). During surgery prophylactic antibiotics were administered : cefamandole 2 g at induction and 2 g postoperatively.

Nine oblique and 6 comminuted fractures were locked in the dynamic mode for the following reasons :

- in 9 cases cortical integrity was more than 50%.
- in 5 nonunions there was sufficient obliteration of the fracture line to permit early weightbearing.
- in 1 case technical problems necessitated dynamic instead of static nailing.

Operating time averaged 1 hour 14 minutes, including patient positioning on the fracture table. Immediately after surgery, alternate positioning in bed was used : limb 4 hours in a 90-90 position and 4 hours extended. From the first postoperative day, mobilization in and out of bed was allowed and weightbearing was encouraged in the patients who had undergone dynamic nailing.

The 36 static fixations were converted to a dynamic state on an average of 56 days postoperatively (18-150 days). At that time radiographic callus was sufficiently solid to allow additional compression without the risk of telescoping.

The screws that were located at the greatest distance from the fracture site were removed and the patients were allowed to bear weight immediately.

Normally weightbearing is allowed immediately post-surgery with dynamic nailings and after dynamization of static nailings. However an exception was made 26 times on the following grounds :

- early weightbearing : elderly patients who underwent static nailing were allowed early weightbearing to avoid prolonged immobilization (3).
- delayed weightbearing : poor compliance with premature weightbearing (3).
- associated lesions (9).
- postoperative complications : one patient developed a deep venous thrombosis ; in the other telescoping (1.5 cm) occurred after dynamization and weightbearing for 1 week (2).
- infection (1) (see also complications).
- the fixation was considered to be only semirigid (radiographically evaluated : i.e. borderline cortical contact) in 8 cases (5 dynamic and 3 static nailings). These patients were first allowed plantar touch, followed by progressive weightbearing.

Table I. — Associated interventions of the tibia  
N = 23 (10 pseudarthroses and nonunions)  
Mean = 2 (1-7)

- |   |
|---|
| 1. External fixator 5                     |
| 2. Fasciotomy 9                           |
| 3. Bone grafting 9                        |
| 4. Zanolli procedure 1                    |
| 5. Fibulotomy 8                           |
| 6. Boehler fixation 3                     |
| 7. Osteosynthesis of the tibial plateau 1 |
| 8. Osteosynthesis of the ankle 2          |
| 9. Ilizarov procedure 1                   |
| 10. Sequestrectomy 4                      |
| 11. Gentamycin-PMMA beads 1               |
| 12. Skin grafting 3                       |

Table II. — Pre- and postoperative complications

1. Compartment syndrome	9
2. Nerbe lesions	9
3. Sudeck algodystrophy	2
4. Local infections	5
5. Nail contact	1
6. Generalized infections	4
7. Loosening of distal screws	1
8. Removal of bone fragment	1
9. Embolism	2
10. Thrombosis	2
11. Partial union	3
12. Total treatment failure	2
13. Irritation of patellar tendon	3
14. Osteoporotic union	3
15. Rotational malalignment	3
16. Shortening	2
17. Varus deformity	2
18. Metal fatigue	0

## RESULTS

### A. Radiographic union

Radiographic union was achieved at an average of 4 months 15 days postoperatively ( $n = 48$ , i.e. 40 fresh fractures and 8 pseudarthroses). For the pseudarthroses time to union was 4 months 6 days ( $n = 8$ ). Fractures locked in the dynamic mode ( $n = 22$ ) showed radiographic union at 3 months 38 days postoperatively (fig. 1), those locked in the static mode ( $n = 26$ ) at 5 months (fig. 2). In closed fractures ( $n = 30$ ) there was radiographic evidence of union at 4 months 19 days, in open fractures ( $n = 18$ ) at 4 months 9 days. In the latter, however, the delay between trauma and surgery was longer.

In 7 fresh fractures the time to radiographic union could not be determined: 1 patient died; 6 patients were transferred to other hospitals and only reviewed at a later stage when consolidation had already occurred.

In 5 patients the callus was insufficient:

- On AP and lateral views obtained in 3 patients with fresh fractures bridging callus formation was seen on 3 sides only (at 3 years 4 months, 2 years 5 months and 2 years, respectively).

- 2 patients with a pseudarthrosis previously infected with *Staph aureus* underwent intramedullary nailing (2 years 1 month and 3 years 2 months after a severe crush injury) after the infection had cleared, as shown by absence of hyperactivity on bone scan, a normal sedimentation rate and no evidence of sequestration, and after failure of external fixation. Reactivation of the infection with fistulization and generalized sepsis occurred in both cases.

### B. Complications

1. Nine patients in whom a compartment syndrome had developed were treated by fasciotomy. In 7 acute cases the fasciotomy was performed preoperatively 6 times and after Küntscher nailing twice because of elevated tissue pressure inside the compartments of the lower leg following surgery. In another case a fasciotomy was carried out unnecessarily.

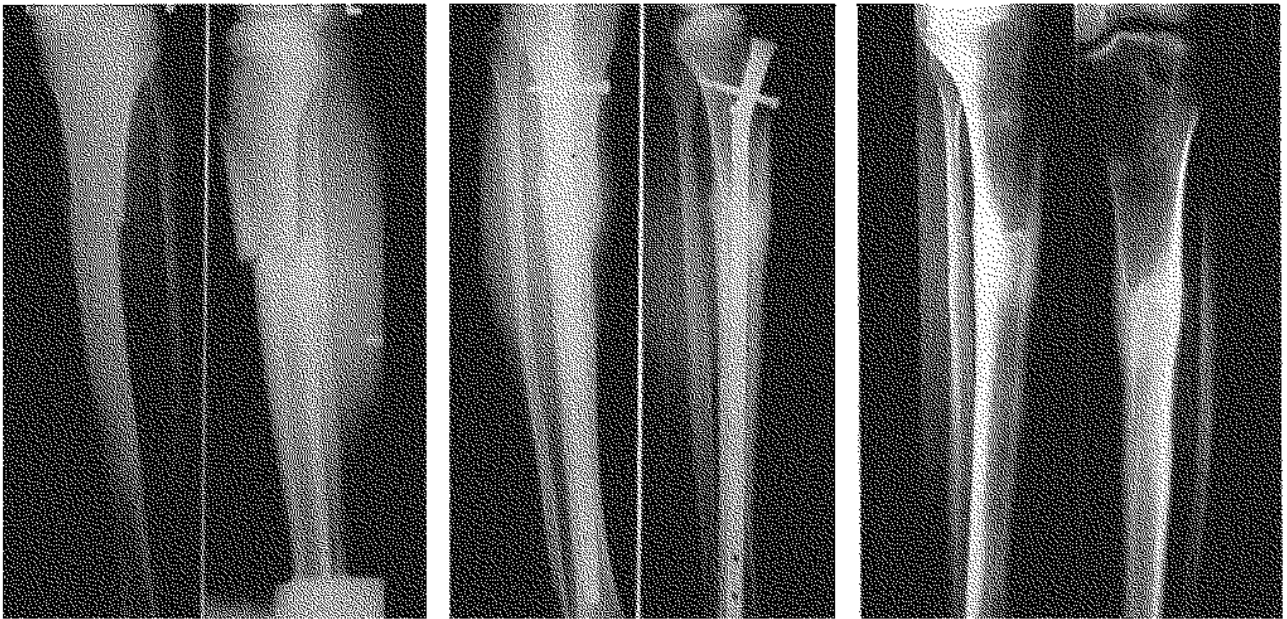2. Nerve damage was observed in 9 cases. The peroneal nerve was involved 7 times, the tibial nerve twice. In 8 of these patients the diagnosis had been established before surgery; in 1 patient with multiple injuries footdrop was only recognized at a later stage.

3. In two patients with an impending Sudeck's syndrome, rapid mobilization, physiotherapy and calcitonin were successful in preventing atrophy of the injured limb.

4. Local infection developed in 5 cases:

a. One patient presented with an infection with *Staph epidermidis* at a proximal screw. The infection resolved after removal of the screw, local wound care and antibiotic therapy. Bone scans, xrays and the erythrocyte sedimentation rate were found to be within normal limits more than 1 year after the infection.

b. Two female patients with varicose veins developed erysipelas at 6 months and 1 year respectively. In one of them the infection cleared uneventfully, with antibiotic treatment; in the other osteomyelitis developed at the site of the

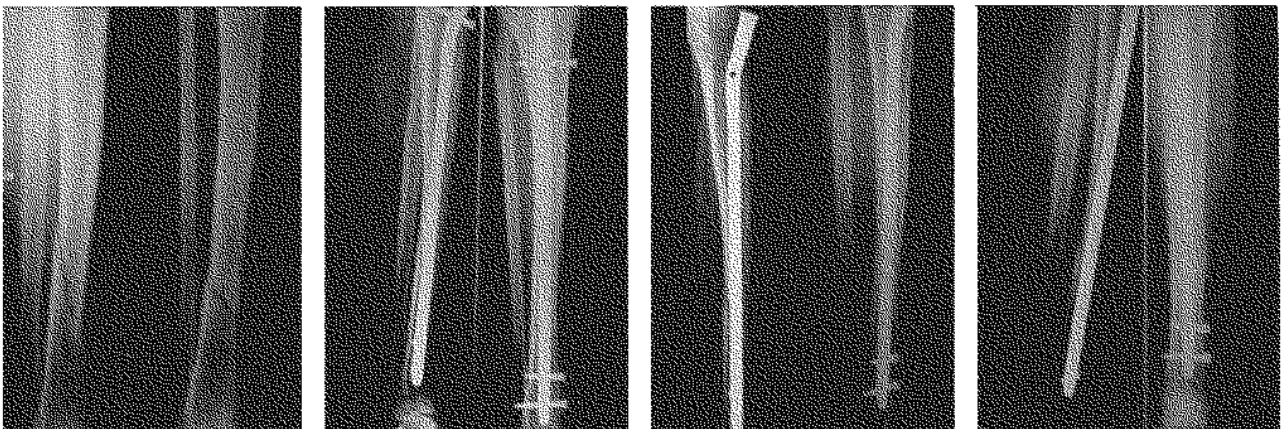

*Fig. 1a*

*Fig. 1b*

*Fig. 1c*

**Fig. 1.** — a. Closed fracture of the proximal third of the left tibia following a motorcycle accident. Fracture of the tibial plateau of the contralateral limb.  
b. Result of dynamic nailing at 3 months postoperatively.  
c. Status after removal of the nail, 18 months later.



*Fig. 2a*

*Fig. 2b*

*Fig. 2c*

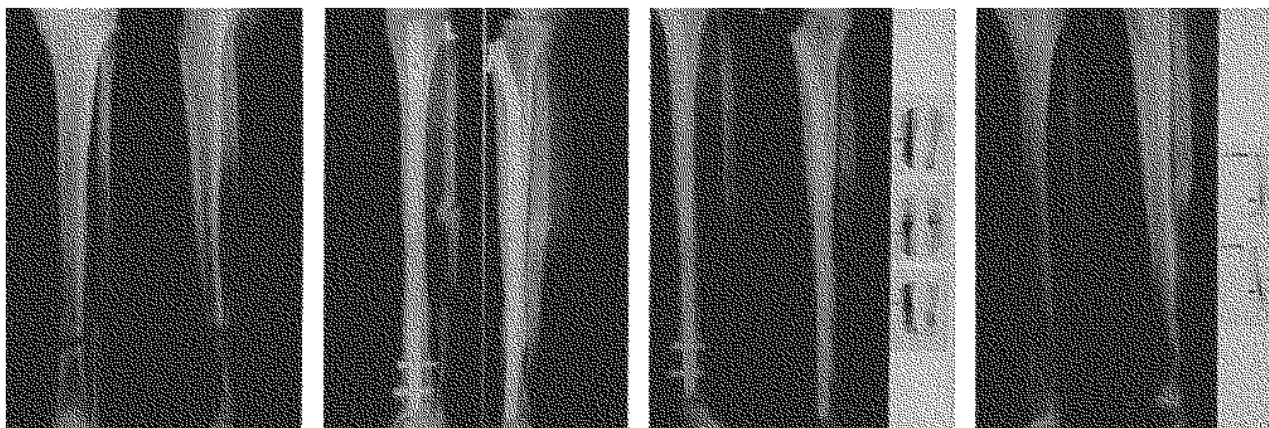
*Fig. 2d*

**Fig. 2.** — a. Spiral fracture of the distal third of the right tibia sustained while practicing judo.  
b. Appearance after static nailing.  
c. Status after dynamization, 1 month later.  
d. Result at 3 months postinjury.

consolidated fracture. The interlocking nail was removed and gentamycin-PMMA beads were implanted. With oral antibiotics, the parameters of infection rapidly returned to baseline values. Although scout xrays and tomograms remain sug-

gestive of a sequestrum, there has been no recurrence two years after the acute episode (fig. 3).

c. Finally, there are the 2 patients with an infected pseudarthrosis in whom the infection was reactivated.



*Fig. 3a*

*Fig. 3b*

*Fig. 3c*

*Fig. 3d*

*Fig. 3.* ... a. Open fracture of the distal third of the tibia sustained in a bumper trauma. Appearance after 6 months of immobilization.

b. Healing of the fracture 3 months after dynamic nailing and immediate weightbearing.

c. Fourteen months postoperatively, lysis around the nail is seen following phlebitis complicated by an ulcer. Positive bone scan, showing involvement of the entire tibia (arrow).

d. Two years after nail removal a sequestrum still persists (arrow), presenting as a hot spot on the bone scans (arrowhead) normal clinical appearance.

5. One patient who had sustained a crush injury presented with an atonic fistula at the fracture site which healed spontaneously.

6. Generalized infections occurred in 4 intubated multiply injured patients who developed pneumonia with sepsis; in none of them was a focal infection observed. Surgery always preceded the occurrence of pneumonia.

7. Loosening of the distal screws occurred in 1 case.

8. Removal of a bone fragment in producing skin irritation at the fracture site was necessary in 1 case.

9. Pulmonary embolism was encountered twice: one patient already had a deep venous thrombosis

with microemboli before surgery. Heparin therapy was stopped 24 hours before the intervention and reinstated immediately postsurgery, in combination with oral anticoagulants. In the second patient massive heart failure developed a few days postoperatively with temporary cardiac arrest; he recovered without permanent disability.

10. In another patient with a deep venous thrombosis extending into the common femoral vein a thrombectomy was performed and a temporary AV shunt applied.

11. As stated previously, there were 3 cases with only partial bridging of the fracture gap. This had no clinical implications.

12. There were 2 total treatment failures.

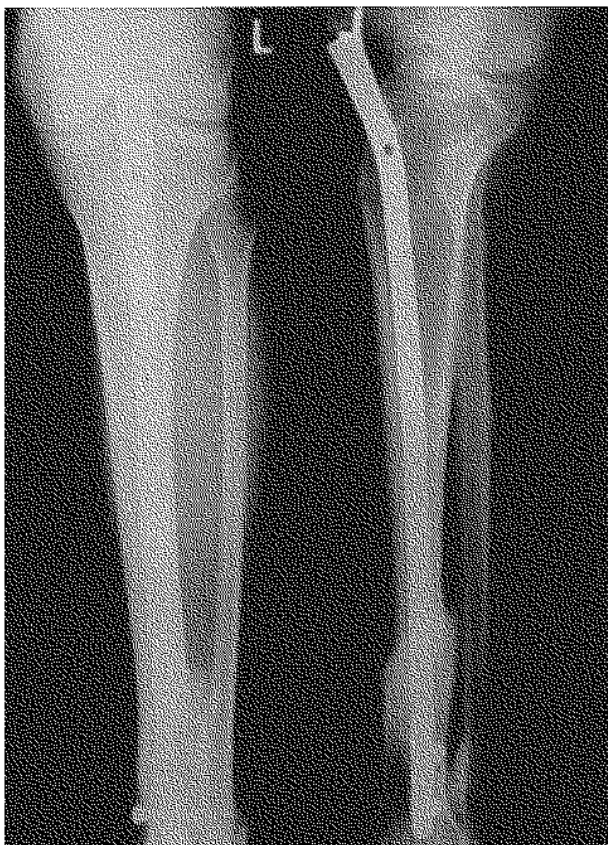
13. Three patients presented with an irritation of the patellar tendon with a mild antalgic extension leg. Removal of the nail permitted full extension.

14. In 3 elderly patients the callus and the entire skeleton were severely osteoporotic.

15. In 3 cases an intraoperative error was committed, resulting in a rotational malalignment at the fracture site (external rotation lag of 5° to 10°).

16. Three patients presented a length discrepancy of the lower extremities :

- 1.5 cm in the patient with telescoping after dynamization (fig. 4).
- 1.5 cm in a patient with bilateral tibial and femoral fractures (0.5 cm shortening of the tibia).
- 2.5 cm after surgery in a patient with an in-



*Fig. 4.* — Telescoping at 2 months postoperatively after dynamization and full weightbearing. Leg length discrepancy of 1.5 cm.

fectured pseudarthrosis, who already presented with limb shortening before surgery (1.5 cm).

17. In 2 cases there was mild varus malalignment at the fracture site :  $\pm 5^\circ$ , of no clinical significance.

18. Fatigue fracture of the nail was never observed in this first series of 60 nailings. There was, however, one case of breakage during extraction.

At the conclusion of the study, the nail had been removed in 21 patients at an average of 1 year 3.5 months postsurgery (7 months to 3 years 9 months). The patients are advised to have the nail removed one year after the operation. In 1 patient the nail fractured in a proximal screw hole on extraction and the distal part had to be left in situ.

### C. Treatment outcome

The final result was assessed during clinical and radiological criteria. Four patients were not included in the classification.

Two of these patients with severe cerebral trauma were physically and mentally so disabled that a clinical evaluation proved impossible ; the radiographic result was excellent.

One patient died, and one patient with a pseudarthrosis sustained a new bifocal tibial fracture, which healed without further complications.

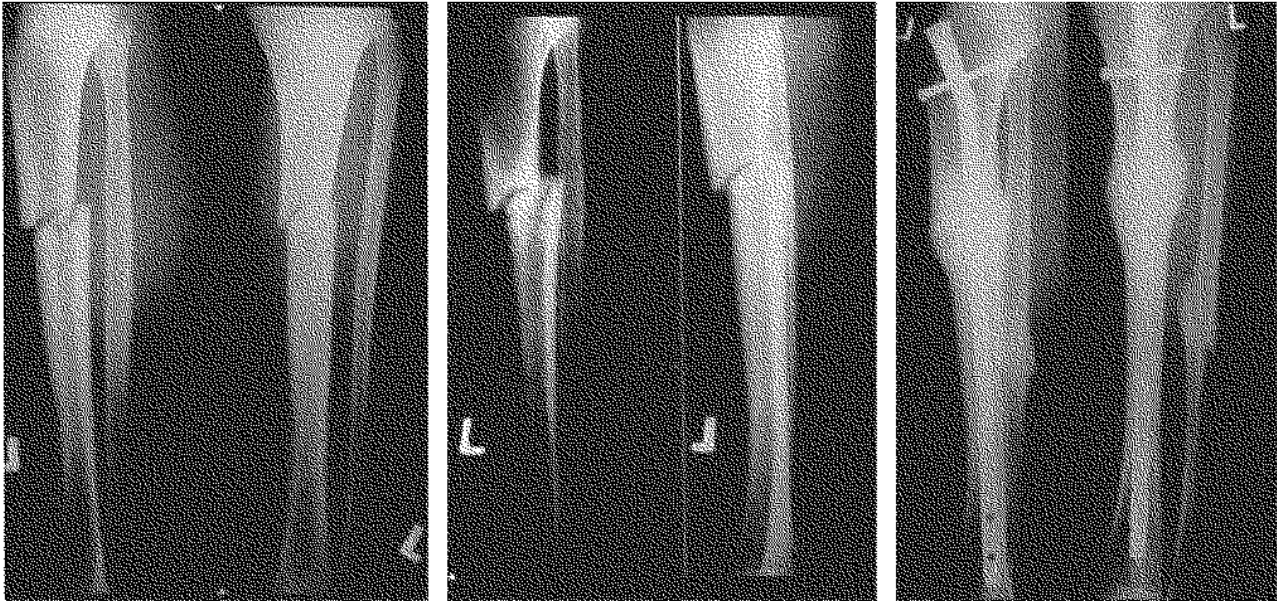In the remaining 56 patients the results were as follows :

- excellent : 40
- good : 6 (2 due to associated lesions)
- moderate : 6 (5 due to associated lesions, 1 telescoping)
- poor : 3 (2 had osteomyelitis, and 1 had poor callus formation).

The patients with a pseudarthrosis (fig. 5) were rated as follows :

- excellent : 5
- good : 1 (due to associated lesions)
- moderate : 1 (due to associated lesions)
- poor : 2 (reactivation of osteomyelitis in both cases).



*Fig. 5a**Fig. 5b**Fig. 5c*

*Fig. 5.* — a. Closed fracture of the proximal third of the left tibia sustained in football.  
 b. Absence of bridging callus after 6 months of conservative treatment. Dynamic nailing and fibulotomy were performed with immediate postoperative weightbearing.  
 c. Two months postoperatively, solid bridging callus and consolidation were achieved.

## DISCUSSION

Tibial shaft fractures carry a high complication rate; infections and pseudarthroses are common findings. Although this is not a comparative study, the interlocking nail seems to score well with regard to these two parameters (7). With the proper indications, the risk of infection is low: in our series the two infections that led to permanent morbidity were preexistent.

Although interlocking nailing was initially used as a treatment for infected pseudarthroses (6, 8), the current external fixation techniques are more suitable to address these problems. Despite the fact that the results were inconclusive in two cases, we would also recommend the latter method for previously infected pseudarthroses, since a long period of quiescence with normalization of all parameters of infecting is not conclusive evidence of total eradication.

Moreover, the intramedullary nail is responsible for spread of the infection to the entire shaft.

Varicose veins, ulcers and skin infections of the lower extremities also predispose to deep infection. If the coverage of the screw at the patellar tendon is poor, even minor trauma may be sufficient to create a port of entry for pathogenic organisms. In this series, generalized infection and sepsis have not resulted in osteomyelitis.

As for quality of callus formation, discrete radiographic disruption of the cortex was observed in only 3 acute cases. In only 1 of these patients (age 87 years) was the bridging callus of inferior quality. The time to solid periosteal callus formation was the same in the 8 patients with an aseptic pseudarthrosis as those with fresh fractures (4).

A fibulotomy was performed in 4 patients with a pseudarthrosis. The need for it has recently been questioned (1), and this seems to be confirmed in the present series. Admittedly, its usefulness is not firmly established from a biomechanical viewpoint.

We agree with others that an open procedure with supplemental bone grafts (not performed on

this series) is not superior to closed nailing techniques (1, 2). We succeeded in obtaining consolidation of the pseudarthrosis in a relatively short period of time, notably 4 months 6 days, which is comparable to the union rate observed in fresh fractures.

Solid callus is formed more rapidly with the dynamic method of interlocking nailing; thanks to the static loading, consolidation is achieved sooner.

The method has some additional advantages :

All shaft fractures can be treated using a standard technique of closed fracture treatment (12, 13). The procedure is technically not very demanding, but there are quite a few technical pitfalls which may lead to serious complications with this type of fracture (14). Particular attention must be paid to rotational stability, which must be achieved by visual determination and the time of dynamization.

The operating time is short : in our series 1 hour 14 minutes, including patient preparation and positioning. The duration of surgery is proportional to the experience of the surgeon and xray technician.

Because of early mobilization the joints above and below the fracture site remain fully mobile, and the risk of thrombosis is low. The patient's spirits are excellent, and nursing is easy (12, 13).

Early weightbearing and rapid restoration of gait ability (12, 13) are possible. Even static nailings seem to tolerate axial loading, although this should not become routine practice. Elderly patients are allowed to ambulate on a static nail, thus avoiding the detrimental effect of prolonged immobilization.

Offsetting these advantages of interlocking nailing are :

— The risk of irradiation to the staff, although these hazards can be minimized in experienced centers.

— Spread of infection to the entire length of the tibia.

— Irritation of the patellar tendon, sometimes leading to a minor extension lag which resolves on extraction of the nail.

— Difficult nail extraction in some instances.

## CONCLUSION

Interlocking nailing provides excellent stabilization of fresh closed or open (grade I and II) fractures of the tibial shaft and aseptic pseudarthroses with a minor bone defect.

## REFERENCES

1. Delefortrie G., Taglang G., Mahieu Ch., Vincent A. Apport de l'enclouage verrouillé dans le traitement des pseudarthroses diaphysaires aseptiques du membre inférieur. *Acta Orthop. Belg.*, 1986, 52, 651-660.
2. Grosse A., Kempf I., Laforgue D. Le traitement des graves pertes de substance osseuse et pseudarthroses du fémur et du tibia par l'enclouage verrouillé. *Rev. Chir. Orthop.*, 1978, 64, suppl. II, 33-35.
3. Kempf I., Grosse A., Laforgue D. L'apport du verrouillage dans l'enclouage centro-médullaire des os longs. *Rev. Chir. Orthop.*, 1978, 64, 635-651.
4. Kempf I., Grosse A., Regaut P. The treatment of non-infected pseudarthrosis of the femur and tibia with locked intramedullary nailing. *Clin. Orthop.*, 1986, 212, 1422-154.
5. Klemm K., Schellman W. D. Dynamische und statische Verriegelung des Marknagels. *Monatsschr. Unfallheilkunde*, 1972, 75, 568-575.
6. Klemm K. Die Verriegelungsnagelung bei infizierten Pseudarthrosen. *Hefte zur Unfallheilkunde*, 1983, 161, 180-186.
7. Klemm K., Börner M. Interlocking nailing of complex fractures of the femur and tibia. *Clin. Orthop.*, 1986, 212, 89-100.
8. Klemm K. Treatment of infected pseudarthrosis of the femur and the tibia with an interlocking nail. *Clin. Orthop.*, 1983, 212, 174-181.
9. Küntscher G. Die Marknagelung von Knochenbrüchen. *Arch. Klin. Chir.*, 1940, 200, 443.
10. Küntscher G. Practice of intramedullary nailing. (trans. H. H. Rinne), Springfield, Ill., Ch. C. Thomas, 1967, pp. 85-96.
11. Küntscher G. Die Marknagelung des Trümmerbrüches. *Langenbecks Arch. Klin. Chir.*, 1968, 322, 1063-1069.
12. Olerud S., Karlstrom G. The spectrum of intramedullary nailing of the tibia. *Clin. Orthop.*, 1986, 212, 101-112.
13. Puno R., Teynor J., Nagano J., Gustilo R. Critical analysis of results of treatment of 201 tibial shaft fractures. *Clin. Orthop.*, 1986, 212, 113-121.
14. Reinders J., Mockwitz J. Technical faults and complications in interlocking nailing of femoral and tibial fractures. *Acta Orthop. Belg.*, 1984, 50, 577-590.



## SAMENVATTING

A. HARTH, J. MOERMAN, W. DE GROOTE, B. VANDEKERCKHOVE, R. VERBEKE, R. VERDONK, H. CLAESSENS. *Behandeling van diafysaire fracturen van de tibia met de grendelpen.*

Tussen 1982 en 1986 werden 60 tibiaschaftfracturen, waaronder 10 pseudarthrosen, behandeld met de grendelpenmethode.

De resultaten werden bekeken na minimaal 2 jaar follow-up: zowel voor de acute fracturen als voor de pseudarthrosen geeft de techniek zeer aanvaardbare resultaten: slechts 3 op 60 gevallen hebben een slecht eindresultaat:

De voordelen van de techniek zijn:

- bijna alle diafysaire fracturen zijn behandelbaar
- gesloten fractuurbehandeling
- vlotte operatieve ingreep
- snelle mobilisatie en belasting
- laag infectierisico
- snelle consolidatie.

Relatieve nadelen zijn:

- de stralingsbelasting
- de langere preoperatieve voorbereiding
- de aantasting van de gehele diafyse wanneer toch infectie optreedt
- irritatie van de patellapees.

Besluit: voor verse diafysaire tibiafracturen (behalve graad III open fracturen) en voor aseptische pseudarthrosen zonder groot botdeficiet, is de grendelpen een uitstekende behandelingsmethode.

## RÉSUMÉ

A. HARTH, J. MOERMAN, W. DE GROOTE, B. VANDEKERCKHOVE, R. VERBEKE, R. VERDONK, H. CLAESSENS. *Traitement des fractures diaphysaires du tibia par enclouage verrouillé.*

De 1982 à 1986, 60 fractures diaphysaires du tibia ont été traitées par enclouage verrouillé. Dans 10 cas l'indication était une pseudarthrose.

Les résultats sont évalués avec un recul de plus de 2 ans. Ils sont satisfaisants tant pour les fractures simples que pour les pseudarthroses. Dans 3 des 60 patients le résultat fut médiocre.

Les avantages de la technique sont les suivants:

- technique est applicable dans presque tous les cas de fracture diaphysaire
- opération facile
- mobilisation et appui précoces
- risque d'infection minime
- consolidation rapide.

Désavantages relatifs:

- exposition aux rayons X
- installation préopératoire plus longue
- en cas d'infection, atteinte de la diaphyse en entier
- irritation du tendon rotulien.

Conclusion: l'enclouage verrouillé donne une stabilité excellente des fractures diaphysaires récentes du tibia, ouvertes ou non, et des pseudarthroses aseptiques sans perte de substance importante.