

THE FEMORAL SUPRACONDYLAR NAIL : PRELIMINARY EXPERIENCE

T. SCHEERLINCK, P. KRALLIS, P.-Y. DESCAMPS, D. HARDY, P. DELINCÉ

The treatment of supracondylar fractures of the femur with an intramedullary nail presents some theoretical advantages. Compared to plate osteosynthesis, intramedullary fixation requires less extensive dissection and is biomechanically more favorable. In the elderly patient, these characteristics seem important since bone quality, extensive procedures and bone grafting remain problematic.

Since August 1994 we have treated 16 consecutive closed fractures of the distal femur (A.O. type : 7 A.1, 2 A.3, 4 C.1, and 3 C.2) with the Green-Seligson-Henry intramedullary retrograde supracondylar nail. Twelve elderly and osteoporotic patients had suffered low-energy trauma, three young patients had been involved in a traffic accident and one other young patient had attempted suicide. The operative technique, complications and results are described. All fractures healed within a few months (2 to 7) without bone grafting. No failure of the fixation material and no deep infection were encountered. With most elderly patients the functional result was judged satisfactory, considering the population studied. Intraoperative determination of alignment and avoiding shortening were the major difficulties, especially with long oblique or comminuted fractures.

Two major complications were encountered in the young population. In one instance nail protrusion in the intercondylar notch caused a deep patellar cartilage erosion and sympathetic dystrophy leading to a 15° flexion deformity. Another young patient needed a quadriceps release at the fracture site and subsequently a femoral valgus osteotomy in order to achieve an acceptable final result.

In elderly osteoporotic patients presenting an isolated supracondylar fracture, antegrade nailing remains the "safest" technique by avoiding an unnecessary arthrotomy. When previous hip or knee surgery precludes the use of antegrade nailing techniques or when the

fracture extends into the intercondylar region, retrograde supracondylar nailing offers some advantages compared to conservative treatment or plate osteosynthesis. On the other hand in young patients, anatomic reduction and alignment should be the goal, and open reduction with plate osteosynthesis, supplemented by bone grafting if needed, should remain the gold standard. When this seems technically impossible, the antegrade or retrograde insertion of an intramedullary nail with intraoperative assessment of length and fracture alignment is an interesting alternative.

Keywords : femur ; supracondylar fracture ; retrograde intramedullary nail.

Mots-clés : fémur ; fracture supra-condylienne ; clou centromédullaire rétrograde.

INTRODUCTION

Because of frequent complications associated with protracted bedrest in the elderly and less predictable results in younger patients, operative rather than conservative methods have been preferred for supracondylar fracture treatment (2, 9, 23, 27, 33). Classic osteosynthesis with single or double buttress plates (30), a 95° dynamic condylar screw or a condylar blade plate (5, 22, 28) requires extensive soft tissue dissection and bone devascularization, often making bone grafting indispensable. Complications such as deep infection (0 to

Department of Orthopedic Surgery and Traumatology, C.H.U. St.-Pierre, Brussels, Belgium.

Correspondence and reprints : T. Scheerlinck, Peckhoevelaan 14, 2610 Wilrijk, Belgium.

5.8% and up to 20% in older series), nonunion (0 to 4%) or secondary displacement are not exceptional despite correct initial reduction (15, 24).

For these reasons intramedullary devices such as an antegrade but "shortened" intramedullary nail (1, 18), the Zickel nail and other elastic or semielastic pins (8, 16, 20, 34), the Huckstep nail (11, 31), the Derby nail (29) and finally the Green-Seligson-Henry (GSH) nail (3, 4, 6, 10, 12, 17, 19) progressively gain popularity. Their intramedullary location gives them a biomechanical advantage, and they require less extensive dissection, which might result in fewer complications.

The idea of a retrograde supracondylar nail is certainly not new, but the introduction of the GSH intramedullary supracondylar nail (IMSC) offers additional theoretical advantages. The GSH nail is fully cannulated, allowing insertion on a guiding rod. The 8° angulation of its distal part makes it possible to introduce it posteriorly in the intercondylar notch in order to limit interaction with patella tracking. The retrograde insertion through an arthrotomy allows nailing even when knee or hip surgery has been performed previously (13, 21, 25), and the same limited approach can be used to reduce intraarticular fractures. The goal of this study is to evaluate the results obtained in the treatment of supracondylar fractures using this new device in younger and older patients.

PATIENTS AND METHODS

Population

Since August 1994, 16 consecutive patients with a supracondylar femoral fracture were treated using an intramedullary supracondylar nail (IMSC, Smith & Nephew Richards, Memphis, Tennessee). Two distinct patient groups could be identified. Twelve patients were elderly (68 to 98 years, mean 83 years), osteoporotic and in poor general condition (group I). Four of them had undergone a previous operation on the same femur: one had an intertrochanteric hip fracture fixed with a screw-plate, another was left with a Girdlestone resection, the third had a total hip arthroplasty and the last a metaphyseal tibial fracture treated using a femorotibial nail removed many years previously. A fifth patient presented a pathological fracture. All

patients suffered their fracture as a result of a low-energy trauma such as a fall from their height or an improper nursing manipulation.

The four patients in the second group were young (24 to 38 years, mean 32 years) and in better general condition (group II). Their fractures were caused by high-energy trauma (traffic accident, defenestration) and were associated with other lesions. One of them presented a paraparesis after a cervical medullary contusion, a Lefort II and III fracture as well as a scapular fracture. The others had multiple fractures of the ipsi- and/or contralateral leg.

Fracture types

Fractures were intra- or extraarticular but always extended into the supracondylar region. In extraarticular fractures the degree of comminution was variable, ranging from transverse nondisplaced to pathological and severely comminuted (A.O. classification (26): 7 A.1 and 2 A.3). Intraarticular fractures were always displaced and completely intercondylar (A.O. classification: 4 C.1 and 3 C.2). Fracture types in the two patient groups are shown in table I.

Table I. — Fracture type according to the patient group

Fracture type	Group I	Group II	Total
A1	6	1	7
A3	1	1	2
C1	3	1	4
C2	2	1	3

Surgical technique

Positioning of the patient and approach

The patient lies in the supine position on the operating table, his uninjured leg resting on a support with maximal hip flexion and abduction. The injured leg lies freely on a leg support bent at 50°. Neither traction nor tourniquet is used. The injured leg is wrapped in a standard extremity set, and the fluoroscopic c-arm is advanced from the lateral side. This set-up provides easy access to the knee and a good fluoroscopic view in the frontal and lateral plane (Fig. 1).

All cases were operated through a medial parapatellar arthrotomy. For extraarticular fractures lateral subluxation of the patella was often sufficient to gain access to the intercondylar notch. Intraarticular fractures

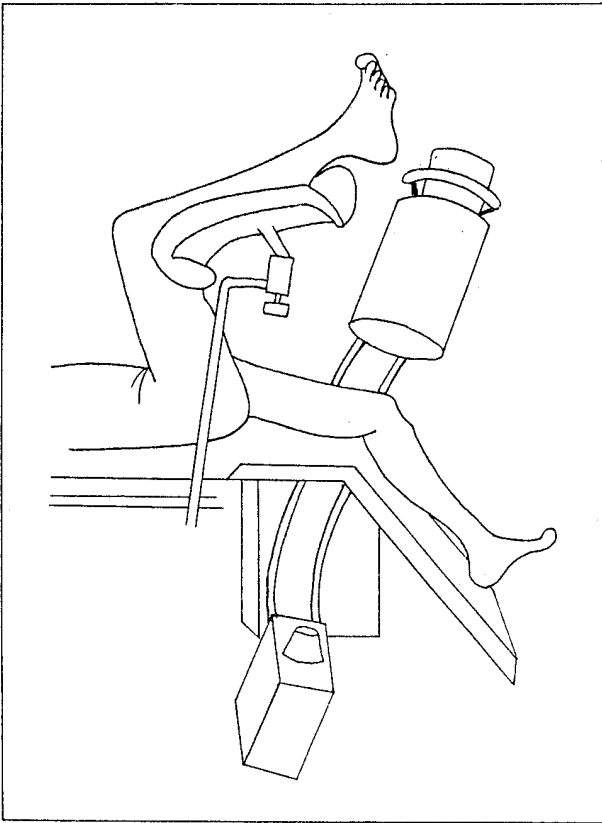


Fig. 1. — Positioning of the patient. The uninjured leg rests on a support with maximal hip flexion and abduction. The injured leg lies freely on a bent leg support. The fluoroscopic C-arm is advanced from the lateral side.

required complete lateral dislocation of the patella to allow better visualization of the articular surfaces. Every effort was made to avoid opening the supracondylar fracture site in order to limit devascularization. Bone grafting was never used.

Osteosynthesis

Intraarticular fractures were first reduced and fixed with 2 or 3 K-wires from the medial or lateral side. Care was taken to insert them at least 15 mm apart, to allow the introduction of the IMSC nail in between. The K-wires were replaced by cannulated screws (\varnothing 6.5 mm).

After closed reduction of the supracondylar fracture, a guiding rod was introduced through an intercondylar entry point situated a few mm to 1 cm above the insertion of the posterior cruciate ligament (PCL) as described by Seligson and Henry (32). The distal femur was then reamed to a diameter 1 mm above that of

the nail. The nail was fixed to the drill guide and the alignment with the interlocking holes was checked. The nail was introduced over the guiding rod into the medullary cavity and countersunk a few mm into the intercondylar notch. Fracture alignment was checked and the most proximal interlocking hole was drilled first; the sleeve and drill were left in place to enhance stability and prevent secondary displacement while drilling more distal holes. The arthrotomy was closed with resorbable suture on a suction drain.

Postoperative care

Prophylactic antibiotics (cefazolin 1g t.i.d.) were administered for the first 48h, but no anticoagulants were used. When possible, patients were seated in an armchair on the first postoperative day and full range-of-motion physiotherapy was started. Between physiotherapy sessions an analgic removable knee extension brace was used, and patients were encouraged to move their ankles. Those patients able to walk without weight bearing received gait training within a week of the operation. Full weight bearing was authorized after clinical and radiological evidence of fracture healing.

RESULTS

All operations were performed by experienced orthopedic surgeons. Operation time ranged from 1 to 1.5 hours. A nail diameter of 12 mm was found to be most frequently appropriate (11 out of 16 cases); the 11-mm nail was used only twice and the 13-mm three times. Regarding nail length, a 200-mm nail was used in 9 cases while 6 patients had a 250-mm and one a 150-mm nail inserted. The number of locking screws ranged from 3 to 9 depending on fracture type and bone quality.

Follow-up

Owing to old age and a high degree of physical and mental debilitation 5 of the 12 patients in group I could not walk or stand properly prior to operation. All other patients in this group recovered their walking or standing ability within 2 to 7 months postoperatively. Three of our four young patients (group II) experienced walking difficulties. One had a paraparesis (cervical trauma), another had a knee flexion deformity of 15° (see complications), and the third needed a

Table II. — Clinical and radiological results

Flexion		Extension lag		Shortening		Axial deviation**	
> 110°	5	0-5°	5	0-1 cm	2	0-5°	6
110°-90°	5	6-10°	4	1-3 cm	7	6-10°	2
< 90°	1*	> 10°	1 + 1*	> 3 cm	1 + 1*	> 10°	1 + 1*

* One patient had a stiff knee prior to trauma owing to a femorotibial nail. Premature removal of the distal locking screws caused secondary impaction and varisation.

** Only 10 cases are presented because the axial deviation is not relevant in the patient with the Girdlestone resection.

quadriceps muscle release followed by a femoral osteotomy to regain a normal walking pattern.

Eleven patients (7 from group I and 4 from group II) were reviewed after fracture healing between 3.5 and 18 months after surgery. Two patients from group I died from unrelated causes a few weeks or months after the operation. One was able to walk without aid 4 months postoperatively; the other was hemiplegic. Three patients were lost to follow-up; one of them informed us that she was able to walk without aid.

All patients reviewed who had normal knee flexion previously (10 patients) reached at least 90° of flexion (90°-140°). An extension lag of 5° or less was found in 5 patients, between 6 and 10° in 4 others and more than 10° in 2. All fractures reviewed were clinically and radiologically healed between 2 and 7 months. By that time a scaniometry and a radiological assessment of the mechanical axis of the operated leg were performed. Results are shown in table II.

Complications

In one patient two proximal locking screws were driven into the femur anterior to the nail. This had no influence on the final result.

Hardware had to be removed in 4 patients. One had an early superficial infection resulting in skin perforation by two distal locking screws. These had to be removed before fracture healing, which led to secondary impaction and protrusion of the distal tip of the nail into the knee. Eventually, the fracture healed without further complications, leaving a completely ankylosed knee at 25° of flexion, 24° of varus and a femoral shortening

of 31 mm. This occurred in a patient who already had a stiff knee owing to a previous femorotibial nail. However, today she is able to walk 50 m with a walking aid and a shoe-lift. In another cachectic patient, two distal screws perforated the skin after fracture healing and had to be removed. One of our youngest patients, who was initially lost to follow-up, had his hardware removed in another hospital. He presented a flexion deformity of 15°, 125° of knee flexion, and major quadriceps atrophy. Reflex sympathetic dystrophy developed as a result of a cartilaginous ulceration of the patella due to friction of the distal extremity of the nail protruding into the intercondylar notch. Another young patient needed a quadriceps release at the fracture site and subsequently a distal femoral valgus osteotomy in order to achieve an acceptable result.

DISCUSSION

The treatment of supracondylar fractures of the femur remains a challenge even for the most experienced orthopedic surgeon. No single universal osteosynthesis technique can meet all requirements of stability, predictability, low complication rate and anatomic reduction. One should gain experience with several techniques, in order to adapt to the patient, the fracture configuration and local considerations such as osteoporosis, open fractures, soft tissue damage or associated lesions.

The development of the IMSC nail seemed attractive to us, as it combines an intraarticular approach allowing an open anatomic reduction of the articular fracture component with minimal soft tissue dissection and rigid fixation. This resulted

in early mobilization, facilitated nursing, especially in elderly debilitated patients and led, as in other series (3, 4, 12, 19), to high consolidation rates. Except in one case where hardware removal was necessitated by superficial infection, no secondary displacement was noted. In contrast to other reports (3, 12, 19), no deep infections, no hardware breakage and no nonunion occurred, but all our fractures were closed.

The overall functional results considering age, preoperative status and associated injuries, were judged favorable at least in the elderly population (group I). However we experienced difficulties in evaluating and restoring proper knee alignment. This could probably be improved by intraoperative assessment of the limb axis prior to definitive locking of the nail. In comminuted and long oblique fractures control of shortening was found problematic too. In such situations, the use of a traction device might be beneficial although distraction without bone grafting could increase the risk of nonunion.

The technique requires an arthrotomy, and this carries the risk of joint stiffness and septic arthritis in nonarticular fractures which could have been treated with a "shortened" antegrade nail (1, 18, 35). Although no septic complications were encountered in the present series, joint stiffness was a problem in several patients. In order to avoid a medial arthrotomy, a transpatellar tendon approach has been described by Green (6), and an arthroscopy assisted nail insertion technique has even been reported (7). However we have no experience with these techniques. Displaced intraarticular fractures on the other hand, require an arthrotomy anyway in order to obtain proper reduction. Nail insertion through the same approach was found very convenient. The IMSC can also be used when hardware or proximal deformity precludes antegrade nailing, and it offers the possibility of multiple distal screw insertion through the nail. Compared to the "shortened" antegrade nailing technique that allows only two distal screws, this can be an advantage, especially in very distal fractures or when bone quality is problematic.

In one instance we encountered a severe patellar cartilage ulceration due to intraarticular protrusion

of the nail in the intercondylar notch, causing a reflex sympathetic dystrophy and severe functional impairment in a young patient. Articular synovial metallosis, as described by Johnson *et al.* (14), was not encountered at hardware removal, but it seems particularly important to insert the nail posteriorly in the notch and to bury it at least a few mm below the articular surface.

One should also keep in mind that anatomic reduction or alignment of the metaphyseal fracture component is often not obtained without the use of a traction device, if the fracture site has to remain closed. In four of the reviewed cases, this led to an axial deviation of more than 5°, which required a corrective femoral osteotomy in one of the younger patients. Although probably beneficial for fracture healing, shortening of more than 1 cm was encountered in nine of the eleven patients available for final radiographic assessment. Because of this, caution should be shown regarding the systematic use of this device in the young and active patient with a severe impacted or comminuted fracture. In those cases we prefer a more anatomic reduction held by firm internal fixation and if necessary supplemented by bone grafts. If this seems technically impossible, the insertion of an intramedullary nail with the aid of a traction device can lead to proper alignment and prevent severe shortening. In older osteoporotic patients, when previous hip or knee surgery prevents the use of an antegrade nailing technique or when supracondylar fractures extend into the knee joint, the IMSC nail can be an attractive alternative to a long and difficult conservative treatment, a femorotibial nail or a difficult and potentially precarious open reduction-fixation.

REFERENCES

1. Butler M., Brumack R., Scott Ellison T., Poka A., Howard Bathon G., Burgess A. Interlocking intramedullary nailing for ipsilateral fractures of the femoral shaft and distal part of the femur. *J. Bone Joint Surg.*, 1991, 73-A, 1492-1502.
2. Connolly J., Dehne E., Lafollette B. Closed reduction and early cast-brace ambulation in the treatment of femoral fractures. Part II: Results in one hundred and forty-three fractures. *J. Bone Joint Surg.*, 1973, 55-A, 1581-1599.

3. Danziger M., Caucci D., Zecher S., Segal D., Covall D. J. Treatment of intercondylar and supracondylar distal femur fractures using the GSH supracondylar nail. *Am. J. Orthop.*, 1995, 24, 684-690.
4. Gellman R., Paiement G., Green H., Coughlin R. R. Treatment of supracondylar femoral fractures with a retrograde intramedullary nail. *Clin. Orthop.*, 1996, 332, 90-97.
5. Giles J., DeLee J., Heckman J., Keever J. Supracondylar-intercondylar fractures of the femur treated with a supracondylar plate and lag screw. *J. Bone Joint Surg.*, 1982, 64-A, 864-870.
6. Green S. Distal intramedullary fixation of supracondylar fractures of the femur. *Techniques Orthop.*, 1988, 3, 71-76.
7. Guerra J., Della Valle C., Corcoran T., Torg J., Duda J. Arthroscopically assisted placement of a supracondylar intramedullary nail : Operative technique. *Arthroscopy*, 1995, 11, 239-244.
8. Healey J., Lane J. M. Treatment of pathological fractures of the distal femur with the Zickel supracondylar nail. *Clin. Orthop.*, 1990, 250, 216-220.
9. Healy W., Brooker A. Jr. Distal femoral fractures. Comparison of open and closed methods of treatment. *Clin. Orthop.*, 1983, 174, 166-171.
10. Henry S., Trager S., Green S. Seligson D. Management of supracondylar fractures of the femur with the GSH intramedullary nail : Preliminary report. *Contemp. Orthop.*, 1991, 22, 631-640.
11. Huckstep R. The Huckstep intramedullary compression nail. Indications, technique, and results. *Clin. Orthop.*, 1986, 212, 48-61.
12. Iannacone W., Bennett F., DeLong W., Born C., Dalsey R. Initial experience with the treatment of supracondylar femoral fractures using the supracondylar intramedullary nail : Preliminary report. *J. Orthop. Trauma*, 1994, 8, 322-327.
13. Jabczynski F., Crawford M. Retrograde intramedullary nailing of supracondylar fractures above total knee arthroplasty. A preliminary report of four cases. *J. Arthroplasty*, 1995, 10, 95-101.
14. Johnson E., Marroquin C. E., Kossovsky N. Synovial metallosis resulting from intraarticular intramedullary nailing of a distal femoral nonunion. *J. Orthop. Trauma*, 1993, 7, 320-326.
15. Johnson K., Hicken G. Distal femoral fractures. *Orthop. Clin.*, 1987, 18, 115-132.
16. Kolmert L., Egund N., Persson B. Internal fixation of supracondylar and bicondylar femoral fractures using a new semielastic device. *Clin. Orthop.*, 1983, 181, 204-219.
17. Koval K., Seligson D., Rosen H., Fee K. Distal femoral nonunion : Treatment with a retrograde inserted locked intramedullary nail. *J. Orthop. Trauma*, 1995, 9, 285-291.
18. Leung K., Shen W., So W., Mui L., Grosse A. Interlocking intramedullary nailing for supracondylar and intercondylar fractures of the distal part of the femur. *J. Bone Joint Surg.*, 1991, 73-A, 332-340.
19. Lucas S., Seligson D., Henry S. Intramedullary supracondylar nailing of femoral fractures. A preliminary report of the GSH supracondylar nail. *Clin. Orthop.*, 1993, 296, 200-206.
20. Marks D., Isbister E., Porter K. Zickel supracondylar nailing for supracondylar femoral fractures in the elderly or infirm patients. A review of 33 cases. *J. Bone Joint Surg.*, 1994, 76-B, 596-601.
21. McLaren A., Dupont J., Schroeber D. C. Open reduction internal fixation of supracondylar fractures above total knee arthroplasties using the intramedullary supracondylar rod. *Clin. Orthop.*, 1994, 302, 194-198.
22. Mize R., Bucholz R., Grogan D. P. Surgical treatment of displaced, comminuted fractures of the distal end of the femur. An extensile approach. *J. Bone Joint Surg.*, 1982, 64-A, 871-879.
23. Mooney V., Nickel V., Harvey J., Snelson R. Cast-brace treatment for fractures of the distal part of the femur. A prospective controlled study of a hundred and fifty patients. *J. Bone Joint Surg.*, 1970, 52-A, 1563-1578.
24. Moore T., Watson T., Green S. A., Garland D. E., Chandler R. W. Complications of surgically treated supracondylar fractures of the femur. *J. Trauma*, 1987, 27, 402-406.
25. Murrell G., Nunley J. Interlocked supracondylar intramedullary nails for supracondylar fractures after total knee arthroplasty. *J. Arthroplasty*, 1995, 10, 37-42.
26. Müller M., Nazarian S., Koch P., Schatzker J. The comprehensive classification of fractures of long bones. Berlin. Springer Verlag. 1990, p. 140.
27. Neer C., Ashby Grantham S., Shelton L. Supracondylar fracture of the adult femur. A study of one hundred and ten cases. *J. Bone Joint Surg.*, 1967, 49-A, 591-613.
28. Olerud S. Operative treatment of supracondylar-condylar fractures of the femur. Technique and results in fifteen cases. *J. Bone Joint Surg.*, 1972, 54-A, 1015-1032.
29. Papagiannopoulos G., Clement D. Treatment of fractures of the distal third of the femur. A prospective trial of the derby intramedullary nail. *J. Bone Joint Surg.*, 1987, 69-B, 67-70.
30. Sanders R., Swiontkowski M., Rosen H., Helfet D. Double-plating of comminuted, unstable fractures of the distal part of the femur. *J. Bone Joint Surg.*, 1991, 73-A, 341-346.
31. Sekel R. Supracondylar fractures above a total knee arthroplasty. A novel use of the Huckstep nail. *J. Arthroplasty*, 1994, 9, 445-447.
32. Seligson D., Henry S., Green S. Intramedullary supracondylar nail. Surgical technique. Smith & Nephew Richards. Memphis, Tennessee. 1994. pp.1-28.
33. Shahcheraghi G., Doroodchi H. Supracondylar fracture of the femur : Closed or open reduction? *J. Trauma*, 1993, 34, 499-502.
34. Shelbourne K., Brueckmann F. R. Rush-pin fixation of

supracondylar and intercondylar fractures of the femur. *J. Bone Joint Surg.*, 1982, 64-A, 161-169.

35. Wu C., Shih C. Treatment of femoral supracondylar unstable comminuted fractures. Comparisons between plating and Grosse-Kempf interlocking nailing technique. *Arch. Orthop. Trauma Surg.*, 1992, 111, 232-236.

SAMENVATTING

T. SCHEERLINCK, P. KRALLIS, P.-Y. DESCAMPS, D. HARDY, P. DELINCÉ. De femorale supracondylaire nagel, initiële ervaring.

De behandeling van supracondylaire femorale breuken d.m.v. een centromedullaire nagel vertoont enkele theoretische voordelen. Vergeleken met plaatosteosynthese vergt het plaatsen van een centromedullaire nagel minder dissectie en is de montage stabiel. Voor oudere patiënten is dit belangrijk gezien de minder goede botkwaliteit en het feit dat uitgebreide heelkundige ingrepen met aanbreng van bottenten vaak problematisch zijn.

Sinds augustus 1994 werden 16 opeenvolgende gesloten distale femorale breuken (A.O. classificatie: 7 A.1, 2 A.3, 4 C.1, 3 C.2) d.m.v. de Green-Seligson-Henry retrograde centromedullaire nagel behandeld. 12 patiënten waren oud, osteoporotisch en liepen hun breuk op na een mineur trauma, 3 patiënten waren jong en het slachtoffer van een verkeersongeval en een andere jonge patient deed een zelfmoord poging. De operatietechniek, complicaties en resultaten worden besproken. Alle breuken heelden binnen de enkele maanden (2 tot 7) zonder dat bottenten nodig waren. Er deden zich geen diepe infecties voor en het osteosynthesemateriaal bood de gewenste stabiliteit. De oudere patiënten hadden globaal gezien een vrij goed functioneel resultaat. Het peroperatief herstellen van een correcte mechanische as en lengte zorgde voor de belangrijkste problemen vooral bij schuine of comminutieve breuken. Bij de jonge patiënten deden er zich twee belangrijke complicaties voor. In één geval veroorzaakte protrusie van de nagel in de trochlea een belangrijke kraakbeenerosie t.h.v. de patella. Dit ging gepaard met algoneurodystrofie gevolgd door een extensiedeficiet van 15°. Bij een andere jonge patiënte moest het extensieapparaat vrijgemaakt worden t.h.v. de femorale callus en was een femorale valgus osteotomie noodzakelijk om een goed resultaat te bekomen.

Bij oude osteoporotische patiënten kan een supracondylaire breuk, zonder intra-articulaire component, waarschijnlijk best d.m.v. een antegrade femurnagel behan-

deld worden om zodoende een artrotomie te vermijden. Wanneer echter het gebruik van een antegrade nagel onmogelijk is (bv. door voorafgaande heup- of kniechirurgie) of wanneer de supracondylaire breuk een intra-articulaire component vertoont, biedt de retrograde supracondylaire nagel enkele voordelen t.o.v. een conservatieve behandeling of een plaatosteosynthese. Voor jonge patiënten is een anatomische reductie en het correct herstellen van de mechanische as noodzakelijk. Open reductie en plaatosteosynthese met het eventueel aanbrengen van bottenten blijft in deze gevallen de gouden standaard. Wanneer dit echter technisch niet haalbaar blijkt, is het inbrengen van een retrograde of antegrade centromedullaire nagel, met peroperatieve controle van lengte en mechanische as, een aantrekkelijk alternatief.

RÉSUMÉ

T. SCHEERLINCK, P. KRALLIS, P.-Y. DESCAMPS, D. HARDY, P. DELINCÉ. Le clou fémoral supracondylien : résultats préliminaires.

Le traitement des fractures fémorales supra-condyliennes par clou centro-médullaire offre théoriquement des avantages biomécaniques par rapport à l'ostéosynthèse par plaque vissée et demande une dissection moins étendue. Ces caractéristiques acquièrent une grande importance lorsqu'on s'adresse à des sujets âgés qui supportent difficilement des interventions agressives, et chez lesquels l'os est de mauvaise qualité.

Depuis août 1994, 16 fractures fermées de la partie distale du fémur (type A.O. : 7 A.1, 2 A.3, 4 C.1, 3 C.2) ont été traitées à l'aide du clou supra-condylien rétrograde de type Green-Seligson-Henry. Douze patients âgés et ostéoporotiques ont présenté leur fracture à la suite d'un traumatisme mineur. Trois jeunes patients ont été victimes d'accidents de roulage et un s'est défenestré. La technique opératoire et les complications sont décrites. Toutes les fractures ont consolidé en quelques mois (2 à 7) et ce, sans l'apport de greffes osseuses. Aucune infection profonde n'est survenue. Le résultat fonctionnel de la majorité des cas dans le groupe des patients âgés, a été jugé favorable si l'on tient compte de l'état général de la population étudiée. La difficulté majeure a été le contrôle peropératoire de la qualité de la réduction, surtout dans les fractures obliques et comminutives.

Deux complications importantes chez des patients jeunes sont à déplorer. La protrusion du clou dans

l'échancrure entraîna une lésion cartilagineuse de la rotule, une algodystrophie et un flessus du genou de 15° dans un cas. Une autre patiente a dû subir une libération de l'appareil extenseur au niveau du cal osseux, suivie d'une ostéotomie de valgisation du fémur afin d'obtenir un résultat acceptable.

Pour le patient âgé présentant une fracture supra-condylienne isolée, l'enclouage antégrade reste préférable à l'enclouage rétrograde qui, par sa voie d'abord intra-articulaire, risque d'entraîner une arthrite ou une raideur du genou. Si une chirurgie préalable de la hanche ou du genou ne permet pas l'insertion d'un clou antégrade ou si la fracture supra-condylienne

présente une extension intra-articulaire, le clou supra-condylien offre certainement un avantage par rapport au traitement conservateur ou à l'ostéosynthèse par plaque vissée. Par contre pour le patient jeune, une réduction aussi anatomique que possible doit être obtenue. Cela implique le plus souvent l'abord de la fracture. Ensuite, une fixation solide par plaque vissée, associée à des greffes osseuses, reste le traitement de choix. Si cela s'avère techniquement impossible, l'enclouage centromédullaire rétrograde ou antégrade avec vérification préalable de la longueur et de l'alignement est une alternative intéressante.