



Adverse local tissue reaction after ceramic-on-ceramic total hip arthroplasty

Jérôme VALCARENGHI, Nicolas POINOT, Pierre-Bernard VERSTRAETEN, Esfandiar CHAHIDI, Benoit CAUFRIEZ,
Vincent COSTENOBLE, Xavier COLLARD

*From the Centre Hospitalier Universitaire d'Ambroise Paré, Department of Orthopaedics and Traumatology,
Mons, Hainaut, Belgium*

We report a rare case of symptomatic adverse local tissue reaction in a patient with a ceramic-on-ceramic total hip bearing surface and review the literature. Probably, ceramic wear debris is not entirely inert and may lead to adverse local tissue reactions.

Keywords: Ceramic-on-ceramic; Pseudotumor; Revision total hip arthroplasty; Osteolysis; ALTR

INTRODUCTION

Outside of cobalt-chromium alloy articulations, the development of adverse local tissue reaction (ALTR) after total hip arthroplasty (THA) is uncommon but remains a significant complication (1). ALTR is used to describe a granulomatous or destructive cystic lesion that develops around a THA (1, 2). The patient often describes the first sign of the development of ALTR and pseudotumor formation as discomfort and pain. ALTR causes soft tissue mass, osteolysis, bone erosion, and significant damage to periarticular soft tissues, leading to total joint failure and instability (1). In THA, ALTR may develop around metal-on-polyethylene implants

Conflicts of interests: The authors declared no potential conflicts of interest concerning this article's research, authorship, and/or publication.

Funding acknowledgement: The authors received no financial support for this article's research, authorship, and/or publication.

due to taper corrosion and around metal-on-metal (MoM) bearing surfaces (3-6).

To our knowledge, just one case reported of a pseudotumor related to a ceramic-on-ceramic (CoC) THA (1). In this view, we present this uncommon case of a pseudotumor in a CoC THA.

CASE REPORT

In 2009, a 61-year-old man underwent a right THA for symptomatic hip osteoarthritis. Given the patient's relatively young age for the procedure, the surgeon selected a cementless arthroplasty with CoC articulation. The patient received a 54 mm acetabular component (Horizon II® - Amplitude)

-
- Valcarengi Jérôme, MD
 - Poinot Nicolas, MD
 - Verstraeten Pierre-Bernard, MD
 - Chahidi Esfandiar, MD
 - Caufriez Benoit, MD
 - Costenoble Vincent, MD
 - Collard Xavier, MD

*Centre Hospitalier Universitaire d'Ambroise Paré,
Department of Orthopaedics and Traumatology, Mons,
Hainaut, Belgium.*

Correspondence: Jérôme Valcarengi, Department of Orthopaedics and Traumatology, CHU Ambroise Paré, Boulevard John Fitzgerald Kennedy 2, 7000 Mons, Belgium. Phone number: +32 468 361 338

E-mail: jerome.valcarengi@gmail.com

© 2022, Acta Orthopædica Belgica.

with a modular 36 mm alumina ceramic liner and a 0 mm alumina ceramic head. The femoral component placed was a 4-size stem with a hydroxyapatite proximal coating (Integrale® - Amplitude). The patient's postoperative course was unremarkable and reportedly without infectious complications. Postoperative radiographs showed both components were in recommended position.

In March 2020, then 72 years old, the patient evaluated a painful total hip. Physical examination revealed a full range of motions. When compared with immediate postoperative radiographs showed a suspicious lytic lesion on the proximal femur (Figure 1). CT-scan imaging showed a 6 x 2 x 2 cm heterogeneous fluid collection consistent with the appearance of a cyst and severe osteolysis of the proximal femur. The three-phase bone scintigraphy supported the proposal to loosen the femoral stem. The C-reactive protein was slightly increased while the rest were within normal limits. Chromium and cobalt levels were obtained, and both were found to be normal at < 0.1 ppb. The patient denied systemic symptoms. The surgical wound was clean with no erythema, swelling, or drainage. After discussing the risks of the procedure, the patient elected to have the CoC articulation revised.

A pseudotumor was found protruding from the joint space. It contained caseous appearing material. The liquid and the pseudotumor were tied off and sent to pathology for examination. All Cultures, including fungal and acid-fast cultures, were negative. No abnormal markings or discoloration

were present on the femoral head, trunnion, ceramic head, or acetabular component. There were no signs of impingement on the neck of the prosthesis or rim of the acetabular shell. The loosening femoral stem and the modular ceramic liner were removed.

After thorough irrigation, a Uption® reconstruction stem (Biomet, Indiana, USA) and a 36-mm Biolox® delta head (CeramTec GmbH, Plochingen, Germany) was placed. Due to bone loss in the greater trochanter, a bone graft and hook plate were used for femur reconstruction (Figure 2). The hip stability and range of motion were tested.

Pathology revealed a large synovial-lined cyst-like structure with histiocytes and lymphocytes in the perivascular stroma. The fibrovascular stroma was thick with a lot of pigmented macrophages. The fibrovascular stroma was thick with a lot of pigmented macrophages. In addition, it showed rare microscopic ceramic particles.

The patient's postoperative course was unremarkable. Rehabilitation was started on postoperative day one, and he was discharged home on the fourth postoperative day. The rehabilitation proceeded without any complications. The patient remained free of symptoms and complications at the 12-month follow-up.

DISCUSSION

ALTR and pseudotumor formation are well described in MoM-bearing surfaces (1). There is no consensus on the exact cause of the process, and

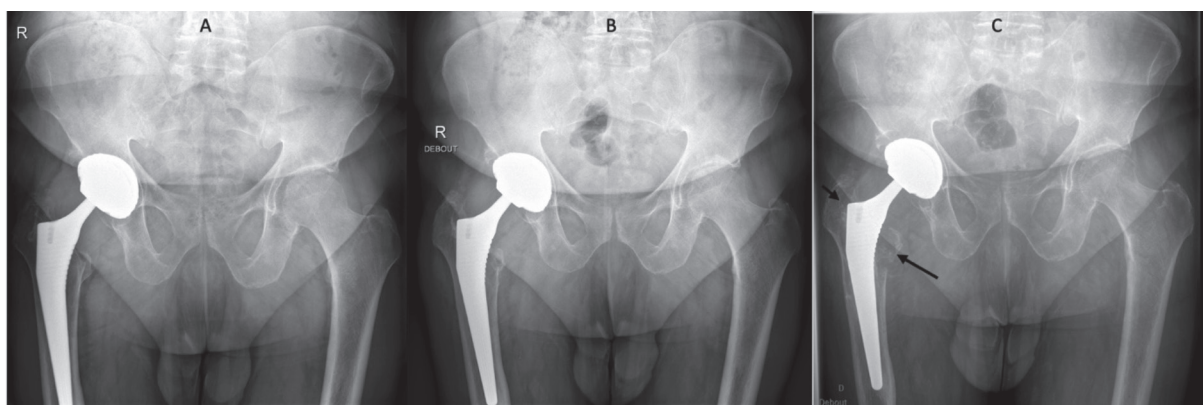


Figure 1. — Anteroposterior pelvis view of right hip in 2009 (A), 2018 (B) and 2020 (C). We can observe suspicious lytic lesions on the first and seven area according Gruen classification (Arrow).

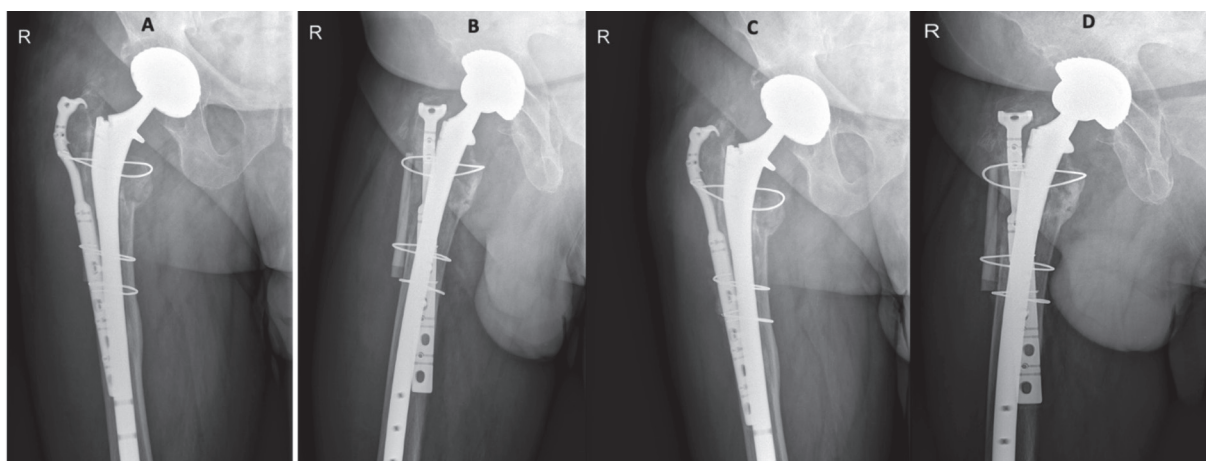


Figure 2. — Anteroposterior pelvis view (A) and lateral view (B) of right hip post-operation, at 9 months post-operatively (C and D).

histological appearances widely vary (7). In MoM articulation, the formation of pseudotumors and ALTR was initially 1-4% (6). However, new data show a prevalence of 36-61% in well-functioning hips (8, 9).

Not all pseudotumors are symptomatic, and not all require immediate treatment. However, their presence should be closely monitored, both clinically and radiographically. Almoussa et al., in a case series study of the natural history of pseudotumor formation, showed that only six patients had increased size at the two-year follow-up (9). For four patients, the pseudotumor decreased in size or resolved over the same period (9). Hart et al. showed that the incidence of pseudotumor formation does not significantly differ in symptomatic or asymptomatic MoM hips (8).

Concerns with CoC articulations primarily center around fracture of the ceramic head or liner, which is an uncommon occurrence (0.01-0.15%) (1, 10). It is well known that CoC articulations are less tolerant of component misplacement; this can lead to posterior edge loading (11). When cups are placed in excessive abduction, wear rates increase (1).

Despite the mostly benign characteristics, ceramic wear debris is not entirely inert. Mochida et al. showed a predominantly macrophage response to ceramic debris; this was confirmed with immunohistochemical staining (1, 12). In vitro studies have shown that macrophage injection of

ceramic debris will increase proinflammatory cytokine production (13). While macrophage apoptosis was more extensive after alumina particle ingestion than polyethylene particles of the same size (1, 13), CoC generated less wear debris than polyethylene articulations, leading to less response (14). In ceramic-on-polyethylene and non MoM articulations in THA, ALTR and pseudotumor formation are primarily due to trunnion or modular neckwear (1, 4, 15-17).

To the authors' knowledge, this is only the second case of such an ALTR/pseudotumor seen in CoC articulation with the absence of a CoCr stem, femoral head, sleeve, or source of Co ions or Co alloy corrosion debris. In the absence of any other cause (metal in the articulation, lack of elevated Co or Cr ions, and lack of exposed porous coating), it is reasonable to assume that the ALTR/pseudotumor was in reaction to wear debris from the CoC articulation.

CONCLUSION

This paper presents the case of symptomatic adverse local tissue reaction in a patient with a CoC total hip bearing surface. It occurred in the absence of a source of metal debris and without elevation of either chromium or cobalt. The case illustrates that ceramic wear debris are probably not entirely inert, and may lead to adverse local tissue reaction with possible ALTR/pseudotumor formation.

REFERENCES

1. Campbell J, Rajaei S, Brien E, Paiement GD. Inflammatory pseudotumor after ceramic-on-ceramic total hip arthroplasty. *Arthroplasty Today* 2017;3(2):83-7.
2. Harris WH, Schiller AL, Scholler JM, Freiberg RA, Scott R. Extensive localized bone resorption in the femur following total hip replacement. *J Bone Joint Surg Am.* 1976;58(5):612-8.
3. Griffiths HJ, Burke J, Bonfiglio TA. Granulomatous pseudotumors in total joint replacement. *Skeletal Radiol.* 1987;16(2):146-52.
4. McGrory BJ, MacKenzie J, Babikian G. A High Prevalence of Corrosion at the Head-Neck Taper with Contemporary Zimmer Non-Cemented Femoral Hip Components. *J Arthroplasty.* 2015;30(7):1265-8.
5. Boardman DR, Middleton FR, Kavanagh TG. A benign psoas mass following metal-on-metal resurfacing of the hip. *J Bone Joint Surg Br.* 2006;88(3):402-4.
6. Pandit H, Glyn-Jones S, McLardy-Smith P, Gundle R, Whitwell D, Gibbons CLM, et al. Pseudotumours associated with metal-on-metal hip resurfacings. *J Bone Joint Surg Br.* 2008;90(7):847-51.
7. Sagoo N, Sharma R, Johnson C, Stephenson K, Aya K. Pseudotumor in the Setting of Metal-on-Metal Total Hip Arthroplasty. *Cureus.* 2020 23;
8. Hart AJ, Satchithananda K, Liddle AD, Sabah SA, McRobbie D, Henckel J, et al. Pseudotumors in association with well-functioning metal-on-metal hip prostheses: a case-control study using three-dimensional computed tomography and magnetic resonance imaging. *J Bone Joint Surg Am.* 2012 15;94(4):317-25.
9. Almousa SA, Greidanus NV, Masri BA, Duncan CP, Garbuz DS. The Natural History of Inflammatory Pseudotumors in Asymptomatic Patients After Metal-on-metal Hip Arthroplasty. *Clin Orthop Relat Res.* 2013;471(12):3814-21.
10. Xing D, Yang C, Li R, Hou Y, Kou B, Li H, et al. Severe Wear and multiple Pseudotumor formation due to revision for ceramic head breakage after ceramic-on-ceramic Total hip arthroplasty: a case report. *BMC Musculoskelet Disord.* 2019; 17;20(1):332.
11. Barrack RL, Burak C, Skinner HB. Concerns about Ceramics in THA: Clinical Orthopaedics and Related Research. 2004;429:73-9.
12. Mochida Y, Boehler M, Salzer M, Bauer TW. Debris from failed ceramic-on-ceramic and ceramic-on-polyethylene hip prostheses. *Clin Orthop Relat Res.* 2001;(389):113-25.
13. Petit A, Catelas I, Antoniou J, Zukor DJ, Huk OL. Differential apoptotic response of J774 macrophages to alumina and ultra-high-molecular-weight polyethylene particles. *J Orthop Res.* 2002;20(1):9-15.
14. Böhler M, Mochida Y, Bauer TW, Plenk H, Salzer M. Wear debris from two different alumina-on-alumina total hip arthroplasties. *J Bone Joint Surg Br.* 2000 Aug;82(6):901-9.
15. Hsu AR, Gross CE, Levine BR. Pseudotumor from modular neck corrosion after ceramic-on-polyethylene total hip arthroplasty. *Am J Orthop (Belle Mead NJ).* 2012;41(9):422-6.
16. Kwon Y-M, Della Valle CJ, Lombardi AV, Garbuz DS, Berry DJ, Jacobs JJ. Risk Stratification Algorithm for Management of Head-Neck Taper Tribocorrosion in Patients with Metal-on-Polyethylene Total Hip Arthroplasty: Consensus Statement of the American Association of Hip and Knee Surgeons, the American Academy of Orthopaedic Surgeons, and The Hip Society. *Journal of Bone and Joint Surgery [Internet].* 2021 Jan 7 [cited 2021 Feb 20]; Publish Ahead of Print. Available from: <https://journals.lww.com/10.2106/JBJS.20.01837>
17. Rahman TM, Frisch NB, Darrith B, Patel I, Silverton CD. Incidence of Pseudotumors in a Dual Modular Stem Construct With and Without Metal-on-Metal Bearing Surface. *JAAOS - Journal of the American Academy of Orthopaedic Surgeons.* 2021; 15;29(2):e92.