



Os acromiale : literature review and treatment options

Ugo BredA, Ghady EL KHOURY, Etienne WILLEMART, Tom DE BAERE

From the Orthopedic departement, Hôpital Delta – CHIREC, Brussels, Belgium

Os acromiale is due to a defect of fusion of the different ossification centers of the acromion. It is a common cause of shoulder pain that should be evoked in the differential diagnosis of the sub-acromial conflict. CT scan or magnetic resonance are therefore often helpful to confirm the diagnosis. Conservative treatment is the first-line management but various surgical techniques are described in case of initial treatment failure. In this context, new arthroscopic techniques offer encouraging results. This article overviews the key points of pathophysiology, clinical manifestations, para-clinical studies and treatment of os acromiale.

Keywords : key points of pathophysiology ; clinical manifestations ; para-clinical studies ; treatment of os acromiale.

INTRODUCTION

The acromion is composed of several ossification centers which generally unite between 15 and 25 year old. Os acromiale corresponds to the absence of fusion of one or more of these centers after this age (1,2,3,4,5). Grüber first described this anatomical variation in 1863 in a cadaveric study (6). Since then, the prevalence of os acromiale in the general population has been estimated between 1 and 30% and bilateral involvement has been identified in 33 to 62% of the cases (1,2,3,4,5,7,8). Some authors indicate that this condition may be more common in men, while other studies have not identified a

difference between gender. In addition, prevalence would be higher among black people (1,2,3,4). Currently, etiological hypotheses tend towards a genetic origin, potentially associated with repeated mechanical stresses (1).

METHODS AND PATIENTS

The acromial apophysis comprises four distinct ossification centers: the basi-, meta-, meso-, and pre-acromion (5). The size of the os acromiale may vary depending on the location of the fusion defect. In this context, a classification into three subtypes has been proposed. Type A corresponds to a failure of fusion between meso- and meta-acromion, type B to a failure of fusion between pre- and meso-acromion and type C to a failure of fusion between meta- and basi-acromion (Figure 1) (3,9). Type A is by far the most common; it represents about 75% of the cases (1,3,7). Very rarely, there may be two non-union sites, determining a double os acromiale (3). Several degrees of fusion between the os acromiale

-
- Ugo Breda¹, MD, ex-resident in general surgery
 - Ghady El Khoury¹, MD, resident in orthopedic surgery
 - Etienne Willemart², MD
 - Tom De Baere², MD

¹Université Catholique de Louvain, Belgium.

²Orthopedic departement, Hôpital Delta, CHIREC, Brussels, Belgium.

Correspondence : Tom De Baere, Boulevard du Triomphe, 201, 1160 Bruxelles. Phone : +32 2 434 81 07.

E-mail : tdebaere01@gmail.com

© 2020, Acta Orthopædica Belgica.

No benefits or funds were received in support of this study. The authors report no conflict of interests.

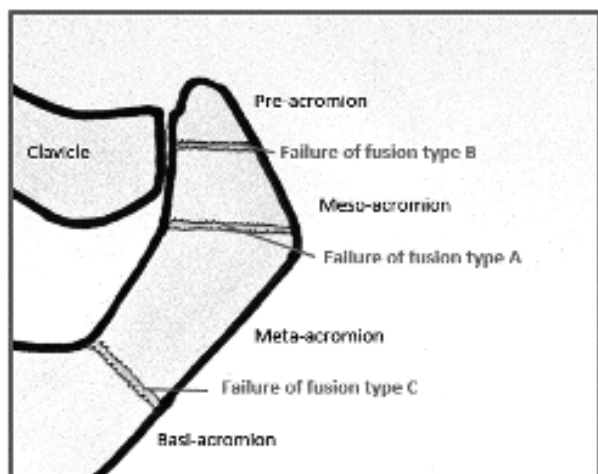


Figure 1. — Ossification nuclei of the acromion and localization of failure to fuse. Adapted from Frizziero A et al. Painful os Acromiale: Conserative Management in a Young Swimmer Athlete (5)

and the acromion are also described. It may be a synchondrosis, a syndesmosis or a discrete synovial joint (1,3).

Although most people with an os acromiale are asymptomatic, 10% of patients with scapalgia present this anatomical variation (7). Therefore, os acromiale must be evoked in the differential diagnosis of the sub-acromial conflict (7,10). Symptoms may begin gradually or appear suddenly after a shoulder trauma (4,7). Most frequent clinical manifestations are pain during palpation of the upper edge of the acromion and during anterior elevation, abduction and rotation of the upper limb against resistance (7). Pain at night has also been described

(3). When the os acromiale is not associated with another extra-articular pathology of the shoulder, clinical examination of the rotator cuff is always normal and the palpation of the acromioclavicular joint is not painful (7).

According to several studies, there is no relationship between this condition and the injury of the rotator cuff or the sub-acromial bursa, although the lower displacement of the os acromiale when the deltoid is contracted may cause a sub-acromial conflict, or even a tear of the rotator cuff, inducing the clinical manifestations (1,2,7,10). Abnormal mobility of the os acromiale may also induce by itself painful symptoms (7,10).

Besides the clinical examination, several imaging modalities can help to make the diagnosis. Standard X-rays sometimes allow to identify a cortical irregularity. It is interesting to note that axial incidences of the scapula have a higher sensitivity than anterior-posterior incidences (Figure 2) (1,7). Ultrasounds may also show a pseudo-articulation and can evaluate the os acromiale mobility (5). However, CT scan and magnetic resonance are the most sensitive exams in routine to visualize a failure of fusion of the acromion (Figure 2) (2,3,7).

Based on some radiological criteria, magnetic resonance would also allow the diagnosis of os acromiale in adolescents (8).

Other imaging techniques such as ^{99m}Tc -MDP SPECT/CT scintigraphy may also take part in the assessment of this condition, showing an increased activity of the affected acromion (11).

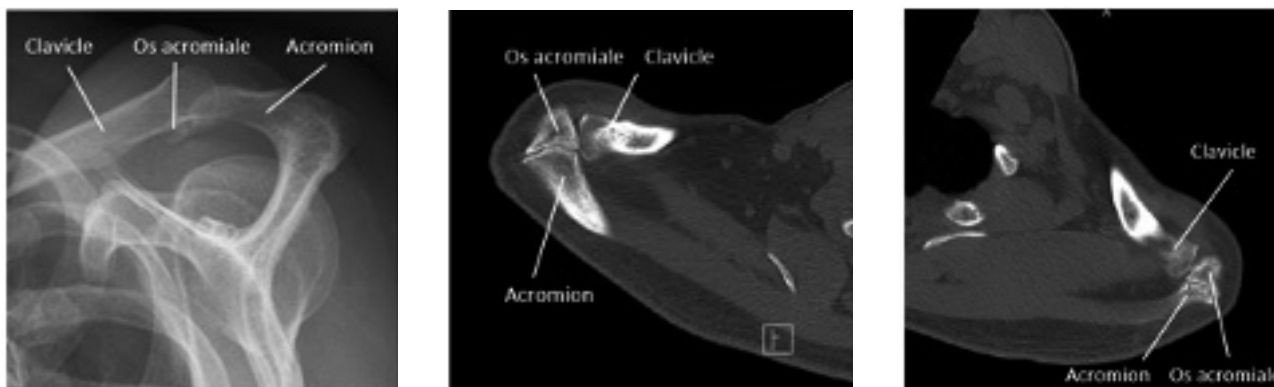


Figure 2. — X-ray with axial incidence of the scapula in a 58-year-old woman: type B os acromiale (A). Arthro-scan of both shoulders in a 42-year-old man: bilateral type A os acromiale (B).

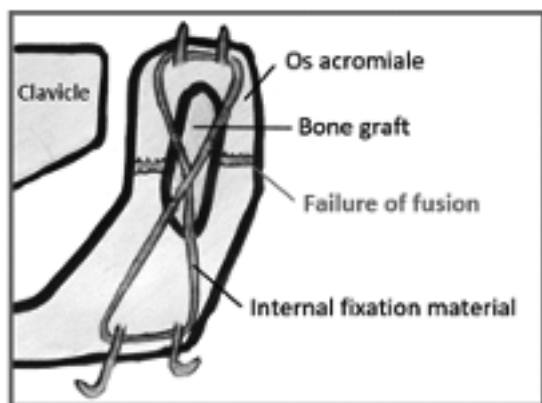


Figure 3. — Stabilization by iliac bone graft and tension band wiring. Adapted from Barbier O et al. Os acromiale, a cause of shoulder pain, not to be overlooked (7).

In addition, the diagnosis of os acromiale can be confirmed by an X-ray or a CT scan guided infiltration of the acromion, leading to an improvement in the symptomatology (7).

TREATMENT

In case of symptomatic os acromiale, conservative treatment may be initially considered. Non-steroidal anti-inflammatory drugs and application of ice will be started. Physiotherapy exercises focusing on the stretching of the internal and external rotator muscles, lowering humeral head muscles and stabilizers of the scapula as well as the anterior serratus will be realized. Sub-acromial infiltration of corticosteroids may also be performed (4,5,10).

If conservative treatment fails after a few months, a surgical sanction can be offered to the patient (4,10). Although there is currently no consensus, some techniques seem to offer interesting results.

Open resection of the os acromiale is discouraged by most authors. This technique leads to a dysfunction and a weakness of the deltoid (4,7). Its indication is limited to small pre-acromial fragments who respect the deltoid insertion (4,10).

Stabilization by tension band wiring on the upper side of the acromion, associated or not with iliac bone graft is currently considered as the reference technique (Figure 3). This procedure offers a reduction of the pain as well as an increased mobility

of the shoulder. However, the osteosynthesis material may become uncomfortable, requiring frequently its removal (4,7,10). To overcome this disadvantage, some teams have proposed to use a polyethylene suture rather than stainless steel wires, allowing probably less post-operative pain due to the equipment, while offering a comparable stiffness (12).

Recently, different arthroscopic techniques have also emerged. These “minimally invasive” approaches allow an early mobilization of the shoulder and thus, a faster postoperative recovery (10). In this context, arthroscopic resection of the os acromiale could be a safe and effective alternative to stabilization by tension band wiring technique (Figure 4) (4,10,13). Indeed, unlike open resection, the periosteum in front of the os acromiale and the insertion of the deltoid are preserved in this case. Furthermore, for meso-os acromiale, a bone excision of 5 to 7 mm at the nonunion site associated with an acromioplasty would offer similar results than an entire arthroscopic resection (4). If necessary, a rotator cuff repair can also be performed in the same operative time (4,13). Other teams proposed to fix the os acromiale by arthroscopy with resorbable screws, with encouraging clinical and radiological results (14).

CONCLUSION

Os acromiale is present in 10% of patients with shoulder pain and should therefore be taken into account in the differential diagnosis of sub-acromial conflict. In this context, magnetic resonance and CT scan are the most sensitive modalities in routine to

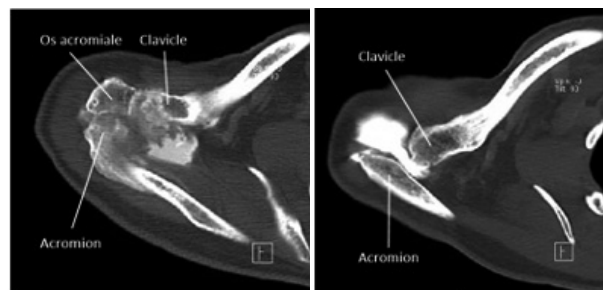

Figure 4. — Preoperative and postoperative arthro-scan in a 58 year-old woman : arthroscopic resection of the os acromiale.

identify a defect in ossification of the acromion. For these patients, a conservative treatment may be initiated. In case of failure, surgical management is often proposed. Stabilization by tension band wiring with iliac autograft is currently considered as the reference technique. However, new arthroscopic approaches offer encouraging results, allowing a faster postoperative recovery and eliminating the risk of symptomatic hardware.

REFERENCES

1. **Yamine K.** The prevalence of Os acromiale : a systematic review and meta-analysis. *Clin. Anat.* 2014 May 27(4) : 610-21.
2. **Rovesta C, Marongiu MC, Corradini A, Torricelli P, Ligabue G.** Os acromiale: frequency and a review of 726 shoulder MRI. *Musculoskelet Surg.* 2017 Dec, 101(3) : 201-5.
3. **Paraskevas G, Raikos A, Lazos L, Economou Z, Natsis K.** Co-existence of os acromiale with suprascapular osseous bridge : a case report and review of the literature. *Folia Morphol (Warsz).* 2009 May, 68(2) : 109-12.
4. **Johnston PS, Paxton ES, Gordon V, Kraeulter MJ, Abboud JA, Williams GR.** Os acromiale : a review and an introduction of a new surgical technique for management. *Orthop. Clin. North Am.* 2013 Oct, 44(4) : 635-44.
5. **Frizziero A, Benedetti MG, Creta D, Morio A, Galletti S, Maffulli N.** Painful Os Acromiale : Conservative Management in a Young Swimmer Athlete. *J. Sports Sci. Med.* 2012 Jun, 11(2) : 352-6.
6. **Gruber W.** Über die arten der Acromialknochen und accidentellen Acromialgelenke. *Arch. Anat. Physiol. Wissensch. Med.* 1863 : 373-387.
7. **Barbier O, Block D, Dezaly F, Sirveaux F, Mole D.** Os acromiale, a cause of shoulder pain, not to be overlooked. *Orthop. Traumatol. Surg. Res.* 2013 Jun, 99(4) : 465-72.
8. **Winfeld M, Rosenberg ZS, Wang A, Bencardino J.** Differentiating os acromiale from normally developing acromial ossification centers using magnetic resonance imaging. *Skeletal Radiol.* 2015 May, 44(5) : 667-72.
9. **Park JG, Lee JK, Phelps CT.** Os acromiale associated with rotator cuff impingement : MR imaging of the shoulder. *Radiology.* 1994 Oct, 193(1) : 255-7.
10. **Kawaguchi S, Fukuta S, Tsutsui T. et al.** Arthroscopic excision of unstable os acromiale associated with impingement syndrome : a case report. *J. Med. Invest.* 2016, 63(1-2) : 131-4.
11. **Al-faham Z, Jolepalem P.** Use of SPECT/CT with 99mTc-MDP Bone Scintigraphy to Diagnose Symptomatic Os Acromiale. *J. Nucl. Med Technol.* 2015 Sep, 43(3) : 236-7.
12. **Shiu B, Song X, Iacangelo A. et al.** Os acromiale fixation : a biomechanical comparison of polyethylene suture versus stainless steel wire tension band. *J. Shoulder Elbow Surg.* 2016 Dec, 25(12) : 2034-9.
13. **Campbell PT, Nizlam NM, Skirving AP.** Arthroscopic excision of os acromiale : effects on deltoid function and strength. *Orthopedics.* 2012 Nov, 35(11) : e1601-5.
14. **Atoun E, van Tongel A, Narvani A, Rath E, Sforza G, Levy O.** Arthroscopically assisted internal fixation of the symptomatic unstable os acromiale with absorbable screws. *J. Shoulder Elbow Surg.* 2012 Dec, 21(12) : 1740-5.