



## Surgical repair of a tibialis anterior tendon rupture : a case report

Adonis SAFAR, Olivier BATH, Jacques HERNIGOU, Eric MOEST, Renaud MAES, Antoine CALLEWIER

*From the CHEpiCURA Department of Orthopaedics and Traumatology, CHEpiCURA, Hainaut, Belgium.*

**A 61-year-old man who stretched in the morning presented a rupture of the tibialis anterior tendon treated by extensor hallucis longus transfer. Rupture of the tibialis anterior tendon is rare. Surgical treatment seems to be more efficient in improving the function.**

**Keywords :** Tibialis anterior tendon ; rupture ; surgical technique.

### INTRODUCTION

Described for the first time by Bruning in 1905 (1), rupture of the tibialis anterior (TA) tendon is a rare injury (2). Very few studies are devoted to this pathology and most are case reports or small case series.

The TA muscle originates on the lateral aspect of the tibia and ends on the plantar and medial aspect of the 1st cuneiform and on the plantar base of the 1st metatarsal.

This tendon is one of the most powerful extensor of the ankle, providing 80% of the strength in dorsal flexion (3,4).

TA tendon rupture usually affects men between 50 and 70 years (5). The cause may be traumatic resulting from a laceration or a direct blow with pain and weakness or immediate loss of ankle dorsiflexion (6). It can also be atraumatic and, in this case, there is a spontaneous rupture on a predisposing degenerative or inflammatory background (2).

Petersen et al. (7) described an avascular area of 45 to 67 mm located in the anterior part of the tendon and corresponding to the most frequent area of spontaneous rupture. This area is located between 5 and 30 mm from the distal bone insertion (2,7). Two types of clinical presentation are possible. The first type concerns young patients undergoing ankle supination with sudden plantar flexion against resistance as can be seen in soccer. The second type concerns older patients with a history of diabetes, difficulty walking, lack of coordination and very often compensation by accessory extensors.

Due to the rarity of TA disruption, there is still controversy about the treatment of this lesion. For old patients or those in poor general condition, the treatment is conservative via an ankle-foot orthosis and physiotherapy.

When patients are physiologically young and athletic or in case of failure of nonsurgical treatment,

- 
- Safar Adonis, MD<sup>1</sup>,
  - Bath Olivier, MD<sup>1</sup>,
  - Hernigou Jacques, MD<sup>1</sup>,
  - Moest Eric, MD<sup>1</sup>,
  - Maes Renaud, MD<sup>1</sup>,
  - Callewier Antoine, MD<sup>1</sup>

*CHEpiCURA Department of Orthopaedics and Traumatology, CHEpiCURA, Hainaut, Belgium*

Correspondence : Adonis Safar, CHEpiCURA Department of Orthopaedics and Traumatology, Site de Baudour, Rue Louis Caty 136, 7331 Baudour, Belgium

E-mail : adonissafar@gmail.com

© 2020, Acta Orthopædica Belgica.

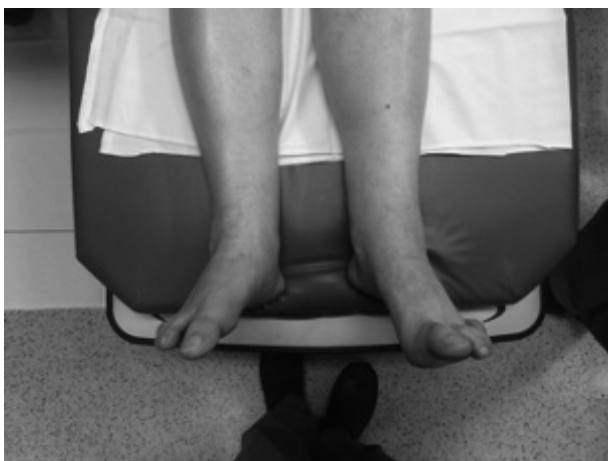surgery is required. It combines several techniques, including primary repair, tendon reconstruction and tendon transfers (3).

We report the case of a patient who had a TA tendon rupture and the surgical technique performed to repair this tendon.

The patient was informed that data concerning this case would be submitted for publication, and he gave his consent.

### CASE REPORT

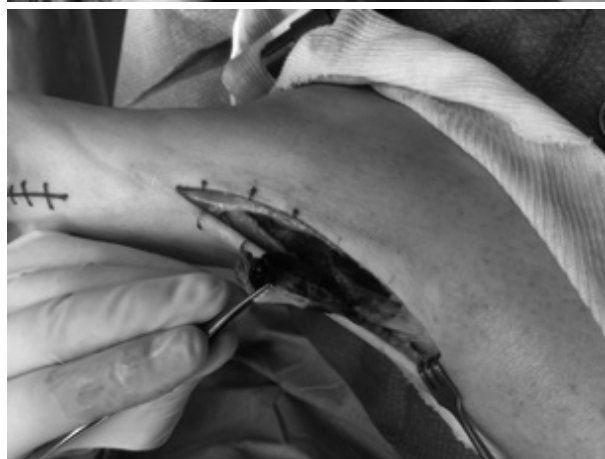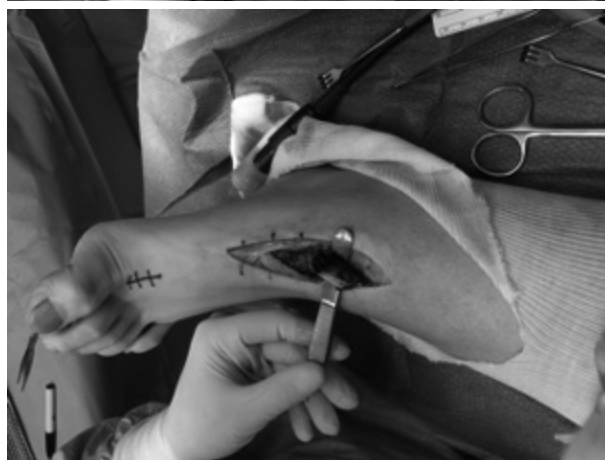
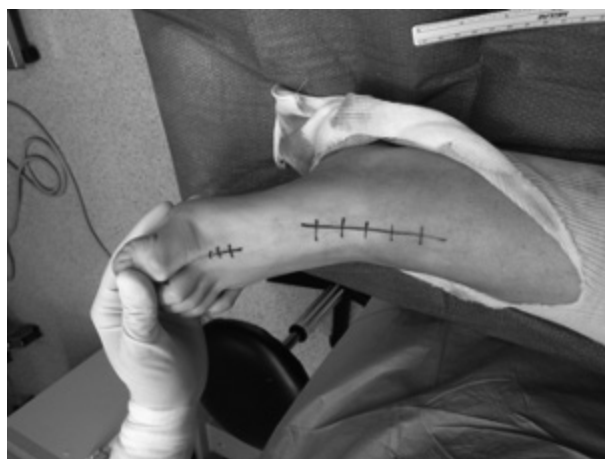A 61-year-old man with no particular history and no specific treatment was examined by a 1st orthopedic surgeon for chronic pain in the left ankle



**Figure 1.** — Preoperative view of the left foot showing loss of ankle dorsiflexion with extension of the hallux.

without notion of trauma. He explains that recently, he woke up in the morning and stretched himself out. After that, he felt intense pain in the instep with immediate functional impotence. On clinical examination, there was pain in the anterior aspect of the left ankle during palpation, loss of dorsiflexion at the ankle joint and a hallux extension (Figure 1). Gait examination revealed a drop foot and recruitment of the accessory extensors.

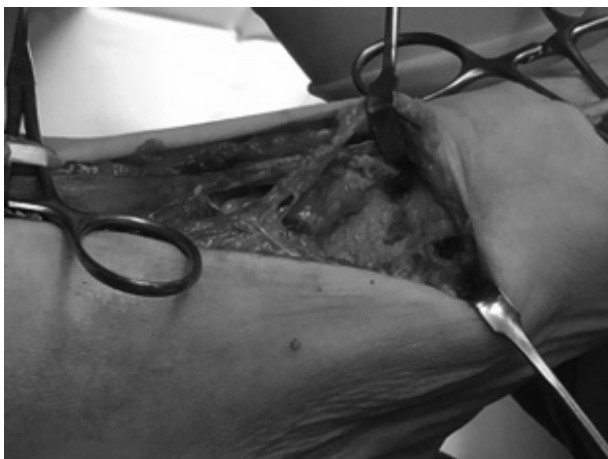The patient was then redirected to perform an ultrasonography. The radiologist concluded that the extensor hallucis longus was ruptured. Due to clinical doubt, the patient was seen by a 2nd orthopedic surgeon. A second ultrasound was performed by another radiologist to obtain a second



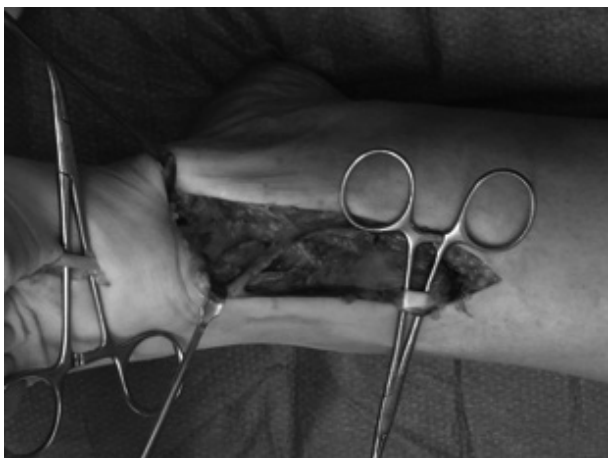
**Figure 2.** — Incision of the skin.

opinion and revealed a complete rupture of the TA tendon with significant retraction.

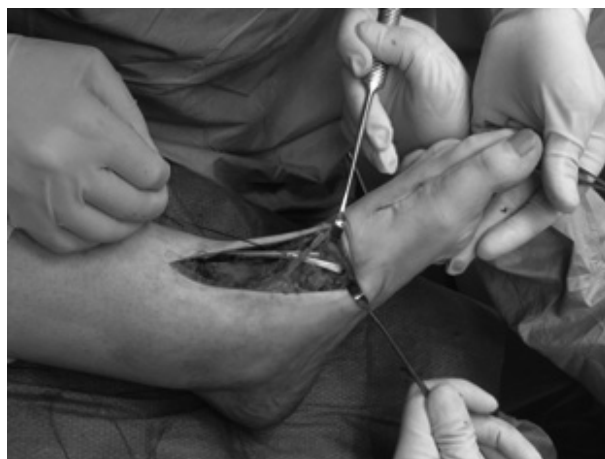The rupture being very distal, we performed a transfer of the extensor hallucis longus described



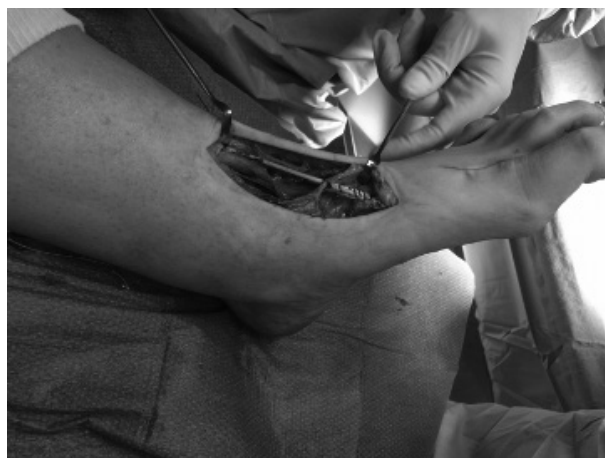**Figure 3.** — Identification of the ruptured tendon.



**Figure 4.** — Transosseous tunnel in the internal aspect of the cuneiform. Note the proximal part of the TA tendon on the right view.



**Figure 5.** — Section of the Extensor Hallucis Longus.



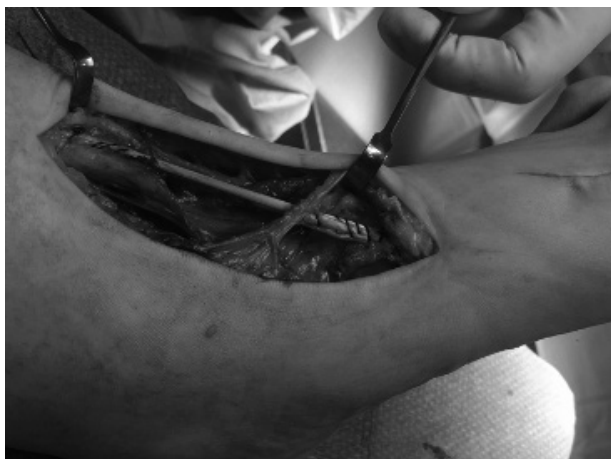for the first time by Tohen in 1966. The incision of the skin was made in front of the TA tendon (Figure 2). Hemostasis were performed and the retracted stump of the tendon was identified (Figure 3).

A second cutaneous incision was made at the level of the extensor hallucis longus distally (Figure 2).

The proximal part of the TA tendon was identified and a transosseous tunnel was drilled on the internal aspect of the first cuneiform (Figure 4).

The extensor hallucis longus was sectioned and its distal stump was sutured on the extensor hallucis brevis (Figure 5).

A latero-lateral suture is performed between the TA tendon and the extensor hallucis longus proximally and the transferred tendon was passed



**Figure 6.** — The EHL and TA are sutured proximally and the EHL graft is passed in the transosseous tunnel and sutured on itself.

into the transosseous tunnel and sutured on itself (Figure 6). Achilles tendon or gastrocnemius release was not necessary during tendon tensioning.

The patient was immobilized postoperatively with non-weight bearing for three weeks. After three weeks, weight-bearing was allowed with a walking boot for six weeks. Physiotherapy was started at nine weeks. After four months, the patient made a full recovery and walked without drop foot. He was examined 16 months after surgery and presented an active dorsiflexion with a gait close to normal.

## DISCUSSION

The rupture of the tibialis anterior tendon is rare. In 1959, Anzel et al. reported only 10 cases of TA rupture in 1014 cases of muscle and tendon ruptures (8).

The diagnosis is made on the clinical findings which shows weakness or loss of extension of the ankle associated with a defect on the anterior aspect of the ankle and dorsal foot. In addition, there is often a palpable mass called pseudotumor corresponding to the retraction of the ruptured tendon. The examination of the walk often reveals a drop foot and a recruitment of the extensor hallucis longus and brevis and extensor digitorum longus (2,9-12). EHL and EDL recruitment can easily mislead the examiner causing often a delay in the diagnosis (3,9,11).

Ultrasonography is a very effective and inexpensive procedure for making the final diagnosis but is operator-dependent (10,13). MRI is the gold standard for diagnosing TA tendon rupture (14), but it is more expensive and waiting is longer. We chose to get ultrasonography for the second opinion because delays to obtain MRI are very long in our country. We also knew that the second radiologist who performed the ultrasonography was very efficient with this examination.

Due to the rarity of the pathology, there is no clear consensus regarding the treatment of TA tendon rupture. The treatment reserved for elderly, debilitated or undemanding patients is the conservative treatment via immobilization with an ankle-foot orthosis to limit drop foot and recruitment of accessory extensors.

Surgery is reserved for young, active patients or in case of failure of non-operative treatment. It is important to determine whether the presentation is acute or chronic to guide treatment as accurately as possible. A “primary” repair consisting in direct suture or autoplasty of the tendon can be performed if there is a distal stump. But when primary repair is impossible, tendon transfer techniques are used. The most common are the transfer techniques using extensor hallucis longus and extensor digitorum longus. Good results have been reported with EHL and EDL transfers (9,11,15). Other techniques are described for larger defects. These use free autografts or allografts of gracilis, plantaris, semitendinosus or peroneus brevis (16-18).

Our patient was active and very demanding and we opted for the EHL tendon transfer with the realization of a transosseous tunnel due to the significant tendon retraction and the absence of distal tendon stump.

Ouzounian and Anderson (19) reviewed 12 patients with TA tendon rupture. The authors’ conclusion was that patients with traumatic rupture demonstrated an improvement in function after surgical treatment. On the other hand, patients with late-diagnosis atraumatic rupture could be managed conservatively.

Markarian et al. (11) reviewed 16 patients and compared operative and nonoperative treatment. Despite a non significant difference between the

two treatments, their data indicate “a trend toward surgical treatment to improve function”.

In their study of 10 patients, Kopp et al. (20) also compared operative and non operative procedures and led to the conclusion that operative treatment resulted in better patient satisfaction but decreased dorsiflexion of the ankle and inversion of the foot relative to the healthy contralateral limb.

Sammarco et al. (9) published the largest study of cases treated surgically in the literature. The authors included 19 patients : 11 patients who received delayed surgical treatment and 8 patients who received early surgical treatment. In both cases, the authors note an improvement in dorsiflexion and gait. Their recommendations are to repair the tendon in any case, regardless of age.

Ellington et al. (15) reported a study of fifteen TA tendon ruptures with nine patients treated with EHL transfer in a retrospective study. They concluded that surgical repair or tendon transfer to treat TA rupture result in a good function and a good patient satisfaction.

Our patient had a good postoperative functional recovery and a walk without lameness.

## CONCLUSION

In conclusion, the rupture of the tibialis anterior tendon is a rare pathology. It needs a thorough clinical examination to make diagnosis. Although there are several therapeutic possibilities, it seems that the current trend is towards surgical treatment for improving function.

## REFERENCES

1. **Brüning F.** Zwei seltene Fälle von subkutaner Sehnenzerreissung. München Med Wchschr.
2. **Anagnostakos K, Bachelier F, Fürst OA, Kelm J.** Rupture of the anterior tibial tendon : three clinical cases, anatomical study, and literature review. *Foot Ankle Int.* mai 2006 ; 27(5) : 330-9.
3. **Rodriguez Alonzo D, Maldague P.** Rupture du tendon tibial antérieur. In : Leemrijse T, Valtin B, editors. Pathologie du pied et de la cheville. Issy-les-Moulineaux : Masson ; 2015.
4. **Scheller AD, Kasser JR, Quigley TB.** Tendon injuries about the ankle. *Orthop Clin North Am.* oct 1980 ; 11(4) : 801-11.
5. **Jerome JTJ, Varghese M, Sankaran B, Thomas S, Thirumagal SK.** Tibialis anterior tendon rupture in gout-case report and literature review. *Foot Ankle Surg Off. J. Eur. Soc. Foot Ankle Surg.* 2008 ; 14(3) : 166-9.
6. **Mao H, Xu G.** Soft tissue repair for tibialis anterior tendon ruptures using plate and screw fixation technique in combination with anterolateral thigh flaps transplantation. *J. Orthop. Surg.* 17 sept 2015 ; 10 : 143.
7. **Petersen W, Stein V, Tillmann B.** Blood supply of the tibialis anterior tendon. *Arch. Orthop. Trauma Surg.* 1999 ; 119(7-8) : 371-5.
8. **Anzel SH, Covey KW, Weiner AD, Lipscomb PR.** Disruption of muscles and tendons ; an analysis of 1, 014 cases. *Surgery.* mars 1959 ; 45(3) : 406-14.
9. **Sammarco VJ, Sammarco GJ, Henning C, Chaim S.** Surgical repair of acute and chronic tibialis anterior tendon ruptures. *J. Bone Joint Surg. Am.* févr 2009 ; 91(2) : 325-32.
10. **Kausch T, Rütt J.** Subcutaneous rupture of the tibialis anterior tendon : review of the literature and a case report. *Arch. Orthop. Trauma Surg.* 1998 ; 117(4-5) : 290-3.
11. **Markarian GG, Kelikian AS, Brage M, Trainor T, Dias L.** Anterior tibialis tendon ruptures : an outcome analysis of operative versus nonoperative treatment. *Foot Ankle Int.* déc 1998 ; 19(12) : 792-802.
12. **Cohen DA, Gordon DH.** The long-term effects of an untreated tibialis anterior tendon rupture. *J. Am. Podiatr. Med. Assoc.* mars 1999 ; 89(3) : 149-52.
13. **Bianchi S, Zwass A, Abdelwahab IF, Zoccola C.** Evaluation of tibialis anterior tendon rupture by ultrasonography. *J. Clin. Ultrasound JCU.* déc 1994 ; 22(9) : 564-6.
14. **Gallo RA, Kolman BH, Daffner RH, Sciulli RL, Roberts CC, DeMeo PJ.** MRI of tibialis anterior tendon rupture. *Skeletal Radiol.* févr 2004 ; 33(2) : 102-6.
15. **Ellington JK, McCormick J, Marion C, Cohen BE, Anderson RB, Davis WH, et al.** Surgical outcome following tibialis anterior tendon repair. *Foot Ankle Int.* mai 2010 ; 31(5) : 412-7.
16. **Funk SS, Gallagher B, Thomson AB.** Repair of Chronic Tibialis Anterior Tendon Ruptures. *Orthopedics.* avr 2016 ; 39(2) : e386-390.
17. **Forst R, Forst J, Heller KD.** Ipsilateral peroneus brevis tendon grafting in a complicated case of traumatic rupture of tibialis anterior tendon. *Foot Ankle Int.* juill 1995 ; 16(7) : 440-4.
18. **Patel R, Fallat L.** Surgical Techniques for Repair of Atraumatic Tibialis Anterior Tendon Ruptures : A Report of Two Cases. *J. Foot Ankle Surg. Off. Publ/ Am. Coll. Foot Ankle Surg.* déc 2017 ; 56(6) : 1343-9.
19. **Ouzounian TJ, Anderson R.** Anterior tibial tendon rupture. *Foot Ankle Int.* juill 1995 ; 16(7) : 406-10.
20. **Kopp FJ, Backus S, Deland JT, O'Malley MJ.** Anterior tibial tendon rupture : results of operative treatment. *Foot Ankle Int.* oct 2007 ; 28(10) : 1045-7.