



Long-term effects of intravenous iloprost therapy in patients with bone marrow oedema of the hip

Timo ZIPPELIUS, Carsten PERKA, Bernd PREININGER, Georg MATZIOLIS, Patrick STRUBE, Eric RÖHNER

From the Department of Orthopedics, Jena University Hospital, Campus Eisenberg, Germany

Bone marrow oedema (BMO) is a multifactorial condition. Various conservative treatment options include analgesic therapy, immobilisation of the affected joint and/or systemic intravenous iloprost or bisphosphonate therapy. Many studies confirm the positive effect of iloprost therapy in larger joints, e.g. the hip and knee joint, after short-term follow up. The objective of this study was to investigate that treatment with iloprost leads to positive long-term functional and radiological outcomes for BMO of the hip joint.

Nineteen patients with BMO of the hip joint, ARCO stage 1-2, were included in this study. The Harris Hip Score, the SF-36, the WOMAC score and a visual analogue pain scale (VAS) were evaluated before and 29 ± 11 months after Ilomedin therapy. All patients underwent MRI for radiological follow-up monitoring three months after treatment.

Significant improvements were found in the WOMAC Index and the VAS. In 79% of patients, follow-up MRI after three months showed complete regression of the oedema.

Based on the positive results of our study, we support treatment with iloprost for BMO of the hip joint at ARCO stage 1-2.

Keywords : Bone marrow oedema ; hip ; iloprost.

INTRODUCTION

Bone marrow oedema (BMO) is a multifactorial condition, the causes of which are not yet fully understood (11,24,25). BMO has a peak onset

between the age of 35 and 40 years. The disease affects men more often than women, at a ratio of 4:1 (11,24,25). The underlying conditions and risk factors for BMO are sickle cell anaemia, trauma, cortisone therapy, alcohol and nicotine abuse, lipid metabolism disorders, rheumatological conditions, chemotherapy and radiotherapy (7,9,11,15,24,25). As avascular necrosis, BMO is classified according to the Association Research Circulation Osseous (ARCO) stages 1 to 4. The occurrence of the BMO and the processes leading to progression remain unclear. Some studies suggest that the BMO is a reversible precursor to avascular necrosis, which accompanies untreated with a local decline and osteonecrosis. Although various vascular factors are known to contribute as BMO, the exact pathogenetic processes remain unknown (3). According to the

- Timo Zippelius¹.
- Carsten Perka².
- Bernd Preininger².
- Georg Matziolis¹.
- Patrick Strube¹.
- Eric Röhner¹.

¹Department of Orthopedics, Jena University Hospital, Campus Eisenberg, Klosterlausnitzer Straße 81, 07607, Eisenberg, Germany.

²Department of Traumatology and Orthopaedics, Charité University Hospital Berlin, Germany.

Correspondence : Eric Röhner, Department of Orthopaedics, Friedrich-Schiller-University, Campus Eisenberg, Klosterlausnitzer Straße 81, 07607 Eisenberg, Germany, Tel.: +49 (0)36691 81 1254, Fax: +49 (0)36691 81 1253

E-mail : e.roehner@krankenhaus-eisenberg.de

© 2018, Acta Orthopaedica Belgica.

No benefits or funds were received in support of this study. The authors report no conflict of interests.

Acta Orthopædica Belgica, Vol. 84 - 2 - 2018

guidelines, therapy for BMO ARCO stage 1 and 2 is non-surgical. The treatment for BMO ARCO advanced stage 2, 3 and 4 is surgical, including core decompression of the affected bone when necrosis is < 30 %, various forms of arthrodesis or total joint replacement (27).

The non-surgical treatment of BMO includes partial weight bearing of the affected joints, anti-inflammatory drugs, bisphosphonates or iloprost therapy. Using iloprost represents a genuine alternative treatment option, precisely in the initial stages of oedema (ARCO 1-2) (1,2,3,8). Iloprost is a stable derivative of prostacyclin, which is used primarily in the treatment of systemic vascular diseases such as Buerger's disease or scleroderma (5,17,18,23).

In a previous study, we were able to show excellent results after iloprost therapy for BMO of the foot and ankle (28). The treatment of BMO for the major joints such as the knee or hip has been investigated extensively, but checkups after some years are missing (3,8,14,19,29,31). Various studies have shown good to excellent therapeutic outcomes for iloprost in treating BMO of the proximal and distal femur by regression of BMO either radiologically in MRI, or according to reduction of pain and improvement of function (3,5,18).

A study conducted by Meizer et al. in patients with BMO of the femoral head showed a significant reduction of pain at rest and upon weight-bearing in 24 patients after short-term follow-up. The investigation was conducted just 4 months after iloprost therapy (22).

The aim of the present study was to investigate that treatment with iloprost without surgical intervention leads to positive long-term outcomes for BMO of the hip joint. The hypothesis of this study is that patients show a marked improvement in function and a significant reduction in pain in the affected joint after iloprost therapy.

PATIENTS AND METHODS

64 patients were hospitalized in the Orthopaedic Department of the Charité University Hospital Berlin and received iloprost therapy between January 2009 and December 2012. Nineteen

patients were retrospectively included in the study. They received a 5-day course of iloprost therapy at a concentration of 0.5ng/kg/min over 6 hours according to a treatment schedule (Ilomedin; Bayer Schering, Germany) (Table 1) and given questionnaires before treatment and during follow-up. The follow-up took place after 29 ± 11 months.

All patients had BMO of the hip joint and met the following inclusion criteria: BMO was confirmed by x-ray and MRI to differ between avascular necrosis and BMO, age 18 years or older, no history of knee or hip trauma, pain in affected joint, no medical objections to therapy. According to the Association Research Circulation Osseous (ARCO) classification, visible BMO in MRI without pathological signs in CT or radiography was assessed as ARCO stage 1, and visible BMO in MRI with signs of sclerosis in CT and minor osteolysis and signs of sclerosis in radiography was assessed as ARCO stage 2 (12).

All patients with ARCO stage 3 or 4 oedema, cardiac arrhythmia, atrial fibrillation or pulmonary hypertension, blood coagulation disorders, chronic infectious diseases, pregnancy, tumour diseases, or who were under the age of 18 years, were excluded from the investigation.

The study had the approval of the local ethics committee of the Charite Berlin (EA1/209/16).

Table I — Patient demographics

number	19
female	7
male	12
age (years)	50 ± 14
BMI (kg/metres ²)	25.2 ± 5.6
idiopathic BMO of femoral head ARCO 1	12
idiopathic BMO of femoral head ARCO 2	5
secondary BMO of femoral head ARCO 2	1
idiopathic acetabular BMO	1

Statistical analysis

Statistical tests were performed using Graph Pad Prism Software (Graph Pad Software, San Diego, USA). Statistical differences were verified using a paired t-test. Probability values of $p < 0.05$ were considered to be statistically significant.

RESULTS

All patients tolerated the 5-day intravenous iloprost therapy without serious adverse effects. Post iloprost therapy, all patients were instructed to bear partial weight with a maximum of 20 kilograms (kg) on the affected joint for 6 weeks using two forearm crutches. Follow-up investigations were undertaken after 3 months and 29 ± 11 months. The follow-up MRI was conducted 3 months after iloprost treatment in all cases.

Seven women and twelve men with BMO Stadium ARCO I-II received a 5-day iloprost therapy as scheduled. The average age at the time of therapy was 50 ± 14 years. The average BMI was 25.2 ± 5.6 . All of the patients tolerated the 5-day iloprost therapy without serious side effects. In MRI before iloprost therapy, BMO of the femoral head was confirmed in 18 patients, and one patient showed an idiopathic acetabular bone-marrow oedema of the hip (Table 1).

Evaluation of the WOMAC score showed a significant improvement after iloprost therapy (79.1

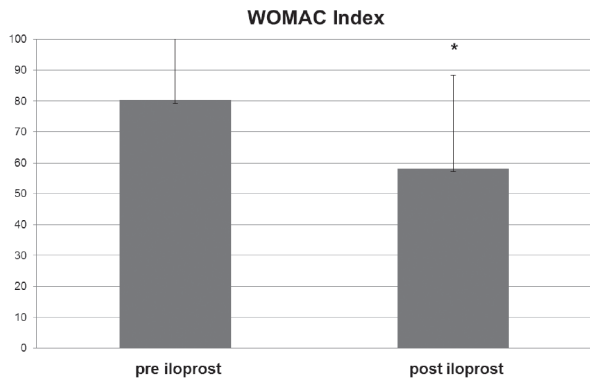


Fig. 1. — shows the significant improvement in the WOMAC index after Ilomedin therapy from 79.1 ± 25.1 points before to 66.3 ± 22.2 points after, $p < 0.05$

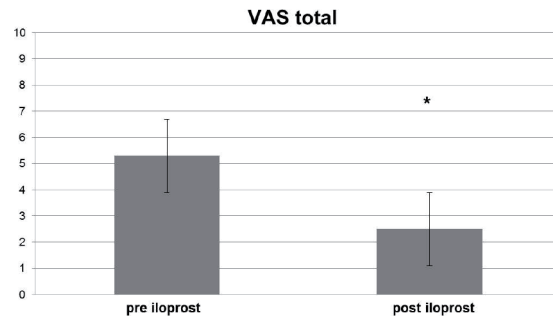


Fig. 2. — A significant reduction in pain was seen after iloprost therapy (VAS 5.3 ± 2.8 points before compared with 2.5 ± 3.6 points after, $p < 0.05$)

± 25.1 points before compared with 66.3 points ± 22.2 points after, $p < 0.05$) (Figure 1). The visual analogue scale also showed significant reduction in pain after iloprost therapy (VAS 5.3 ± 2.8 points before compared with 2.5 ± 3.6 points after, $p < 0.05$) (Figure 2).

Improvements were found for the SF-36 score and HHS, but they were not significant. SF-36 showed a marked increase in the number of points for all parameters (Figure 3). For HHS we observed an increase from 47 ± 25 points to 63 ± 18 points (Figure 4).

In the follow-up MRI three months after iloprost therapy, a complete regression of the oedema was observed in 15 out of 19 included patients. Four patients with ARCO stage 2 changed to ARCO stage 3 or 4 and received additional surgery after 6-12 months. Two patients received core decompression and iloprost therapy and two patients received total hip arthroplasty extending.

DISCUSSION

We were able to determine a significant improvement of function and reduction of pain for BMO of the hip joint after an average of 29 ± 11 months after iloprost therapy. Bone-marrow oedema (BMO) of the hip is a common disease and particularly affects adults in their third, fourth or fifth decade. Studies observing the course of the disease have shown that the degenerative changes can lead to osteonecrosis and the subsequent need

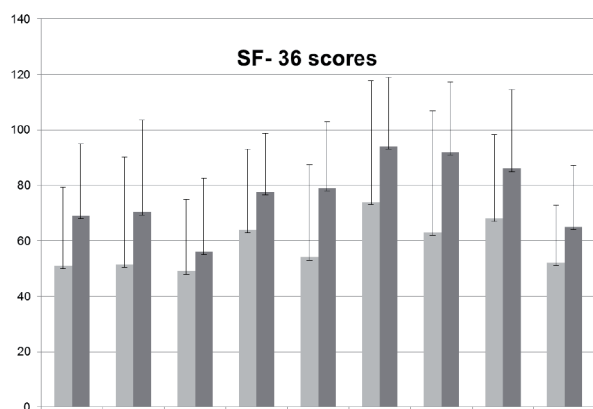


Fig. 3. — The SF-36 score showed a marked increase in the number of points for all parameters. Physical functioning (PF): extent to which the patient's health status impairs physical activities such as self-sufficiency, walking, lifting. Physical role functioning (RP): extent to which the patient's health status impairs daily activities and work. Bodily pain (BP): extent of pain and its effect on work. General health perceptions (GH): personal assessment of health (current, future, resistance). Vitality (VT): feeling of being full of energy, in full swing or tired and fatigued. Social role functioning (SRF): extent to which physical health or emotional problems affect normal social activities. Emotional role functioning (ERF): extent to which emotional problems affect work and daily activities. Mental health (MH): general mental health, including depression, anxiety, emotional and behaviour-related control, general mood status. Change in health (DIV): patient's assessment of current health status compared with the previous year

for total arthroplasty within 2-3 years (3,26). Early recognition of the symptoms and radiological diagnostics therefore play a central role, as does the question as to the correct form of therapy (1,10,26,30,32). The conservative forms of therapy for BMO of the hip joint are generally well known. Beside immobilisation and reduced weight-bearing of the affected joint or bone, treatment with iloprost, bisphosphonates or monoclonal antibody therapy are additional therapeutic options in ARCO stages 1 and 2 (1,10,26,30,32). Iloprost has an oedema-reducing effect that is based on a reduction of hydrostatic pressure in the area of the venous branches of the terminal vascular bed (8,9).

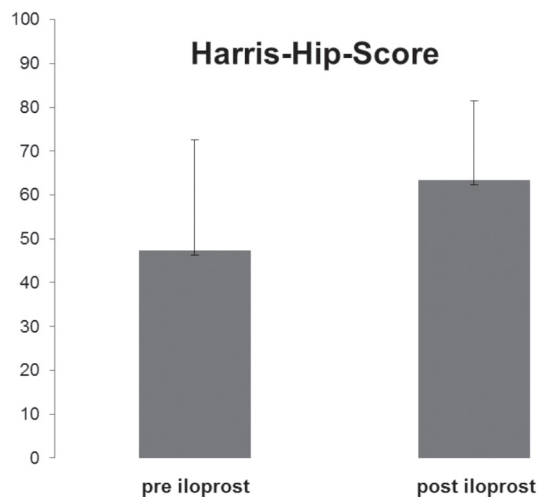


Fig. 4. — In the Harris Hip Score, we observed an increase from 47 ± 25 points to 63 ± 18 points

Significance of bisphosphonate and monoclonal antibody therapy

Effects of an intravenous bisphosphonate therapy in the treatment of BMO are still a matter of considerable debate. The S3 guideline part 2 for non-traumatic avascular femoral head necrosis in adults recommends a bisphosphonate therapy for reduction of pain and delaying of femoral head collapse (27).

In contrast, in a study by Meier et al., no significant effects of bisphosphonate therapy over and above anti-inflammatory medication were shown in patients with osteonecrosis of the knee. This study included 30 patients, 14 with ibandronate therapy and 16 with a placebo therapy. At baseline, 24 and 48 weeks, both groups were comparable in relation to radiological outcome and pain score (20). In another study conducted by Baier et. al, patients with BMO of the knee and foot were treated with intravenous prostacyclin or bisphosphonate therapy. After 3 months and 1 year, significant improvement of SF-36, VAS and WOMAC score could be shown (2). A new therapeutic concept in the treatment of BMO in stage 1 might be the monoclonal antibody denosumab (Prolia). Various studies have shown positive effects of denosumab in the treatment of osteoporosis and bone metastasis (4,13). In a study

by Brown et al., 1189 postmenopausal women with a T-score ≤ -2.0 were included. Group 1 (n = 594) was treated with subcutaneous denosumab injection in comparison with group 2 (n = 595) with an alendronate therapy. After a 12-month follow-up, a significant increase in bone mineral density (BMD) was detected after denosumab therapy in group 1 compared with group 2 (3.5% versus 2.6%; $p < 0.0001$). In summary of this study, denosumab showed a significantly greater increase of BMD and larger decrease in bone turnover markers in comparison with alendronate (4).

Significance of iloprost therapy

Iloprost is a potent therapeutic agent to treat BMO of the hip joint in early ARCO stage 1 and 2 (see table 2). A study conducted by Meizer et al. showed a significant reduction of pain at rest and upon weight-bearing in 29 patients. The investigation was conducted 4 months after iloprost therapy and the VAS used showed a reduction in pain at rest from 1.78 ± 1.29 to 0.74 ± 1.07 (58.3%, $p < 0.0001$) as well as a reduction of pain under weight-bearing from 3.19 ± 0.86 to 1.85 ± 1.43 (41.9%, $p < 0.0001$) (22).

A further study conducted by Aigner et al. showed an improvement in the Harris Hip Score

Table II. — Studies of iloprost therapy of the hip joint

Author [reference]	Patients/ BME location	Methods	Results
Aigner et al. 2005 [1]	36/ 38 femoral head	A: 17 Patients 1x20 μ g/5 days iloprost B: 20 Patients core decompression	MRI: A: Complete remission of BMO in all hips B: Complete remission of BMO in 14 hips Harris Hip Score: A: Before 64.7 after 3 months to 97 B: Before 53.7 after 3 month to 95.1
Disch et al. 2005 [7]	33/ 40 femoral head 16 group1 (BMO) 17 group 2 (necrosis)	Iloprost therapy 6 hours/d over 5 days	MRI after 3 months: BMO showed reduction from stage 4 to 1 in all patients Harris Hip Score: Group 1: before 56.5 to 80.5 after 3 month Group 2: before 58.7 to 78.5 after 3 month VAS Group 1: before 54.5 to 33.4 after 3 month Group 2: before 61.1 to 33.6 after 3 month
Beckmann et al. 2013 [3]	23/ 24 femoral head	12 patients: iloprost 12 patients :core decompression 12 patients: iloprost and core decompression	VAS after 12 month Iloprost: before 6.3 to 2.93 Decompr.: before 6.56 to 3.51 Iloprost +Decomp.: before 6.43 to 1.37 Harris Hip Score after 12 month Iloprost: before 60.58 to 79.42 Decompr.: before 61.58 to 72.25 Iloprost +Decomp.: before 58.33 to 88.42 WOMAC Iloprost: before 52.58 to 29.67 Decompr.: before 50.58 to 37 Iloprost +Decomp.: before 53.08 to 14.91
Studies with combined BMO of the hip joint, knee or foot and ankle joint			
Claßen et al. 2016 [6]	108/ 52% femoral head 18% knee 20% ankle 8% foot	Iloprost therapy 6 hours/d over 5 days	Follow-up time 49.71 (15-96) month Harris Hip Score: 89 ± 15 Knee Society Score: 150 ± 31 Foot and ankle survey: 457 ± 50 VAS 0 to 5: 80% VAS 0 or no pain: 37%

from 64.7 points (44-89) before iloprost therapy to 97 points (83-100) after 3 months in 17 patients investigated (18 hips) (1).

The results of the present study confirm the good outcome after iloprost therapy for BMO of the hip joint after long-term follow-up.

The limitations of the present study are its retrospective design, the small number of cases and missing control group. With our dosing, there were no events like headache, dizziness or vertigo, which are described in other studies.

CONCLUSION

Nevertheless, on the basis of the present study, it can be stated that patients with BMO who receive intravenous iloprost treatment show good clinical outcomes several years thereafter and benefit significantly from iloprost therapy. In the advanced stage ARCO 2, iloprost therapy only appears to delay the progression of the BMO. Based on the positive results of previous studies and on our own results, we recommend treatment with iloprost for BMO of the hip joint at ARCO stage 1-2.

Compliance with ethical standards: Patients were not part of previously published studies.

Conflict of interest None.

REFERENCES

1. **Aigner N, Petje G, Schneider W, Meizer R, Wilk et al.** Bone marrow edema syndrome of the femoral head: treatment with the prostacyclin analogue iloprost versus core decompression: an MRI-controlled study. *Wien Klin Wochenschr* 2005 ; 117 : 130-5.
2. **Baier C, Schaumburger J, Götz J et al.** Bisphosphonates or prostacyclin in the treatment of bone-marrow oedema syndrome of the knee and foot. *Rheumatol Int* 2013 ; 33 : 1397-402.
3. **Beckmann J, Schmidt T, Schaumburger J, Rath B, Lüring C, Tingart M, Grifka J.** Infusion, core decompression, or infusion following core decompression in the treatment of bone edema syndrome and early avascular osteonecrosis of the femoral head. *Rheumatol Int* 2013 ; 33 : 1561-5.
4. **Brown JP, Prince RL, Deal C et al.** Comparison of the effect of denosumab and alendronate on BMD and biochemical markers of bone turnover in postmenopausal women with low bone mass: a randomized, blind, phase 3 trial. *J Bone Miner Res* 2009 ; 24 : 153-61.
5. **Buckley MS, Staib RL, Wicks LM.** Combination therapy in the management of pulmonary arterial hypertension. *Int J Clin Pract Suppl* 2013 ; 179 : 13-23.
6. **Claßen T, Becker A, Landgraber S et al.** Long-term clinical results after iloprost treatment for bone marrow edema and avascular necrosis. *Orthop Rev* 2016 ; 8 : 6150.
7. **Craiovan BS, Baier C, Grifka J et al.** Bone marrow edema syndrome (BMES). *Orthopaede* 2013 ; 42 : 191-204.
8. **Disch AC, Matziolis G, Perka C.** The management of necrosis-associated and idiopathic bone-marrow oedem of the proximal femur by intravenous iloprost. *J Bone Joint Surg Br* 2005 ; 87 : 560-4.
9. **Doury P.** Bone-marrow oedema, transient osteoporosis, and algodystrophy. *J Bone Joint Surg Br* 1994 ; 76 : 993-4.
10. **Elder GJ.** From marrow oedema to osteonecrosis: common paths in the development of post-transplant bone pain. *Nephrology (Carlton)* 2006 ; 11 : 560-7.
11. **Fernandez-Canton G.** From bone marrow edema to osteonecrosis. *New concepts. Reumatol Clin* 2009 ; 5 : 223-7.
12. **Gardeniers JW.** A new international classification of osteonecrosis of the ARCO (Association Research Circulation Osseous) Committee. *ARCO News* 1992 ; 4 : 41-6.
13. **Geith T, Mutschler W, Berger F.** Therapy of bone marrow edema syndrome in the knee with denosumab. *Case report. Unfallchirurg* 2015 ; 118 : 230-2.
14. **Hofmann S, Engel A, Neuhold A et al.** Bone-marrow edema syndrome and transient osteoporosis of the hip: an MRI-controlled study of treatment by core decompression. *J Bone Joint Surg Br* 1993 ; 75 : 210-6.
15. **Jäger M, Tillmann FP, Thornhill TS et al.** Rationale for prostaglandin I2 in bone marrow oedema-from theory to application. *Arthritis Res Ther* 2008 ; 10 : R120.
16. **Jäger M, Zilkens C, Bittersohl B et al.** Efficiency of iloprost treatment for osseous malperfusion. *Int Orthop* 2011 May ; 35 : 761-5.
17. **Kawald A, Burmester GR, Huscher D, Sunderkötter C, Riemekasten G.** Low versus High-dose iloprost therapy over 21 days in patients with secondary Raynaud's Phenomenon and Systemic Sclerosis: a randomized, open, single-center study. *J Rheumatol* 2008 ; 35 : 1830-7.
18. **Krug S, Sablotzki A, Hammerschmidt S, Wirtz H, Seyfarth HJ.** Inhaled iloprost for the control of pulmonary hypertension. *Vasc Health Risk Manag* 2009 ; 5 : 465-74.
19. **Mayerhoefer ME, Kramer J, Breitenseher MJ et al.** Short-term outcome of painful bone marrow oedema of the knee following oral treatment with iloprost or tramadol: results of an exploratory phase II study of 41 patients. *Rheumatology (Oxford)* 2007 ; 46 : 1460-5.
20. **Meier C, Kraenzlin C, Friederich NF et al.** Effect of ibandronate on spontaneous osteonecrosis of the knee : a

- randomized, double-blind, placebo-controlled trial. *Osteoporos Int* 2014 ; 25 : 359-66.
21. **Meizer R, Radda C, Stolz G et al.** MRI-controlles analysis of 104 patients with painful bone marrow edema in different joint localizations treated with the prostacyclin analogue iloprost. *Wien Klin Wochenschr* 2005 ; 117 : 278-86.
 22. **Meizer R, Meraner D, Meizer et al.** Outcome of painful bone marrow edema of the femoral head following treatment with parenteral iloprost. *Indian J Orthop* 2009 ; 43 : 36-9.
 23. **Noël B, Panizzon RG.** Use of duplex ultrasonography in the treatment of thromboangiitis obliterans with iloprost. *Dermatology* 2004 ;208 : 238-40.
 24. **Orth P, Anagnostakos K.** Coagulation abnormalities in osteonecrosis and bone marrow edema syndrome. *Orthopedics* 2013 ; 36 : 290-300.
 25. **Poll LW, Willers R, Häussinger D, Mödder U, von Dahl S.** MRI bone marrow findings in 63 patients with type I Gaucher disease. *Rofo* 2010 ; 182 : 979-85.
 26. **Rajpura A, Wright AC, Board TN.** Medical management of osteonecrosis of the hip: a review. *Hip Int* 2011 ;21 : 385-92.
 27. **Roth A, Beckmann J, Bohndorf K et al.** S3-Guideline non-traumatic adult femoral head necrosis. *Arch Orthop Trauma Surg* 2016 ; 136 : 165-74.
 28. **Röhner E, Zippelius T, Steindl D, Fussi J, Perka C.** Effects of intravenous iloprost therapy in patients with bone marrow oedema of the foot and ankle. *Eur J Orthop Surg Traumatol* 2014 ; 24 : 1609-16.
 29. **Steinbach LS, Suh KJ.** Bone marrow edema pattern around the knee on magnetic resonance imaging excluding acute traumatic lesions. *Semin Musculoskelet Radiol* 2011 ; 15 : 208-20.
 30. **Taljanovic MS, Graham AR, Benjamin JB et al.** Bone marrow edema pattern in advanced hip osteoarthritis: quantitative assessment with magnetic resonance imaging and correlation with clinical examination, radiographic findings, and histopathology. *Skeletal Radiol* 2008 ; 37 : 423-31.
 31. **Vande Berg B, Lecouvet F, Koutaissoff S et al.** Transient bone marrow edema of the hip. *J Radiol* 2011 ; 92 : 557-66.
 32. **Vande Berg B, Lecouvet F, Koutaissoff S et al.** Bone Marrow Edema of the femoral head. *JBR-BTR* 2007 ; 90 : 350-7.