



Three-dimensional virtual reality simulation of periarticular tumors using Dextroscope reconstruction and simulated surgery : a preliminary 10 case study

JingSheng SHI, Jun XIA, YiBing WEI, SiQun WANG, JianGuo WU, FeiYan CHEN, GangYong HUANG, Jie CHEN

From the Department of Orthopedics, Huashan Hospital of Fudan University, Shanghai 200040, China

Dextroscope® three-dimensional (3D) imaging has been extensively applied for generation of virtual reality (VR) workspaces for in neurosurgery and laparoscopy, though few applications in orthopedic surgery have been reported.

Patients undergoing surgery for periarticular tumors ($n = 10$) from Oct. 2008 to Jun. 2010 were enrolled and presurgically subjected to computed tomography (CT), magnetic resonance imaging (MRI), and MRI angiography (MRI-A). Imaging data was transferred and integrated in Dextroscope, producing a VR simulation. Resultant presurgical 3D anatomical reconstructions and intraoperative anatomical characteristics (virtual vs. actual data) and surgical approach (virtual vs. actual situation) measurement and subjective appearance were compared.

Anatomical characteristics in the area of interest and tumor diameters were consistent between virtual and actual data. However, the virtual surgical situations remained inconsistent with the actual intraoperative situation in many cases, leading to complications. The resolution of original CT, MRI, and MRI-A images directly correlated with the quality of 3D simulations, with soft tissues most poorly represented. Tumor tissue imaging quality in 3D varied extensively by tumor type.

Conclusions : Anatomical structures of periarticular tumors can be reconstructed using the Dextroscope system with good accuracy in the case of simple fenestration, increasing individualization of treatment, surgical competence level, and potentially reducing intraoperative complications. However, further specialization of VR tools for use in orthopedic applications that involve specialized tools and procedures,

such as drilling and implant placement, are urgently required.

Keywords : simulation ; virtual surgery ; reconstruction ; periarticular tumor ; virtual reality

Abbreviations : virtual reality (VR) ; computed tomography (CT), magnetic resonance imaging (MRI), and magnetic resonance angiography (MRI-A)

INTRODUCTION

Multimodal virtual reality (VR) imaging for presurgical visualization is increasingly common in

- JingSheng Shi, MS.
- Jun Xia*, MD.
- YiBing Wei, MD.
- SiQun Wang, MD.
- JianGuo Wu, MS.
- FeiYan Chen, MD.
- GangYong Huang, MD.
- Jie Chen, MS

Department of Orthopedics, Huashan Hospital of Fudan University, Shanghai 200040, China.

Correspondence : Jun Xia Department of Orthopedics, Huashan Hospital of Fudan University, Middle Urumqi Road No. 12, Shanghai 200040, China.

E-mail : Drxiajun@126.com

© 2014, Acta Orthopædica Belgica.

contemporary clinical settings (22). These techniques have been widely and successfully employed in neurosurgery and laparoscopy (7,12), but less than 16 cases and 23 published articles have reported orthopedic applications of VR despite the potential for improvements in surgical evaluation and planning, minimization of unanticipated intraoperative variations, and improvements in patient outcomes (15). These cases consisted primarily of acetabular fractures (21), total hip replacement (19), and arthroscopic knee surgery (4), representing few of the myriad of potential orthopedic applications.

Dextroscope® is a prominent VR system for reconstruction of two-dimensional (2D) from DICOM data and three-dimensional (3D) stereoscopic virtual workspaces from magnetic resonance imaging (MRI) and computed tomography (CT) data (3,13,23-25,29). The 3D user interface reflects the computer-generated scenario into the user's eyes using mirrors and time-split synchronized liquid display shutter glasses, allowing full manipulation of the 3D workspace by hand-held pen and virtual 'tool rack' (8). Color, transparency, segmentation, image fusion, and linear and volumetric measurements can also be manipulated and exported in image or video format (8), allowing for complete surgical simulation.

Periarticular tumors in 10 patients were assessed by conventional MRI and CT imaging and data was integrated with Dextroscope to produce a 3D workspace to examine pathological anatomical structure. Simulated virtual and actual intraoperative anatomical characteristics and surgeries were compared to provide a preliminary evaluation of orthopedic use of Dextroscope for periarticular tumor treatment.

SUBJECTS AND METHODS

Subjects

Benign periarticular tumor patients ($n = 10$; M:F, 4:6; aged 23-52 years; mean age 39.2 years) scheduled for curettage and artificial bone or bone cement implantation at the Department of Orthopedics from Oct. 2008 to Jun. 2010 were enrolled. Diagnoses of aneurysmal bone cyst in proximal femur (5 cases), giant-cell tumor of bone in the proximal tibia (3 cases), chondroblastoma in proximal humerus (1 case), and bone cyst in left distal

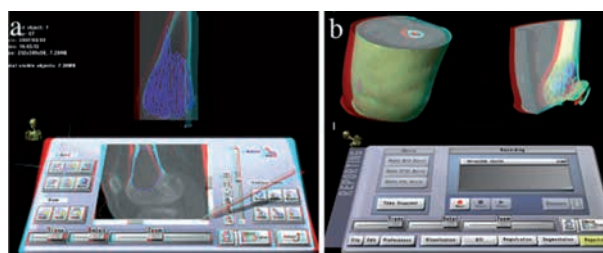


Fig. 1. — The Dextroscope interface.

(a) Single extraction of the area of interest using 'tool kit' (bottom) for automatic recognition and extraction of the area using bitmap grayscale ranges, and (b) one-by-one image selection and integration, including automatic and manual operation using 2- and multiple-point methods.

tibia (1 case) were confirmed by postsurgical pathological examination. All patients were followed a minimum of 12 months. The study was approved by the Institutional Review Board of the Huashan Hospital of Fudan University, and written informed consent was obtained from each patient.

VR image data

All patients were subject to CT (SOMATOM Sensation® 64-Slice CT System; Siemens, Germany), MRI (GE 3.0 Tesla Signal Horizon; GE Healthcare, USA), and MRI angiography (MRI-A) 2 days prior to surgery using layer thickness and spacing of 2 mm.

Native DICOM images were converted to RadioDexter version 1.0 (Volume Interactions, Singapore) software format, preliminarily processed, loaded into the Dextroscope® (Volume Interactions, Singapore) 3D VR environment, and observed by an operator equipped with liquid crystal stereoscopic glasses, transmitter (left hand), and virtual pen (right hand). Areas of interest were assigned (Fig. 1a) and integrated by automated or manual 2- or multiple-point selection (Fig. 1b).

The operator assigned tissue colors for visualization and segmented or rotated structures. Selective removal of skin, skeleton, tumors, vessels, and neighboring anatomical and functional structures using variant segmentation and extraction was used to reveal anatomical characteristics in the final reconstructions (Fig. 2). Resultant presurgical 3D anatomical reconstructions (virtual data) were used to generate tumor vertical, transverse, and anteroposterior diameters and these values were compared to intraoperative measurements (actual data).

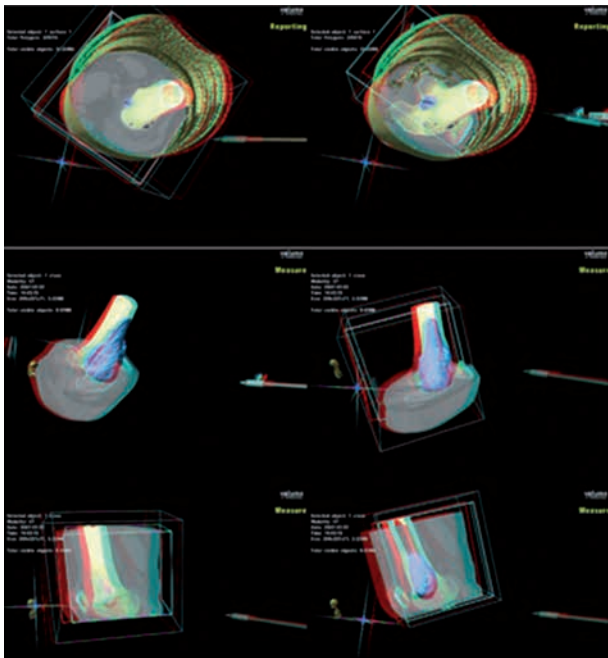


Fig. 2. — Removal of blocking structures and tissues to generate reconstruction images for measurement.

Presurgical planning and surgical approach

The VR workspace was used to expose lesion sites according to standard surgical requirements for optimal field of view, including soft tissue incision, bone flap fenestration, and tumor curettage, to generate individualized presurgical plans. Final output images/videos (virtual situation) were used as surgical references, and rela-

tionships between relationship between lesions and neighboring tissues were examined. Subjective image assessment by the operator and surgical precision were compared with those from the intraoperative surgical situation (actual situation). Standard postsurgical care was performed.

Statistical analysis

Statistical analyses were performed in SPSS version 16.0 (SPSS Inc., USA). All continuous variables were presented as means \pm standard deviations (SD) and analyzed using paired *t*-tests. *P*-values less than 0.05 were considered statistically significant ($p < 0.05$).

RESULTS

Patient data and Dextroscope imaging

Patient data for all 10 cases are shown in Table 1. Each patient dataset yielded successful virtual and actual information for both data and situation. Imaging resolution was determined by the resolution of the original image data and was highly variant between individual tissue types based on subjective visual assessment. Optimal visual effects were achieved in the skeleton and skin, though blood vessel also exhibited relatively high-quality reconstruction images. Conversely, low-quality reconstruction was apparent in soft tissues, such as muscles. The quality of tumor tissue reconstruction varied by tumor characteristics (*data not shown*).

Table 1. — Periarticular tumor patients examined by Dextroscope

Case no.	Gender	Age (yrs)	Diagnosis	Affected	Location side	Condition*	Follow-up (mo)
1	M	41	Aneurysmal bone cyst	L	proximal femur	-	12
2	F	43	Aneurysmal bone cyst	R	proximal femur	Psoriasis	15
3	M	23	Chondroblastoma	L	proximal humerus	-	26
4	F	35	Giant-cell tumor of bone	R	proximal tibia	-	16
5	F	48	Bone cyst	L	distal tibia	Sjögren's syndrome	18
6	M	39	Aneurysmal bone cyst	R	proximal femur	-	22
7	F	30	Giant-cell tumor of bone	L	proximal tibia	-	14
8	F	49	Aneurysmal bone cyst	L	proximal femur	Diabetes	17
9	M	52	Aneurysmal bone cyst	R	proximal femur	-	18
10	F	32	Giant-cell tumor of bone	L	proximal tibia	Hypertension	17

Abbreviations : M, male ; F, female ; R, right ; L, left

*Pre-existing conditions or complications

Table 2. — Dextroscope VR (virtual data) vs. intraoperative (actual data) tumor size

	Vertical	Diameter* Transverse	Anteroposterior
Virtual data ($n = 10$)	3.92 ± 1.22	1.96 ± 0.53	1.73 ± 0.44
Actual data ($n = 10$)	3.92 ± 1.13	1.91 ± 0.44	1.81 ± 0.41
<i>t</i> -value	< 0.01	1.25	1.92
<i>P</i> -value	0.99	0.24	0.09

*Diameters are means \pm SD (cm)

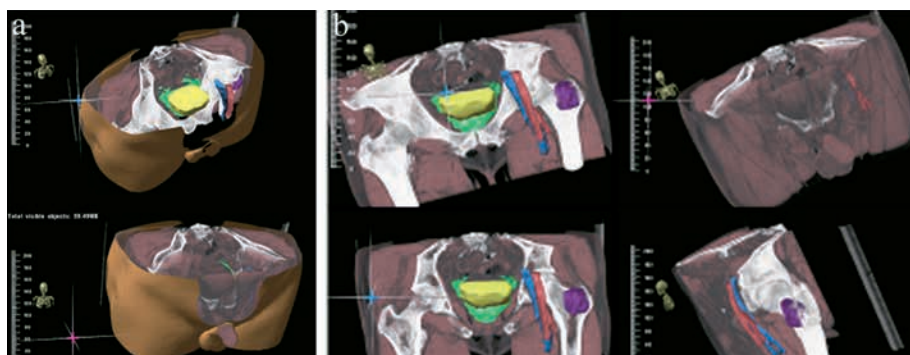


Fig. 3. — Reconstruction of male patient (no. 1) with aneurysmal bone cyst of the left proximal femur. (a) Bilateral hip joint structures were reconstructed and rotated. (b) Structures surrounding bilateral hip joints, skin, skeleton, muscles, and pelvic organs were reconstructed, segmented, and integrated to highlight the femoral artery and vein, (c) which can be observed by layer and rotation in 3D.

All patients exhibited good joint function, no local tumor recurrence, and no distant metastasis during follow-up (mean 17.5 months ; 12 to 26 months). In all patients, virtual and intraoperative data for anatomical structures were not significantly different based on subjective visual assessment and tumor diameter measurements ($p > 0.05$) (Table 2). The virtual and actual situations closely matched ; however, subjective image assessment and surgical precision of the virtual situation exhibited notable discrepancies from the actual situation.

Typical clinical applications

Patient 1. A male patient with aneurysmal bone cyst in the left proximal femur is shown. Anatomical structures surrounding bilateral hip joints, skin, skeleton, muscles, pelvic organs, femoral artery, and femoral vein were successfully reconstructed and multi-modal 3D VR images were produced (Fig. 3). The lateral approach was simulated, and bone flap fenestration and tumor curet-

tage were performed (Fig. 4). Intraoperative complications were primarily caused by underestimation and imprecise analysis of the anatomical

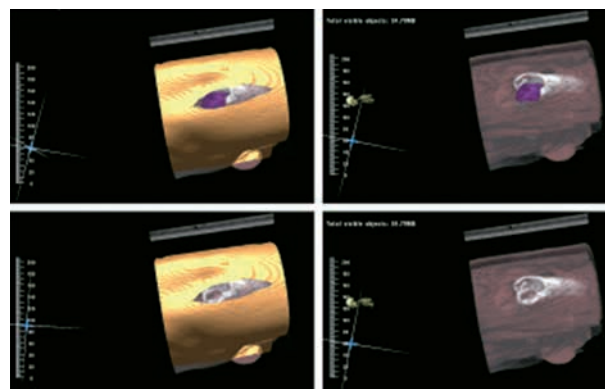


Fig. 4. — Lateral incision (patient no. 1) simulated in the lateral decubitus position. Skin and abductor muscle are incised by layer by layer showing the bone flap fenestration (upper left), phyma curettage (lower left), and hidden skin (upper and lower right).

details of lesion's areas. Some discrepancies were observed between the virtual and actual situation.

Patient 3. A male patient with chondroblastoma in left proximal humerus is shown. Anatomical structures of the proximal humerus were reconstructed, revealing skin and muscles (Fig. 5). Skin incision was simulated, and the tumor surface of the proximal humerus was exposed via the deltopectoral approach. Front fenestration, focus curettage, and allogeneic/autologous bone grafts were performed. Virtual and actual situations were highly consistent.

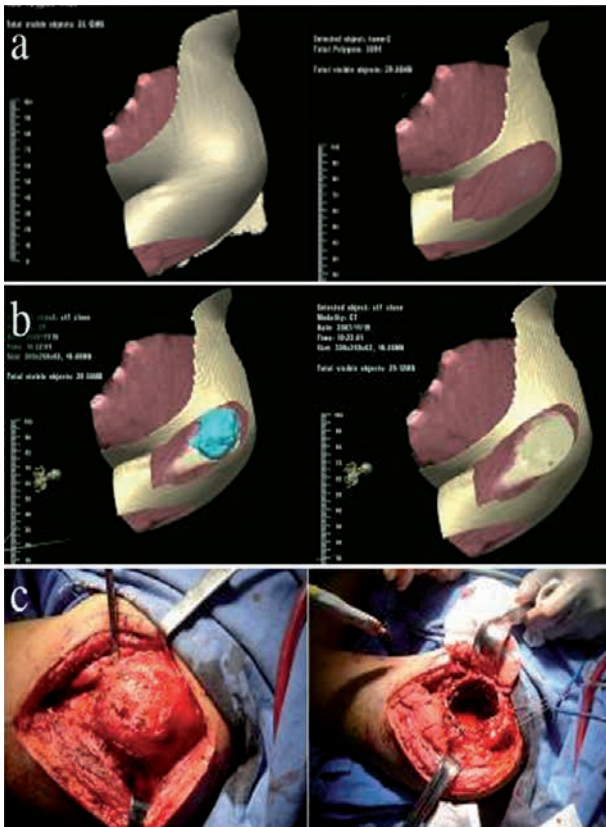


Fig. 5. — Reconstruction of male patient (no. 3) with chondroblastoma of the left proximal humerus. (a) 3D reconstruction of the anatomical structures of the proximal humerus with alternately exposed skin and muscles. (b) Simulated incision in the lateral decubitus position showing skin and abductor muscle incisions to expose the area of interest (tumor surface on the proximal humerus). (c) Actual surgical situation (shown) was highly consistent with the simulated virtual situation.

DISCUSSION

All 10 cases exhibited benign periarticular tumors modeled successfully by Dextroscope, with no significant differences in virtual and actual tumor size measurements or subjective visual assessments ($p < 0.05$). Using this VR environment, a step-wise approach was applied for examination of the skeleton, blood vessels, and musculature by level, aiding in surgical planning. Notably, the resolution (quality) of 3D reconstruction models of variant tissue and tumor types varied highly, suggesting that maximum effectiveness is achieved when highly-accurate visualization of soft tissues and muscles is not required.

In the United States, the market VR applications for healthcare reached approximately \$670 million in sales in 2011, with a high compound annual growth rate (CAGR) of over 10% from 2006-2010 and projected sustained growth through 2015 (8). A number of new fields in healthcare have employed VR and fast imaging steady-state acquisition for preoperative simulation (10). Additionally, VR features are now commonplace in surgical robotics utilized in healthcare and defense programs (11,16). Formal standards have advanced from the original European MultiMedia Usability Services (EMMUS) guideline ISO 13407 (1999 ; *now withdrawn*) to a set of detailed guidelines produced by the contemporary Center for Usability Research and Engineering (CURE) (5,6).

Formal training and certification programs for VR operators have appeared, particularly in fields of laparoscopic surgery where these techniques are commonplace. Additionally, VR-based training programs for conventional surgery now allow novice operators to gain experience prior to attempting real surgical procedures (9). Unfortunately, traditional and informal apprentice-training programs, known to produce methodological inconsistencies and highly variable results (9), are still widely applied in the developing field of orthopedics. New approaches to training, such as techniques that correlate clinical practice with VR training using the Delta consensus approach have recently been proposed, though they have not yet been applied in orthopedic surgery (18). Periartic-

ular tumor treatment strategies involving convention regimens of radiotherapy, chemotherapy, biotherapy, molecular-targeted therapy, and surgery may be dramatically improved by standardization and wide implementation of the VR surgical protocols. Further exploration will, however, be required to generate clinically applicable orthopedic recommendations and training programs for VR applications.

It is widely accepted that MRI T1-weighted images are most accurate for identification of intramedullary tumors, tumor infiltration into soft tissue, and relationships with important vascular and nervous structures (1,17,20). CT scan is, however, superior to MRI for identifying lesions in bone structures, and MRI-A excels at identification of tumor blood supplies (1,17,20). Considering the particularities of periarticular tumor surgery, detailed combination of these images by a trained VR operator can aid in limb salvage operation and preservation of joint function. Numerous methods for 3D virtual workspace construction have been reported, though Dextroscope is the most prominent in contemporary literature over the past decade for its ease and simplicity of comprehensively combining multiple image types to achieve a virtual 2D or 3D workspace (14). For contemporary clinical treatment of periarticular tumors, Dextroscope is the logical approach due to simplicity, comprehensive multi-image integration, and wide availability.

As specialize VR systems and software become increasingly available, the discrepancy between virtual and actual surgical situations is shrinking rapidly, particularly in neurosurgical and laparoscopic fields (2,18). In orthopedics, the accuracy of virtual 3D imaging remains limited imaging resolution limitations, particularly for soft tissues, and operating procession, particularly for minor nerves or blood vessels. For instance, the femoral artery branch in patient no. 1 of the present study was very difficult to visualize and process. Recently, new “advanced” VR, also termed “augmented reality”, systems have appeared that involve sophisticated integrations of stereoscopic evaluation and computational analysis abilities, allowing for fully immersive VR models that not only duplicate but offer more capabilities than actual reality (2). These

approaches may also be useful in future development of more accurate applications involving assessment of periarticular tumors, particularly in cases where quantitative analysis of blood flow may be critical to prevent complications or ensure complete tumor removal.

Additionally, the Dextroscope system is not specifically designed for orthopedic surgery, and it can only be used for simple procedures, such as fenestration. In addition, the system cannot provide the corresponding haptic feedback, which recently became the research focus of neurosurgery and endoscopy (14,26). While validation methodologies for surgical simulation using VR have been established in other fields, these are also urgently required in orthopedic surgery using VR (27). Vankipuram *et al.* (28) report the only study of validation of VR widely available to date, demonstrating that VR could effectively be used as a tool to train novice surgeons for orthopedic drilling. More advanced software add-ons and standardization of simulation methods are urgently required in the field of orthopedics to address specific issues, such as the use of orthopedic specific implants and tools, such as drilling.

The findings in these cases indicate that the Dextroscope system is capable of improving results in basic fenestration by providing 3D VR workspaces that approximate actual periarticular tumor size and surgical situation based on tumor measurements and subjective visual assessments. This method is, at best preliminary, requiring further refinement of specialized tools before wide application of VR can be made in many orthopedic surgery types, such as upper cervical and pelvic tumor surgeries.

REFERENCES

1. Agarwal M, Puri A. Limb salvage for malignant primary bone tumours : current status with a review of the literature. *Indian J Surg* 2003 ; 65 : 354-360.
2. Alaraj A, Lemole MG, Finkle JH, Yudkowsky R, Wallace A, Luciano C, Banerjee PP, Rizzi SH, Charbel FT. Virtual reality training in neurosurgery : Review of current status and future applications. *Surg Neurol Int* 2011 ; 2 : 52.
3. Anil SM, Kato Y, Hayakawa M, Yoshida K, Nagahisha S, Kanno T. Virtual 3-dimensional preopera-

- tive planning with the dextroscope for excision of a 4th ventricular ependymoma. *Minim Invasive Neurosurg* 2007 ; 50 : 65-70.
4. **Cannon WD, Eckhoff DG, Garrett WE, Jr., Hunter RE, Sweeney HJ.** Report of a group developing a virtual reality simulator for arthroscopic surgery of the knee joint. *Clin Orthop Relat Res* 2006 ; 442 : 21-29.
 5. **CURE-Center for Usability Research & Engineering.** Arrival at <http://www.cure.at>.
 6. **EMMUS (European MultiMedia Usability Services).** Introduction to ISO 13407. In 1999. Arrival at www.ucc.ie/hfrg/emmus/methods/iso.html.
 7. **Goh KY.** Separation surgery for total vertical craniopagus twins. *Childs Nerv Syst* 2004 ; 20 : 567-575.
 8. **Gu SX, Yang DL, Cui DM, Xu QW, Che XM, Wu JS, Li WS.** Anatomical studies on the temporal bridging veins with Dextroscope and its application in tumor surgery across the middle and posterior fossa. *Clin Neurol Neurosurg* 2011 ; 113 : 889-894.
 9. **Gurusamy KS, Aggarwal R, Palanivelu L, Davidson BR.** Virtual reality training for surgical trainees in laparoscopic surgery. *Cochrane Database Syst Rev* 2009 : CD006575.
 10. **Kalorama Healthcare Reports.** Virtual Reality (VR) in Healthcare in the US (Markets for Surgery, Visualization, Rehabilitation and Training). *Ed. 2. Kalorama Info* 2011 : 1-185.
 11. **Kin T, Oyama H, Kamada K, Aoki S, Ohtomo K, Saito N.** Prediction of surgical view of neurovascular decompression using interactive computer graphics. *Neurosurgery* 2009 ; 65 : 121-128 ; discussion 128-129.
 12. **Kockro RA, Serra L, Tseng-Tsai Y, Chan C, Yih-Yian S, Gim-Guan C, Lee E, Hoe LY, Hern N, Nowinski WL.** Planning and simulation of neurosurgery in a virtual reality environment. *Neurosurgery* 2000 ; 46 : 118-135 ; discussion 135-117.
 13. **Kockro RA, Stadie A, Schwandt E, Reisch R, Charalampaki C, Ng I, Yeo TT, Hwang P, Serra L, Perneczky A.** A collaborative virtual reality environment for neurosurgical planning and training. *Neurosurgery* 2007 ; 61 : 379-391 ; discussion 391.
 14. **Lemole GM, Jr., Banerjee PP, Luciano C, Neckrysh S, Charbel FT.** Virtual reality in neurosurgical education: part-task ventriculostomy simulation with dynamic visual and haptic feedback. *Neurosurgery* 2007 ; 61 : 142-148 ; discussion 148-149.
 15. **Mabrey JD, Reinig KD, Cannon WD.** Virtual reality in orthopaedics: is it a reality ? *Clin Orthop Relat Res* 2010 ; 468 : 2586-2591.
 16. **McCloy R, Stone R.** Science, medicine, and the future. Virtual reality in surgery. *BMJ* 2001 ; 323 : 912-915.
 17. **Meyer MS, Spanier SS, Moser M, Scarborough MT.** Evaluating marrow margins for resection of osteosarcoma. A modern approach. *Clin Orthop Relat Res* 1999 : 170-175.
 18. **Palter VN, Graafland M, Schijven MP, Grantcharov TP.** Designing a proficiency-based, content validated virtual reality curriculum for laparoscopic colorectal surgery : a Delphi approach. *Surgery* 2012 ; 151 : 391-397.
 19. **Petrolo L, Testi D, Taddei F, Viceconti M.** Effect of a virtual reality interface on the learning curve and on the accuracy of a surgical planner for total hip replacement. *Comput Methods Programs Biomed* 2010 ; 97 : 86-91.
 20. **Quan GM, Slavin JL, Schlicht SM, Smith PJ, Powell GJ, Choong PF.** Osteosarcoma near joints : assessment and implications. *J Surg Oncol* 2005 ; 91 : 159-166.
 21. **Reddix RN, Jr., Webb LX.** Computer-assisted preoperative planning in the surgical treatment of acetabular fractures. *J Surg Orthop Adv* 2007 ; 16 : 138-143.
 22. **Robison RA, Liu CY, Apuzzo ML.** Man, mind, and machine : the past and future of virtual reality simulation in neurologic surgery. *World Neurosurg* 2011 ; 76 : 419-430.
 23. **Spicer MA, Apuzzo ML.** Virtual reality surgery: neurosurgery and the contemporary landscape. *Neurosurgery* 2003 ; 52 : 489-497 ; discussion 496-487.
 24. **Spicer MA, van Velsen M, Caffrey JP, Apuzzo ML.** Virtual reality neurosurgery : a simulator blueprint. *Neurosurgery* 2004 ; 54 : 783-797 ; discussion 797-788.
 25. **Stadie AT, Kockro RA, Reisch R, Tropine A, Boor S, Stoeter P, Perneczky A.** Virtual reality system for planning minimally invasive neurosurgery. Technical note. *J Neurosurg* 2008 ; 108 : 382-394.
 26. **van der Meijden OA, Schijven MP.** The value of haptic feedback in conventional and robot-assisted minimal invasive surgery and virtual reality training : a current review. *Surg Endosc* 2009 ; 23 : 1180-1190.
 27. **Van Nortwick SS, Lendvay TS, Jensen AR, Wright AS, Horvath KD, Kim S.** Methodologies for establishing validity in surgical simulation studies. *Surgery* 2010 ; 147 : 622-630.
 28. **Vankipuram M, Kahol K, McLaren A, Panchanathan S.** A virtual reality simulator for orthopedic basic skills : a design and validation study. *J Biomed Inform* 2010 ; 43 : 661-668.
 29. **Yi ZQ, Li L, Mo DP, Zhang JY, Zhang Y, Bao SD.** Preoperative surgical planning and simulation of complex cranial base tumors in virtual reality. *Chin Med J (Engl)* 2008 ; 121 : 1134-1136.