



## Kienböck's disease in a 6-year-old boy

Pierre-Louis DOCQUIER, Alidou TRAORE, Sébastien HUGON

*From the Cliniques Universitaires Saint-Luc, Brussels, Belgium*

**A case of avascular necrosis of the lunate bone in a 6-year-old boy is reported. This is the youngest child reported in literature with Kienböck's disease. Clinical and radiological healing was obtained with conservative treatment.**

**Non-operative management is recommended in children with avascular necrosis of the lunate bone.**

**Keywords :** Kienböck's disease ; conservative treatment ; children.

### INTRODUCTION

Kienböck's disease or lunatomalacia typically affects young adults between the ages of 20 to 40, predominantly male manual workers (22). The aetiology and treatment remain controversial (7,22). In adults, the condition can lead to a predictable pattern of collapse and arthritis (2). There is no strong evidence to support any particular form of treatment (22). Patients are generally improved with immobilization of the wrist but this does not halt progression of the collapse (22). Various surgical procedures have been advocated but there is still little evidence to support any particular form of operative treatment, or to indicate its superiority over conservative measures (5).

### CASE REPORT

A 6-year-old right-handed boy presented with the diagnosis of Kienböck's disease in the left wrist.

The parents were requiring a second opinion after a surgical intervention (radial shortening) had been planned in another institution.

Initially, the child complained about left wrist pain after a trivial trauma (direct blow). The pain was related to mobilisation of the wrist. The wrist was slightly stiff with slightly decreased extension and flexion. The radiograph showed a Lichtman stage IIIa lunatomalacia (15). A CT-scan (fig 1) and a magnetic resonance imaging (fig 2) were already available. Ulnar variance could not be measured on radiographs, as the ulnar styloid was not yet ossified ; it was measured on the MRI and was found to be negative : -4 mm. A forearm cast had been applied for 6 weeks.

The boy was a fourth child, born at full term, in cephalic presentation with a weight of 3.9 kg. He had presented normal neuropsychomotor development. The child's past history (strabismus operation and tonsillectomy) and family history were non-contributory.

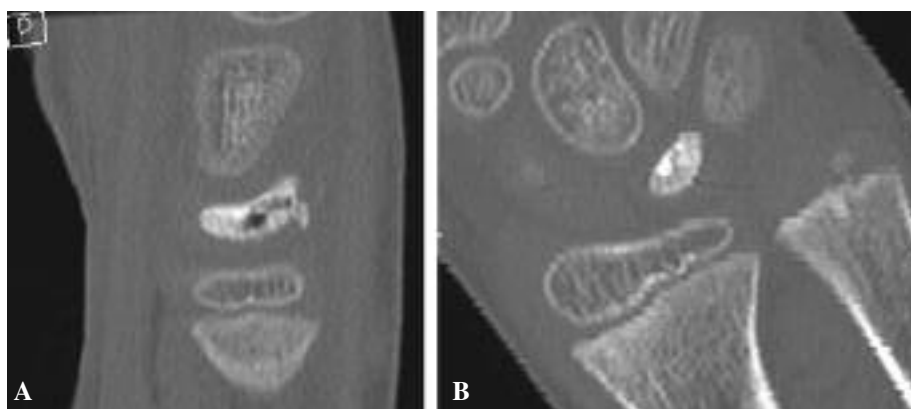
- 
- Pierre-Louis Docquier, MD, Orthopaedic surgeon.
  - Alidou Traoré, MD, Orthopaedic surgeon, Fellow.
  - Sébastien Hugon, MD, Resident.

*Department of Orthopaedic Surgery, Cliniques universitaires St-Luc, Bruxelles, Belgium.*

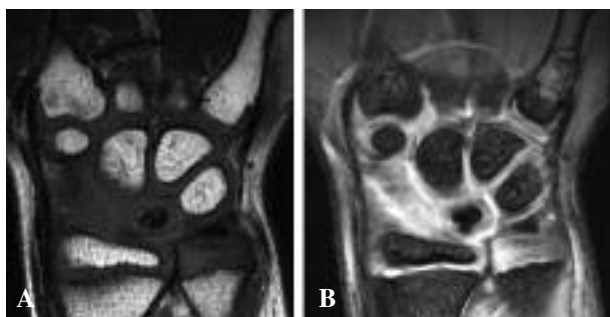
Correspondence : Pierre-Louis Docquier, Department of orthopaedic surgery, Cliniques Universitaires Saint-Luc, 10, avenue Hippocrate, B-1200 Bruxelles, Belgique.

E-mail : Pierre-Louis.Docquier@uclouvain.be

© 2009, Acta Orthopædica Belgica.



**Fig. 1.** — A. Sagittal view of the wrist showing flattening and increased density of the lunate with heterogeneity. B. Coronal view



**Fig. 2.** — A. T1-weighted-MRI showing the avascular necrosis of the lunate (loss of the medullary signal). B. T2-weighted-MRI : hyposignal of the lunate.

At his first visit in our institution, one week after cast removal, the child was not painful anymore but mobility was decreased : flexion 60°, extension 40°. Grip strength was reduced in comparison to the normal side.

A conservative treatment was advised with relative rest (sports not allowed) and a removable orthosis. After four months, he had regained full wrist mobility and the radiograph showed reconstruction signs. After 19 months of follow-up, reconstruction was complete (fig 3) and the child was allowed to practice sports without restriction.

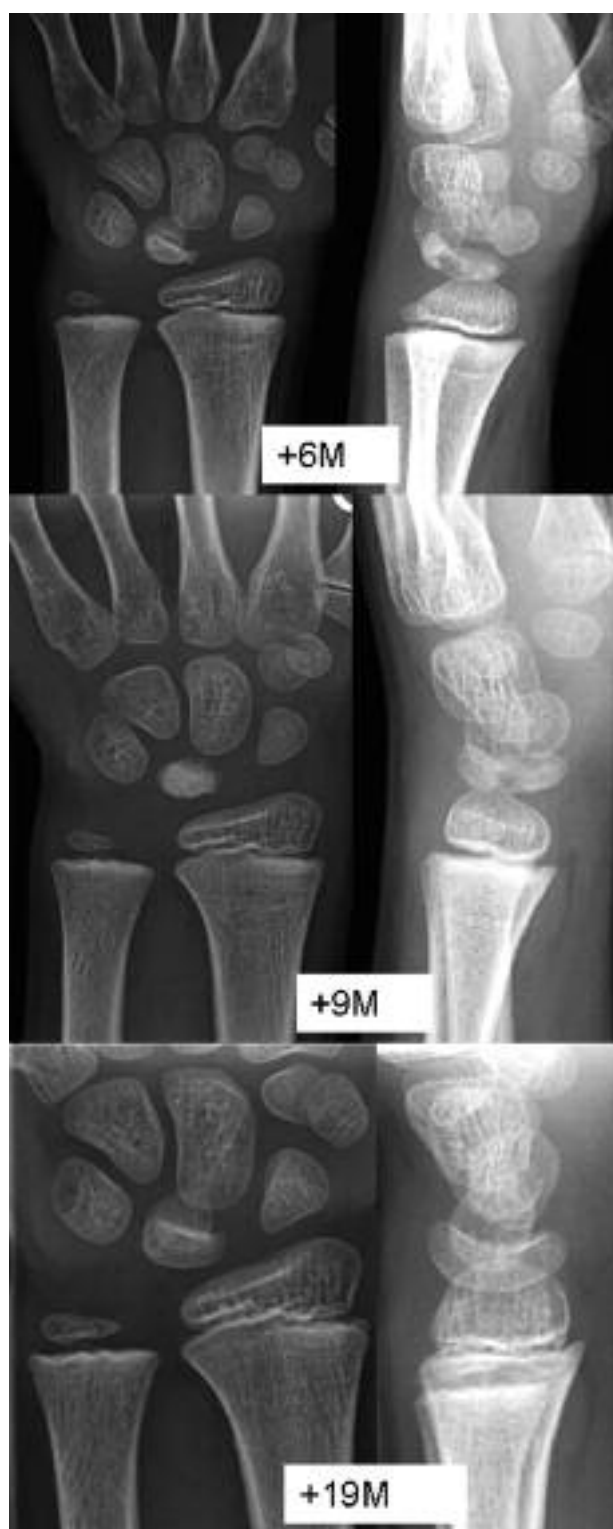## DISCUSSION

The aetiology of Kienböck's disease remains controversial. Negative ulnar variance, major

uncovering of the lunate, abnormal radial inclination, trapezoidal shape of the lunate, and single-sided lunate vascularization pattern have been reported as morphological risk factors (22). In the present case, ulnar variance was negative.

Few cases of Kienböck's disease have been reported in patients younger than 20 years (1,3,4,6,8-14,16-21,23). In these young patients, various postulated aetiologic pathologies have been noted : sickle cell anemia (14), dermatomyositis (13), multiple exostosis (3), cerebral palsy (9). In the other cases, a history of trauma or microtrauma was present (1,10) or no aetiologic factor was found (10,23). The youngest child reported so far in literature was 7 years old (13). The natural history of Kienböck's disease in children seems to be favorable as children have an higher remodeling potential than adults (7). Non operative treatment seems to yield good results (4) with possible long-term normal radiological appearance of the lunate and carpal height ratio restoration (9,21). Other authors reported the effectiveness of radial osteotomies in teenage patients (12,19). Edelson *et al* however reported one case of radial shortening in a 12-year-old child with recurrence of Kienböck's disease 16 months post-operatively (6).

The present case is the youngest child reported with Kienböck's disease. The evolution was favorable with conservative treatment. We agree with most authors to recommend nonoperative treatment in children, as spontaneous healing seems to occur consistently.



**Fig. 3.** — Long-term evolution. Radiograph after 6 and 9 months of follow-up showed signs of revascularization. At 19 months, the lunate is fully vascularized and has a normal shape.

## REFERENCES

1. **Amadio PC, Hanssen AD, Berquist TH.** The genesis of Kienböck's disease : evaluation of a case by magnetic resonance imaging. *J Hand Surg* 1987 ; 12-A : 1044-1049.
2. **Beckenbaugh RD, Shives TC, Dobyns JH, Linscheid RL.** Kienböck's disease : the natural history of Kienböck's disease and consideration of lunate fractures. *Clin Orthop Relat Res* 1980 ; 149 : 98-106.
3. **de Gauzy JS, Kany J, Darodes P, Dequae P, Cahuzac JP.** Kienböck's disease and multiple hereditary osteochondromata : a case report. *J Hand Surg* 1999 ; 24-A : 642-646.
4. **De Smet L.** Kienböck's disease in a 12-year-old girl. *Acta Orthop Belg* 2003 ; 69 : 361-362.
5. **Delaere O, Dury M, Molderez A, Foucher G.** Conservative versus operative treatment for Kienböck's disease. A retrospective study. *J Hand Surg* 1998 ; 23-B : 33-36.
6. **Edelson G, Reis ND, Fuchs D.** Recurrence of Kienböck disease in a twelve-year-old after radial shortening. Report of a case. *J Bone Joint Surg* 1988 ; 70-A : 1243-1245.
7. **Ferlic RJ, Lee DH, Lopez-Ben RR.** Pediatric Kienböck's disease : case report and review of the literature. *Clin Orthop Relat Res* 2003 ; 408 : 237-244.
8. **Foster RJ.** Kienböck's disease in an 8-year-old girl : a case report. *J Hand Surg* 1996 ; 21-A : 595-598.
9. **Greene WB.** Kienböck disease in a child who has cerebral palsy. A case report. *J Bone Joint Surg* 1996 ; 78-A : 1568-1573.
10. **Hosking OR.** Kienböck's disease in an 8 year old boy. *Aust N Z J Surg* 1989 ; 59 : 92-93.
11. **Imaeda T, Nakamura R, Miura T, Makino N.** Magnetic resonance imaging in Kienböck's disease. *J Hand Surg* 1992 ; 17-B : 12-19.
12. **Iwasaki N, Minami A, Ishikawa J, Kato H, Minami M.** Radial osteotomies for teenage patients with Kienböck disease. *Clin Orthop Relat Res* 2005 ; 439 : 116-122.
13. **Kahn SJ, Sherry DD.** Kienböck's disease-avascular necrosis of the carpal lunate bone-in a 7-year-old girl with dermatomyositis. *Clin Pediatr* 1994 ; 33 : 752-754.
14. **Lanzer W, Szabo R, Gelberman R.** Avascular necrosis of the lunate and sickle cell anemia. A case report. *Clin Orthop Relat Res* ; 187 : 168-171.
15. **Lichtman DM, Mack GR, MacDonald RI, Gunther SF, Wilson JN.** Kienböck's disease : the role of silicone replacement arthroplasty. *J Bone Joint Surg* 1977 ; 59-A : 899-908.
16. **Mathieu L, Dumontier C.** [Kienböck's disease in a nine-year-old boy : a case report.] (in French). *Chir Main* 2009 ; 28 : 99-102.
17. **Minami A, Itoga H, Kobayashi M.** Kienböck's disease in an eleven-year-old girl. A case report. *Ital J Orthop Traumatol* 1992 ; 18 : 547-550.
18. **Nakamura R, Imaeda T, Suzuki K, Miura T.** Sports-related Kienböck's disease. *Am J Sports Med* ; 19 : 88-91.

19. Nakamura R, Imaeda T, Miura T. Radial shortening for Kienböck's disease : factors affecting the operative result. *J Hand Surg* 1990 ; 15-B : 40-45.
20. Nakamura R, Watanabe K, Tsunoda K, Miura T. Radial osteotomy for Kienböck's disease evaluated by magnetic resonance imaging. 24 cases followed for 1-3 years. *Acta Orthop Scand* 1993 ; 64 : 207-211.
21. Rasmussen F, Schantz K. Lunatomalacia in a child. *Acta Orthop Scand* 1987 ; 58 : 82-84.
22. Schuind F, Eslami S, Ledoux P. Kienböck's disease. *J Bone Joint Surg* 2008 ; 90-B : 133-139.
23. Yasuda M, Okuda H, Egi T, Guidera PM. Temporary scapho-trapezoidal joint fixation for Kienböck's disease in a 12-year-old girl : a case report. *J Hand Surg* 1998 ; 23-A : 411-414.