



## Management of greater trochanteric pain syndrome : a systematic review

Simon KOULISCHER, Antoine CALLEWIER, David ZORMAN

*From the Université Libre de Bruxelles, Belgium*

**Greater trochanteric pain syndrome is characterized by pain at or around the greater trochanter. Numerous management modalities have been proposed, with varying success. Cochrane and Pubmed database have been searched from 1990 for studies focusing on the management of this syndrome. We only selected studies with a validated outcome measure. 11 studies met our inclusion criteria. Evidence points towards a pain reduction in the first months after a corticosteroid injection, but this effect does not persist with time. Low energy shock wave therapy also has a positive effect in the short term, the longer term results being more controversial. Although surgery is poorly documented, authors agree to reserve this option only for greater trochanteric pain syndrome failing to respond to conservative measures. The complication and re-intervention rate should not be underestimated.**

**Keywords :** greater trochanteric pain syndrome; trochanteritis ; lateral hip pain; corticosteroid injection

### INTRODUCTION

Greater trochanteric pain syndrome is a frequently overlooked cause of lateral hip pain. GTPS is characterized by prolonged or intermittent peritrochanteric pain exacerbated by palpation of the lateral aspect of the hip (25). Other frequently reported symptoms include pain with weight-bearing activities and pain with lying on the side at night (11, 14). A variety of underlying

diagnoses may cause GTPS : bursopathy, calcific tendinitis, iliotibial-band syndrome, snapping hip syndrome, meralgia paresthetica (32). However most of these clinical entities lack clear diagnostic criteria or management algorithm. The term GTPS encompasses those different entities, and is therefore more frequently used. The terms “trochanteric bursitis” or “trochanteritis” have been used in the past as synonyms, but since histological and radiological studies haven’t established clear signs of inflammation of the bursa (4, 41) these terms are now infrequently used.

In the general practice, the incidence has been estimated at 1.8 per 1000 persons per year (28), and the prevalence at 5.6 patients per 1000 adults (5). It is more frequent in women aged 40 to 60 (39, 48). The higher prevalence in women has been related to the broader configuration of the pelvis, leading to abnormal force vectors around the hip. Sporting activities have also been incriminated (3).

Lateral hip pain can be referred from the hip joint and does not clearly differentiate GTPS from hip

- Simon Koulischer, MD
- Antoine Callewier, MD
- David Zorman, MD

*Université Libre de Bruxelles Belgium*

Corresponding author: Simon Koulischer Address : Service d’orthopédie, CHU La Louvière, Avenue Max Buset 34, 7100 La Louvière.

E-mail : simon.koulischer@gmail.com

© 2017, Acta Orthopædica Belgica.

*No benefits or funds were received in support of this study. The authors report no conflict of interests.*

Acta Orthopædica Belgica, Vol. 83 - 2 - 2017

osteoarthritis. A positive FABER (flexion abduction external rotation) in patient with lateral hip pain (LHP) response helps to differentiate GTPS from osteoarthritis with a mean sensitivity of 0.81 and a mean specificity of 0.82 (18). However, no clear diagnostic criteria have been established and most author agree that it is a diagnostic of exclusion, based on clinical findings. It is frequently overlooked : 20% of patients referred for lower back pain to a tertiary care surgical spine specialist for consideration of surgery were ultimately diagnosed with GTPS (44).

Radiologic studies are often necessary to exclude other diagnosis, or to confirm GTPS. MRI has high sensitivity and low specificity for diagnosing GTPS (2). It is however a good exam to exclude gluteus medius tears (13). Sonographic findings include edema around the abductors tendons and tendinosis (29).

Conservative measures including over-the-counter analgesic and rest are usually effective (21). Physiotherapy, low-energy shock wave therapy, and local corticosteroid injection are frequently used as a second-line treatment. Lastly, multiple surgical interventions have been described for recalcitrant GTPS.

There is a multiplication of publications focusing on intra- or extra articular hip pathology and arthroscopy. However most of these studies are of low evidence level and there is no consensus regarding the management options.

Lateral hip pain after total hip arthroplasty (THA) has sometimes been related to GTPS. Multiple causes of persisting pain can be incriminated after THA (45). These causes differ both in terms of frequency and nature compared to the causes of GTPS on native hips. The demographic findings of GTPS after THA are different : the male-female ratio tends to be more equal, and the age at onset is higher. For these reasons, it seemed reasonable to exclude the THA patients of this study.

In the recent years, multiple studies have been undertaken about gluteus medius tear and such lesions have evolved to a separate clinical entity, which requires a specific treatment (8).

For those two reasons, it seemed us important to limit the scope of this review to the current

literature of the management of GTPS on native hips, excluding gluteus medius tears.

Two systematic reviews on the topic have been published (14, 30). Probably due to the paucity of evidence, both review included studies lacking validated outcome measures. They also included studies focusing primarily on gluteus medius tears repairs. The aim of this systematic review is to numerate the management modalities available for GTPS that have been documented by studies using validated outcomes measures. We also want to grade the evidence available for each therapeutic option, and provide directions for further research.

## MATERIALS AND METHODS

This systematic review and meta-analysis was performed in accordance with the PRISMA (Preferred Reporting Items for Systematic Reviews and Meta-Analyses) format (27). We performed an electronic search of the published literature by searching the PubMed database from 1990 through 2015 and the Cochrane Controlled Trials Register from its inception through 2015 for papers appropriate to this study. Terms for the database searches included “greater trochanteric pain syndrome” and “trochanteric bursitis”. A study was potentially eligible for inclusion in the systematic review if the duration of follow-up was at least three months and the study was peer-reviewed and in the English language. Technical reviews, case reports, studies in a language other than English, studies that lacked peer review were excluded.

Inclusion and exclusion criteria can be found in table 1.

The search was conducted on the 21 of october 2015 and last updated on the 5th of december 2015. Review of the abstracts of the identified studies reduced the number of potentially eligible studies. The full text of these articles was reviewed, with further exclusion of studies not meeting our inclusion criteria. The bibliographies of all identified studies were also searched. These studies underwent data extraction of demographic and outcome measures as well as quality appraisal. We chose difference in means as our main summary measure. Articles were sought for conflict of

Table I. — Inclusion and exclusion criteria

Inclusion criteria	Exclusion criteria
Validated clinical outcome measures	Gluteus medius repair technique
Follow-up of at least three months	GTPS post THA
Minimum of four subjects included	Non English language
MINORS index of at least 10 and 16 for non comparative studies and comparative studies respectively	Conference and meeting abstracts

interest. Determination of study evidence level was based on recommendations by the Centre for Evidence-based Medicine.

Heterogeneity of the data precluded the realization of a meta-analysis. For the same reason, it was not possible to quantify the effect of a possible publication bias.

## RESULTS

### *Conservative treatment*

In a RCT in a general practice setting, Brinks et al randomized 60 GTPS-patients to a course of analgesics as needed. At 3 months, 34% of the patients had recovered corresponding to a decrease in the mean VAS of 1.6 (5.3 to 3.7). At 12 months follow-up, 60% of the patients had recovered and mean VAS was 3 points lower (2.3). Of note, we do not know if the patients in this group had complementary physiotherapy, has the access to physiotherapy is unrestricted in the Netherlands. (6)

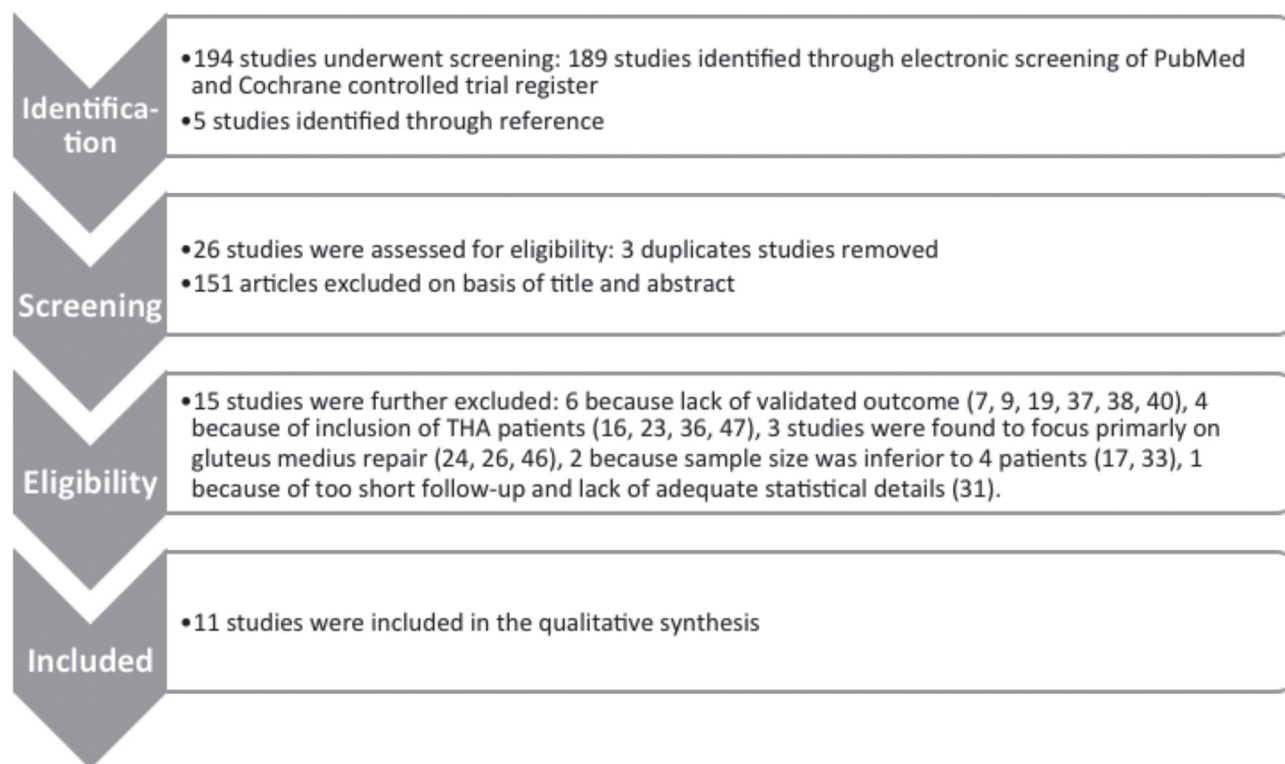
In a level II quasi-randomized design, Rompe et al sequentially assigned 229 patients to LEWS, home training or corticosteroids injections. 76 patients were allocated to 6 weeks of a home training program consisting of piriformis and ITB stretching, gluteal strengthening, straight leg raises, and assisted squats. At 4 months, 40.8% had significant improvement, defined as “completely recovered” or “much improved” on the Likert scale. Pain improved on average 1 point on the VAS (6.2 to 5.2). At 15 months, 80.2% had completely or much improved, with the decrease in VAS further improving to 3.5 (from 6.2 to 2.7). (35)

In the same study, 76 patients were assigned to a course of low-energy shock-wave therapy (SWT). At 3 months, the VAS had decreased of 2.9 (from 6.3 to 3.2). At 15 months, 74.3% of the patients

described having completely recovered or being much improved, with an overall VAS decrease of 3.5 (from 6.3 to 2.4). In a case control study, Furia reported a 30.3 mean increase in HHS of 33 patients after 12 months of LESWT treatment. Compared with the primary outcome of other conservative measures, SWT had a superior VAS and Harris Hip Score (HHS) improvement. Shock-wave therapy allowed 64% of patients to return to normal physical activity. This overall improvement in the LEWS group was better than that in a control group, which was treated with a multimodal approach consisting of a combination of relative rest, anti-inflammatory medications, ice, gluteal and tensa fascia lata muscle stretching and strengthening, physiotherapy modalities, iontophoresis, a corticosteroid injection, and a local anesthetic injection. However, no explicit delineated program for the control group is described. (20)

In both studies, minimal complications of shock-wave therapy were reported, such as temporary erythema and skin irritation and pain during procedure.

Three studies examined the effect of a single injection of mixture of corticosteroid and local anesthetic. Cohen et al conducted a multicenter double blind randomized control trial. 64 patients were randomized in two groups of 32 patients. The first group had a fluoroscopically guided injection and the second group a traditional bedside injection. No statistically significant differences in outcome was found between the groups, neither at one month post-injection, nor at 3 months post injection. The overall VAS improvement was of 2.4 points at 1 months and 2.5 points (4.8 to 2.3) at 3 months. 33 patients (51%) perceived a positive global effect at 3 months. 1 patient (1.5%) was lost to follow-up at 1 months, and 16 (25%) at 3 months. The use of fluoroscopy increased the cost of the procedure



#### Conservative:

- Analgesics as needed (6)
- Home-training (35)
- Low-energy shock wave therapy (20, 35)
- Injection of corticosteroid and local anesthetic (6, 10, 35)
- Multimodal (20)

#### Open surgery:

- Longitudinal ITB release and bursectomy (42)
- Trochanteric reduction osteotomy (22)
- Proximal ITB lengthening (12)
- Distal ITB lengthening (34)

#### Endoscopic surgery:

- Bursectomy (1)
- ITB release and bursectomy (15)

Table II — The results of conservative management in the included studies

Date, First Author	Number of subjects	Intervention	Outcome	Follow-up	Results (difference in outcome mean)	Lost to follow up	Level of evidence
2009, Cohen (43) (10)	64	Fluoroscopically guided injection (N=32) and bedside injection (N=32)	VAS (secondary outcome: Oswestry, SF-36, patient satisfaction)	3 months	FGI: VAS from 5.1 to 2.6 and 2.0 at rest at 1 and 3 month respectively BI: From 4.6 to 2.7 and 1.9 at 1 and 3 months respectively no statistically significant difference between two groups	1.5% at 1 months, and 25% at 3 months	2
2009, Furia (20)	66	LESWT (N=33) and multimodal therapy (MT) (N=33)	VAS, Harris Hip score, Roles and Maudsley score	12 months	LESWT: VAS from 8.5 to 3.7 and 2.7 at 3 and 12 months respectively MT: VAS from 8.5 to 7 and 6.3 at 3 and 12 months respectively The results of LESWT were found significantly better than the control group.	3 out of 69	3
2009, Rompe (35)	239	LESWT (N= 78) Corticosteroids injections (N= 75), Home training (N= 76)	VAS, Likert scale	15 months	LESWT: VAS from 6.3 to 3.2 and 2.4 at 4 and 15 months Corticosteroids injection: VAS from 5.8 to 4.5 and 5.3 at 4 and 15 months Home training: VAS from 6.2 to 5.2 and 2.7 at 4 and 15 months See text for interpretation	16 out of 239	2
2011, Brinks (6)	120	Analgesics as needed/ Usual Care (UC) (N=60), Corticosteroid injection	Likert scale, NRS	12 months	UC: NRS from 5.3 to 3.7 and 2.3 respectively Injection: NRS from 5.1 to 2.5 and 2.1 respectively	0 out of 120	2

FGI : fluoroscopically guided injection ; BI : Blind injection; UC ; NRS: numeric rating scale ;

by up to 700%, but was not superior in terms of outcome. (10)

76 patients were assigned to a single injection in the study by Rompe. At 4 months follow-up, the VAS improved from 5.8 to 4.5, and 50.6% were completely recovered or much improved. These results were found significantly better than home-training, but no differences with LESWT could be established. 15 months after the injection however, VAS was at 5.3 (overall difference in mean VAS : 0.5), which was found significantly worse than the results observed in the home training and LESWT

groups. At 15 months, radial shock wave and home training were equally effective, with failure rates of 26 and 20% respectively.

In the injection arm of the randomized controlled trial conducted by Brinks, the VAS evolved from 5.1 initially to 2.5 and 2.1 at respectively 3 and 12 months post injection. These results at 3 months are significantly better than those observed in the usual care group, but no differences within the 2 groups could be found 12 months after the injection.

Reported complications of corticosteroids and local anesthetic injection have a low incidence and

include skin irritation, swelling, transient insensible spot and a temporary increase in local pain.

The results of conservative management in the included studies is reported in table 2

FGI : fluoroscopically guided injection; BI : Blind injection; UC ; NRS : numeric rating scale;

### *Surgery*

6 articles focusing on 6 different surgical technique were included in the review, representing 94 patients (102 hip). All are case series of level 4 evidence. The patients were included after a failure of a minimum of 6 month conservative treatment. None of the included surgical study had a proper control group. Although no serious complication was described, the overall re-intervention rate was 3.8%. 4 of the 6 surgical studies included involve either direct lengthening or release of the ITB.

Open longitudinal ITB release and bursectomy was described by Slawski in 1997, in 5 patients (7 hips) that had a trochanteritis for one year non responsive to conservative management. The mean HHS improved from 51 to 95 at a mean 20 months of follow up. Slawski does not report any complication. All patients were satisfied and had unrestricted return to athletic and vocational activities. 1 patient lost to follow up at 20 months (but improved at 6 months). (42)

In 2003, Govaert described an open trochanteric reduction osteotomy. The proposed theoretical background was that this intervention could provide hyperhemia, and biomechanical benefits including a reduction in friction. 10 patients (12 hips) were included in the study. Of note, 5 of the patients included had a previous unsuccessful open ITB release and bursectomy. The mean Merle d'Aubigné Postel score improved from 15.8 to 27.5. Complications included persisting pain related to osteosynthesis hardware, hematoma, and heterotopic calcification. 3 patients had to be re-operated on. One patient complained of screw-related pain, one underwent surgical drainage for haematoma. One patient had post-traumatic displacement of the greater trochanter after 6 months from surgery and one had post-operative poor results with persistent pain and marked Trendelenburg gait. (22)

In 2007, Baker evaluated the results of 30 patients who underwent arthroscopic bursectomy. At a mean 26 months follow-up, the mean HHS improved from 51 to 77 ( $p < 0.001$ ). Five patients were lost to follow-up (16.6%). All improvements were seen early, at the 1-month examination and did not tend to deteriorate over time. Of the patients, 72% (18/25) stated that they would definitely or likely have the surgery again, whereas 8% (2/25) would definitely not. 2 patients had to undergo reinterventions : 1 for persisting symptoms with realization of an open procedure; 1 patients had to undergo the drainage of a seroma. (1)

In 2007, Craig evaluated the results of an open proximal Z-lengthening of the ITB. Once the ITB overlying the greater trochanter has been exposed, anterior and posterior longitudinal incisions are made, and the band is divided in a Z-fashion. The longitudinal incision in the ITB is then repaired by lengthening the band by 1 cm, leaving open the 5-cm long proximal defect overlying the posterior aspect of the greater trochanter. 15 patients (17 hips) were retrospectively evaluated. After a mean follow-up of 47 months, the HHS improved from 46 to 82. 8 patients described excellent results; 8 good results; 1 poor result. This single patient underwent a secondary repair gluteus medius. (12)

Open distal ITB lengthening under local anesthetics was reported by Pretell. 11 patients (13 hips) were evaluated at a mean follow up of 43 months. The mean HHS improved from 61 to 91 ( $p < 0.05$ ). 1 patient had to be reoperated for seroma drainage. Other reported complication included pain during procedure. (34)

In 2015, Dominguez evaluated 23 patients who had an endoscopic release of the ITB and peritrochanteric bursectomy. HHS improved from 40 to 86 at one year. Complication included hematoma. One patient developed a neuroma that was subsequently excised under local anesthetics. (15)

## DISCUSSION

Although GTPS is a frequent and debilitating condition, limited evidence about the management

Date, First Author	Number of subjects (hips)	Intervention	Mean follow-up (months)	Primary outcome	Results	Complications	Reintervention rate	Lost to follow-up	Level of evidence
1997, Slawski	5 (7)	Open ITB release and bursectomy	20	HHS	HHS from 51.7 to 95	NA	NA	1 out of 7	4
2003, Goovaert	10 (12)	Open trochanteric reduction and osteotomy	23	PMA	15.8 to 27.5	Haematoma, persisting pain with Trendelenburg gait, heterotopic calcification, post-traumatic displacement of the greater tochanter	25%	0	4
2007, Baker	30 (30)	Endoscopic bursectomy	26.1	VAS, HHS	HHS from 51 to 77	Persisting pain, hematoma, seroma	2 out of 30 (1 for seroma drainage, of for conversion open procedure)	5 out of 30	4
2007, Craig	15 (17)	Open proximal ITB Z-lengthening	47	HHS	46 to 82	Persisting pain	1 secondary repair of gluteus medius	0	4
2009, Pretell	11 (13)	Open distal ITB lengthening	43	HHS	61 to 91	seroma	Seroma	0	4
2015, Dominguez	23 (23)	Endoscopic bursectomy and ITB release	12	HHS, VAS, WOMAC, HOS	40 to 86	Hematoma, seroma	1 out of 23 (neuroma excision)	NA	4

option is available.

Most authors agree that the condition is self-limited. The control arm of Brinks trial documented a 60% recovery rate at 12 months with a symptomatic analgesic treatment.

Corticosteroids injection and LESWT are the best documented therapeutic options.

There is concordant data to support the idea that corticosteroids are more effective than usual care

(6) or home-training (35) in the first four months after the injection. This effect does not last : at 15 months, although the result of injection has been reported similar to usual care (6), they are worse than home-training or LESWT. This phenomenon of a transient amelioration after corticosteroid injection has also been observed for other chronic tendinopathies, like epicondylitis (43). Furthermore, a possible effect of dry needling on GTPS has been

recently suggested (33). We couldn't find any trial with injection of a placebo, which could rule out needling as an effect-modifier.

LESWT is more efficient than injection and multimodal therapy after a follow-up of at least 12 months. Only minor adverse events are reported. However larger scale trials are necessary to confirm those results.

There is a consensus to reserve surgery only to patients not responding to conservative treatment. The time between onset of the symptoms and surgery seems to decline in the recent years : 6 months in 2015 study (15), 1 one year in 2009 (34), compared to a mean 3.8 years in 1997 (42). There is lack of consensus regarding the best surgical technique : every article included related a different surgical procedure, although the majority of the procedure where aimed at releasing or lengthening the ITB.

Most study reports good results, but no control group is included. Because of the heterogeneity in the inclusion criteria and low number of patients included, it is not possible to compare the results of different surgical methods. Greater trochanteric osteotomy is the procedure with the highest complication rate.

Although no serious complication was reported with the endoscopic procedure, the overall reintervention rate is reported at 5.6%. Therefore, in our opinion, the assumption that endoscopic procedure is a "safe and easily reproducible procedure" (15) should be better documented, with regards to the low number and quality of evidence available. Although frequently used in the management of other chronic tendinopathies, the effect of Platelet Rich Plasma-injection has not been thoroughly investigated for this particular indication.

The main limitations of this study come from the studies it is based on. Most author agree that GTPS is a clinical diagnosis. This lack of clear diagnostic criteria and resultant heterogeneity make the comparison between studies difficult. Some authors systematically exclude other conditions through imagery. Some author use a positive response to injection has a diagnostic clue to the diagnosis, whereas some author consider absence of response

to injection has a GTPS reluctant to conservative measure. Lot of research are focusing on the management of gluteus medius tear – since the conditions frequently overlap, ruling out such tears with MRI might prove useful.

We did not include unpublished evidence. Furia has pointed out the existence of unpublished data regarding LESWT (20). Furthermore, we did not include non-english language publications.

## CONCLUSION

GTPS is a frequent cause of lateral hip pain. It is frequently overlooked. In the majority of the cases, the evolution is spontaneously favorable. Corticosteroids have a positive effect in the first months after the injection, but this effect does not persist with time. LESWT has a positive effect in the short term, the longer term results are more controversial, some studies finding no difference with home training at 15 months, although another study found better results with LESWT than multimodal approach at 12 months. Surgery is nowadays only reserved to GTPS failing to respond to conservative measures. There is a lack of consensus regarding the best surgical technique. Although most of the results are good, the complication and re-intervention rate should not be overlooked. Furthermore, all the surgical studies are case series (level 4 evidence) lacking proper control group. Therefore, in our opinion, surgery for recalcitrant GTPS should be reserved to informed patients that are included in research protocols. Further studies should focus on defining and validating clear diagnostics criteria for GTPS. The natural evolution of GTPS should also be better documented. Larger scale prospective surgical trial with proper selected control groups should be conducted in order to analyse the potential benefit in recalcitrant GTPS.

## REFERENCES

1. Baker CL, Massie RV, Hurt WG, Savory CG. Arthroscopic bursectomy for recalcitrant trochanteric bursitis. *Arthrosc J Arthrosc Relat Surg Off Publ Arthrosc Assoc N Am Int Arthrosc Assoc* 23 : 827–832, 2007.



2. **Blankenbaker DG, Ullrick SR, Davis KW et al.** Correlation of MRI findings with clinical findings of trochanteric pain syndrome. *Skeletal Radiol* 37 : 903–909, 2008.
3. **Blank E, Owens BD, Burks R, Belmont PJ.** Incidence of greater trochanteric pain syndrome in active duty US military servicemembers. *Orthopedics* 35 : e1022–1027, 2012.
4. **Board TN, Hughes SJ, Freemont AJ.** Trochanteric bursitis : the last great misnomer. *Hip Int J Clin Exp Res Hip Pathol Ther* 24 : 610–615, 2014.
5. **Brinks A, van Rijn RM, Bohnen AM et al.** Effect of corticosteroid injection for trochanter pain syndrome : design of a randomised clinical trial in general practice. *BMC Musculoskelet Disord* 8 : 95, 2007.
6. **Brinks A, van Rijn RM, Willemsen SP et al.** Corticosteroid injections for greater trochanteric pain syndrome : a randomized controlled trial in primary care. *Ann Fam Med* 9 : 226–234, 2011.
7. **Brooker AF.** The surgical approach to refractory trochanteric bursitis. *Johns Hopkins Med J* 145 : 98–100, 1979.
8. **Chandrasekaran S, Gui C, Hutchinson MR et al.** Outcomes of Endoscopic Gluteus Medius Repair : Study of Thirty-four Patients with Minimum Two-Year Follow-up. *J Bone Joint Surg Am* 97 : 1340–1347, 2015.
9. **Chirputkar K, Weir P, Gray A.** Z-lengthening of the iliotibial band to treat recalcitrant cases of trochanteric bursitis. *Hip Int J Clin Exp Res Hip Pathol Ther* 17 : 31–35, 2007.
10. **Cohen SP, Strassels SA, Foster L, Marvel J, Williams K, Crooks M, Gross A, Kurihara C, Nguyen C, Williams N.** Comparison of fluoroscopically guided and blind corticosteroid injections for greater trochanteric pain syndrome : multicentre randomised controlled trial. *BMJ* 338 : b1088, 2009.
11. **Collée G, Dijkmans BA, Vandenbroucke JP, Cats A.** Greater trochanteric pain syndrome (trochanteric bursitis) in low back pain. *Scand J Rheumatol* 20 : 262–266, 1991.
12. **Craig RA, Jones DPG, Oakley AP, Dunbar JD.** Iliotibial band Z-lengthening for refractory trochanteric bursitis (greater trochanteric pain syndrome). *ANZ J Surg* 77 : 996–998, 2007.
13. **Cvitanić O, Henzie G, Skezas N, Lyons J, Minter J.** MRI diagnosis of tears of the hip abductor tendons (gluteus medius and gluteus minimus). *AJR Am J Roentgenol* 182 : 137–143, 2004.
14. **Del Buono A, Papalia R, Khanduja V, Denaro V, Maffulli N.** Management of the greater trochanteric pain syndrome : a systematic review. *Br Med Bull* 102 : 115–131, 2012.
15. **Domínguez A, Seijas R, Ares O, Sallent A, Cuscó X, Cugat R.** Clinical outcomes of trochanteric syndrome endoscopically treated. *Arch Orthop Trauma Surg* 135 : 89–94, 2015.
16. **Farmer KW, Jones LC, Brownson KE, Khanuja HS, Hungerford MW.** Trochanteric bursitis after total hip arthroplasty : incidence and evaluation of response to treatment. *J Arthroplasty* 25 : 208–212, 2010.
17. **Farr D, Selesnick H, Janecki C, Cordas D.** Arthroscopic bursectomy with concomitant iliotibial band release for the treatment of recalcitrant trochanteric bursitis. *Arthrosc J Arthrosc Relat Surg Off Publ Arthrosc Assoc N Am Int Arthrosc Assoc* 23 : 905.e1–5, 2007.
18. **Fearon AM, Scarvell JM, Neeman T, Cook JL, Cormick W, Smith PN.** Greater trochanteric pain syndrome : defining the clinical syndrome. *Br J Sports Med* 47 : 649–653, 2013.
19. **Fox JL.** The role of arthroscopic bursectomy in the treatment of trochanteric bursitis. *Arthrosc J Arthrosc Relat Surg Off Publ Arthrosc Assoc N Am Int Arthrosc Assoc* 18 : E34, 2002.
20. **Furia JP, Rompe JD, Maffulli N.** Low-energy extracorporeal shock wave therapy as a treatment for greater trochanteric pain syndrome. *Am J Sports Med* 37 : 1806–1813, 2009.
21. **Geraci MC, Brown W.** Evidence-based treatment of hip and pelvic injuries in runners. *Phys Med Rehabil Clin N Am* 16 : 711–747, 2005.
22. **Govaert LHM, van der Vis HM, Marti RK, Albers GHR.** Trochanteric reduction osteotomy as a treatment for refractory trochanteric bursitis. *J Bone Joint Surg Br* 85 : 199–203, 2003.
23. **Iorio R, Healy WL, Warren PD, Appleby D.** Lateral trochanteric pain following primary total hip arthroplasty. *J Arthroplasty* 21 : 233–236, 2006.
24. **Kagan A.** Rotator cuff tears of the hip. *Clin Orthop* : 135–140, 1999.
25. **Karpinski MR, Piggott H.** Greater trochanteric pain syndrome. A report of 15 cases. *J Bone Joint Surg Br* 67 : 762–763, 1985.
26. **Lequesne M, Djian P, Vuillemin V, Mathieu P.** Prospective study of refractory greater trochanter pain syndrome. MRI findings of gluteal tendon tears seen at surgery. Clinical and MRI results of tendon repair. *Jt Bone Spine Rev Rhum* 75 : 458–464, 2008.
27. **Liberati A, Altman DG, Tetzlaff J et al.** The PRISMA statement for reporting systematic reviews and meta-analyses of studies that evaluate healthcare interventions : explanation and elaboration. *BMJ* 339 : b2700, 2009.
28. **Lieveense A, Bierma-Zeinstra S, Schouten B, Bohnen A, Verhaar J, Koes B.** Prognosis of trochanteric pain in primary care. *Br J Gen Pract J R Coll Gen Pract* 55 : 199–204, 2005.
29. **Long SS, Surrey DE, Nazarian LN.** Sonography of greater trochanteric pain syndrome and the rarity of primary bursitis. *AJR Am J Roentgenol* 201 : 1083–1086, 2013.
30. **Lustenberger DP, Ng VY, Best TM, Ellis TJ.** Efficacy of treatment of trochanteric bursitis : a systematic review.

- Clin J Sport Med Off J Can Acad Sport Med* 21 : 447–453, 2011.
31. **McEvoy JR, Lee KS, Blankenbaker DG, del Rio AM, Keene JS.** Ultrasound-guided corticosteroid injections for treatment of greater trochanteric pain syndrome : greater trochanter bursa versus subgluteus medius bursa. *AJR Am J Roentgenol* 201 : W313–317, 2013.
  32. **Mulligan EP, Middleton EF, Brunette M.** Evaluation and management of greater trochanter pain syndrome. *Phys Ther Sport Off J Assoc Chart Physiother Sports Med* 16 : 205–214, 2015.
  33. **Pavkovich R.** Effectiveness of dry needling, stretching, and strengthening to reduce pain and improve function in subjects with chronic lateral hip and thigh pain : a retrospective case series. *Int J Sports Phys Ther* 10 : 540–551, 2015.
  34. **Pretell J, Ortega J, García-Rayo R, Resines C.** Distal fascia lata lengthening : an alternative surgical technique for recalcitrant trochanteric bursitis. *Int Orthop* 33 : 1223–1227, 2009.
  35. **Rompe JD, Segal NA, Cacchio A, Furia JP, Morral A, Maffulli N.** Home training, local corticosteroid injection, or radial shock wave therapy for greater trochanter pain syndrome. *Am J Sports Med* 37 : 1981–1990, 2009.
  36. **Sayed-Noor AS, Pedersen E, Wretenberg P, Sjöden GO.** Distal lengthening of ilio-tibial band by Z-plasty for treating refractory greater trochanteric pain after total hip arthroplasty (Pedersen-Noor operation). *Arch Orthop Trauma Surg* 129 : 597–602, 2009.
  37. **Sayegh F, Potoupnis M, Kapetanos G.** Greater trochanter bursitis pain syndrome in females with chronic low back pain and sciatica. *Acta Orthop Belg* 70 : 423–428, 2004.
  38. **Schapira D, Nahir M, Scharf Y.** Trochanteric bursitis : a common clinical problem. *Arch Phys Med Rehabil* 67 : 815–817, 1986.
  39. **Segal NA, Felson DT, Torner JC et al.** Greater trochanteric pain syndrome : epidemiology and associated factors. *Arch Phys Med Rehabil* 88 : 988–992, 2007.
  40. **Shbeeb MI, O'Duffy JD, Michet CJ, O'Fallon WM, Matteson EL.** Evaluation of glucocorticosteroid injection for the treatment of trochanteric bursitis. *J Rheumatol* 23 : 2104–2106, 1996.
  41. **Silva F, Adams T, Feinstein J, Arroyo RA.** Trochanteric bursitis : refuting the myth of inflammation. *J Clin Rheumatol Pract Rep Rheum Musculoskelet Dis* 14 : 82–86, 2008.
  42. **Slawski DP, Howard RF.** Surgical management of refractory trochanteric bursitis. *Am J Sports Med* 25 : 86–89, 1997.
  43. **Smidt N, van der Windt DAWM, Assendelft WJJ et al.** Corticosteroid injections, physiotherapy, or a wait-and-see policy for lateral epicondylitis : a randomised controlled trial. *Lancet Lond Engl* 359 : 657–662, 2002.
  44. **Tortolani PJ, Carbone JJ, Quartararo LG.** Greater trochanteric pain syndrome in patients referred to orthopedic spine specialists. *Spine J Off J North Am Spine Soc* 2 : 251–254, 2002.
  45. **Van Hofwegen C, Baker CL, Savory CG, Baker CL.** Arthroscopic bursectomy for recalcitrant trochanteric bursitis after hip arthroplasty. *J Surg Orthop Adv* 22 : 143–147, 2013.
  46. **Voos JE, Shindle MK, Pruett A, Asnis PD, Kelly BT.** Endoscopic repair of gluteus medius tendon tears of the hip. *Am J Sports Med* 37 : 743–747, 2009.
  47. **Wiese M, Rubenthaler F, Willburger RE, Fennes S, Haaker R.** Early results of endoscopic trochanter bursectomy. *Int Orthop* 28 : 218–221, 2004.
  48. **Williams BS, Cohen SP.** Greater trochanteric pain syndrome : a review of anatomy, diagnosis and treatment. *Anesth Analg* 108 : 1662–1670, 2009.