



Outcomes of open reduction and internal fixation in displaced intra-articular scapular fractures : a case series

Marij ZAHID, Rizwan Haroon RASHID, Hina INAM, Akbar Jaleel ZUBAIRI, Naveed BALOCH, Pervaiz Mahmood HASHMI

From the Aga Khan University Hospital, Karachi, Pakistan

Scapular fractures are rare injuries and usually occur due to high energy trauma. Displaced Intra articular fractures usually require operative treatment and yields better outcomes as compared to conservative management.

To assess the functional and radiological outcomes of displaced intra-articular scapular fractures managed with open reduction and internal fixation.

12 patients were retrospectively reviewed and included in the study. Post-operative functional outcomes were assessed using mean quick DASH (Disability of arm, hand and shoulder) score while radiological outcomes were analyzed as percentage of implant cut-through, mal-union, non-union or infection.

The mean follow up was 14 months. Mean age was 40 years. The mean quick DASH score was 7.19 +/- 4.86. All of the patients had successful clinical and radiological healing and pain-free movements.

Open reduction and internal fixation in displaced intra-articular scapular-fractures yields excellent and promising outcomes.

Keywords : scapula ; spine ; follow-up studies ; fracture fixation ; intra-articular fractures ; retrospective studies.

INTRODUCTION

Scapular Fractures account for 0.4 to 1% of all fractures and 3%-5% of all fractures of shoulder girdle (1,2)). These usually occur due to high energy trauma including road traffic accidents, fall from height, crush and sports injuries. Road traffic accident so far is the most common cause in which about

50% are the occupants of the motor vehicle (1,3) and 20% are pedestrians (2). These are associated with thoracic injuries like pneumothorax (2), pulmonary contusions, arterial injuries, closed head and spine injuries (1) splenic or liver lacerations. Brachial plexus injury is associated in 5-13% of the cases and is often the most important prognostic factor (2,10).

Most extra-articular fractures of the scapula and un-displaced intra-articular fractures are managed conservatively (16,20) while operative intervention is mostly used in displaced intra-articular fractures of the scapula in order to prevent degenerative arthritis,

■ Marij Zahid, M.D.
Resident, Section of Orthopedics , Aga Khan University Hospital, Karachi.

■ Rizwan Haroon Rashid, M.D.
Instructor, Section of Orthopedics, Aga Khan University Hospital, Karachi.

■ Hina Inam, M.D.
Resident, Department of Surgery , Aga Khan University Hospital, Karachi.

■ Akbar Jaleel Zubairi, M.D.
Resident, Section of Orthopedics, Aga Khan University Hospital, Karachi.

■ Naveed Baloch, M.D.
Senior Instructor, Section of Orthopedics, Aga Khan University Hospital, Karachi.

■ Pervaiz Mahmood Hashmi, M.D.
Associate Professor, Section of Orthopedics, Aga Khan University Hospital, Karachi.

Correspondence : Dr. Marij Zahid, Resident, Section of Orthopedics, Aga Khan University Karachi. Tel : +92-332-241-8141. E-mail : marijzh@gmail.com, marij.zahid@aku.edu.

© 2017, Acta Orthopædica Belgica.

No benefits or funds were received in support of this study. The authors report no conflict of interests.

rotator cuff dysfunction and joint instability (4). Management of displaced Intra-articular scapular fractures includes open reduction and internal fixation either via a posterior approach, modified judet approach, anterior approach or minimally invasive percutaneous internal fixation (3-6).

Operative criteria still remains controversial and varies with surgeons. It includes at least one of the following: ≥ 20 mm medial/lateral (M/L) displacement (lateral border offset) of glenoid, $\geq 45^\circ$ of angular deformity on a scapular-Y radiograph, the combination of angulation $\geq 30^\circ$ plus Medial/ lateral displacement ≥ 15 mm, gleno-polar angle (GPA) $\leq 22^\circ$, double disruption of the superior shoulder suspensory complex (scapula neck, coracoid, clavicle, and acromion) greater than 10 mm and open fractures (1,7-9). Complications of the surgery include post-operative infections, hematoma, neural injury, rotator cuff dysfunction, heterotopic ossification, mal-union, non-union, fixation failure and pain. There is very little literature addressing the outcomes of scapular fractures managed with operative fixation and current study aims to address to this important but relatively uncommon problem.

MATERIALS AND METHODOLOGY

We performed a retrospective analysis of all patients admitted with displaced intra-articular scapular fracture and managed with operative intervention at Aga Khan University Hospital from 2012 to 2014. Patients with incomplete data and those lost to follow-up were excluded.

Medical record files and orthopedics database of the patients were reviewed and recorded in a structured performa which included variables like age, gender, classification of fractures according to Ideberg's classification (10), laterality of fracture, hand dominance, mode of injury, duration of hospital stay, duration from injury to surgery, surgical approach and complications. Moreover, radiological characteristics like gleno-polar angle, medio-lateral displacement, translation, angulation and glenoid versions were measured pre-operatively on 3-Dimensional reconstructive CT scan while post-operative characteristics were also recorded from the standard radiographs.

A single examiner reviewed all radiographs including 3-Dimensional reconstructive CT scans for the purpose of classification, measuring deformities and displacements. All the patients were followed for at least 6 months. Clinical outcomes were measured as quick DASH (Disability of Arm, shoulder and hand) scores of the individuals on their regular follow-ups at 6 months and mean calculated while radiological outcomes were measured as bone healing, non-union, mal-union, implant cut-through need for re-operation and post-operative

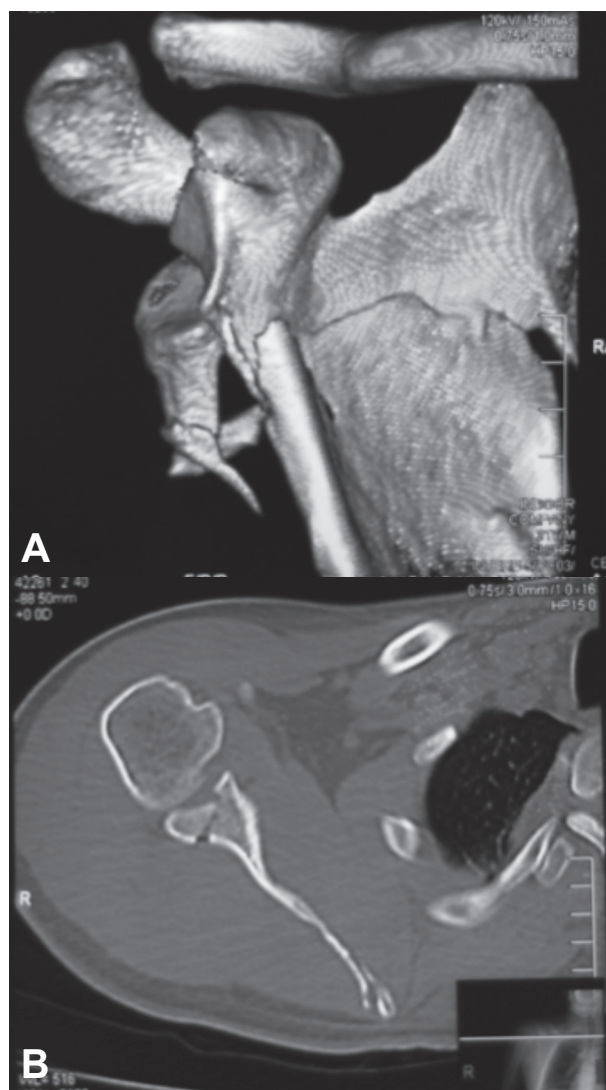


Fig. 1. — A and B: 30 year old gentleman history of RTA with right sided displaced intra-articular scapular fracture

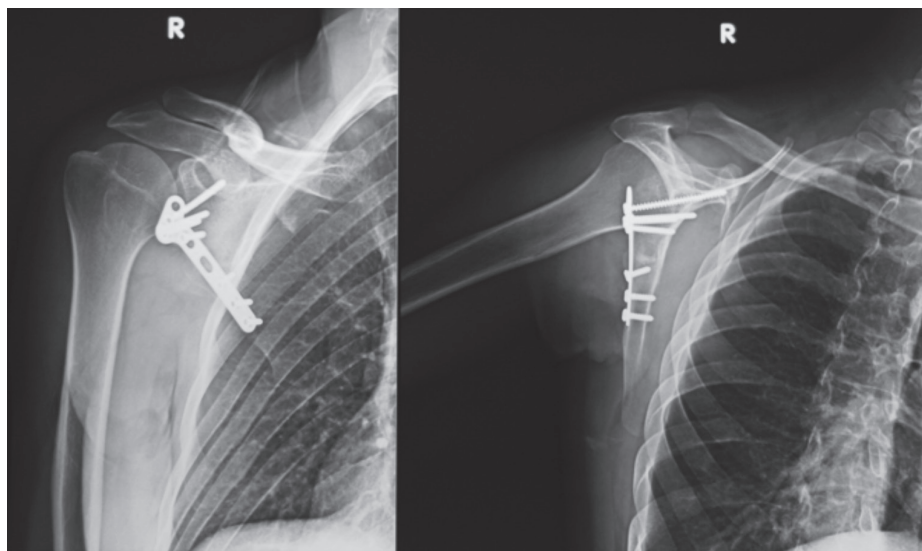


Fig. 2. — Same patient as in Fig 1. 6 months post ORIF of scapula showing good healing

radiological characteristics mentioned above. Data was analyzed using SPSS v20 and projected as mean and frequencies for the above mentioned variables.

RESULTS

A total of 12 patients with intra articular scapular fractures were included. 83.33% of the patients were male, 16.66% were female with mean age 40 years (range 17 to 63 years). 58.33% of these patients had a history of road traffic accident, 25% of fall while 16.67% patients presented with fire-arm injury (gunshot). These injuries were observed in conjunction with pneumothorax in two patients, rotator cuff tear in two and axillary nerve injury, and head injury in one patient each. 10 patients were operated using a posterior Judet approach while 2 patients were operated using an anterior approach as they had concomitant rotator cuff tears (Table I). No complications like implant cut out, mal-union, non-union, post-operative infections, per-operative nerve or vascular insult were observed in any of the patients (Table II). Mean quick DASH score was 7.19 ± 4.86 SD. All patients had a satisfactory radiological outcome with good healing (see Table II). Mean pre-operative medial/lateral displacement was 10.36mm while post operatively it was calculated as 0.86 mm. Mean pre-operative

and post-operative translations were 16.17mm and 1.35mm respectively (Table III). Summary of all patients is presented in Table IV.

DISCUSSION

Scapular Fractures are infrequent and generally occurring in high energy blunt trauma. The problem with the management of scapular fractures in general is due to the lack of an easy classification guiding the surgeons towards an evidence based treatment. Literature regarding outcome of treatment of specific fracture types is scarce comprising mostly of case reports, limited data analysis with no randomized comparative studies.

Schandelmaier P. et al (6) described a 22 cases follow up in his paper on management of scapular fractures and their indication for surgery was intra-articular displacement of more than 5 mm. They found no deterioration of the functional results with time. The results of operatively treated fractures of the glenoid were good if there was no associated complete brachial plexus palsy. With brachial plexus palsy the outcome after operative treatment was determined by the neurological recovery. We in our study recorded one case with axillary nerve neuropraxia, the patient recovered to full functional range of motion with time.

Hardegger F.H. et al (11) documented the largest series of scapular fractures which were surgically treated. Reduction and internal fixation of distinct fractures of glenoid was recommended by them. He stated that in most cases of scapula fractures, early treatment yields excellent results and that the range of motion improves over a period of time. In the

current study mean duration from injury to surgery is 4.3 days and all the patients recovered well.

Lewis S. et al (10) reported a mean DASH score of 10 (range of 0.83 to 29.17) which is comparable to our study in which the mean quick DASH score was 7.19 (range of 0 to 13.63). There are studies which compared DASH score with quick DASH score and concluded the equal efficacy of the two (12).

Jones C.B. et al (13) analyzed operative vs. non-operative treatment of displaced scapular fractures but he concluded that there was no difference in the outcomes of the two groups. More-over he implied that operative management is useful in fractures with medial/lateral displacement >20 mm.

Lantry J.M. et al (14) in a systematic review of 243 cases, pointed out that good to excellent functional outcomes were obtained in 85% of cases which mainly consisted of displaced glenoid fossa and scapular neck fractures while in our study it was calculated a 100% but with limitations of a small sample size and a single observer based study for radiographic characteristics.

Recently a new classification system was described by Lambert S, et al. (15) focusing on the lateral scapular suspension system (LSSS). Disruption of the LSSS comprises a complete spectrum of injuries ranging from the simple partial capsular sprain injury of the acromio-clavicular joint to a complex scapula-thoracic dissociation (internal disarticulation of the scapula). Many scapular fractures may have associated LSSS injuries, making it important for the surgeon to look for them in all patients with scapular fractures. This classification was not applicable in our patients as we did not detect this injury pattern in them.

Table I. — Patients' characteristics and classification

Mean Age (in years)		40+/- 8.33 SD
Gender	Male	10 (83.33%)
	Female	2 (16.67%)
Duration from injury to surgery		4.33+/-3.72 SD
Laterality of fracture	Right	4 (33.33%)
	Left	8 (66.67%)
Hand Dominance	Right	11 (91.67%)
	Left	01 (8.33%)
Ideberg's classification	Type III	5 (41.66%)
	Type IV	6 (50%)
	Type V	1 (8.33%)
Mechanism of injury	RTA	7 (58.33%)
	Fall	3 (25%)
	Firearm injury	2 (16.68%)
Associated injuries	Pneumothorax	2 (16.68%)
	Nerve/ brachial plexus Injury	1 (8.37%)
	Head injuries	1 (8.37%)
	Rotator cuff tear	2 (16.74%)
	None	6 (50.33)
Surgical approach	Posterior Judet	10 (83.33%)
	Anterior	2 (16.66%)

SD = Standard Deviation ; RTA = Road Traffic Accident

Table II. — Outcomes on follow-up

Mean Quick DASH Score	7.19 +/- 4.86 SD
Bone healing (after 6 months)	12 (100%)
Non-union	None
Mal-union	None
Need for re-operation	None
Return to work activities	12 (100%)

CONCLUSION

Open reduction and internal fixation provides excellent and promising outcomes in patients with displaced fracture of glenoid fossa. However other factors like poly-trauma or injury to brachial plexus should always be taken into consideration. Due to lack of high sample randomized studies and limited literature, a challenge remains for the future and

Table III. — Pre-operative and post-operative radiological characteristics

Radiological characteristic	Mean	
	Pre-operative	Post-operative
Medial/lateral displacement (in mm)	10.36 +/- 4.12 SD /0	0.86+/-0.76 SD /0
Angulation (in degrees)	59.10 +/- 8.51 SD	49.33 +/- 10.86 SD
Translation (in mm)	16.17 +/- 2.75 SD	1.35 +/- 0.99 SD
Gleno-polar angle (in degrees)	29.08 +/- 8.26 SD	27.57+/- 7.19 SD
Glenoid version (in degrees)	-14.88 +/- 3.67 SD	N/A

SD= Standard Deviation

Table IV. — Patient Summary

Patient Age	Gender	Ideberg Classification	Quickdash	Implant
60	F	4	4.54	One third Semi tubular plate
53	M	3	7.31	One third Semi tubular plate
48	M	4	4.30	2.7mm T plate and lag screws
43	M	4	00	2.7mm T plate and lag screws
19	M	3	13.63	One third Semi tubular plate
32	M	4	11.36	2.7mm T plate and lag screws
60	M	3	6.81	One third Semi tubular plate
26	M	4	9.36	2.7mm T plate and lag screws
64	M	3	5.91	One third Semi tubular plate
25	M	3	12.63	One third Semi tubular plate
56	F	4	3.64	One third Semi tubular plate
58	M	5	6.81	One third Semi tubular plate

impels the reviewers to conduct comparative studies on the fracture types that may benefit from surgical treatment such as intra-articular displaced glenoid and scapula neck fractures.

REFERENCES

1. **Ada JR, Miller ME.** Scapular fractures: analysis of 113 cases. *Clin Orthop.* 1991;269:174-80.
2. **Armstrong CP, Van der Spuy J.** The fractured scapula: importance and management based on a series of 62 patients. *Injury.* 1984;15:324-9.
3. **Bauer G, Fleischmann W, Dussler E.** Displaced scapular fractures: indication and long-term results of open reduction and internal fixation. *Arch Orthop Trauma Surg.* 1995;114:215-9.
4. **Cole PA, Gauger EM, Herrera DA et. al.** Radiographic follow-up of 84 operatively treated scapula neck and body fractures. *Injury.* 2012;43:327-33.
5. **Goss TP.** Scapular fractures and dislocations: diagnosis and treatment. *J Am Acad Orthop Surg.* 1995;3:22-33.
6. **Gummeson C, Ward MM, Atroshi I.** The shortened disabilities of the arm, shoulder and hand questionnaire (QuickDASH): validity and reliability based on responses within the full-length DASH. *BMC Musculoskelet Disord.* 2006;7:44.
7. **Hardegger FH, Simpson LA, Weber BG.** The operative treatment of scapular fractures. *J. Bone Joint Surg. Am.,* 1984;66:725-31.
8. **Hoffmann R, Tarhan O, Petersen P.** Schulterblattbrüche: Welche müssen wann operiert werden. *OP-Journal* 2002: 18 225-229.
9. **Ideberg R, Grevsten, Sven et. al.** Epidemiology of scapular fractures Incidence and classification of 338 fractures. *Acta Orthop Scand.* 1995;66:395-7.
10. **Imatani R.** Fractures of the scapula. *J Trauma.* 1975;15:473-8.
11. **Jones CB, Sietsema DL.** Analysis of operative versus nonoperative treatment of displaced scapular fractures. *Clin Orthop Relat Res.* 2011;469:3379-89.
12. **Labler L, Platz A, Weishaupt D et. al.** Clinical and functional results after floating shoulder injuries. *J Trauma Acute Care Surg.* 2004;57:595-602.

13. **Lantry JM, Roberts CS, Giannoudis PV.** Operative treatment of scapular fractures: a systematic review. *Injury*. 2008;39:271-83.
14. **Lewis S, Argintar E, Jahn R et. al.** Intra-articular scapular fractures: Outcomes after internal fixation. *J Orthop Surg*. 2013;10:188-92.
15. **Mayo KA, Benirschke SK, Mast JW.** Displaced Fractures of the Glenoid Fossa; Results of Open Reduction and Internal Fixation. *Clin Orthop Relat Res*. 1998;347:122-30.
16. **McGahan JP, Rab GT, Dublin A.** Fractures of the scapula. *J Trauma Acute Care Surg*. 1980;20:880-3.
17. **Nordqvist A, Petersson C.** Fracture of the Body, Neck, or Spine of the Scapula A Long-Term Follow-Up Study. *Clin Orthop Relat Res*. 1992;283:139-44.
18. **Obrebskey WT, Lyman JR.** A modified Judet approach to the scapula. *J Orthop Trauma*. 2004;18:696-9.
19. **Schandelmaier P, Blauth M, Schneider C et.al.** Fractures of the glenoid treated by operation, A 5-to 23-Year follow-up of 22 cases. *J Bone Joint Surg Br*. 2002;84:173-7.
20. **Wilber MC, Evans EB.** Fractures of the scapula. An analysis of forty cases and a review of the literature. *J Bone Joint Surg Am*. 1977;59:358-62.
21. **Zlowodzki M, Bhandari M, Zelle BA et. al.** Treatment of scapula fractures: systematic review of 520 fractures in 22 case series. *J Orthop Trauma*. 2006;20:230-3.