



## Surgical management of anterior cruciate ligament injuries in Belgium anno 2013

Hans VAN DER BRACHT, Laurent GOUBAU, Bart STUYTS, Alexander SCHEPENS, Peter VERDONK, Jan VICTOR

*From GZA Hospitals, Sint-Augustinus, Antwerpen, Belgium, for the Belgian Knee Society*

**Background :** Anatomic ACL surgery, including double bundle ACL reconstruction, has been investigated widely. The purpose of this study was to gain insight in the currently used surgical management of anterior cruciate ligament injuries amongst Belgian orthopaedic surgeons.

**Methods :** A survey consisting of epidemiological questions, ACL surgery related questions and questions concerning rehabilitation was submitted to all members of the Belgian Knee Society.

**Results :** Anatomic single bundle ACL repair with transportal femoral tunnel drilling, using an autologous hamstring graft fixed with a cortical suspension system proximal and an interference screw distal is currently the most common technique. The surgery is usually performed under general anesthesia with a one-night stay in the hospital. Postoperatively a hinge brace is mostly used.

**Conclusion :** Although much research concerning double bundle ACL surgery is performed, only few surgeons perform this technique. Most surgeons perform an anatomic single bundle repair. This is in accordance with the current knowledge regarding cost effective care. Performing this procedure in day care with the aid of loco-regional anesthesia and avoidance of a hinged brace can help to reduce the cost for the healthcare system without compromising the outcome.

**Keywords :** anterior cruciate ligament ; epidemiology ; surgery ; national health.

### INTRODUCTION

Anterior cruciate ligament (ACL) surgery is currently considered the standard treatment for the ACL deficient knee in the young and active patient (3). In 2012 around 4500 primary and revision ACL surgeries were performed in Belgium (annual incidence around 40/100.000 inhabitants). (Data obtained from the Belgian National Institute for Health and Disability Insurance (RIZIV/INAMI)). The mean direct medical cost for anterior cruciate

- 
- Hans Van der Bracht, MD, PhD Orthopaedic Surgeon.
  - Laurent Goubau, MD, Registrar Orthopaedic Surgery.  
*Dept Orthopaedic Surgery, University Hospital, Gent and GZA Sint-Augustinus, Antwerp, Belgium.*
  - Bart Stuyts, MD, Orthopaedic Surgeon.  
*Dept Orthopaedic Surgery, GZA Sint-Augustinus, Antwerp, Belgium.*
  - Alexander Schepens, MD, Orthopaedic Surgeon.  
*Dept Orthopaedic Surgery, AZ St-Lucas, Gent, Belgium.*
  - Peter Verdonk, MD, PhD, Professor Orthopaedic Surgery.  
*Dept Orthopaedic Surgery, AZ Monica, Deurne, Belgium.*
  - Jan Victor, MD, PhD, Professor Orthopaedic Surgery and head of department.  
*Dept Orthopaedic Surgery, University Hospital, Gent, Belgium.*
- Correspondence : Hans Van der Bracht, AZ St-Lucas, Groenebriel 1, 9000 Gent, Belgium.  
E-mail : info@vanderbracht.com  
© 2015, Acta Orthopædica Belgica.
-

ligament (ACL) injuries in Belgium is 1358 euros per injury (17). Despite the direct medical cost, several studies revealed that ACL reconstruction surgery is a cost effective intervention based on currently available evidence (17,20,45).

Although arthroscopic ACL reconstruction surgery has become a routine procedure, it has evolved considerably over the past 40 years (12). In the 1980s, the gold standard technique consisted of a transtibial, anteromedial bundle reconstruction. Since this reconstruction technique combines the tibial posterolateral (PL) bundle attachment with the femoral anteromedial (AM) bundle origin, it was defined as “mismatch” reconstruction (25,31,32). Even though the clinical results of conventional reconstructions were satisfactory and reliable over time, a positive “Pivot Shift” test of varying grades and proportions up to 25% persisted during clinical examination (12,57,54). Biomechanical studies confirmed the lack of rotational control of the transtibial single bundle technique, possibly also accounting for secondary meniscal or cartilaginous problems seen after ACL reconstruction surgery (11,46,50).

In the 21st century, ACL reconstruction surgery has been reconsidered with a primary focus on anatomic reconstruction (9,10,11,46). In an attempt to restore the anatomy and kinematics of the knee as closely as possible, double bundle ACL surgery has been developed (12,43,53).

A better understanding of ACL anatomy and function has also led to modifications in single bundle ACL surgery (9). In an effort to replicate the function of both the anteromedial and posterolateral bundles of the ACL with a single-bundle reconstruction, the surgical goal is to create a single tunnel positioned within the anatomic centre of the native femoral footprint. Proper positioning of the femoral tunnel during ACL reconstruction is paramount, with nonanatomic tunnel placement cited as the most common cause of clinical failure secondary to pain and persistent instability (26,29,41,50). Initially, modifications to the conventional transtibial technique such as posterolateral beveling of the tibial tunnel and using a more collinear, proximal, and medial tibial starting point have been used to obtain these goals (50). However, obtaining a more anatomic femoral tunnel position with a transtibial

tunnel technique has been at the expense of the tibial tunnel position. Recent studies revealed that besides femoral tunnel placement, tibial tunnel placement also contributes to rotational control of the knee in single bundle ACL surgery (6,10,54). A more anterior and medial situated tibial tunnel aperture results in better joint kinematics compared to a more posterior and lateral positioned aperture as performed in conventional techniques (6,10,54). The tranportal technique has been introduced (13,15,18,38,39). This technique provides the advantage of completely independent tibial and femoral tunnel placement. Compared to a transtibial approach, a tranportal technique enables the surgeon to perform a more anatomic ACL reconstruction (25).

Furthermore, recent research has re-focused on additional extra-articular procedures in order to better control rotational knee stability (14).

Due to the evolution of ACL surgery and recent insights in more anatomical procedures many different surgical options are available. It was therefore an aim of this study to investigate if recent advances in ACL reconstruction, as published in the literature, are effectively introduced in the daily practice of orthopaedic surgeons, performing ACL reconstruction surgery.

## MATERIALS AND METHODS

An online questionnaire was mailed to all 119 Belgian orthopaedic surgeons who were both member of the Belgian Association for Orthopaedic surgery and Traumatology (BVOT) and member of the Belgian Knee Society (BKS). One reminder was sent 6 weeks later. No further reminders had been sent according to the policy of the BVOT to avoid an overload of questionnaires and mailings amongst members of this scientific association.

The survey consisted of 3 parts. In the first part, epidemiological data of the participating surgeons were questioned. The second part contained 15 questions concerning the surgical technique (graft properties, tunnel positioning, anatomic references, additional procedures and fixation devices). The third part contained 5 questions concerning post-operative care and rehabilitation.

Data from the completed questionnaires were collected and analysed using Microsoft Excel (Microsoft, Redmond, WA, USA).

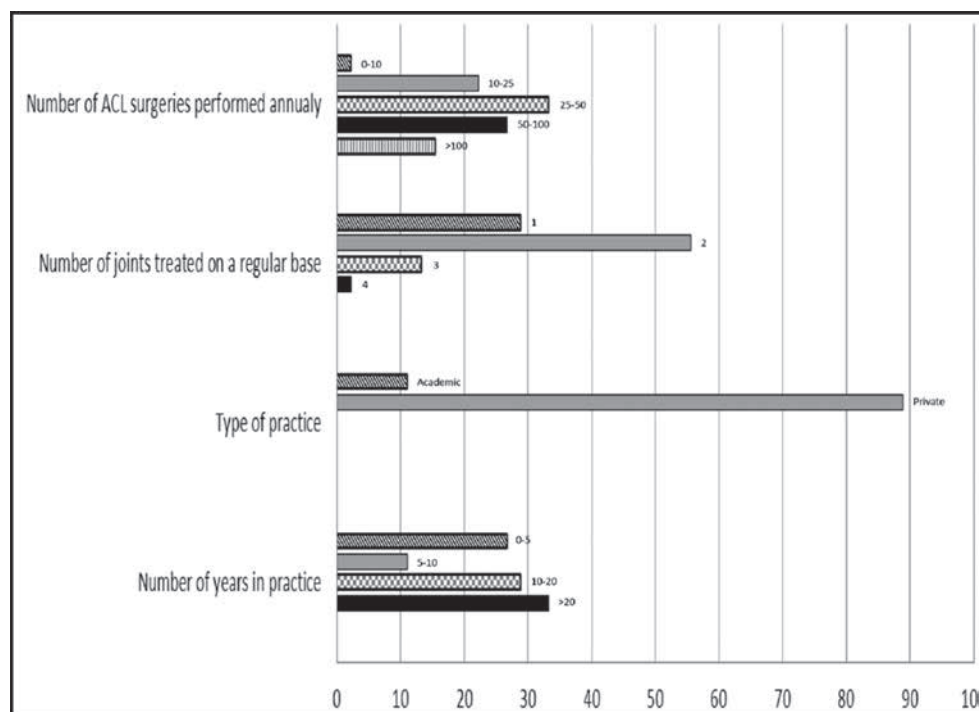


Fig. 1. — Epidemiological data of the participating surgeons represented as %

## RESULTS

### General questions


45 surgeons (38%) answered the questionnaire. All surgeons perform more than 10 ACL surgeries a year, the majority between 25 and 50 ACL reconstructions a year. 28.9% of the surgeons solely perform knee surgery whereas 55.6% of the questioned surgeon perform knee surgery combined with one other joint (28.9% shoulder, 28.9% hip, 15.6% foot and ankle, 6.7% wrist and hand injuries, 4.4% back injuries, 4.4% elbow surgery). 15.5% of the respondents combine knee surgery in daily practice with 2 or more other joint surgery. All further epidemiological data of the participating surgeons are reported in figure 1.

### Surgical technique

93.3% of the included surgeons perform an arthroscopic single bundle technique, 4.4% perform

a double bundle, single tunnel technique, and 1 surgeon performs an extra-articular procedure as a standard technique (53). The combination of an intra-articular ACL reconstruction with an extra articular augmentation is rarely used as a routine procedure but often performed in selected cases (2.2% in 50%-75%, 6.7% in 25-50%, 26.7% in less than 25%, 33.3% hardly ever and 31.1% never). 93.3% of the surgeons use an autologous ipsilateral tendon graft, whereas 6.7% of the surgeons use an allograft. Of those surgeons who use an autologous tendon graft a doubled gracilis and semitendinosus is being used by 68.3%, quadrupled semitendinosus by 21.4%, tripled semitendinosus in 7.1%, tripled gracilis and ST in 2.4% and patella tendon in 2.4%.

A transportal technique for femoral tunnel drilling is performed by 57.8% of the surgeons. 71.1% measure the intra-articular femoral entry point with the aid of an offset guide or positions the femoral tunnel aperture in the centre of the native ACL footprint. The minority uses other techniques such as fluoroscopy or place the femoral tunnel just in line



**Fig. 2.** — Differences in surgical technique used for tibial tunnel drilling in ACL surgery (DGA = drill-guide, IAA = intra-articular aperture, MCL = medial collateral ligament).

with the tibial tunnel. For femoral fixation, a cortical suspension device was used by 91.1% and transfixing pins by 8.9%.

Results of the survey concerning tibial tunnel positioning and orientation are reported in figure 2. For the primary tibial fixation of the graft, an interference screw is used most often (91.1%). Other techniques include a transfixing pin : 6.7%, or a cortical suspension system : 2.2%). A backup fixation method is used by 64.4% of the surgeons (Screw : 24.1% and Staple : 75.9%).

87.8% of the orthopedic surgeons perform ACL surgery under general anesthesia and 12.2% under loco-regional anesthesia. 80% of the surgeons perform ACL surgery with a one-night stay in the hospital. The surgery is done in an outpatient clinic in 13.3%. 6.7% of the surgeons keep the patient in the hospital for 2 nights. 57.8% of surgeons use oral painkillers to alleviate pain symptoms after ACL surgery whereas 53.3% use an intravenous painkiller, 26.7% perform a femoral block, 22.2% use intra-articular painkillers and 11.1% use peri-articular injections.

### Postoperative care and rehabilitation

70.7% of the surgeons use a hinged brace in their postoperative rehabilitation protocol whereas 29.3% use no bracing. Full weight bearing (FWB) is immediately allowed after the operation in 53.3%, after 1 week in 4.4%, after 2 weeks in 26.7%, and after 4 weeks in 13.3%.

### DISCUSSION

Although a lot of research concerning double bundle ACL surgery has been conducted, only few surgeons use this technique in daily practice. Most Belgian surgeons perform an anatomic single bundle ACL reconstruction surgery routinely. Hereby, transportal femoral tunnel drilling, followed by fixation of an autologous hamstring graft with a cortical suspension system proximally and an interference screw and staple distally is used. Furthermore, a reasonable number of surgeons occasionally perform an extra-articular procedure to enhance rotational stability of the knee.

## General questions

The majority of the questioned Belgian surgeons, member of the BKS and BVOT, perform knee surgery in combination with one other joint, treating 25-50 ACL surgeries per year in a private practice. A similar number of ACL surgeries performed annually by a single surgeon are seen in similar other studies (30,44). A big difference between this study and similar other studies is the fact that the majority of surgeons is working in a non-academic hospital. Furthermore no information concerning sub-specialization could be found in other studies.

## Surgical technique

Double-bundle ACL surgery was introduced to reproduce the anatomy and biomechanics of the native ACL as closely as possible. The superiority of double bundle over single bundle ACL surgery has been proven biomechanically and clinically (4,7,43). Although much research concerning double bundle ACL surgery has been performed, most surgeons in this study perform a single bundle technique. This could possibly be explained by the fact that the majority of participating surgeons in this study is working in a non-academic setting. Research and the development of new techniques are mainly initiated in university hospitals. Furthermore, it is unclear if double bundle ACL surgery is still not introduced in Belgium or if many surgeons have abandoned a double bundle technique already.

However, the majority of Belgian knee surgeons routinely perform an anatomic single bundle procedure with independent tunnel placement, using a transportal technique. This technique allows for an anatomic femoral and tibial tunnel positioning (7). Recent studies have revealed that not only anatomic femoral tunnel positioning is of importance, but optimal tibial tunnel positioning is a key to better biomechanical outcome. Therefore, it has been proposed to position the tibial tunnel aperture more anteriorly compared to the classic postero-medial position. The use of a transportal technique for femoral tunnel drilling will however also induce some key concerns such as a shorter femoral tunnel length, a bigger chance to injury the cartilage of the

medial femoral condyle and a higher re-rupture rate (5,19,22).

Recent studies showed that a double-bundle anterior cruciate ligament reconstruction does not appear to be cost-effective at this time compared to single bundle techniques (11,45).

Therefore, the common practice in Belgium to treat ACL ruptures is in accordance with the current knowledge concerning a cost-effective treatment. Furthermore, a long and difficult learning curve has been attributed to double bundle ACL surgery with a double possibility of committing an error (12).

Most of the questioned surgeons position the femoral tunnel aperture with the aid of an offset guide or central in the native footprint remnant. This technique has also been confirmed, as a routine procedure, by other studies (35,42). For tibial tunnel drilling, the majority of the questioned surgeons position the tip of the drill-guide based on a measurement in reference to the anterior border of the forehorn of the lateral meniscus, the anterior border of the tibial ACL footprint or the anterior border of the PCL. The position of the cortical entry point on the tibia is for most surgeons a standard spot, referenced to the tibial tubercle or the MCL. Only few surgeons will change the tibial cortical entry point depending on the geometry of the native ACL. The cortical position of the tibial tunnel will however determine the transverse angle of the tibial tunnel and will therefore determine the longest axis of the tibial tunnel aperture (51). By changing the transverse angle one can change the orientation of the tibial tunnel aperture and therefore position the tibial tunnel aperture according to the orientation of the footprint. The drill-guide angle (DGA) for the tibial tunnel routinely used ranges from 45° to 55° and most of the surgeons drill the tibial tunnel with a DGA of 50°. The DGA is inversely related to the size of the tibial tunnel aperture (51). By using a DGA of 45° or more the risk for femoral notch impingement is reduced, the risk for overhang of the tibial tunnel aperture over the borders of the native ACL is reduced (51). Therefore a DGA between 45° and 55° is seen as an appropriate DGA according to current knowledge.

Nearly all questioned surgeons use autologous ipsilateral hamstring tendon grafts. Similar results

are seen in Sweden (2). In the UK, Canada and the USA, where the majority of the surgeons preferred to use a bone-patellar tendon-bone (BPTB) autograft. Recent surveys show a shift towards the use of autologous hamstring grafts (30,35,42,44). Both graft types have advantages and disadvantages. The use of a BPTB graft has the advantage of direct bone-to-bone contact allowing for faster in-growth (56). Hamstring autografts on the other hand tend to induce less anterior knee pain, extension deficit and progression to osteoarthritis, compared to BPTB ACL reconstructions (16,21,24). In terms of knee function scores, instrumented laxity testing and evolution towards osteoarthritis no evidence exists to prove superiority of one of the techniques (1,8,23,28,47,48). However, the use of autologous hamstrings tendons seems to be the most cost-effective graft option.

Although an extra-articular augmentation procedure is rarely performed on a routine basis, 67% of Belgian knee surgeons perform this procedure in selected patients. This is a huge difference compared to other similar studies where extra-articular augmentation procedures are rarely performed. In the late 1960's and early 1970's the anterolateral tenodesis was introduced (12,36). This technique gained however no favor because peripheral reconstructions did not afford long-term stability of the knee (12). Afterwards attention was given to direct intra-articular ACL reconstruction surgery. The use of extra-articular procedures was however never completely abandoned in Belgium (52). In high demand athletes, intra-articular and extra-articular procedures were often combined. Recently research has focused on the clinical importance of extra-articular procedure on the anterior lateral side of the knee to better rotationally control knee stability (14).

For ACL graft fixation on the femoral side 91.1% of the participating orthopedic surgeons use a cortical suspension system. It is known that cortical suspension systems cause a so-called windshield wiper effect resulting in more tunnel widening (34). However, no significant correlation between tunnel widening and clinical outcome is seen (4). For tibial fixation of the graft an interference screw is mostly used (91.1%). An adjuvant staple is used by 46.7%. Several studies confirm the advantage of a backup

fixation system resulting in less laxity but at the cost of more kneeling pain (27,55).

The majority of the Belgian orthopedic surgeons perform ACL surgery under general anesthesia, which requires a one-night stay in the hospital. It is however shown that ACL reconstruction can be successfully performed in day care using loco-regional anesthesia, with high patient satisfaction levels and low readmission or complication rate (49).

The majority of surgeons prescribe oral painkillers or intravenous painkillers in the postoperative period. Only a minority of the surgeons use femoral nerve blocks (FNB), intra articular painkiller injection and periarticular multimodal drug injection. Concerning FNB and intra-articular painkiller injections there appears to be no evidence of additional benefit over periarticular multimodal drug injection (33). Furthermore, there is a small but identifiable risk associated with performing FNBs, with potentially catastrophic effects (40).

### Postoperative care and rehabilitation

Most of the surgeons (69%) use a hinged brace in their postoperative rehabilitation protocol. A review of systematic reviews reports strong evidence of no added benefit of bracing after ACL reconstruction (0-6 weeks post-surgery) as an adjunct to standard treatment in the short term. Therefore its use is not recommended (37).

### Limitations

This study has several weaknesses. First, the percentage of participating surgeons was rather low despite two subsequent mailings. No further questioning was allowed according to the policy of the BVOT concerning mailings to their members.

Second, only members of the BKS were involved in this study. Therefore the results of this study may not reflect the approach to the surgical treatment of anterior cruciate deficient knees amongst all Belgian orthopaedic surgeons but only to those who are a member of the Belgian Knee Society. Seen the number of BKS members compared to the number of BVOT members, presumably most surgeons who

perform knee surgery in Belgium are a member of the BKS.

Third, in the effect of age, gender, activity level of the patient or the difference between acute or chronic ACL tears was not investigated.

## CONCLUSION

In general anatomic single bundle ACL reconstruction surgery using autologous hamstring grafts appears to be the gold standard amongst Belgian orthopedic surgeons anno 2013. This is in accordance with current knowledge for cost effective care. The procedure is however mainly performed under general anesthesia with a one-night stay in the hospital. Furthermore a hinged brace is usually prescribed in the post-operative period. Performing ACL reconstruction surgery in day care with the aid of loco-regional anesthesia and avoidance of a hinged brace may help to reduce the cost for the healthcare system without compromising the outcome.

## REFERENCES

1. Ahlden M, Kartus J, Ejerhed L *et al.* Knee laxity measurements after anterior cruciate ligament reconstruction, using either bone patellar tendon bone or hamstring autografts, with special emphasis on comparison over time. *Knee Surg Sports Traumatol Arthrosc* 2009 ; 17 : 1117-1124.
2. Ahldén M, Samuelsson K, Sernert N *et al.* The Swedish National Anterior Cruciate Ligament Register A Report on Baseline Variables and Outcomes of Surgery for Almost 18,000 Patients. *The American Journal of Sports Medicine* 2012 ; 40 : 2230-2235.
3. Altmann D. Standards in operative treatment of acute trauma of the cruciate ligaments. *Trauma und Berufskrankheit* 2006 ; 8 (2) : 150-154.
4. Andersson D, Samuelsson K, Karlsson J. Treatment of anterior cruciate ligament injuries with special reference to surgical technique and rehabilitation : an assessment of randomized controlled trials. *Arthroscopy* 2009 ; 25 : 653-658.
5. Basdekis G, Abisafi C, Christel P. Influence of Knee flexion angle on femoral tunnel characteristics when drilled through the anteromedial portal during Anterior Cruciate Ligament Reconstruction. *Arthroscopy* 2008 ; 24 : 459-464.
6. Bedi A, Maak T, Musahl V *et al.* Effect of tibial tunnel position on stability of the knee after anterior cruciate ligament reconstruction : is the tibial tunnel position most important ? *Am J Sports Med* 2011 ; 39 (2) : 366-373.
7. Bedi A, Musahl V, Steuber V *et al.* Transtibial versus Anteromedial Portal reaming in Anterior Cruciate Ligament Reconstruction : An anatomic and Biomechanical Evaluation of Surgical Technique. *Arthroscopy* 2011 ; 27 : 380-390.
8. Biau DJ, Katsahian S, Kartus J *et al.* Patellar Tendon Versus Hamstring Tendon Autografts for Reconstructing the Anterior Cruciate Ligament : A Meta-Analysis Based on Individual Patient Data. *Am J Sports Med* 2009 ; 37 : 2470-2477.
9. Bird JH, Carmont MR, Dhillon M *et al.* Validation of a new technique to determine midbundle femoral tunnel position in anterior cruciate ligament reconstruction using 3-dimensional computed tomography analysis. *Arthroscopy* 2011 ; 27 : 1259-1267.
10. Brophy RH, Pearle AD. Single-bundle anterior cruciate ligament reconstruction : a comparison of conventional, central, and horizontal single-bundle virtual graft positions. *Am J Sports Med* 2009 ; 37 (7) : 1317-1323.
11. Brophy RH, Wright RW, Matava MJ. Cost analysis of converting from single-bundle to double-bundle anterior cruciate ligament reconstruction. *Am J Sports Med* 2009 ; 37 (4) : 683-7.
12. Chambat P, Guier C, Sonnery-Cottet B *et al.* The evolution of ACL reconstruction over the last fifty years. *Int Orthop* 2013 ; 37(2) : 181-6.
13. Chhabra A, Kline AJ, Nilles KM *et al.* Tunnel expansion after anterior cruciate ligament reconstruction with autogenous hamstrings : a comparison of the medial portal and transtibial techniques. *Arthroscopy* 2006 ; 22 : 1107-1112.
14. Claes S, Vereecke E, Maes M *et al.* Anatomy of the anterolateral ligament of the knee. *Journal of anatomy* 2013 ; 223(4) : 321-328.
15. Colvin AC, Shen W, Musahl V *et al.* Avoiding pitfalls in anatomic ACL reconstruction. *Knee Surg Sports Traumatol Arthrosc* 2009 ; 17 : 956-963.
16. Cooper DE, Deng XE, Burstein AL *et al.* The strength of the central third patellar tendon graft. *Am J Sports Med* 1993 ; 21 : 818-823.
17. Cumps E, Verhagen E, Annemans L *et al.* Injury rate and socioeconomic costs resulting from sports injuries in Flanders : data derived from sports insurance statistics 2003. *Br J Sports Med* 2008 ; 42(9) : 767-72.
18. Dargel J, Schmidt-Wiethoff R, Fischer S *et al.* Femoral bone tunnel placement using the transtibial tunnel or the anteromedial portal in ACL reconstruction : a radiographic evaluation. *Knee Surg Sports Traumatol* 2009.
19. Farrow LD, Parker RD. The relationship of lateral anatomic structures to exiting guide pins during femoral tunnel preparation utilizing an accessory medial portal. *Knee Surg Sports Traumatol Arthrosc* 2010 ; 18 : 747-753.
20. Farshad M, Gerber C, Meyer DC, *et al.* Reconstruction versus conservative treatment after rupture of the anterior

- cruciate ligament : cost effectiveness analysis. *BMC Health Serv Res* 2011 ; 11 : 317.
21. **Fiedeler BM, Vangsness CT, Bin LU et al.** Gamma irradiation : effect on biomechanical properties of human bone patellar tendon bone allografts. *Am J Sports Med* 1995 ; 23 : 63-66.
  22. **Hall MP, Ryzewicz M, Walsh PJ et al.** Risk of iatrogenic injury to the Peroneal Nerve during Posterolateral Femoral tunnel Placement in Double bundle Anterior Cruciate Ligament reconstruction. *Am J Sports Med* 2009 ; 37 : 109-113.
  23. **Harilainen A, Linko E, Sandelin J.** Randomised prospective study of ACL reconstruction with interference screw fixation in patellar tendon autografts versus femoral metal plate suspension and tibial post fixation in hamstring tendon autografts : 5-year clinical and radiological followup results. *Knee Surg Sports Traumatol Arthrosc* 2006 ; 14 : 517-528.
  24. **Haut-Donahue TL, Howell SM, Hull ML et al.** A biomechanical evaluation of anterior and posterior tibialis tendons as suitable single loop anterior cruciate ligament grafts. *Arthroscopy* 2002 ; 18 : 589-597.
  25. **Herbert M, Lenschow S, Fu FH et al.** ACL mismatch reconstructions : influence of different tunnel placement strategies in single-bundle ACL reconstructions on the knee kinematics. *Knee Surg Sports Traumatol Arthrosc* 2010 ; 18 (11) : 1551-8.
  26. **Hettrich CM1, Dunn WR, Reinke EK et al.** The rate of subsequent surgery and predictors after anterior cruciate ligament reconstruction : two- and 6-year follow-up results from a multicentre cohort. *Am J Sports Med.* 2013 ; 41 (7) : 1534-40.
  27. **Hill PF, Russell VJ, Salmon LJ et al.** The influence of supplementary tibial fixation on laxity measurements after anterior cruciate ligament reconstruction with hamstring tendons in female patients. *Am J Sports Med* 2005 ; 33 : 94-101.
  28. **Holm I, Oiestad BE, Risberg MA et al.** No difference in Knee Function or Prevalence of Osteoarthritis after reconstruction of the Anterior Cruciate Ligament with 4-strand Hamstring Autograft versus Patellar Tendon-Bone Autograft : A randomised study with 10-year follow-up. *Am J Sports Med* 2010 ; 38 : 448-454.
  29. **Hosseini A, Lodhia P, Van de Velde SK et al.** Tunnel position and graft orientation in failed anterior cruciate ligament reconstruction : a clinical and imaging analysis. *Int Orthop* 2012 ; 36(4) : 845-52.
  30. **Kapoor B, Clement DJ, Kirkley A et al.** Current practice in the management of anterior cruciate ligament injuries in the United Kingdom. *Br J Sports Med* 2004 ; 38 : 542-544.
  31. **Kato Y, Ingham SJ, Kramer S et al.** Effect of tunnel position for anatomic single-bundle ACL reconstruction on knee biomechanics in a porcine model. *Knee Surg Sports Traumatol Arthrosc* 2010 ; 18 : 2-10.
  32. **Kocher MS, Steadman JR, Briggs KK et al.** Relationships between objective assessment of ligament stability and subjective assessment of symptoms and function after anterior cruciate ligament reconstruction. *Am J Sports Med* 2004 ; 32 : 629-634.
  33. **Koh IJ, Chang CB, Seo ES et al.** Pain management by periarticular multimodal drug injection after anterior cruciate ligament reconstruction : a randomized, controlled study. *Arthroscopy* 2012 ; 28 (5) : 649-57.
  34. **Kuskucu SM.** Comparison of short-term results of bone tunnel enlargement between EndoButton CL and cross-pin fixation systems after chronic anterior cruciate ligament reconstruction with autologous quadrupled hamstring tendons. *J Intern Med Res* 2008 ; 36 : 23-30.
  35. **Lee YHD, Kuroda R, Zhao J et al.** A tale of 10 european centres - 2010 APOSSM travelling fellowship review in ACL surgery. *Sports Medicine, Arthroscopy, Rehabilitation, Therapy & Technology* 2012 ; 4 : 27.
  36. **Lemaire M.** Résultats de la plastie extra-articulaire palliative de la rupture du ligament croisé antérieur. *Rev Chir Orthop* 1983 ; 69 : 278-282.
  37. **Lobb R, Tumilty S, Claydon L.** A review of systematic reviews on cruciate ligament reconstruction rehabilitation. *Physical therapy in sports* 2012 ; 13 : 270-278.
  38. **Lubowitz J, Konicek J.** Anterior Cruciate Ligament Femoral Tunnel Length : Cadaveric Analysis Comparing Anteromedial Portal Versus Outside – In Technique. *Arthroscopy* 2010 ; 26 : 1357-1362.
  39. **Lubowitz J.** Anteromedial portal technique for Anterior Cruciate Ligament Femoral Socket : Pitfalls and Solutions. *Arthroscopy* 2009 ; 25 : 95-101.
  40. **Mall NA, Wright RW.** Femoral nerve block use in anterior cruciate ligament reconstruction surgery. *Arthroscopy* 2010 ; 26 : 404-416.
  41. **Marchant BG, Noyes FR, Barber-Westin SD et al.** Prevalence of nonanatomical graft placement in a series of failed anterior cruciate ligament reconstructions. *Am J Sports Med* 2010 ; 38 (10) : 1987-96.
  42. **McRae SM1, Chahal J, Leiter JR et al.** Survey study of members of the Canadian Orthopaedic Association on the natural history and treatment of anterior cruciate ligament injury. *Clin J Sport Med* 2011 ; 21 (3) : 249-58.
  43. **Meredick RB, Vance KJ, Appleby D et al.** Outcome of single-bundle versus double -bundle reconstruction of the anterior cruciate ligament. A Meta-Analysis. *Am J Sports Med* 2008 ; 36 : 1414-1421.
  44. **Mirza F, Mai DD, Kirkley A et al.** Management of injuries to the anterior cruciate ligament : results of a survey of orthopaedic surgeons in Canada. *Clinical Journal Of Sport Medicine* 2000 ; 10 : 85-88
  45. **Paxton ES, Kymes SM, Brophy RH.** Cost-effectiveness of anterior cruciate ligament reconstruction : a preliminary comparison of single-bundle and double-bundle techniques. *Am J Sports Med.* 2010 ; 38 (12) : 2417-25.
  46. **Pearle AD, Shannon FJ, Granchi C et al.** Comparison of 3-dimensional obliquity and anisometric characteristics of anterior cruciate ligament graft positions using surgical navigation. *Am J Sports Med.* 2008 ; 36 (8) : 1534-41.



47. Pearsall AW, Hollis JM, Russel GV *et al.* A biomechanical evaluation comparison of three lower extremity tendons for ligamentous reconstruction about the knee. *Arthroscopy* 2003 ; 19 : 1091-1096.
48. Samuelsson K, Andersson D, Karlson J. Treatment of Anterior Cruciate Ligament Injuries with Special Reference to Graft Type and Surgical Technique. *Arthroscopy* 2009 ; 10 : 1139-1174.
49. Shaw AD, DiBartolo G, Clathworthy M. Daystay hamstring acl reconstruction performed under regional anesthesia. *The knee* 2005 ; 12 : 271-273.
50. Strauss EJ, Barker JU, McGill K *et al.* Can anatomic femoral tunnel placement be achieved using a transtibial technique for hamstring anterior cruciate ligament reconstruction ? *Am J Sports Med* 2011 ; 39(6) : 1263-9.
51. Van der Bracht H, Bellemans J, Victor J *et al.* Can a tibial tunnel in ACL surgery be placed anatomically without impinging on the femoral notch ? A risk factor analysis. *Knee Surg Sports Traumatol Arthrosc* 2014 ; 22 (2) : 291-7.
52. Van Tornhout B, Martens M. Anterolateral instability of the knee. Results with a modified MacIntosh tendoplasty. *Acta Orthop Belg* 1982 ; 48 (3) : 468-72.
53. Verhelst L, Van Der Bracht H, Oosterlinck D *et al.* ACL repair with a single or double tunnel : a comparative laboratory study of knee stability using computer navigation. *Acta Orthop Belg* 2012 ; 78 : 771-778.
54. Voos JE, Musahl V, Maak TG *et al.* Comparison of tunnel positions in single-bundle anterior cruciate ligament reconstructions using computer navigation. *Knee Surg Sports Traumatol Arthrosc* 2010 ; 18(9) : 1282-9.
55. Walsh MP, Wijdicks CA, Parker JB *et al.* A comparison between retrointerference screw, suture button and combined fixation on tibial side of an all-inside anterior cruciate ligament reconstruction. A Biomechanical study in a porcine model. *Am J Sports Med* 2009 ; 37 : 160-167.
56. Woo SL, Hollis JM, Adam DJ *et al.* Tensile properties of human femur-anterior cruciate ligament tibia complex. The effect of specimen age and orientation. *Am J Sports Med* 1991 ; 19 : 217-225.
57. Zantop T, Kubo S, Petersen W *et al.* Current techniques in anatomic anterior cruciate ligament reconstruction. *Arthroscopy* 2007 ; 23(9) : 938-947.