



Clinical results following meniscal sutures : does concomitant ACL repair make a difference ?

Ana M^a MARTIN-FUENTES, Cristina OJEDA-THIES, Jesus VILA-RICO

From Dept. of Orthopaedic Surgery and Traumatology, University Hospital "Doce de Octubre", Madrid, Spain

Introduction : The purpose of this study is to analyze the clinical results of meniscal tears repaired with an all-inside suture with special attention to the results in stable versus anterior cruciate ligament (ACL)-deficient knees.

Methods : We studied 45 meniscal tears (32 medial, 13 lateral) repaired in 43 patients using a single all-inside suture system. The patients were divided in two groups and followed-up for at least 12 months. Group A (stable knees with isolated meniscal tears) consisted of 19 patients treated with all-inside sutures. Group B (ACL-deficient knees with meniscal tears) consisted of 24 patients treated with ACL reconstruction together with the meniscal repair. All the meniscal tears were located in red/red (35) or red/white (10) zone. Criteria for clinical success included absence of joint-line tenderness, locking, swelling, and a negative McMurray test. Preoperative and postoperative clinical evaluation also included the Tegner and Lysholm knee scores.

Results : The clinical success rate of the repairs was 86%. According to our criteria, six of 43 repaired menisci (14%) were considered failures. Mean Lysholm scores improved significantly in both groups (58 to 88.20) and the improvement was significantly greater in group B (From 54.47 to 88, $p < 0.05$). Twenty patients (83.3%) had an excellent or good result in group B and sixteen (84%) in group A, according to the Lysholm knee score.

Conclusions : Our clinical results show that arthroscopic meniscal repair with all-inside devices provided a high rate of meniscus healing and seem to be safe and effective, for isolated meniscal tears as well as for

ACL-deficient knees with meniscal tears. Final functional scores were similar for ACL-competent and ACL-deficient knees.

Keywords : meniscal tear ; all-inside suture ; ACL rupture.

INTRODUCTION

Since the importance of the meniscus has been better understood, attention towards the preservation of this structure has increased. Significant increases in contact pressure have been found after even partial meniscectomy (8,35). Furthermore, the meniscus is believed to contribute to joint stability. It has been found that medial meniscectomy in the presence of an ACL-deficient knee significantly increases anterior translation of the tibia (9,11). The meniscus also provides shock absorption (18).

- Ana M^a Martin-Fuentes, MD, Registrar.
- Cristina Ojeda-Thies, MD, FEBOT, Consultant Surgeon.
- Jesus Vila-Rico, MD, PhD, Consultant Surgeon.

Dept. of Orthopaedic Surgery and Traumatology, University Hospital "Doce de Octubre" - Avda. De Córdoba s/n, Madrid, 28041 Spain.

Correspondence : Ana M^a Martín-Fuentes, Dept. of Orthopaedic Surgery and Traumatology, University Hospital "Doce de Octubre", Avda. De Córdoba s/n, Madrid, 28041 Spain.

E-mail : ana_martinfu@hotmail.com

© 2015, Acta Orthopædica Belgica.

Trauma is a common cause of meniscal tears. For example, meniscus tears occur in 40% to 60% of patients with anterior cruciate ligament (ACL) ruptures (23,29). Meniscal repair is indicated for patients following traumatic rupture. Most of these tears extend into the middle third of the meniscus, provided with vascularity (red-red and red-white zones), so repair is possible in most cases, with high success rates (6). Several authors have observed that repair performed together with ACL reconstruction seems to show a better healing percentage than an isolated suture (10,25), perhaps because of the hemorrhage generated during the ACL reconstruction, rich in pluripotent stem cells, platelets and growth factors (36,42).

Therefore, the best candidate for meniscal repair is the young compliant patient with at least 1 cm long peripheral longitudinal single meniscal tear. A meniscal repair, rather than a partial meniscectomy, should always be considered in the young athlete to protect his articular cartilage (13).

Among the 3 arthroscopic repair techniques known today (inside-out, outside-in, and all-inside), all-inside hybrid fixation has become increasingly popular because of its fast application and reduction of the risk of serious neurovascular complications (2,16,37). However, several reports have mentioned complications that are directly associated with these devices such as chondral injuries and synovitis (4,12,13). Another concern is the inferior strength of these devices compared with vertical sutures, which may be a critical factor that contributes to meniscal healing according to some previous biomechanical studies (5,7,26).

The purpose of this study was to evaluate the mid-term outcome in patients who had undergone all-inside suture repair of medial or lateral meniscal tears, alone or in combination with anterior cruciate ligament (ACL) reconstruction.

METHODS

From August 2008 to July 2012, 45 arthroscopic meniscal repairs (32 medial, 13 lateral) in 43 consecutive patients were performed in our hospital by three surgeons. All meniscal tears were sutured with the FasT-Fix (Smith & Nephew, Andover, Massachusetts, USA), an all-inside hybrid meniscal suture system (33).

Thirty three males (77%) and 10 females (23%), with an average age of 31 years (range 17-47 years) at the time of surgery were included in the study. All patients were clinically evaluated preoperatively and postoperatively, and all underwent an imaging protocol study that included X-rays (antero-posterior, lateral) and Magnetic resonance imaging (MRI) of the knee. Patients were included in this study if they presented (1) a vertical full-thickness tear longer than 1 cm in length, (2) location of the meniscal tear less than 6 mm from the menisco-capsular junction (red/red or red/white zone) (24), (3) fixation of the meniscus solely with the FasT-Fix system, and (4) at least follow-up of one year. Patients who had had a combined repair or patients with knee injuries other than meniscal tears or ACL ruptures were excluded.

The anterior cruciate ligament (ACL) was reconstructed in the 24 ACL-deficient knees using three types of techniques : hamstring autograft (8 cases), patellar bone-tendon-bone graft (8) and allograft from a cadaver (3). Reconstruction was performed simultaneously with the meniscal repair, with the technique depending on surgeon preference. Seven patients of the ACL-deficient knees were found to have concomitant chondral injuries (6 on the medial condyle and 1 on the lateral condyle), averaging a surface area of 1 cm². None of the ACL-stable knees were found to have chondral injuries.

Surgical technique

All patients were operated under intradural anesthesia. The tear length and the rim width were recorded at the time of surgery, as well as the morphology of the meniscus tear. Dislocated bucket-handle tears were reduced before beginning the suture. The tear edges were freshened with a meniscus rasp and shaver. Using microfracture awls, multiple perforations were made in the meniscal rim to produce vascular access channels and encourage bleeding in order to stimulate the healing response. In the majority of cases, in medial as well as lateral tears, the menisci were approached with the FasT-Fix device inserted through the contralateral portal. Occasionally, the most posterior horn of the medial meniscus was more accessible via the ipsilateral portal. The two T-Fix bars were then inserted across the meniscal tear in vertical, horizontal, or oblique patterns, depending on the anatomy of the tear (Fig. 1). For a horizontal suture, the delivery needle was transferred 5 mm sideways ; while for a vertical suture, it was placed perpendicular to the tear in order to ensure maximum tension. Upon insertion of the second implant, the device was removed from the joint.

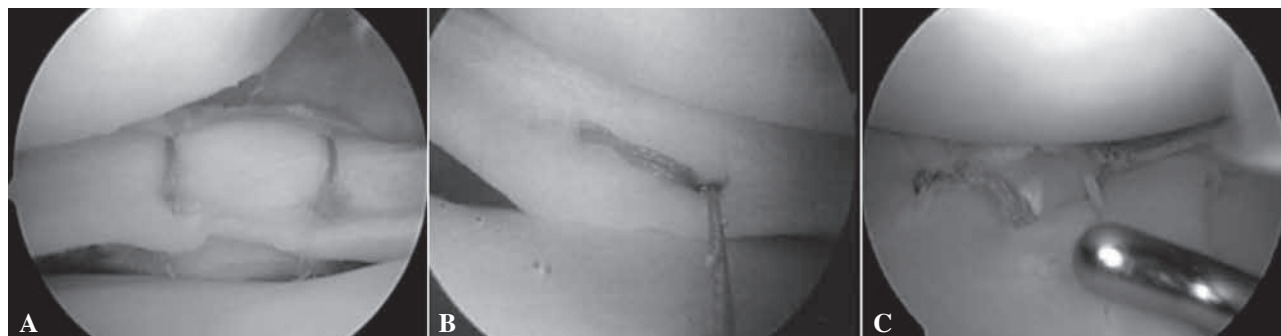

Fig. 1. — Intraoperative arthroscopic views. (A) Vertical mattress suture configuration. (B) Horizontal mattress suture configuration. (C) Vertical and oblique mattress suture configuration.

If the patient had a concomitant ACL injury, arthroscopic reconstruction was conducted immediately after the meniscal repair.

Rehabilitation

Postoperative care consisted of non-weight bearing motion with a hinged postoperative brace. The range of motion was limited to 90° of flexion. Weight bearing and range of motion limitations were maintained for 4 weeks postoperatively, and progressed to full weight bearing by postoperative week 6. Running, swimming, and cycling were initiated at 3 months. Unrestricted activity was permitted at 6 months for patients with isolated meniscal repair and at 9 months for patients with meniscal repair and concomitant ACL reconstruction.

Clinical evaluation

The patients were divided into two groups. Group A included 19 patients with stable knees and isolated meniscal tears (12 medial, 8 lateral), whereas Group B comprised 24 patients with meniscal tears (20 medial, 5 lateral) in ACL-deficient knees. The mean follow-up period was 30.6 months for group A (range, 12 to 60 months) and 38.26 months for group B (range, 12 to 60 months). No patients were lost to follow-up in this series. Patient characteristics and data regarding the type and repair of meniscal injuries are summarized in Table I.

Patients were evaluated by the corresponding author, who did not perform the surgeries. We used the Lysholm (24) knee score and Tegner (39) activity score to evaluate knee function, as well as subjective parameters, which included effusion, range of motion, ligamentous stability (in cases of ACL reconstruction), evaluation for joint line tenderness, blocking and McMurray's test. If a

second-look arthroscopy was necessary, the condition of the meniscus was evaluated with MRI before the revision surgery.

Clinical results were considered a failure if the patients had symptoms such as swelling, joint line tenderness, locking, or blocking; positive McMurray's test (according to the criteria of Barrett *et al* (10)); a subjective Lysholm score of less than 84; or needed repeat surgery for partial meniscectomy. If one or more of these parameters were present, we considered clinical success had not been achieved.

Statistical analysis

For comparison of the preoperative and postoperative Lysholm and Tegner scores between the two groups of patients, we used the Chi-square test. In an effort to identify factors that might affect the results of meniscal repairs, we compared patients with clinically healed menisci with the patients with clinically failed repairs in both groups. Parameters that were examined for their influence on the clinical result were age, chronicity of tear (time from injury to repair), length of tear, side repaired (medial or lateral), and repair of one or both menisci. We used the Fisher Exact test and Kruskal-Wallis test to evaluate these conditions. The level of significance was set to 0.05.

RESULTS

Of the nineteen patients of group A, sixteen (84.2%) reported no symptoms suggestive of meniscal tears at the last follow-up visit. One patient (5.2%) reported recurrent episodes of pain during moderate exertion and tenderness upon joint-line

Table I. — Study population

	GROUP A (STABLE KNEES)	GROUP B (ACL-DEFICIENT KNEES)
Number of cases	19 patients (20 meniscal tears)	24 patients (25 meniscal tears)
Gender (male/female)	12 M (63%) – 7 F (37%)	21 M (87%) – 3 F (13%)
Age (average, range)	30 years (20-47 years)	26 years (17-35 years)
Knee	10 Right – 9 Left	16 Right – 8 Left
Meniscus	12 Internal – 8 External (1 both)	20 Internal – 5 External (1 both)
Location	20 Body-Posterior horn	25 Body-Posterior horn
Arnozcky zone	16 Red-Red – 4 Red-White	19 Red-Red – 6 Red-White
Type of tear	13 Longitudinal vertical – 6 Oblique – 1 Radial	13 Longitudinal vertical – 3 Oblique – 8 Bucket handle
Length	17 mm (10-25 mm)	15.8 mm (10-25 mm)
Chondral damage	0	7
Femoral condyle affected		6 Medial – 1 Lateral
Size of defect		< 1 cm ²
Chronicity	6 Acute (30%) – 14 Chronic (70%)	5 Acute (20%) – 20 Chronic (80%)
Time to surgery (months)	5.25 Acute – 17.27 Chronic	2.5 Acute – 14.6 Chronic
Number of sutures	2.37 (1-6)	2.33 (1-6)

palpation (following repair of a chronic injury of the external meniscus), and two patients (10.5%) had tenderness upon joint-line palpation plus effusion (two tears of the internal meniscus with chronic bucket-handle injuries). None of them had locking episodes. These three cases (15.8%) were considered failures. However, revision arthroscopy and partial meniscectomy was necessary only in one case, 9 months after initial surgery.

The Lysholm score increased to a mean value of 88.6 (range, 59-100), a statistically significant improvement compared with the preoperative mean value of 62.47 (range, 29-77) ($P < 0.001$, Chi-square test). Sixteen patients (84%) had an excellent or good outcome, 2 patients (10.5%) had a fair result, and 1 patient (5.5%) had a poor result. The Tegner activity score improved significantly ($P < 0.01$) from an average of was 3.53 (range, 3-5) preoperatively to 4.53 (range, 2-7) postoperatively. Most patients had returned to usual activities of daily living.

In group B, 20 cases (83.3%) (16 tears of the internal meniscus and 4 of the external meniscus) showed a complete recovery of the entire joint at the last follow-up visit, with a complete absence of

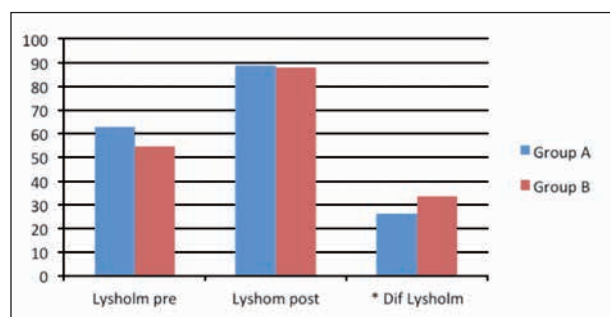
pain, joint locking, and swelling. Of the remaining cases, three patients (12.5%) (2 injuries of the internal meniscus and 1 of the external meniscus, all of them chronic) had occasional episodes of pain, especially in flexion, and swelling. Two of these patients were subsequently subjected to a partial meniscectomy due to failure of healing. The other patient (4.2%) had a new severe traumatic incident 4 months postoperatively, resulting in ACL re-rupture and a new external meniscal lesion. Revision arthroscopy with ACL reconstruction and partial meniscectomy was necessary in this patient. The follow-up surgery confirmed that the suture of the internal meniscus had healed properly. Only one of these 24 patients suffered a complication. He suffered hypoesthesia in the anteromedial aspect of the tibia and foot due to an injury of the saphenous nerve that recovered at 3 months after surgery. There were no other major complications directly associated with the suture device. We haven't found any failure in ACL reconstruction which needed a second surgery to repair.

Lysholm scores significantly improved ($P < 0.005$, Chi-Square test) from 54.47 (range, 40-65) preoperatively to 88 (range, 65-100) post-

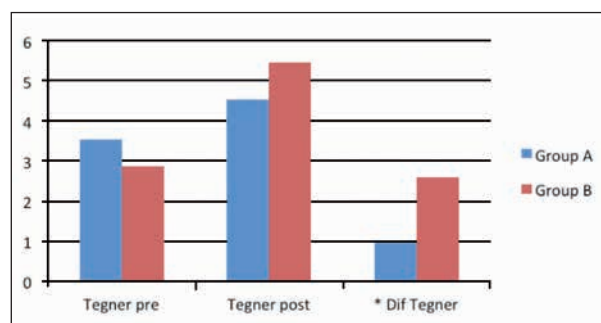
Table II. Differences between Lysholm and Tegner scales in Group A (stable knees) and Group B (ACL-deficient knees).

A : Preoperative and postoperative scores on Lysholm scale in both groups. The improvement was significantly greater in Group B than in Group A. B : Preoperative and postoperative Tegner scores in both groups, being significant the improvement in Group B as well. *Significant difference on healing knee scores ($p < 0.05$)

A : Lysholm knee scale



B : Tegner activity score



operatively. 20 patients (83.3%) had an excellent or good outcome and 4 patients (16.7%) had a fair result. Preoperatively, the mean Tegner activity score was 2.86 (range, 1-4) whereas the postoperative mean value was 5.47 (range, 3-7), a statistically significant difference ($p < 0.05$).

The improvement in the Lysholm score was significantly greater in Group B than in Group A (33.53 vs 26.13, p value 0.0018). However, patients with ACL-deficient knee showed significantly lower preoperative scores for both Lysholm Knee Score (54.47 vs 62.47, p value 0.0037) and Tegner Activity Scale (2.87 vs 3.53, p value 0.0449) (Table II).

Statistical analysis showed that none of the factors that were examined (age, chronicity of tear, length of tear, side repaired and repair of one or both menisci) significantly affected the clinical outcome ($p > 0.05$).

DISCUSSION

The present study proves that good clinical result could be achieved with all-inside techniques, in isolated meniscal tears as well as in meniscal tears associated with ACL ruptures, regardless of the size or the chronicity of the injury.

Evaluation of the results of meniscal repair requires studying a number of factors. The presence or absence of concomitant ligamentous repairs (especially the ACL) needs to be considered, as

patients undergoing concurrent ACL reconstruction make up a different population that is believed to have a better chance of healing (10,25,35). For this reason, we believed it could be interesting to compare the same suture system in two different groups : Group A (stable knee affected with isolated meniscal tears) and group B (ACL-deficient knees affected with meniscal tears).

When comparing both groups, we observed a similar proportion of good clinical results in both populations (Group A : 84.4% vs Group B : 87.5%), according to the criteria of Barrett *et al* (10). Regarding the Lysholm scores, 86% of surgeries were successful in group A, compared to 84% for group B ; this difference was not significant. However, the difference between preoperative and postoperative values was significantly higher in group B (Group A Lysholm increase : 26.13 ; Group B Lysholm increase : 33.53, $p < 0.001$) ; in other words, patients with concomitant ACL reconstruction showed significantly greater improvement of knee parameters after surgery compared with group A. However, we must take into account that prior symptomatology in ACL-deficient knees was significantly worse (Group A preoperative Lysholm : 62.47 vs Group B preoperative Lysholm : 54.47, $p < 0.005$). Similar results were observed if the Tegner score was analyzed.

We used three different techniques to repair ACL ruptures, 85% of them were performed with

autografts. We did not find any graft failures in this group and we do not believe that the type of reconstruction would influence in the final result. However, most patients were operated on using autografts which remain the gold standard in ACL reconstructions (15,32).

Several authors (14,17,19,28,34,40) have stated that in knees with meniscal sutures combined with ACL reconstruction, a very favorable environment for good healing of the meniscus is created. The factors that come into play for the best result of suturing could come from hemarthrosis and fibrin clot formation generated during the ACL reconstruction (36,42).

Different rates of healing are reported following meniscal repair, because clinical success may be different than complete healing. The rate of complete healing after meniscal repair has been reported in the literature (41) to be only around 60%.

Ahn *et al* (1) reviewed meniscal repairs among 140 patients undergoing simultaneous arthroscopic ACL reconstruction. 84.3% of meniscal repairs were completely healed at the time of second-look arthroscopy. The clinical success rate was 96.4%, because most patients in the incompletely healed group showed no clinical symptoms associated with residual meniscal tears. The status of the incompletely healed meniscus and its association with the risk of increasing failure rate with time and its long-term protective effect on cartilage are still unknown. We evaluated the success rate based on clinical findings, as only one of our patients underwent a second look arthroscopy due to an ACL re-rupture, and we found that the sutured meniscus was completely healed. Other authors have observed that in spite of satisfactory clinical outcomes at follow-up, a radiological signal alteration may still be visible on MRI, believed but not proven definitively to be scar tissue (20,27). In light of this evidence, we did not perform repeat MRI examinations to all of our patients.

Upon clinical evaluation using the criteria proposed by Barret (10), we observed 6 failed cases of meniscal suture, three patients in group A and three cases in group B: In the three patients of group A (15.7%) (2 chronic lesions of the internal meniscus and 1 of the external meniscus), the postoperative

presence of persistent pain and swelling, were considered signs of failed healing of the suture. Arthroscopic surgery with partial meniscectomy was necessary in one of these three cases. Three patients in group B (12.5%) (2 lesions of the internal meniscus and 1 of the external meniscus, all of them chronic) still had pain, especially in flexion, with occasional effusion. Two of them underwent repeat arthroscopic surgery in order to perform a partial meniscectomy.

We tried to identify factors predictive of an unsatisfactory result in both groups, such as chronicity of tear (time from injury to repair), length of tear, side of repair (medial or lateral) and repair of one or both menisci. Popescu *et al* (31) prospectively evaluated meniscal suturing using the Fast-Fix device for 25 chronic meniscal tears (> 3 months). Their results suggested that chronic meniscal tears in the red zone or red-white zone could heal. In our series, we found no significant differences between the results of acute and chronic injuries, length of tear, repair side and number of menisci repaired. Clinical results similar to those in our study have been reported in other studies with meniscal repair devices (21,22,30,38).

We had one neurovascular complication, a patient who suffered hypoesthesia in the antero-medial aspect of the tibia and foot due to a saphenous nerve injury that recovered 3 months after surgery. It is difficult to know whether this lesion was directly associated with the suturing technique or with the pressure caused by the hinged postoperative brace.

The present study is clearly limited by its retrospective design, the relatively low number of patients and the lack of a control group. The clinical result was used to determine the success rate in our study, and there was no objective measurement such as second-look arthroscopy or postoperative MRI examination to evaluate the consistency of all of the repairs. Another limitation is that these devices are not compared with traditional suture techniques, though the overall success rate is comparable to them in this short-term follow-up study. The interobserver variability defined by the existence of 3 different surgeons may influence results but increases the external validity of this study.

The strengths of our study are that all patients have been operated on with the same type of suturing system, and that we have compared two statistically similar groups. Another strength is that the evaluation of patients was performed prospectively. Mean follow-up is sufficient to ensure a mid-term clinical result and to clinically confirm the recovery of the meniscus. We have included consecutive patients in our series, and none were lost to follow-up. We have obtained good results in the mid-term follow-up of our group of 45 meniscal repairs, with reproducible clinical results.

CONCLUSIONS

We observed consistently good clinical results with meniscal repairs using an all-inside technique with the Fast-Fix system, for isolated meniscal sutures as well as for meniscal sutures associated with ACL-reconstruction (84% vs. 83.3%). Although patients with ACL ruptures showed significantly greater improvement after surgery, their preoperative situation was also significantly worse. The final result was, however, similar for knees treated with and without concomitant ACL-reconstruction.

REFERENCES

- Ahn JH, Lee YS, Yoo JC, Chang MJ, Koh KH, Kim MH.** Clinical and second-look arthroscopic evaluation of repaired medial meniscus in anterior cruciate ligament-reconstructed knees. *Am J Sports Med* 2010 ; 38 (3) : 472-47.
- Albrecht-Olsen P, Kristensen G, Burgaard P, Joergensen U, Toerholm C.** The arrow versus horizontal suture in arthroscopic meniscus repair. *Knee Surg Sports Traumatol Arthrosc* 1999 ; 7 (5) : 268-273.
- Albrecht-Olsen P, Kristensen G, Törmälä P.** Meniscus bucket-handle fixation with an absorbable Biofix tack : Development of a new technique. *Knee Surg Sports Traumatol Arthrosc* 1993 ; 1 (2) : 104-106.
- Anderson K, Marx RG, Hannafin J, Warren RF.** Chondral injury following meniscal repair with a biodegradable implant. *Arthroscopy* 2000 ; 16 : 749-753.
- Arnoczky SP, Lavagnino M.** Tensile fixation strengths of absorbable meniscal repairs as a function of hydrolysis time. *Am J Sports Med* 2001 ; 29 : 118-23.
- Arnoczky SP, Warren RF.** Microvasculature of the human meniscus. *Am J Sports Med* 1982 ; 10 (2) : 90-95.
- Asik M, Sener N.** Failure strength of repair devices versus meniscus suturing techniques. *Knee Surg Sports Traumatol Arthrosc* 2002 ; 10 : 25-9.
- Baratz ME, Fu FH, Mengato R.** Meniscal tears : The effect of meniscectomy and of repair on intra-articular contact areas and stress in the human knee : A preliminary report. *Am J Sports Med* 1986 ; 14 (4) : 270-275.
- Barber FA, Herbert MA.** Meniscal repair devices. *Arthroscopy* 2000 ; 16 (6) : 613-618.
- Barrett GR, Field MH, Treacy SH, Ruff CG.** Clinical results of meniscus repair in patients 40 years and older. *Arthroscopy* 1998 ; 14 (8) : 824-829.
- Becker R, Schroder M, Starke C, Urbach D, Nebelung W.** Biomechanical investigations of different meniscal repair implants in comparison with horizontal sutures on human meniscus. *Arthroscopy* 2001 ; 17 (5) : 439-444.
- Bonshahi AY, Hoppgood P, Shepard CJ.** Migration of a broken arrow : A case report and review of the literature. *Knee Surg Sports Traumatol Arthrosc* 2004 ; 12 : 50-51.
- Calder S, Myers PT.** Broken arrow : A complication of meniscal repair. *Arthroscopy* 1999 ; 15 : 651-2
- Cannon WD, Vittori JM.** The incidence of healing in arthroscopic meniscus repair in anterior cruciate ligament-reconstructed knee versus stable knee. *Am J Sport Med* 1992 ; 20 (2) : 176-181.
- Chang SK, Egami DK, Shaieb MD, Kan DM, Richardson AB.** Anterior cruciate ligament reconstruction : allograft versus autograft. *Arthroscopy* 2003 ; 19 (5) : 453-462.
- Chiang CW, Chang CH, Cheng CY, Chen AC, Chan YS, Hsu KY, Chen WJ.** Clinical results of all-inside meniscal repair using the FasT-Fix meniscal repair system. *Chang Gung Med J* .2011 ; 34 (3) : 298-305.
- Ellermann A, Siebold R, Buelow JU, Sobau C.** Clinical evaluation of meniscus repair with a bioabsorbable arrow : a 2- to3-year follow-up study. *Knee Surg Sport Traumatol Arthrosc* 2002 ; 10 (5) : 289-293.
- Greis PE, Holmstrom MC, Bardana DD, Burks RT.** Meniscal injury : II : Management. *J Am Assoc Orthop Surg* 2002 ; 10 (3) : 177-187.
- Henning CE, Lynch MA, Clark JR.** Vascularity for healing of meniscus repairs. *Arthroscopy* 1987 ; 3 (1) : 13-18.
- Hoffelner T, Resch H, Forstner R, Michael M, Minnich B, Tauber M.** Arthroscopic all-inside meniscal repair – Does the meniscus heal ? A clinical and radiological follow-up examination to verify meniscal healing using a 3-T MRI. *Skeletal Radiol* .2011 ; 40 (2) : 181-187.
- Kalliakmanis A, Zourntos S, Bousgas D, Nikolaou P.** Comparison of arthroscopic meniscal repair results using 3 different meniscal repair devices in anterior cruciate ligament reconstruction patients. *Arthroscopy* 2008 ; 24 (7) : 810-816.
- Kotsovolos ES, Hantes ME, Mastrokalos DS, Lorbach O, Paessler HH.** Results of all-inside meniscal repair with the FasT-Fix meniscal repair system. *Arthroscopy* 2006 ; 22 (1) : 3-9 .

23. **Levy AS, Meier SW.** Approach to cartilage injury in the anterior cruciate ligament-deficient knee. *Orthop Clin North Am* 2003 ; 34 (1) : 149-167.
24. **Lysholm J, Gillquist J.** Evaluation of knee ligamentsurgery results with a special emphasis on use of a scoringscale. *Am J Sports Med* 1982 ; 10 (2) : 150-154.
25. **McCarthy E, Marx R, DeHven K.** Meniscus repair : consideration in treatment and update of clinical result. *Clin Orthop Relat Res* 2002 ; 402 : 122-134.
26. **McDermott ID, Richards SW, Hallam P, Tavares S, Lavelle JR, Amis AA.** A biomechanical study of four different meniscal repair systems, comparing pull-out strengths and gapping under cyclic loading. *Knee Surg Sports Traumatol Arthrosc* 2003 ; 11 : 23-9.
27. **Miao Y, Yu JK, Zheng ZZ, Yu CL, Ao YF, Gong X, Wang YJ, Jiang D.** MRI signal changes in completely healed meniscus confirmed by second-look arthroscopy after meniscal repair with bioabsorbable arrows. *Knee Surg Sports Traumatol Arthrosc* 2009 ; 17 (6) : 622-30.
28. **Morgan CD, Wojtys EM, Casscells SW.** Arthroscopic meniscus repair evaluated by second look arthroscopy. *Am J Sport Med* 1991 ; 19 (6) : 632-637.
29. **Noyes FR, Basset RW, Grood ES, Butler DL.** Arthroscopy in acute traumatic hemarthrosis of the knee. Incidence of anterior cruciate tears and other injuries. *J Bone Joint Surg Am* 1980 ; 62 (5) : 687-695, 757.
30. **Perdue PS, Hummer CD, Colosimo AJ, Heidt RS, Dormer SG.** Meniscal repair : Outcomes and clinical follow up. *Arthroscopy* 1996 ; 12 (6) : 694-698.
31. **Popescu D, Sastre S, Caballero M, Lee JW, Claret I, Nuñez M, Lozano L.** Meniscal repair using the FasT-Fix device in patients with chronic meniscal lesions. *Knee Surg Sports Traumatol Arthrosc* 2010 ; 18 (4) : 546-550.
32. **Prodromos C, Joyce B, Shi K.** A meta-analysis of stability of autografts compared to allografts after anterior cruciate ligament reconstruction. *Knee Surg Sports Traumatol Arthrosc* 2007 ; 15 (7) : 851-856.
33. **Reish MW, Kurzweil PR.** Fast-Fix meniscus repair. *Tech Knee Surg* 2007 ; 6 (3) : 161-167.
34. **Rosenberg TD, Scott SM, Coward DB et al.** Arthroscopic meniscal repair evaluated with repeat arthroscopy. *Arthroscopy* 1986 2 (1) : 14-20.
35. **Seedhom BB, Hargreaves DJ.** Transmission of the load in the knee joint with special reference to the role of the menisci : Part II : Experimental results, discussions, and conclusions. *Engl Med* 1979 ; 8 : 220-228.
36. **Shelbourne KD, Jari S, Gray T.** Outcome of untreated traumatic articular cartilage defects of the knee : a natural history study. *J Bone Joint Surg Am* 2003 ; 85-A (Suppl 2) : 8-16.
37. **Stärke C, Kopf S, Petersen W, Becker R.** Meniscal repair. *Arthroscopy* 2009 ; 25 (9) : 1033-1044.
38. **Stone RG, Frewin PR, Gonzales S.** Long-term assessment of arthroscopic meniscus repair : A two- to six-year follow-up study. *Arthroscopy* 1990 ; 6 (2) : 73-78.
39. **Tegner Y, Lysholm J.** Rating system in the evaluation of knee ligament injuries. *Clin Orthop Relat Res* 1986 ; 198 : 43-49.
40. **Tucciarone A, Godente L, Fabbrini R, Garro L, Salate Santone F, Chillemi C.** Meniscal tear repaired with Fast-Fix sutures : clinical results in stable versus ACL-deficient knees. *Arch Orthop Trauma Surg* 2012 ; 132 (3) : 349-356.
41. **vanTrommel MF, Simonian PT, Potter HG, Wickiewicz TL.** Different regional healing rates with the outside-in technique for meniscal repair. *Am J Sports Med* 1998 ; 26 (3) : 446-452.
42. **Ventura A, Terzaghi C, Borgo E, Verdoia C, Gallazzi M, Failoni S.** Use of growth factors in ACL surgery : preliminary study. *J Orthop Traumatol* 2005 ; 6 : 76-79.