



Prepatellar Friction Syndrome : a common cause of knee pain in the elite cyclist

Tom CLAES, Steven CLAES, Jeffrey DE ROECK, Toon CLAES

From the AZH St-Elisabeth Hospital, Herentals, Belgium

Background : Although anterior knee pain is extremely common in high-level road cyclists, the exact etiology still remains unclear.

Methods : A group of 28 professional male elite cyclists diagnosed with Prepatellar Friction Syndrome (PPFS) were retrospectively reviewed with specific attention for the typical history, clinical findings and treatment modalities.

Results : A traumatic onset of the complaints was reported by 10 athletes, while the complaints were caused by chronic overuse in the remaining 18 subjects. Conservative treatment delivered poor results and all cases were eventually treated surgically. Surgery confirmed macroscopic damage to at least one prepatellar fascial layer in all patients, after which partial fasciectomy was performed through a mini incision.

Conclusion : PPFS is a new clinical entity of the triple-layered prepatellar fascial structures. Correct diagnosis is critical and based on the typical history and clinical findings. Partial prepatellar fasciectomy is the treatment of choice in order to regain the pre-injury performance level.

Keywords : cycling ; anterior knee pain ; prepatellar friction syndrome ; prepatellar fascia.

INTRODUCTION

With a worldwide cumulative television audience of 3.5 billion people watching the Tour de France annually, the popularity of professional road

cycling is still increasing each year. The world governing body for sports cycling “Union Cycliste International/International Cycling Union” (UCI) released in February 2012 a report stating that (professional) “cycling is in a healthy position and resisting the effects of the current global economic downturn”. In 2012, there were 40 professional teams (18 UCI ProTeams and 22 UCI Professional Continental Teams) with a total budget of 321 million euro.

In sharp contrast with these economical facts, current medical literature contains relatively few epidemiological reports on overuse injuries in professional road cyclists. De Bernardo *et al* (6) found that 62.7% of all cycling-related injuries in 51 top-level cyclists were caused by overuse, with 32.1%

■ Tom Claes, MD.
Department of Orthopedic Surgery & Traumatology, University Hospitals Leuven, Leuven, Belgium.

■ Steven Claes, MD, PhD.

■ Toon Claes, MD.
Department of Orthopedic Surgery & Traumatology, AZH St-Elisabeth Hospital, Herentals, Belgium.

■ Jeffrey De Roeck, MD.
Department of Radiology, AZH St-Elisabeth Hospital, Herentals, Belgium.

Correspondence : Tom Claes, Department of Orthopedic Surgery & Traumatology, University Hospitals Leuven, Weligerveld 1, 3212 Pellenberg, Belgium.

E-mail : tokkeclaes@gmail.com

© 2015, Acta Orthopædica Belgica.

of them affecting the knee. Iliotibial band friction syndrome was the most common diagnosis in almost half of the cases. Silberman stated that the knee is the most common site of overuse injury and the shoulder for traumatic injury (10). Clarsen *et al* found on the other hand that after lower back pain, “anterior knee pain” was the second most common overuse injury in professional road cyclists (12-month prevalence of 36%). Knee pain accounted for the vast majority of missed trainings and races caused by overuse injuries. The authors state that the “high prevalence of anterior knee pain [...] appears to confirm anecdotal reports that knee pain is a common injury affecting competitive cyclists.” (4).

The term “anterior knee pain” is however a clinical symptom, not a diagnosis. Traditionally, the cartilage and subchondral bone of the patellofemoral joint is considered as the major culprit of anterior knee pain in the general population (5). This very common “patellofemoral pain syndrome” has been shown to be associated with a volume deficit and weakness of the quadriceps muscle (5,8,13). However, as cycling mainly involves quadriceps contraction, elite cyclists are known to carry extremely well-developed quadriceps muscles. Moreover the clinical history of cyclists, presenting with non-traumatic anterior knee pain, almost never includes the typical symptoms attached to the classic picture of the “patellofemoral pain syndrome” e.g. going up and down stairs, kneeling, squatting and sitting for a longer time (“movie sign”). This suggests the prevalence of other clinical entities causing frequently anterior knee pain complaints in professional cyclists.

Being confronted with large numbers of elite cyclists showing all kind of knee disorders, the clinical impression arose that a significant amount of patients exhibit an extra-articular etiology for their knee complaints. In 2003, Dye *et al* were the first to describe the rather complex anatomy of the soft-tissues anterior to the patella (7). These authors described the prepatellar fascia as a complex system of three fibrous layers with intercalated bursae (Fig. 1). The trilaminar layers can be divided from superficial to deep. Those structures included a superficial fascia with transversely oriented fibers, an intermediate fascia with obliquely oriented

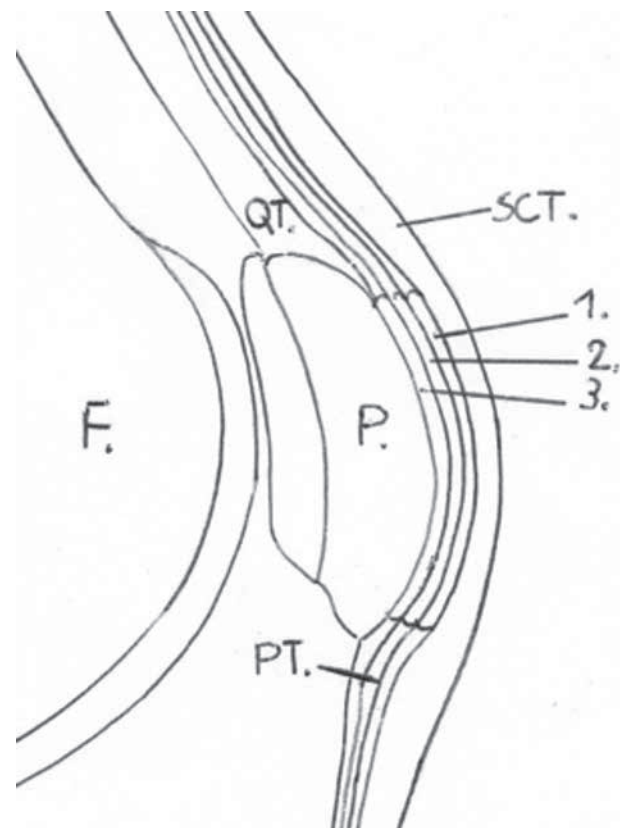


Fig. 1. — Sagittal drawing of the knee shows the prepatellar trilaminar arrangement with in between three prepatellar bursae. F = femur, QT = quadriceps tendon, SCT = Subcutaneous tissue, P = patella, 1 = subcutaneous bursa between subcutaneous tissue and superficial transversely oriented fascia, 2 = sub-fascial bursa between superficial transversely oriented fascia and intermediate obliquely oriented aponeurosis, 3 = subaponeurotic bursa between intermediate obliquely oriented aponeurosis and deep longitudinally oriented fibers of the rectus femoris, PT = patella tendon.

fibers, and a deep fascia with longitudinally oriented fibers in the extension of the rectus femoris tendon.

A bursa is situated between each of the layers. These bursae play an important role in reducing friction between the layers (3). The presence of three bursae anterior to the patella confirms the high exposure to friction. It should be remembered that especially high-level cyclists are susceptible to friction syndromes due to their extremely repetitive motion activities. During 4 hour of cycling, a rider with a cadence of 85 rpm will have 20.400 pedal revolutions. A small amount of malalignment,

whether anatomic or equipment related, can lead to dysfunction, impaired performance, and pain. Repetitive activity can lead to fatigue and chronic irritation of a specific structure such as tendon, fascia or bone. Without adequate recovery, micro trauma stimulates an inflammatory response, causing the release of vasoactive substances, inflammatory cells, and enzymes that damage local tissue. Cumulative micro trauma due to further repetitive activity eventually leads to clinical injury. The authors describe a new clinical entity of anterior knee pain in elite cyclists caused by friction of the pre-patellar soft-tissue layers on the patellar surface or edges due to overload.

MATERIALS & METHODS

History & Clinical features

This retrospective single center study was reviewed and approved by the institutional Ethics Committee (OG 150) In all cases, the diagnosis was made by clinical examination in combination with the typical history. An important aspect in the history is the moment in time when the patient encounters his pain. Prepatellar friction syndrome is characterized by experiencing pain exclusively during cycling, and is seen almost exclusively in high mileage riders. In non-traumatic cases, pain starts usually after a really long training, also during or after a training camp or stage race. An aggravating factor may be the raise of rotations per minute (higher cadence). In these cases, the athlete experiences more pain with a higher pedaling, and less pain at a lower cadence, even if more power is applied. Standing on the pedals (riding “en danseuse”) uphill is most of the time a pain reliever because of less knee flexion and a lower cadence, giving less friction anterior to the patella. In a patellofemoral disorder this would be the inverse.

Problems do start for a lot of road cyclists during winter – and springtime, because of wearing long leg sleeves to protect them from cold. This will raise the pressure on the anterior soft tissues and tends to increase the friction phenomena. External compression on the knee/patella aggravates the anterior knee pain. When the patient is asked to release his detachable long sleeves, pain becomes much more tolerant in a high number of cases.

Concerning the onset of complaints, in most cases the pain starts without a history of a recent trauma, although a clear trauma can be the eliciting cause. In these cases there sometimes is still a bruise visible at the painful spot

on the patella. Mechanism of trauma may be hitting the patella against the handlebar of the bicycle causing a contusion on the soft-tissues anterior to the patella, or may be a fall direct on the anterior aspect of the knee. Even minor mechanical trauma to the prepatellar fascia obvious promotes friction. A complete history is essential in making the diagnosis of prepatellar friction syndrome.

Physical examination starts by looking for prepatellar wounds or bruises due to recent trauma. Palpation reveals local tenderness at one specific anterior spot or over the patella or its ridges. Sometimes an irregularity due to fascial damage can be felt and even seen as a dimple. The most frequent localization on the patella in this series was the superomedial part of the patella. In most cases a prominent ridge in this area is present, which, could serve as a prominence for the insertion of the vastus medialis muscle. The superolateral part is the second most frequent pathologic area followed by the inferomedial edge. Patellofemoral compression test, grinding test and squat test are all negative. It is indicated to examine the patient just after a good ride with the bicycle, when pain is more prominent. After even a small period of rest, pain on clinical examination may be completely absent, which can explain the unfamiliarity of the pathology. In cases of doubt, a test injection with a local anesthetic might be very useful.

Technical investigation

Imaging of a defect in the prepatellar fascial layers might be quite a challenge. Ultrasound is in our experience the golden standard for technical investigation of PPFs. It is a low cost and easy available imaging technique. Ultrasound of the pathologic prepatellar fascia has to be compared with the contralateral side. A high frequency linear probe has to be used, and care has to be taken not to apply too much pressure with the probe on the tissues.

Ultrasound shows in the typical cases a defect in the fibers of the prepatellar fascia at the pathological side. With gentle pressure of the probe, the subcutaneous tissue can be pushed in the defect, against the cortex of the patella as with a rotator cuff tear in which the deltoid touches the head of the humerus. The complex structure of the prepatellar soft tissue can also be shown with the use of MRI (1,12). Axial view of the patella in T1-weighted fat-suppressed images gives the ability to differentiate the three layers if they are present. Findings of Dye *et al* and Aguiar *et al* have shown a trilaminar pattern in 93% respectively 78% of the cases (1,7).

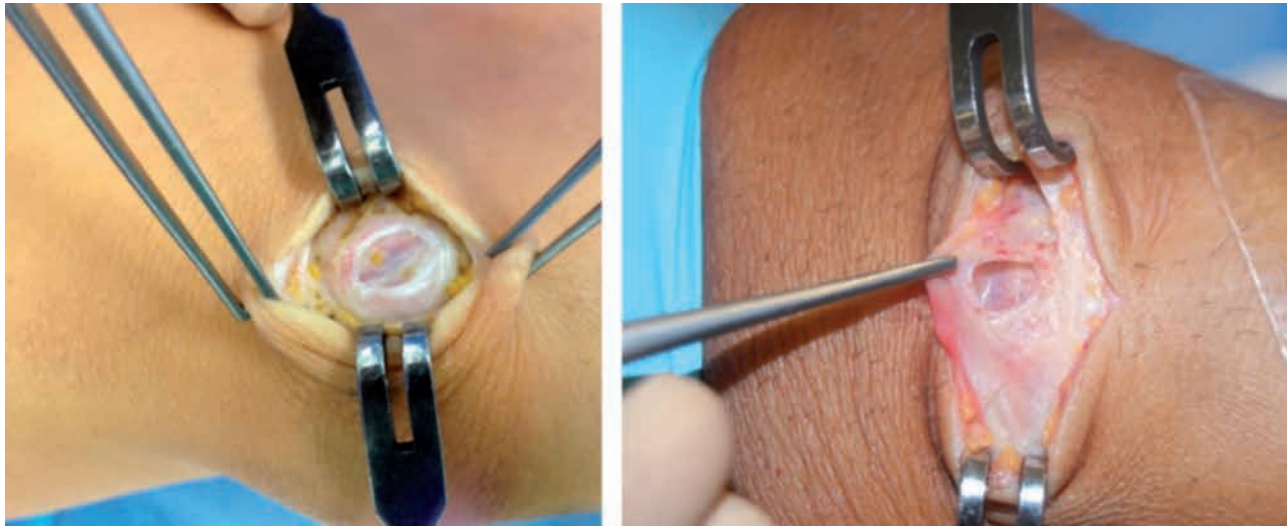


Fig. 2. — Images of 2 different patients showing the defect in the prepatellar soft tissue

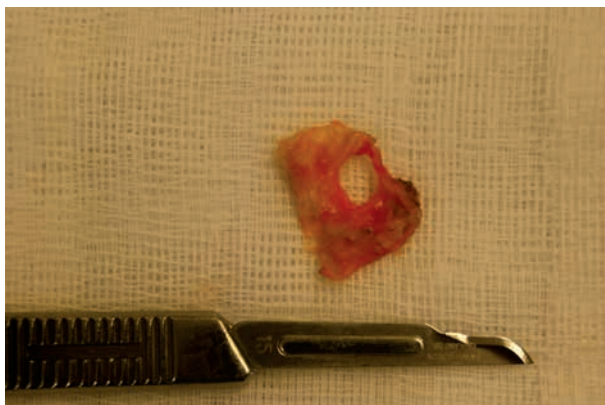

Fig. 3. — Resected tissue with a central hole

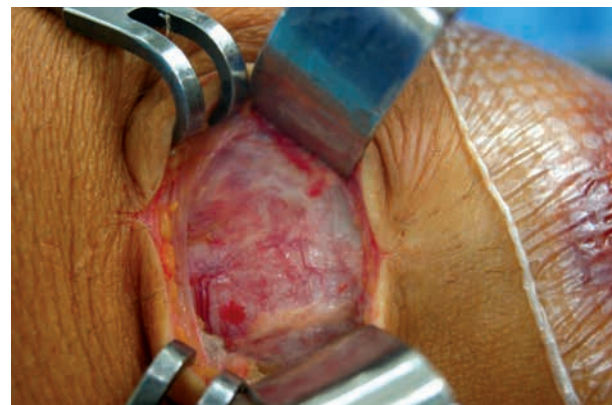


Fig. 4. — Hyperemic aspect of the deep layer

Operative treatment

Due to persistent complaints, all included patients went eventually for surgery as a definite treatment. Before anesthesia a proper examination is necessary to locate exactly the painful spot which is marked preoperatively. All patients were installed in dorsal decubitus and a tourniquet was used. A small vertical incision is made over the marked area of the patella. After retraction of the skin, the underlying area is inspected for fascial irregularities. Every case showed a substantial defect in the superficial and/or intermediate layer (Fig. 2). As a rule the deep third layer is structurally intact, but with major hyperemia and neovascularisation. Which layer is damaged most, is sometimes very difficult to distinguish due

to diffuse damage to the soft tissues. It has to be stressed that these cases don't show any evidence of a classic prepatellar bursitis, nor clinically, nor on imaging, nor preoperatively. The pathological soft-tissue is resected until stable and healthy margins have been obtained (Fig. 3). After resection a window in the prepatellar trilayered soft tissue is created with sight on the hyperemic deepest layer (Fig. 4). After closure a compressive bandage is applied to prevent postoperative hemorrhage.

After treatment

Postoperative treatment exists of immediately quadriceps rehabilitation with electrical stimulation. Active and passive mobilization of the knee is started immediately

with knee flexion only up to 45 degrees in the first week. Cycling exercises can be started after three to six weeks.

RESULTS

The operated series consisted of 29 patients. All patients were male (semi-) professional cyclists, 11 contested in the UCI ProTour/Cyclocross World Cup races, 17 participated in the UCI Continental Tour (Europe) and 1 was a recreational triathlon athlete. All were operated by the senior author (TC). The median age of the athletes was 25.3 years (ranges, 18 to 34 years). A traumatic onset was reported by 10 athletes, while in the remaining 19 patients, the complaints were triggered by chronic overuse. The patients' symptoms had continued for several months and conservative treatment had failed to give relief. All the patients had been treated with a combination of rest, physiotherapy, bike fit, and/or corticosteroid and local analgesic infiltration without success. All the athletes were no longer able to train or race effectively. All patients were treated operatively with a resection of the damaged and inflamed prepatellar soft-tissue using a mini-incision. Hematoma was the most common post-operative complication. In 6 patients a prepatellar hematoma was noticed, all within the first 2 weeks after surgery. Drainage was obtained with a needle aspiration, except one who needed drainage. In one patient a postoperative seroma was seen. All patients were pain free following their operation after 3 months. All subjects returned to their pre-injury level.

DISCUSSION

The "cycling knee" has to withstand billions of cycles during a season as a professional cyclist, which may induce different patterns of friction. The best known friction syndrome in cycling is the iliotibial band (ITB) syndrome where the iliotibial tractus gets damaged by repetitive knee flexion and extension causing friction secondary to cyclic anterior-posterior motion of the ITB over the lateral femoral epicondyle (8).

With the PPFS we describe another specific friction syndrome affecting high-level cyclists. The two

superficial layers of the triple-layered prepatellar fascia rub against the well-fixed deep periosteal fascial layer, with subsequent mechanical damage to the fascia causing more friction and chronicity. This pathologic entity is very specific for cycling. Running and squatting poses almost no problem in this pathologic condition. The structural friction and late damage of the prepatellar soft tissue cause pain and the inability to perform longer cycling training sessions or races.

The prevalence of anterior knee pain in cyclists is high and often assigned to patellofemoral chondromalacia. This retropatellar pain is caused by increased pressure across the patellofemoral joint and/or patellofemoral maltracking. Improper adjustment of the bicycle seat can also lead to patellofemoral hyperpression when the saddle is positioned too low (2). Treatment exists of proper seat positioning, adequate training with quadriceps strengthening, especially the vastus medialis obliquus and stretching of the quadriceps, hamstring and gastrocnemius-soleus complex (9).

Unlike the literature, the authors believe that patellofemoral chondromalacia in high-level cyclist is very rare and significantly overdiagnosed. A proper anamnesis and clinical examination often reveal no retropatellar but prepatellar pain, no positive hyperpression test and no pain in deep flexion or when climbing stairs. Furthermore the quadriceps musculature is often one of the best developed muscles in professional cyclists. Significant patellofemoral chondromalacia in cyclists is rather rare and should be thoroughly substantiated when making the diagnosis. Prepatellar soft tissue friction is a much more important cause of anterior knee pain in cyclists.

The symptoms of PPFS are presenting only during cycling with an aggravation of the complaints when an extra compression is added to the prepatellar structures. Tight leg sleeves that the cyclists wear in wintertime may be one of the causes. When the pedal strokes per minute increase, the cyclist will create more friction resulting in more pain. Examination occurs ideally just after a significant training provoking pain. MRI can show both the normal and the damaged triple prepatellar layer structure, but ultrasound seems more effective because of the superficial localization of the

pathology, this besides the advantage of its availability and less costs.

CONCLUSION

Although anterior knee pain is extremely common in professional cyclists, the exact etiology has not been described, but commonly attributed to patellofemoral chondromalacia. A new clinical entity in high-level cyclists is presented. The prepatellar friction syndrome (PPFS) is caused by direct traumatic or chronic overuse damage to the triple-layered soft-tissues anterior to the patella. Correct diagnosis is critical and based on the typical history and clinical findings. Diagnosis can be confirmed both by ultrasound and by MRI. Surgical treatment with careful excision of the disrupted area prepatellar soft-tissue layer delivers excellent results with all athletes regaining their pre-injury performance level.

Acknowledgments

The authors thank Katrien Van Den Bosch and Johan Bellemans for their appreciated contribution to the study.

REFERENCES

1. **Aguiar RO et al.** The prepatellar bursa : cadaveric investigation of regional anatomy with MRI after sonographically guided arthroscopy. *AJR Am J Roentgenol* 2007 ; 188 (4) : W355-8.
2. **Bini R, Huma P, Croft J.** Effects of bicycle saddle height on knee injury risk and cycling performance. *Sports Med* 2011 ; 41 (6) : 463-476.
3. **Bywaters EG.** The bursae of the body. *Ann Rheum Dis* 1965 ; 24 : 215-18.
4. **Clarsen B, Krosshaug T, Bahr R.** Overuse injuries in professional road cyclists. *Am J Sports Med* 2010 ; 38 (12) : 2494-501.
5. **Chiu JK, Wong YM, Yung PS, Ng GY.** The effects of quadriceps strengthening on pain, function, and patellofemoral joint contact area in persons with patellofemoral pain. *Am J Phys Med Rehabil* 2012 ; 91 (2) : 98-106.
6. **De Bernardo N, Barrios C, Vera P, Laiz C, Hadala M.** Incidence and risk for traumatic and overuse injuries in top-level road cyclists. *J Sports Sci* 2012 ; 30 (10) : 1047-53.
7. **Dye SF et al.** Soft-tissue anatomy anterior to the human patella. *J Bone Joint Surg Am* 2003 ; 85-A (6) : 1012-7.
8. **Halabchi F, Mazaheri R, Seif-Barghi T.** Patellofemoral pain syndrome and modifiable intrinsic risk factors ; how to assess and address ? *Asian J Sports Med* 2013 ; 4 (2) : 85-100.
9. **Post WR.** Anterior knee pain : diagnosis and treatment. *J Am Acad Orthop Surg* 2005 ; 13 (8) : 534-43.
10. **Silberman MR.** Bicycling injuries. *Curr Sports Med Rep* 2013 ; 12 (5) : 337-45.
11. **Strauss E, Kim S, Calcei J, Park D.** Iliotibial band syndrome : evaluation and management. *J Am Acad Orthop Surg* 2011 ; 19 : 728-736.
12. **Wangwinyuvirat M et al.** Prepatellar quadriceps continuation : MRI of cadavers with gross anatomic and histologic correlation. *AJR Am J Roentgenol* 2009 ; 192 (3) : 111-6.
13. **Werner S.** An evaluation of knee extensor and knee flexor torques and EMGs in patients with patellofemoral pain syndrome in comparison with matched controls. *Knee Surg Sports Traumatol Arthrosc* 1995 ; 3 (2) : 89-94.