



Arthroscopic debridement with and without distal ulnar resection in the treatment of triangular fibrocartilage complex tears

Luc DE SMET, Maarten VAN NUFFEL, Pieter KOORNEEF, Ilse DEGREEF

From Orthopaedic Surgery, Upper Limb Surgery, University Hospitals of Leuven, Pellenberg Campus, Pellenberg, Belgium

A retrospective survey for debridement with or without wafer distal ulna resection was performed. Forty six patients responded to a questionnaire on pain, disability and time off work. The mean DASH score decreased from 42 to 28 on average. Thirty two patients were satisfied. The pain was considered severe in 12 patients. There were significant differences in the outcome between debridement only and debridement with wafer resection of the distal ulna.

Key words : wrist ; arthroscopy ; TFCC ; disability ; wafer.

INTRODUCTION

The TFCC (triangular fibrocartilage complex) has been studied extensively (9,13,14,20). Palmer classified TFCC-lesions into two groups: a traumatic (type I) and a degenerative (type II) group (21,22). The distinction between a degenerative tear and a chronic (central) posttraumatic tear is not always obvious. Anatomical vascularity studies of the TFCC indicate that only the ulnar rim is vascularized (1,4,15). This makes sutures in the central or radial part rather hazardous. In these lesions, most authors propose to perform a synovectomy and a debridement of the tear and, if necessary, a shortening of the distal ulna (wafer procedure). Although this is common practice, outcome studies are sparse.

We conducted a retrospective survey on this procedure to evaluate the disability.

MATERIAL AND METHODS

We reviewed the files of all patients who had a wrist arthroscopy between 2005 and 2010 in our institution : from a total of 468 patients, 107 underwent a procedure on the TFCC (resection or suture). A questionnaire was sent to all of these : 74 responded ; 34 had debridement only and 12 also had a wafer procedure. These 46 are the cohort included in this study. Twenty five patients who had a TFCC suture were not included in the study (Fig. 1).

In the questionnaire a quick DASH questionnaire (Disability of arm, shoulder and hand) was included. We also asked for a pain evaluation (VAS – visual analogue score), loss of force and motion and sick leave. The DASH questionnaires were designed to evaluate the disability rather than the impairment. It is a self-administrated questionnaire which includes 30 items related to functional activities and symptoms in daily life. The patient is asked to attribute a score of 1 to 5 on all items.

- Ilse Degreef, MD, PhD, Assistant-Surgeon-in-chief.
- Luc De Smet, MD, PhD, Surgeon-in-chief.
- Maarten van Nuffel MD, fellow.
- Pieter Koorneef, MD, Resident.

Orthopaedic Surgery, Upper Limb Surgery, University Hospitals of Leuven, Pellenberg Campus, Pellenberg, Belgium.

Correspondence : Luc De Smet, Department of Orthopaedic Surgery, University Hospital Pellenberg, Weligerveld 1, B-3212 Pellenberg, Belgium.

E-mail : Luc.desmet@uz.kuleuven.ac.be

© 2014, Acta Orthopædica Belgica.

The raw score is converted into a 0 to 100 scale. The questionnaires are designed more critically and analyzed for relevancy and validity. The DASH score has been proposed by the AAOS as the standard for hand and upper limb disability evaluation. The Quick DASH is limited to only 11 questions but correlates very well with the former DASH score (7, 8,10).

All data were processed and statistical analysis was performed; significance was set at $p < 0.05$.

There were 12 males and 33 females, the mean age was 34 years (range : 12 to 66). A traumatic event was recalled by 28 patients. The right side was involved in 27, the left side in 18, the dominant side in 31, the non-dominant side in 12 (in 2 cases the dominance was not known). The patients were not recalled due to restricted regulation of the privacy policy. Ethical approval was acquired according to hospital requirements.

A preoperative DASH score was present in 25 cases (18 in 34 TFCC resections, 7 in 12 wafer procedures). The mean DASH score was 42 (SD 19.6), 49 in the TFCC resections (SD 17.3) and 40 in the wafer procedures (SD 20.2).

Surgery was performed according to standard procedures under general anaesthesia and traction (25). The standard 3-4 portal was used for visualisation, the 6R for instrumentation. After general inspection the synovium in the ulnar compartment of the wrist was removed with soft tissue shavers, afterwards the central tear was debrided with arthroscopic nibblers and shavers. When the distal ulnar was prominent or when the cartilage was damaged, the distal 2 mm were removed with an arthroscopic bone burr.

The portals were not closed and the wrists were packed in a bulky dressing and mobilisation was allowed within pain limits. After 7 to 10 days the dressing

was removed and more mobilisation was encouraged. In anxious patients or when the range of motion was not sufficient after 4 to 6 weeks, physiotherapy was started.

RESULTS

The average postoperative follow-up was 35 months (range 11 to 67). Thirty two patients (70%) were satisfied or very satisfied (DASH less than 30). The postoperative DASH was 28 (SD 23.8). The subgroup with wafer obtained a DASH of 34 (SD 19.4), the subgroup without a wafer procedure had a DASH of 25 (SD 24.9). The difference between the preoperative DASH and postoperative DASH was highly significant (non paired T-test 0.015). The difference between the two subgroups was not statistically significant (T-test, $p = 0.26$). In the group with completed preoperative DASH scores, the improvement in DASH score was also significant (paired T-test $p = 0.0013$). This was also the case in the group with TFCC resection (paired T-test 0.0073), but in the wafer procedure, there was no significant improvement in the DASH score (paired T-test $p = 0.14$). In 22 patients DASH score was lower than 20, in 10 between 21 and 40 and in 14, it was higher than 41 (Table I). Differences in DASH score were not significant when the cut-off was set at 20 ($p = 0.32$), 30 ($p = 0.29$) or 40 ($p = 0.47$) (Fisher exact test). The DASH score improved (compared to the preoperative value) in 18 patients, remained status quo in 6 and was worse in 1.

Table. I — DASH score improvement

		N	Preop.	Postop.	Significance
T test total group	Total	46	42 (SD 19.6)	28 (SD 23.8)	0.015
	TFCC resection	34	42 (SD 17.3)	25 (SD 24.9)	0.26
	Wafer	12	40 (SD 20.2)	34 (SD 19.4)	
Paired T test	Total	25	42 (SD 19.6)	24 (SD 24.5)	0.0013
	TFCC resection	18	42 (SD 17.3)	22 (SD 24.2)	0.0073
	Wafer	7	40 (SD 20.2)	32 (SD 24.0)	0.14

In the total group, disability was significantly improved. However, this was based mostly on the improvement in the group with TFCC resection only. Improvement after added wafer resection is debatable. (preop. = before surgery, postop. = at final follow up, SD = standard deviation ; N = number).

Table II. — DASH score categories

DASH	< 20	21-40	> 41
Debridement only	18	79	
+ wafer	4	35	
Total	22	10	14
Fisher exact	0.32	0.29	0.47

Differences in DASH score were not significant when the cut-off was set at 20, 40 or 41 as demonstrated by the Fisher exact test.

The mean VAS for pain was 4.0 (SD 2.99) for the whole group ; 3.8 (SD 3.16) without wafer, 4.6 (SD2.66) with wafer (T-test p 0.44, not significant). However, 12 patients reported severe pain (26%).

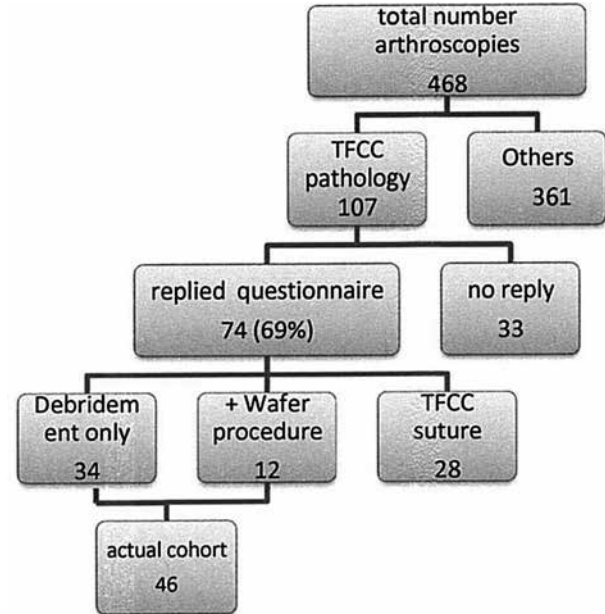
Subjective loss of motion was reported in 18 cases, loss of force 19 patients. The mean time off work was 5.8 months (range : zero to 26 months) in the 37 patients with a paid job, one patient did not return to her previous occupation.

DISCUSSION

In this survey we studied the disability of the patients after debridement combined or not with a wafer procedure for complex TFCC tears. In previous studies (6-8) we found that grip force and range of motion did not change after procedures on the TFCC, and we also found a good correlation of the DASH score with grip force and range of motion (when the latter was not markedly restricted).

In the literature, poor results were mainly due to persisting pain, and functional restrictions were not important. The first series was reported by Osterman in 1990 on 52 patients : 73% had pain relief and 88% considered the procedure worthwhile (19). Minami *et al* reported on 16 cases and had according to their own scoring system 13 good and excellent results ; 3 had moderate to severe persisting pain (16). Westkaemper *et al* in 28 cases reported, used the Mayo wrist score and noted 21 excellent and good results (75%). The mean period off work was 9.5 weeks (24). Husby and Haugsvedt in 2001 obtained 27 excellent and good

Table III. — Flow chart of this survey



results (84%) in their series of 32 cases (11). The Mayo wrist score was used. The time off work was very short, only 5 weeks on average. Miwa *et al* had very good outcomes : 26 of the 29 patients (89.6%) had excellent and good results according to Minami's criteria (17). Darlis *et al* used radiofrequency probes to debride the TFCC and of 20 cases, 17 had good and excellent results (Mayo wrist score) (5).

The use of the laser was reported by Blackwell *et al* in 2001 with 68% good and excellent outcomes in 35 patients (3). Nagle and Bernstein had 7 excellent, 2 good, 1 fair and 1 poor result with laser assisted ulnar shortening (wafer) (18). Infanger and Grimmis patients all had pain relief after laser assisted TFCC debridement (79 cases) (12). The mean DASH was 12, with 60 less than 210 and 19 between 21 and 30 points. The time off work was 3.5 weeks on average.

More detailed data on the wafer procedure were published by Tomaino *et al* and Bernstein *et al* (2, 23). Tomaino reported 12 cases : 8 were completely pain free and 4 had minor symptoms, they all were satisfied. Bernstein had 9 excellent and good results in their 11 cases and a better outcome than classical extra-articular shortening.

Our series has a substantially worse outcome than most others reported. The DASH score was higher, patient satisfaction was lower and the sick leave was much longer. However, this is mainly related to the protective nature of the Belgian social security system which does not give incentives to return to work as soon as possible. Still the high percentage of persisting pain is problematic. We assume that other features than the torn TFCC may play a role in ulnar wrist pain. Further fine-tuning of the painful wrist is mandatory to perform adequate surgery for each patient and to obtain better outcomes.

REFERENCES

- Bednar M, Arnocsky S, Weiland A.** The microvasculature of the triangular fibrocartilage complex : Its clinical significance. *J Hand Surg* 1991 ; 16-A : 1101-1105.
- Bernstein M, Nagle D, Martinez A, Stogin JM Jr, Wiedrich TA.** A comparison of combine arthroscopic triangular fibrocartilage debridement and arthroscopic wafer distal ulna resection versus arthroscopic triangular fibrocartilage debridement and ulnar shortening osteotomy for ulnar impaction syndrome. *Arthroscopy* 2004 ; 20 : 392-401.
- Blackwell R, Jemison D, Foy B.** The holium-yttrium aluminium gammat laser in wrist arthroscopy : a five- year experience in the treatment of central fibrocartilage complex tears by partial excision. *J Hand Surg* 2001 ; 26-A : 77-84.
- Chidgey L, Paul C, Bittar E, Spanier S.** Histological anatomy of the triangular fibrocartilage. *J Hand Surg* 1991 ; 16-A : 1084-1100.
- Darlis N, Weiser R, Sotereaos D.** Arthroscopic triangular fibrocartilage complex debridement using radiofrequency probes. *J Hand Surg* 2005 ; 30-B : 638-642.
- Degreef I, Welters H., Milants P, Van Ransbeeck H, De Smet L.** Disability and function after arthroscopic repair of ulnar avulsions of the triangular fibrocartilage complex of the wrist. *Acta Orthop Belg* 2005 ; 71 : 289-293.
- De Smet L.** The DASH questionnaire and score in the evaluation of hand and wrist disorders. *Acta Orthop Belg* 2008 ; 74 : 575-581.
- De Smet L.** Relationship of impairment, disability and working status after reconstructive surgery of the wrist. *Hand Surg* 2007 ; 12 : 1-5.
- Garcia-Elias M, Domenech-Mateu JM.** The articular disc of the wrist. Limits and relations. *Acta Anat* 1987 ; 128 : 51-54.
- Hudak P, Amadio P, Bombardini C.** Development of an upper extremity outcome measure : the DASH. *Am J Industr Med* 1996 ; 29 : 602-608.
- Husby T, Haugstvedt J.** Long-term results after arthroscopic resection of lesions of the triangular fibrocartilage complex. *Scand J Plast Reconstr Hand Surg* 2001 ; 35 : 79-83.
- Infanger M, Grimm D.** Meniscus and disc lesions of the triangular fibrocartilage complex : treatment by laser-assisted wrist arthroscopy. *J Plast Reconstr Surg* 2009 ; 62 : 466-471.
- Kauer J.** The distal radioulnar joint: Anatomic and functional considerations. *Clin Orthop Relat Res* 1992 ; 275 : 37-45.
- Mikic Z.** Detailed anatomy of the articular disc of the distal radioulnar joint. *Clin Orthop Relat Res* 1989 ; 245 : 123-132.
- Mikic Z.** The blood supply of the human distal radioulnar joint and the microvasculature of its articular disk. *Clin Orthop Relat Res* 1992 ; 275 : 19-28.
- Minami A, Ishikawa J, Suenaga N, Kasaqima T.** Clinical results of treatment of triangular fibrocartilage complex tears by arthroscopic debridement. *J Hand Surg* 1996 ; 21A : 406-411.
- Miwa H, Hashizume H, Fujiwara K, Inoue H.** Arthroscopic surgery for traumatic triangular fibrocartilage complex injury. *J Orthop Sci* 2004 ; 9 : 354-359.
- Nagle D, Benson L.** Wrist arthroscopy: Indications and results. *Arthroscopy* 1992 ; 8 (Suppl 2) : 198-203.
- Osterman L.** Arthroscopic debridement of triangular fibrocartilage complex tears. *Arthroscopy* 1990 ; 6 : 120-124.
- Palmer A, Werner F.** The triangular fibrocartilage complex of the wrist. Anatomy and Function. *J Hand Surg* 1981 ; 6 : 153-162
- Palmer A.** Triangular fibrocartilage complex lesions: A classification. *J Hand Surg* 1989 ; 14-A : 594-606.
- Palmer A.** Triangular fibrocartilage disorders : Injury patterns and treatment. *Arthroscopy* 1990 ; 6 : 125-132.
- Tomaino M, Weiser R.** Combined arthroscopic TFCC debridement and wafer resection of the distal ulna in wrists with triangular fibrocartilage complex tears and positive ulnar variance. *J Hand Surg* 2001 ; 26-A : 1047-1052.
- Westkaemper J, Mitsionis G., Panayotis N et al.** Wrist arthroscopy for treatment of ligament and of triangular fibrocartilage complex injuries. *Arthroscopy* 1998 ; 14 : 479-483.
- Whipple T, Marotta J, Powell J, Powell J.** Techniques of wrist arthroscopy. *Arthroscopy* 1986 ; 2 : 244-252.