



## Effect of intravenous dexamethasone on prevertebral soft tissue swelling after anterior cervical discectomy and fusion

Tae Wook NAM, Dong Ho LEE, Jong Ki SHIN, Tae Sik GOH, Jung Sub LEE

From Busan Centum Hospital, and Pusan National University School of Medicine, Busan, and Asan Medical Center, Seoul, Republic of Korea

The authors compared the effect of postoperative administration of corticosteroids (dexamethasone) on prevertebral soft tissue swelling with that of placebo in patients with anterior cervical discectomy and fusion (ACDF). Sixty-two consecutive patients with degenerative disc disease of the cervical spine, who underwent a one level ACDF, were examined prospectively. They were assigned randomly to 3 treatment groups. Group 1 received 10/5/5 mg, immediately postoperatively and on day 1 and 2, group 2 received 20/10/10 mg, and group 3 received placebo (normal saline). Plain lateral radiographs in the supine position were taken preoperatively, immediately postoperatively, and then daily for 5 days after the operation. The area of the prevertebral soft tissue density was measured from the lower border of C1 to the upper end plate of C7 on the lateral radiographs, using a PACS digital measuring instrument. The patients were also asked to evaluate dyspnea and dysphagia, using a 10-point visual analog scale (VAS). The 3 groups did not differ statistically with regard to the area of prevertebral soft tissue density and VAS for dysphagia, at any time. However, group 1 and 2 showed significant reduction in VAS for dyspnea, compared to group 3, immediately postoperatively, on day 1 and day 2. Group 1 and 2 showed no significant difference of VAS for dyspnea on any postoperative day, suggesting that the dose played no role. As a conclusion, steroids are not effective in reducing postoperative prevertebral soft tissue density, but might reduce initial dyspnea.

**Keywords:** postoperative edema ; steroids ; anterior cervical discectomy and fusion.

### INTRODUCTION

Airway obstruction requiring reintubation or tracheostomy after anterior cervical discectomy and fusion (ACDF) is a potentially life threatening condition (7,13). Fortunately the incidence is low. The causes of upper airway obstruction after this procedure are pharyngeal oedema (7,11), pseudomeningo-coele (1,4,11), haematoma (3), angioedema (9), and dislodgement of the graft or plate (12). Sagi *et al* (13) reported a retrospective analysis of potential risk factors for airway obstruction in 311 patients who

- 
- Tae Wook Nam, MD, PhD, Orthopaedic Surgeon.  
*Dept of Orthopaedic Surgery, Busan Centum Hospital, Busan, Republic of Korea.*
  - Dong Ho Lee, MD, PhD, Professor of Orthopaedic Surgery.  
*Dept of Orthopaedic Surgery, Asan Medical Center, University of Ulsan College of Medicine, Seoul, Republic of Korea.*
  - Jong Ki Shin, MD, Orthopaedic Fellow.
  - Tae Sik Goh, MD, MD, Orthopaedic Resident.
  - Jung Sub Lee, MD, Professor of Orthopaedic Surgery.  
*Medical Research Institute, Dept of Orthopaedic Surgery, Pusan National University School of Medicine, Busan, Republic of Korea.*

Correspondence : Jung Sub Lee, Medical Research Institute, Dept of Orthopaedic Surgery, Pusan National University School of Medicine, 1-10 Ami-Dong, Seo-Gu, Busan, Republic of Korea, 602-739. E-mail : jungsublee@pusan.ac.kr

© 2013, Acta Orthopædica Belgica.

underwent ACDF. Other authors also studied the problem (2,13,14). Only two groups (6,10) studied the effect of steroids, but they came to opposite conclusions. Therefore, the authors set up a randomized study comparing the effect of postoperative administration of corticosteroids (dexamethasone) with that of placebo.

## MATERIALS AND METHODS

A prospective randomized study was conducted on 62 consecutive patients, treated by one level ACDF for cervical radiculopathy between June 2009 and October 2011. There were 21 females and 41 males. The average age was  $47.1 \pm 7.8$  years.

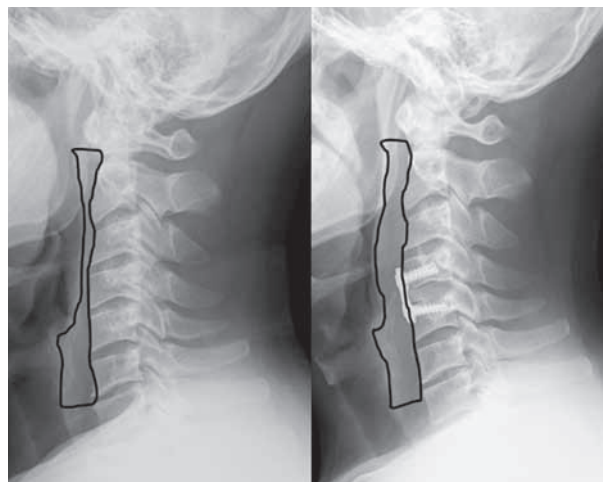
A classical Robinson-Smith left-sided anterior approach was used. The graft material consisted of allogeneous fibular cortical bone and 1 ml of demineralized bone matrix. Plate and screw fixation was added. A suction drain was used in all patients, and remained for 2 days. The exclusion criteria were radiculopathy requiring 2 level ACDF, myelopathic disease, cervical trauma and corpectomy. Litigious cases, i.e. traffic accidents and workers' compensation, were also excluded.

All patients were randomly assigned to 3 treatment groups (20, 20 and 22 persons), using admission chart numbers at surgery. The first dose was given immediately postoperatively, the subsequent doses 24 and 48 hours after the operation, all intravenously. Group 1 received 10/5/5 mg of dexamethasone; group 2: 20,10 and 10 mg; group 3 a placebo (normal saline). These dosages were based on the advice of pneumologists and otorhinolaryngologists. All patients received 50 mg of ranitidine intravenously after the main drug injection for gastric protection.

Plain lateral radiographs were taken preoperatively, immediately postoperatively, and then daily for 5 days after the operation. The area of the prevertebral soft tissue density was measured from the lower border of C1 to the upper end plate of C7 on the lateral radiographs using a PACS digital measuring instrument (Fig. 1). The distance from the cassette to the radiation tube was standardised.

Three independent observers measured the prevertebral soft tissue density; the measurements were repeated one week later. Both intra-observer and inter-observer reliabilities were evaluated using Pearson's correlation analysis.

The patients also completed a 10-point visual analog scale (VAS) for dyspnea and dysphagia, assisted by a



**Fig. 1.** — Preoperative and postoperative lateral radiographs showing the prevertebral soft tissue density.

physician who was not involved in the operation: immediately postoperatively, and then daily for 5 days after the operation.

Statistical analysis was performed with SPSS 11.5 software for Windows (SPSS, Chicago, IL, USA). Data were expressed as means  $\pm$  standard deviation. Non-continuous variables were compared by means of a chi-square test. Groups were compared by means of the ANOVA test and the Kruskal-Wallis test, as appropriate. The post-test (Dunns or Bonferroni test) was used to analyze individual group differences. The correlations in each group were tested with the Pearson's and Spearman's test, as appropriate. A  $p < 0.05$  was regarded as statistically significant.

## RESULTS

The 3 groups did not differ statistically with regard to age, gender, weight, length, smoking habits, duration of surgery and fusion level (Table I). The means for preoperative and postoperative measurements of prevertebral soft tissue, VAS for dysphagia and VAS for dyspnea are recorded in Table II. No patient needed reintubation due to acute airway obstruction caused by soft tissue swelling.

Table II shows the evolution of the 3 variables. The 3 groups did not differ statistically with regard to the surface of the prevertebral soft tissue density and VAS for dysphagia, at any time. However,

Table I. — Patients' demographics

	Group 1	Group 2	Group 3	<i>p</i>
Age in years	45.6 ± 7.3	46.9 ± 8.6	48.8 ± 7.6	0.403
F/M (n)	6/14	9/11	6/16	0.435
Weight (kg)	67.6 ± 6.7	66.1 ± 7.6	69.4 ± 7.6	0.349
Height (cm)	168.8 ± 4.6	167.4 ± 5.4	169.3 ± 5.1	0.437
Smokers	9	8	8	0.850
Duration of surgery (min)	79.3 ± 12.1	79.8 ± 13.6	77.3 ± 13.0	0.804
Fusion level (n)				
4-5/5-6/6-7	2/9/9	3/8/9	2/11/9	0.957

Table II. — Serial measurements of prevertebral soft tissue density, VAS for dysphagia and VAS for dyspnea

	Preop.	Immediately postop.	Day 1	Day 2	Day 3	Day 4	Day 5
Prevertebral soft tissue density (cm <sup>2</sup> )							
Group 1	477 ± 101	1533 ± 224	1699 ± 258	1865 ± 318	1886 ± 282	1776 ± 307	1576 ± 292
Group 2	485 ± 95	1520 ± 226	1689 ± 248	1836 ± 321	1867 ± 282	1747 ± 251	1541 ± 305
Group 3	479 ± 115	1629 ± 229	1789 ± 267	1963 ± 338	1966 ± 302	1853 ± 301	1706 ± 335
<i>p</i> value	0.971	0.237	0.387	0.419	0.501	0.473	0.202
VAS for dysphagia							
Group 1		1.9 ± 0.9	2.9 ± 1.0	2.5 ± 0.9	1.8 ± 0.9	1.2 ± 0.7	0.6 ± 0.6
Group 2		1.9 ± 0.7	3.0 ± 0.8	2.6 ± 1.1	2.0 ± 0.9	1.5 ± 0.7	1.0 ± 0.6
Group 3		1.9 ± 0.8	3.0 ± 0.8	2.5 ± 1.0	2.0 ± 1.1	1.4 ± 1.0	1.0 ± 1.0
<i>p</i> value		0.970	0.810	0.936	0.792	0.353	0.078
VAS for dyspnea							
Group 1		1.0 ± 0.6	1.8 ± 0.7	2.0 ± 0.8	1.8 ± 0.7	1.0 ± 0.9	0.6 ± 0.7
Group 2		0.9 ± 0.6	1.9 ± 0.7	1.9 ± 0.7	1.8 ± 0.6	1.0 ± 0.7	0.5 ± 0.6
Group 3		1.4 ± 0.7	2.4 ± 0.8	2.5 ± 0.9	1.6 ± 0.7	1.1 ± 0.8	0.6 ± 0.7
<i>p</i> value		0.018*	0.043*	0.027*	0.695	0.833	0.653

\* significant.

group 1 and 2 showed significant reduction in VAS for dyspnea compared to group 3, immediately postoperatively and on the first and second post-operative day. There was no significant difference between group 1 and 2 as to VAS for dyspnea.

In all 3 groups there was no correlation between gender, smoking habits, operative duration, fusion level, and degree of soft tissue swelling, at any time. Neither was there within the 3 groups any correlation between soft tissue swelling, VAS for dysphagia, and VAS for dyspnea, at any time.

The mean Pearson's correlation coefficients for intra-observer and inter-observer reliability were very high, at 0.912 and 0.899 respectively.

## DISCUSSION

### Incidence and risk factors

One of the most dangerous complications after anterior cervical spine surgery is acute airway obstruction. Although the incidence of acute airway

obstruction is low (cf. infra), it is a potentially lethal condition. Several authors (2,7,8,13,14) reported airway change and obstruction after anterior cervical surgery. Emery *et al* (7) reported seven patients who had upper airway obstruction after multilevel cervical corpectomy. The airway obstruction was due to oedema rather than haematoma, and the risk factors were smoking habit and asthma. Sagi *et al* (13) retrospectively assessed the factors affecting airway complications after anterior cervical spine surgery. The risk factors were exposure of more than 3 vertebral bodies, blood loss more than 300 ml, exposure of higher levels (C2, C3 or C4) and operative time more than 5 hours. The incidence of airway obstruction was 6.1%, the incidence of reintubation 1.9%. Epstein *et al* (8) assessed the risk factors for delayed extubation or tracheostomy in patients who underwent multilevel anterior and posterior surgery: prolonged operative time, obesity, transfusion, anterior reoperation, anterior procedure up to C2, 4 level surgery and asthma.

### Effect of steroids

Postoperative airway swelling has been described after thyroidectomy, upper oropharyngeal procedures, and anterior cervical spine surgery. Intravenous steroids have been used clinically in an attempt to control postoperative upper airway oedema. However, there are only a few studies about the effect of steroids on reducing prevertebral soft tissue swelling after anterior cervical spine surgery (6,10), and until now their effect remains controversial. Indeed, Pedram *et al* (10) prospectively studied 236 patients who underwent anterior cervical spine surgery: 158 control patients received nothing and 78 patients received 3 doses of steroids perioperatively. Oedema of hypopharynx and larynx were assessed fiberoptically. They found that the mucosal lesions were more severe in the control group than in the steroid group and they recommended steroids. However, Emery *et al* (6) came to the opposite conclusion. They prospectively evaluated 66 patients who underwent 2 or 3 level anterior cervical corpectomy. Thirty-five patients received 3 doses of intravenous dexamethasone, while 31 patients received saline. They noted that 5 out of

35 patients (14%) in the steroid group and 6 out of 31 (19%) in the saline group required delayed extubation, but the difference was not significant. They did not recommend intravenous steroids for the prevention of delayed extubation after multilevel anterior cervical corpectomy. The current study shows that steroids, in higher or lower dose, are not effective in reducing postoperative prevertebral soft tissue density or VAS for dysphagia, but are effective in reducing VAS for dyspnea, immediately postoperatively and during the first 2 postoperative days. A weakness of this study was the fact that the steroids were not administered preoperatively.

### Intubation

Suk *et al* (14) prospectively assessed prevertebral soft tissue swelling after 1 or 2 level ACDF, during the first 5 postoperative days. They concluded that the peak prevertebral soft tissue swelling occurred on the third day and recommended to maintain the intubation as long as 3 days, rather than just overnight, if a patient was anyway planned to remain intubated after a long and difficult procedure above C5. Also the authors found that the prevertebral soft tissue swelling peaked on the third postoperative day. However, clinical symptoms such as dysphagia and dyspnea did not correspond to this radiological finding: indeed, VAS for dysphagia and VAS for dyspnea peaked on the first and second day in all 3 groups, which suggests that the duration of intubation after anterior cervical spine surgery remains controversial.

### REFERENCES

1. Andrew SA, Sidhu KS. Cervical-peritoneal shunt placement for postoperative cervical pseudomeningocele. *J Spinal Disord Tech* 2005; 18: 290-292.
2. Andrew SA, Sidhu KS. Airway changes after anterior cervical discectomy and fusion. *J Spinal Disord Tech* 2007; 20: 577-581.
3. Boockvar JA, Philips MF, Telfeian AE, O'Rourke DM, Marcotte PJ. Results and risk factors for anterior cervicothoracic junction surgery. *J Neurosurg* 2001; 94 (1 suppl): 12-17.
4. Chang HS, Kondo S, Mizuno J, Nakagawa H. Airway obstruction caused by cerebrospinal fluid leakage after anterior cervical spine surgery. A report of two cases. *J Bone Joint Surg* 2004; 86-A: 370-372.

5. **DeBehnke DJ, Havel CJ.** Utility of prevertebral soft tissue measurements in identifying patients with cervical spine fractures. *Ann Emerg Med* 1994 ; 24 : 1119-1124.
6. **Emery SE, Akhavan S, Miller P et al.** Steroids and risk factors for airway compromise in multilevel cervical corpectomy patients : a prospective, randomized, double-blind study. *Spine* 2009 ; 34 : 229-232.
7. **Emery SE, Smith MD, Bohlman HH.** Upper-airway obstruction after multilevel cervical corpectomy for myelopathy. *J Bone Joint Surg* 1991 ; 73-A : 544-551.
8. **Epstein NE, Hollingsworth R, Nardi D, Singer J.** Can airway complications following multilevel anterior cervical surgery be avoided ? *J Neurosurg* 2001 ; 94 (2 suppl) : 185-188.
9. **Krnacik MJ, Heggeness MH.** Severe angioedema causing airway obstruction after anterior cervical surgery. *Spine* 1997 ; 22 : 2188-2190.
10. **Pedram M, Castagnera L, Carat X, Macouillard G, Vital JM.** Pharyngolaryngeal lesions in patients undergoing cervical spine surgery through the anterior approach : contribution of methylprednisolone. *Eur Spine J* 2003 ; 12 : 84-90.
11. **Penberthy A, Roberts N.** Recurrent acute upper airway obstruction after anterior cervical fusion. *Anaesth Intensive Care* 1998 ; 26 : 305-307.
12. **Riew KD, Sethi NS, Devney J, Goette K, Cjoi K.** Complications of buttress plate stabilization of cervical corpectomy. *Spine* 1999 ; 24 : 2404-2410.
13. **Sagi HC, Beutler W, Carroll E, Connolly PJ.** Airway complications associated with surgery on the anterior cervical spine. *Spine* 2002 ; 27 : 949-953.
14. **Suk KS, Kim KT, Lee SH, Park SW.** Prevertebral soft tissue swelling after anterior cervical discectomy and fusion with plate fixation. *Int Orthop* 2006 ; 30 : 290-294.