



## Intra-abdominal fluid after hip arthroscopy : A case report

JORIS JAEKERS, JAN VAN MELKEBEEK, MARC VAN CLEEMPUT, ROGER VAN RIET

*From the Department of Orthopaedics and Surgery, AZ Monica and the Monica Orthopaedic Research (MoRe) Foundation, Deurne, Belgium*

**The use of hip arthroscopy for diagnostic and therapeutic reasons has been steadily increasing over the last decade. It is considered a safe procedure, but some complications may be potentially life threatening. We present a case of intra-abdominal accumulation of irrigation fluid during hip arthroscopy in a 26-year-old patient. A literature review revealed only six other cases of fluid extravasation and its potentially dangerous consequences. The use of transparent sterile dressings during surgery might help early recognition of this unusual complication.**

**Keywords :** arthroscopy ; hip ; complication ; FAI.

### INTRODUCTION

In recent years, hip arthroscopy has become a common surgical procedure for both diagnostic as well as therapeutic indications. The complication rate is low and it is therefore considered a reasonably safe technique. However, although most complications are minor, some are potentially life-threatening (3,14). We would like to report a case of a very rare, but severe complication during hip arthroscopy.

### CASE REPORT

An arthroscopy of the left hip was performed in a 26-year-old male patient. The indication for surgery was a cam-type femoro-acetabular impingement. There was no relevant medical history. The

patient had undergone a successful procedure on the right side three months before, for the same pathology.

The patient was placed in supine position on a traction table ; the hip was disinfected and covered with sterile dressings in a standard fashion. Three standard portals were made ; anterior, anterolateral and maximal mid-anterior. Saline infusion was done using a flow- and pressure controlled pump with a starting pressure of 70 mmHg. During surgery, pressures never exceeded 90 mmHg. There were no technical problems with the procedure or the equipment used.

Standard monitoring of blood pressure, blood oxygen saturation, capnography and electrocardiogram were performed. There was no measurement of core body temperature. All vital parameters remained within normal range during the procedure which lasted 35 minutes.

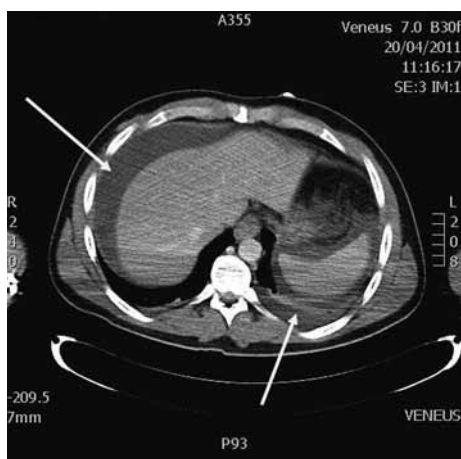
On removal of the sterile dressings postoperatively, a severely distended abdomen was noted.

- 
- Joris Jaekers, MD, resident general surgery.
  - Jan Van Melkebeek, MD, orthopedic surgeon.
  - Marc Van Cleemput, MD, general surgeon.
  - Roger van Riet, MD, PhD, orthopedic surgeon.

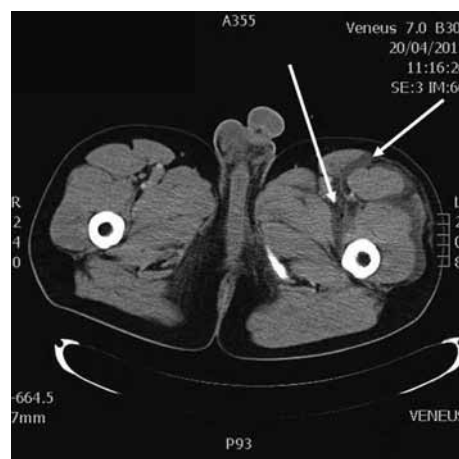
*Department of Orthopaedics and Surgery, AZ Monica and Monica Orthopaedic Research (MoRe) Foundation, Deurne, Belgium.*

Correspondence : Roger van Riet, Department of Orthopaedic Surgery, Monica Hospital, Stevenslei 20, 2100 Antwerp, Belgium. E-mail : drrogervanriet@azmonica.be

© 2012, Acta Orthopædica Belgica.



**Fig. 1.** — Computed tomography image of the abdomen showing free fluid in the abdomen surrounding the liver and spleen respectively (upper and lower white arrows).



**Fig. 2.** — Computed tomography image of the abdomen showing fluid infiltration in and around the thigh musculature on the left side (white arrows).

The decision was made to wake the patient and perform a clinical examination and anamnesis. When the patient regained consciousness, he complained of an uncomfortable feeling in the abdomen, but no pain. The abdomen was hard to the touch and shifting dullness could be heard on percussion of the abdomen. Normal bowel sounds were noted. A urethral catheter was placed to measure the bladder pressure as an indication of the intra-abdominal pressure: the readings showed a mean pressure of 9 mmHg (normal range 0 mmHg to 7 mmHg in a young, healthy individual) (10).

Arterial blood gas analysis revealed a pH of 7.149, pCo<sub>2</sub>: 54.0 kPa, Po<sub>2</sub>: 220.0 kPa, SpO<sub>2</sub>: 99.1%, base-deficit: -8.2, Hb: 14.5 g/dl.

Since the patient's vital signs showed no haemodynamic instability, a computed tomography of the abdomen was performed with administration of intravenous contrast.

A large quantity of free intra-abdominal fluid could be seen reaching the diaphragm on both sides. Furthermore, fluid infiltration was noted throughout the musculature of the left thigh (Figs. 1 & 2). Free air was observed following the contour of the left iliopsoas muscle. There was no distention of gastrointestinal structures and no renal congestion was found.

Treatment options were discussed with the patient; it was decided to perform a diagnostic

laparoscopy to evaluate the potential intra-abdominal damage and to remove the fluid excess. Peroperatively a perforation of the retroperitoneal space was observed on the left side. There was substantial fluid infiltration of the tissues in the left lateral abdominal wall and left fossa iliaca with some infiltration through Toldt's fascia. No critical intra-abdominal or gastro-intestinal lesions were observed. A large quantity (1.6 liter) of clear fluid was evacuated through a suction cannula. A Penrose drain was left in place for postoperative monitoring and further drainage of the remaining intra-abdominal fluid.

The patient had an uncomplicated recovery, and he was discharged from hospital 2 days postoperatively. At a routine check-up one month postoperatively, he had no residual abdominal complaints.

## DISCUSSION

Hip arthroscopy is considered a safe and low-risk procedure if performed by an experienced orthopaedic surgeon. The complication rate is reportedly 0.5% to 6.4% (3,14).

Most frequent complications include transient nerve palsy and perineal injury (due to distraction of the hip joint during the procedure), portal wound bleeding or haematoma, trochanteric bursitis and instrument breakage. Furthermore, iatrogenic

damage to neurovascular structures, chondral and labral damage have been reported. A rare, but potentially very dangerous complication is extravasation of the infusion fluid into extracapsular spaces, such as the retro peritoneum or intra-abdominal cavity (3,5,9, 13,14).

Up to this date only 6 other cases of fluid extravasation have been reported in literature. The first report was made by Bartlett *et al* in 1998. Fluid extravasation to the abdomen occurred whilst trying to retrieve loose bodies in the hip joint 12 days after open reduction and internal fixation of an acetabular fracture. The patient developed a cardiac arrest and died postoperatively (1). Verma and Sekiya reported a second case of a 21-year old female patient who underwent hip arthroscopy on the right side for femoro-acetabular impingement in 2010. After surgery an extensive amount of fluid in the abdomen and bilateral pleural effusions were found on CT scan. The treatment was conservative and the patient recovered fully from her operation (16). Haupt *et al* reported in 2008 a case in which intra-abdominal fluid accumulation was noticed, without any direct consequences for the patient (6). Sharma *et al* (2009) and Fowler *et al* (2010) both described a case of emergency laparotomy following an abdominal compartment syndrome after hip arthroscopy (5,12). Ladner *et al* described another case of limited fluid accumulation in the abdomen which was observed and treated with intravenous administration of furosemide (8).

Although this complication is very rare, it can be dangerous and potentially life threatening. There is no clear explanation for the mechanism of fluid travel during hip arthroscopy. The most likely mechanisms are a path along the iliopsoas muscle after opening the tendon sheath of the iliopsoas and/or a congenital existing path along the iliac neuro-vascular bundle. In some patients a congenital communication between the retro- and intraperitoneal spaces may exist or excessive fluid pressure during the arthroscopy might cause a tear in the peritoneum allowing the fluid to drain to the intra-peritoneal space (5,6,8,16).

At normal irrigation pressures, this is very unlikely, and as Haupt *et al* reported in their article, pressure deregulation and increasing infusion pres-

sure may cause the path along the iliopsoas muscle of femoral canal to be formed (6,8,12,15).

Other possible causes of fluid extravasation may include the following : increased irrigation pump pressure, prolonged surgery time and capsulotomy or tenotomy of the iliopsoas muscle. Performing a hip arthroscopy following an acetabular fracture can therefore also be seen as a formal contra-indication for this procedure (5,6,8,12,15,16).

During surgery, some warning signs may alert the surgeon to a possible fluid leak or extravasation : inability to distend the joint, increased fluid requirements to maintain joint distention, frequent cutoff of the pump's irrigation system, distention of the abdomen and / or thigh and hypothermia. If one or more of these signs are present during the procedure, the surgeon should always be cautious of possible problems (6,8).

Some authors proposed the intra-operative decrease of body temperature as an other warning sign. Monitoring of body temperature however can be seen as providing a relatively unspecific information since many of the patients undergoing hip arthroscopy may exhibit a certain degree of hypothermia because the infusion fluids which are used are at room temperature (6,8,12).

It is important to remember that complications such as fluid extravasation and compartment syndrome are not only reserved for arthroscopic procedures on the hip joint. Case reports of compartment syndromes of the lower leg, fluid accumulation in the thigh and even intra- and extra peritoneal accumulation of fluid after knee arthroscopy have been reported in literature (2,11).

A study of De Wachter *et al* concerning the surrounding soft tissue pressure during shoulder arthroscopy showed elevated pressures in the deltoid- and supraspinatus muscles during arthroscopic subacromial decompression to levels which exceeded the values which are thought to induce a compartment syndrome. Furthermore they measured paratracheal pressures during the same procedure on forty patients : five patients showed significant elevation of the paratracheal pressure with risk of tracheal compression (4).

The extravasation of irrigation fluid in the abdomen itself may be a minor problem as long as

it is noticed in time by the surgeon. A healthy patient is capable of rapidly resorbing the extravasated fluid due to the large surface area of the peritoneum (10,16). As long as there are no haemodynamic or abdominal effects, treatment can be conservative and observation or administration of furosemide can be sufficient (7,10,15,16). These options were discussed with the patient but it was decided to perform a diagnostic laparoscopy.

If extravasation is not noticed and a large amount of fluid accumulates in the abdomen, the situation could become more severe. The distention can create intra-abdominal hypertension (IAH: sustained or repeated elevation of intra-abdominal pressure above or equal to 12 mmHg) or an abdominal compartment syndrome (ACS: sustained intra-abdominal pressure above 20 mmHg with new organ dysfunction or failure). These entities may result in: a) venous compression within the abdomen causing a decreased venous return to the heart which may cause haemodynamic instability, b) decreased splanchnic circulation, c) elevated respiratory pressures and d) renal failure. Hypothermia and pressure related damage to intra-abdominal organs are other possible disastrous outcomes. In these cases a more aggressive treatment approach is advisable (7,10,15,16).

Since the incident we have become more vigilant towards this phenomenon and as an added safety measure, we have started to use transparent sterile dressings during surgery. This permits the surgeon to regularly check the abdomen for distention. Although the incidence of this complication is very low, we would like to propose this as a safety measure for all arthroscopic procedures of the hip as it is an easy way of preventing this potentially life-threatening complication.

## REFERENCES

- Bartlett CS, DiFelice GS, Buly RL et al.** Cardiac arrest as a result of intraabdominal extravasation of fluid during arthroscopic removal of a loose body from the hip joint of a patient with an acetabular fracture. *J Orthop Trauma* 1998 ; 12 : 294-299.
- Bomberg BC, Hurley PE, Clark CA, McLaughlin CS.** Complications associated with the use of an infusion pump during knee arthroscopy. *Arthroscopy* 1992 ; 8 : 224-228.
- Clarke MT, Arora A, Villar RN.** Hip arthroscopy : Complications in 1054 cases. *Clin Orthop Relat Res* 2003 ; 406 ; 84-88.
- De Wachter J, Van Glabbeek F, Van Riet R et al.** Surrounding soft tissue pressure during shoulder arthroscopy. *Acta Orthop Belg* 2005 ; 71 : 521-527.
- Fowler J, Owens BD.** Abdominal compartment syndrome after hip arthroscopy. *Arthroscopy* 2010 ; 26 : 128-130.
- Haupt U, Völkle D, Waldherr C, Beck M.** Intra- and retroperitoneal irrigation liquid after arthroscopy of the hip joint. *Arthroscopy* 2008 ; 24 : 966-968.
- Ivatury RR, Sugeran HJ, Peitzman AB.** Abdominal compartment syndrome : recognition and management. *Adv in Surg* 2001 ; 35 : 251-269.
- Ladner B, Nester K, Cascio B.** Abdominal fluid extravasation during hip arthroscopy. *Arthroscopy* 2010 ; 26 : 131-135.
- Nwachukwu BU, McFeely ED, Nasreddine AY et al.** Complications of hip arthroscopy in children and adolescents. *J Pediatr Orthop* 2011 ; 31 : 227- 231.
- Papavramidis TS, Athanasios MD, Pliakos I, Kesisoglou I, Papavramidou N.** Abdominal compartment syndrome – Intra-abdominal hypertension : defining, diagnosing, and managing. *J Emerg Trauma Shock* 2011 ; 4 : 279-291.
- Romero J, Smit CM, Zanetti M.** Massive intraperitoneal and extraperitoneal accumulation of irrigation fluid as a complication during knee arthroscopy. *Arthroscopy* 1998 ; 14 : 401-404.
- Sharma A, Sachdev H, Gomillion M.** Abdominal compartment syndrome during hip arthroscopy. *Anaesthesia* 2009 ; 64 : 567-569.
- Simpson J, Sadri H, Villar R.** Hip arthroscopy technique and complications. *Orthop Traumatol Surg Res* 2010 ; 96S : 68-76.
- Smart LR, Oetgen M, Noonan B, Medvecky M.** Beginning hip arthroscopy : Indications, positioning, portals, basic techniques, and complications. *Arthroscopy* 2007 ; 23 : 1348-1353.
- Sugrue M, Buhkari Y.** Intra-abdominal pressure and abdominal compartment syndrome in acute general surgery. *World J Surg* 2009 ; 33 : 1123-1127.
- Verma M, Sekiya JK.** Intrathoracic fluid extravasation after hip arthroscopy. *Arthroscopy* 2010 ; 26 : 90-94.