



Outcomes of percutaneous kyphoplasty in patients with intravertebral vacuum cleft

Ai Min WU, Wen Fei NI, Wei WENG, Yong Long CHI, Hua Zi XU, Xiang Yang WANG

From the Second Affiliated Hospital of Wenzhou Medical College, Wenzhou, ZheJiang, China

An intravertebral vacuum cleft (IVC) is not an uncommon finding ; it is more likely to occur in patients with osteoporotic vertebral compression fractures (OVCF). There are scarce data on the treatment of these patients with percutaneous balloon kyphoplasty (PKP). Between August 2005 and March 2010, 35 single vertebral fracture patients with an IVC sign were treated by PKP. Visual Analogue Score (VAS), Oswestry Disability Index (ODI), Kyphotic Angulation (KA), and Compression Ratio (CR) improved significantly postoperatively ($p < 0.05$). These values were maintained at the one year follow-up. Balloon kyphoplasty leads less often to leakage (here in only 14.3% of the patients) than vertebroplasty (in 75% according to the literature). On the other hand, balloon kyphoplasty seems to predispose to intradiscal leakage : here in 3 out of 5 cases. This may cause a compression fracture of the adjacent vertebra.

Keywords : vertebral compression fracture ; intravertebral vacuum cleft ; vertebroplasty ; percutaneous balloon kyphoplasty ; minimally invasive.

INTRODUCTION

The intravertebral vacuum cleft (IVC) is not a rare phenomenon. It occurs most frequently in osteoporotic vertebral compression fractures (OVCFs). Its incidence increases, as the population is aging. The advent of CT-scan and MRI has facilitated the detection.

Most authors treat osteoporotic fractures accompanied by an intravertebral vacuum cleft, with percutaneous vertebroplasty (PVP). It has been suggested that the co-existence of a cleft improves the correction of the kyphosis (2,17,21). However, the efficacy of PVP in IVC patients is controversial (3,6,19,25), and a high incidence of cement leakage is reported (6,18). Percutaneous balloon kyphoplasty (PKP) is reported to lead to excellent results in OVCF patients (10,23), but there are scarce data on its effect in the presence of a cleft. The authors studied its efficacy in 35 patients with an IVC sign treated by PKP.

-
- Ai Min Wu, MD, Resident.
 - Wen Fei Ni, MD, PhD, Associate Chief.
 - Wei Weng, MD, Resident.
 - Yong Long Chi, MD, Professor.
 - Hua Zi Xu, MD, Professor, Chief.
 - Xiang Yang Wang, MD, PhD, Professor, Dept Chief.
- Department of Spinal Surgery, Second Affiliated Hospital of Wenzhou Medical College, Wenzhou, ZheJiang, China.*
- Correspondence : Wen Fei NI, Department of Orthopaedic Surgery, ZheJiang Spine Research Center, Second Affiliated Hospital of Wenzhou Medical College, 109# XueYuanXi Road, 325027 WenZhou, ZheJiang, China.
- E-mail : wenfeini@yeah.net
- © 2012, Acta Orthopædica Belgica.
-

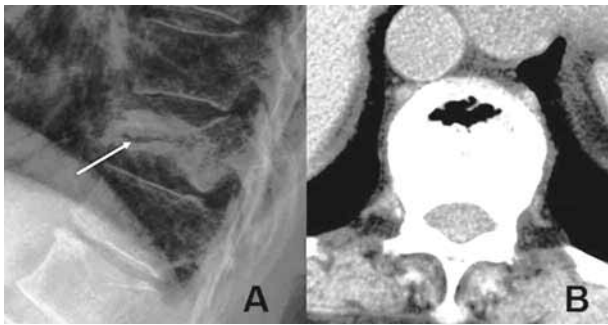


Fig. 1A&B. — A : plain lateral radiograph showing an intravertebral vacuum cleft as a transverse, linear radiolucent area (arrow) ; B : CT-scan : same.

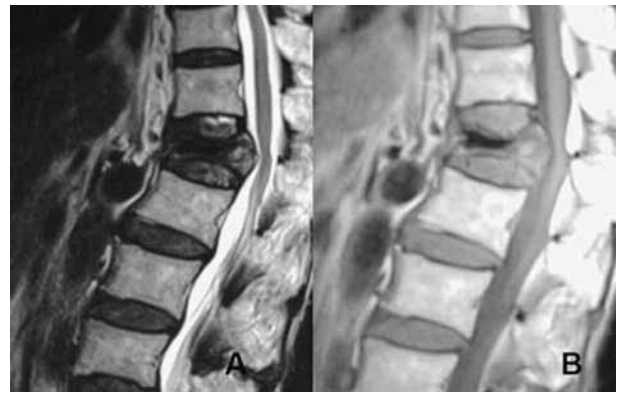


Fig. 2. — A : sagittal T2-weighted MR image showing a low signal intensity in the location of the cleft (classically, one would expect a high signal intensity) ; B : sagittal T1-weighted MR image also showing a low intensity.

MATERIALS AND METHODS

Demographics

The authors saw 398 patients with vertebral compression fractures between August 2005 and March 2010. Thirty-five of these (24 females and 11 males) had a single fracture with an intravertebral cleft (IVC) ; idiopathic osteoporosis was at the origin in 31, and steroid treatment in 4. The mean duration of complaints was 6.3 months (range : 1 month to 6 years). Analgesics and bed rest had been tried for at least one month, without result. The average age at operation was 72.5 years (range : 62 to 84). The involved vertebrae were : T7 (2 cases), T8 (1 case), T10 (2 cases), T11 (4 cases), T12 (7 cases), L1 (11 cases), L2 (6 cases), L3 (2 cases).

The mean follow-up duration was 26.8 months (range : 12-56 months).

The diagnostic criteria for intravertebral cleft (IVC) were : 1. a transverse, linear or semi-lunar radiolucent area on plain radiographs or CT (Fig. 1) ; 2. a low-signal intensity on T1-weighted images, and a high-signal intensity on T2-weighted images and Short Tau Inversion Recovery (STIR) images (Fig. 2). Two experienced radiologists decided about the presence of an intravertebral cleft.

Bone mineral density (BMD) was measured routinely by means of dual-energy x-ray absorptiometry (DEXA).

Operative procedure

All patients were treated with percutaneous kyphoplasty (PKP), under local or general anaesthesia, in the prone position, with soft pads under the chest and the

pelvis. Needles, 11 or 13 gauge, were inserted transpedicularly, on both sides, under fluoroscopic control. Subsequently, they were exchanged over a guide wire for working cannulas. Balloon tamps were now inserted through the cannulas and inflated under fluoroscopic and manometric control. The inflation was stopped when the pressure reached 300 psi or when the balloon made contact with the end-plate. Then, the balloons were deflated and withdrawn. Polymethylmethacrylate (PMMA) cement was injected to fill the cavity as soon as it reached the “toothpaste” viscosity. Continuous fluoroscopic monitoring was performed during injection to survey the extravasation of cement. All patients were mobilized 12 to 24 hours after the procedure. Calcium, vitamin D and bisphosphonates (alendronate) were administered.

Clinical and radiological variables

A Visual Analogue Score (VAS) for back pain and an Oswestry Disability Index (ODI) were obtained before the start of analgesic treatment, immediately preoperatively, postoperatively, and at last follow-up, after one year. Kyphotic Angulation (KA) and Compression Ratio (CR) of the vertebral body were measured by means of the digital STARPACS system, preoperatively, postoperatively, and at last follow-up. The KA was measured between the superior end-plate and the inferior end-plate of the fractured vertebra (Fig. 3). The CR (Fig. 3) was calculated according to the following formula : CR =

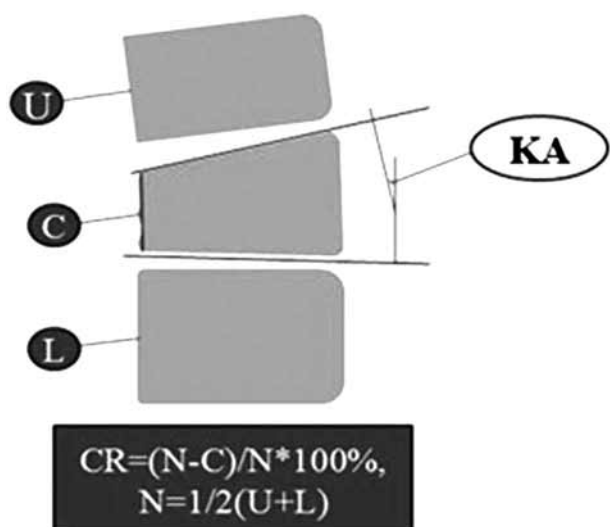


Fig. 3. — The Kyphosis Angulation (KA) and the Compression Ratio (CR) : see “Clinical and radiological variables”.

$(N - C) / N \times 100\%$, wherein $N = (U + L) / 2$, while N is the estimated normal anterior height of the fractured vertebra, U is the anterior height of the proximal adjacent vertebra, L is the anterior height of the distal adjacent vertebra, C is the anterior height of the fractured vertebra.

Classification of cement opacification

The cement patterns of opacification were classified according to Lane *et al* (11) : 1. a “cleft pattern of opacification” means opaque cement filling the intravertebral cleft (Fig. 4A) ; 2. a “trabecular pattern of opacification” means opaque cement interspersed throughout the trabecular space (Fig. 4B) ; 3. a mixed pattern of opacification represents opaque cement filling the intravertebral cleft in the center and interspersed throughout the trabecular space in the periphery (Fig. 4C). Complications such as cement leakage and adjacent fracture were also recorded.

Statistical analysis

The data were analyzed with standard software : SPSS, version 17.0, SPSS Inc., Chicago, Illinois, USA. The preanalgesic, preoperative, postoperative and final data were tested by the “repeated-measures analysis of variance” (ANOVA). The level of significance was set at $p < 0.05$.

RESULTS

The mean operative time was 45 minutes (range : 25 to 110). Ten patients lost about 50 ml of blood ; all others lost less than 10 ml, which was negligible.

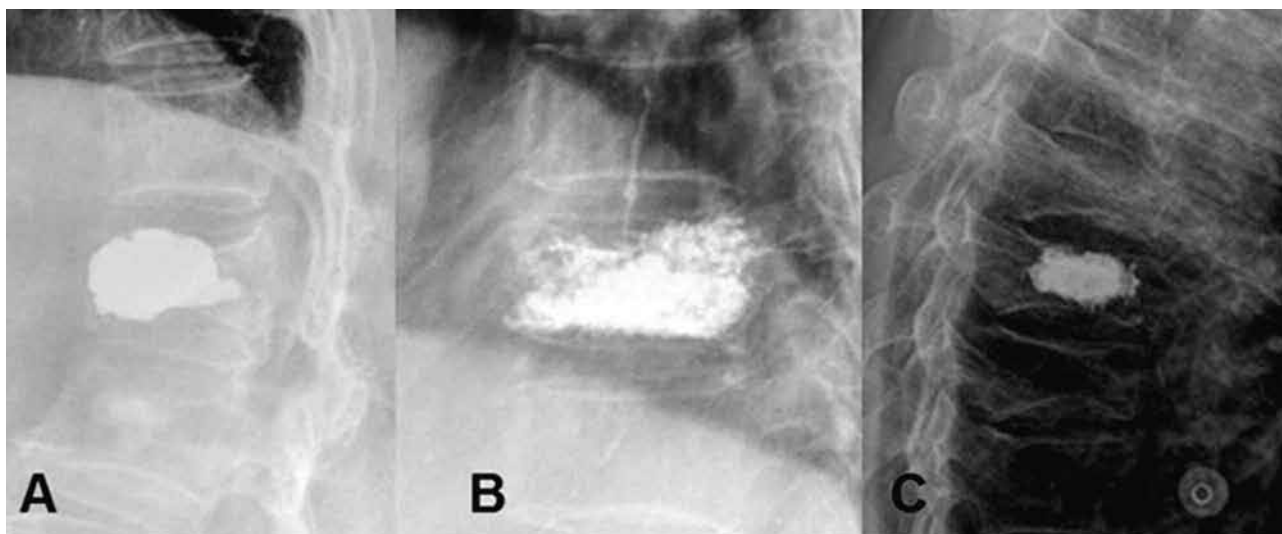


Fig. 4. — The patterns of cement opacification : A. cleft pattern ; B. trabecular pattern ; C. mixed pattern

Table I. — VAS, ODI, Kyphotic Angulation (KA), and Compression Ratio (CR) (N = 35)

	preanalgesic value	preoperative value	postoperative value	value at last follow-up
VAS	8.43 ± 0.54	8.19 ± 0.70 ^a	3.01 ± 0.94 ^b	2.69 ± 0.80 ^c
ODI	84.41 ± 4.99	83.88 ± 5.68 ^a	27.71 ± 6.15 ^b	26.65 ± 5.11 ^c
KA (°)	–	16.85 ± 7.13	8.79 ± 4.72 ^b	9.16 ± 4.61 ^c
CR (%)	–	39.62 ± 14.00	20.78 ± 11.26 ^b	21.37 ± 12.68 ^c

^a: $p > 0.05$, compared with preanalgesic value ; ^b: $p < 0.05$, compared with preoperative value ; ^c: $p > 0.05$, compared with post-operative value.

On an average 4.8 ml (range : 3 to 7.5) of polymethylmethacrylate (PMMA) was injected.

Improvement of VAS, ODI, Kyphotic Angulation (KA), and Compression Ratio (CR)

All these variables improved significantly ($p < 0.05$) (Table I) after injection, and these values were maintained at the one year follow-up ($p > 0.05$). Interestingly, conservative treatment did not improve VAS or ODI ($p > 0.05$).

Patterns of cement opacification

Twenty-three vertebrae (65.7%) showed a cleft pattern, 3 vertebrae a trabecular pattern, and 9 vertebrae a mixed pattern.

Complications

Two anterior and 3 intervertebral (intradiscal) leaks were noted, all without problems. No leaks into the vertebral canal or into the venous system were seen. Embolic events or neurosurgical complications did not occur. One woman with intradiscal leakage complained of back pain after 3 months ; there was a fracture of the proximal adjacent vertebra, which was treated with kyphoplasty.

DISCUSSION

Intravertebral cleft sign

The IVC sign was first reported by Maldague *et al* (14) ; Theodorou (22) and Sarli *et al* (20) subsequently described the details of this phenomenon.

It appears as a transverse, linear or semi-lunar radiolucent area on plain radiographs and it may induce instability. The diagnosis is more frequently made since CT and MRI have become routine. Usually, the cleft will appear smaller or even disappear in the standing position, but it will appear larger in the supine position, so that this position facilitates the diagnosis with plain radiographs. McKiernan *et al* (16) found that the accuracy of plain radiographs was 16% in the standing position, while it increased to 64% in the supine position. MRI granted an accuracy of 96% ; in addition, continued supine position led to fluid collection in the cleft (13). Malghem *et al* (15) noted that progressive changes in the content of the cleft occurred within one hour after the patients were placed in a supine position. Initially, the cleft showed a gas-like pattern during extension of the spine, with a radiolucent band on plain radiographs and a signal void on MRI images. Later, the vacuum phenomenon disappeared on radiographs, and a fluid-like high-signal-intensity pattern appeared on T2- or T2*-weighted MRI images, suggestive of a slow fluid inflow within the intravertebral cleft. Also Linn *et al* (13) noted that the high fluid signal appeared on MRI during repeated measurements after 5 and 6 minutes in acute vertebral fracture patients.

Pain

Analgesics and bed rest had no effect in the current study. Ha *et al* (6) reported that IVC patients had less reduction of pain and more inconvenience in daily life after vertebroplasty (PVP) than those without it. Moreover, Peh *et al* (19) stressed that 4 out of 18 IVC patients were not improved or even

worse after vertebroplasty. Wiggins *et al* (25) came to the same conclusion in 5 out of 15 patients. They felt that merely filling the IVC might not be adequate in some patients, because the rest of the vertebral body would remain unsupported, causing further pain. Kim *et al* (8) did not accept this hypothesis : CT-scans showed that the cement filling was equally perfect in satisfied and dissatisfied patients. Moreover, Chen *et al* (3) mentioned pain relief in 27 patients with IVC after vertebroplasty. Also Krauss *et al* (9) found that after vertebroplasty patients with IVC had the same pain reduction as patients without it. In short, vertebroplasty remains controversial.

In the current study all patients experienced partial or total pain relief after balloon kyphoplasty, and 21 out of 35 (60%) even reached an improvement of the VAS score with 5 marks. This pleads for the efficiency of this technique. Wang *et al* (24) stressed that, according to the literature, pain relief in IVC patients was more constant after balloon kyphoplasty than after vertebroplasty.

Correction of kyphosis

Vertebroplasty improves the kyphotic deformity in IVC patients (6,8,9). Sun *et al* (21) obtained a correction of 5.4° with this technique in patients with IVC. With balloon kyphoplasty Grohs *et al* (5) obtained a correction of about 3°, merely via the prone position, and a further 6° after balloon kyphoplasty. They noted a mean correction of 8.06° with balloon kyphoplasty. They believe that this technique ensures a better correction than vertebroplasty, a hypothesis which is consistent with the literature study of Wang *et al* (24).

Leakage

An intravertebral cleft seems to facilitate cement leakage, at least after vertebroplasty : Ha *et al* (6) noted cement leakage in 9 out of 12 (75%) IVC patients, but in only 24 out of 58 patients (32.6%) without IVC. Also Nieuwenhuijse *et al* (18) identified the IVC sign on MRI as a strong risk factor of cement leakage after vertebroplasty : it occurred in 75.1% of their cases. However, balloon kypho-

plasty avoids this negative effect in IVC patients : Wang *et al* (24) reported only 7.4% cement leakage in their 27 patients. The current study confirms this trend : cement leakage after balloon kyphoplasty occurred in only 14.3% of the patients, in spite of the presence of an IVC. The explanation is probably the fact that the cement is injected under lower pressure, because the balloon has created a cavity.

On the other hand, balloon kyphoplasty predisposes to intradiscal leakage : this occurred in 3 out of 5 cases in the current study. Indeed, patients with IVC often have an end-plate fracture which communicates with the cleft (1), and intradiscal leakage enhances new fractures at an adjacent level (4,12). This occurred in one of our patients, 3 months after treatment. Caution during the injection might avoid this problem.

Limitations

A limitation of this study is that patients are unwilling to come to hospital for follow-up after 3 months, a further follow-up of some patients is one year after operation, and some of them is two years after operation. Therefore, the interval of follow-up after 3 months is different between patients. Anyway, the fact that the postoperative values of VAS, ODI, KA and CR were practically maintained after one year, pleads for the efficiency of balloon kyphoplasty. Randomized large scale studies are necessary.

REFERENCES

1. Armingeat T, Pham T, Legre V, Lafforgue P. Coexistence of intravertebral vacuum and intradiscal vacuum. *Joint Bone Spine* 2006 ; 73 : 428-432.
2. Carlier RY, Gordji H, Mompoin DM *et al*. Osteoporotic vertebral collapse : percutaneous vertebroplasty and local kyphosis correction. *Radiology* 2004 ; 233 : 891-898.
3. Chen LH, Lai PL, Chen WJ. Unipedicle percutaneous vertebroplasty for spinal intraosseous vacuum cleft. *Clin Orthop Relat Res* 2005 ; 435 : 148-153.
4. Chen WJ, Kao YH, Yang SC *et al*. Impact of cement leakage into disks on the development of adjacent vertebral compression fractures. *J Spinal Disord Tech* 2010 ; 23 : 35-39.

5. **Grohs JG, Matzner M, Trieb K, Krepler P.** Treatment of intravertebral pseudarthroses by balloon kyphoplasty. *J Spinal Disord Tech* 2006 ; 19 : 560-565.
6. **Ha KY, Lee JS, Kim KW, Chon JS.** Percutaneous vertebroplasty for vertebral compression fractures with and without intravertebral clefts. *J Bone Joint Surg* 2006 ; 88-B : 629-633.
7. **Kim KT, Suk KS, Kim JM, Lee SH.** Delayed vertebral collapse with neurological deficits secondary to osteoporosis. *Int Orthop* 2003 ; 27 : 65-69.
8. **Kim YJ, Lee JW, Kim KJ et al.** Percutaneous vertebroplasty for intravertebral cleft : analysis of therapeutic effects and outcome predictors. *Skeletal Radiol* 2010 ; 39 : 757-766.
9. **Krauss M, Hirschfelder H, Tomandl B, Lichti G, Bär I.** Kyphosis reduction and the rate of cement leaks after vertebroplasty of intravertebral clefts. *Eur Radiol* 2006 ; 16 : 1015-1021.
10. **Kumar K, Nguyen R, Bishop S.** A comparative analysis of the results of vertebroplasty and kyphoplasty in osteoporotic vertebral compression fractures. *Neurosurgery* 2010 ; 67 (3 Suppl Operative) : 171-188.
11. **Lane JI, Maus TP, Wald JT et al.** Intravertebral clefts opacified during vertebroplasty : pathogenesis, technical implications, and prognostic significance. *Am J Neuro-radiol* 2002 ; 23 : 1642-1646.
12. **Lin EP, Ekholm S, Hiwatashi A, Westesson PL.** Vertebroplasty : cement leakage into the disc increases the risk of new fracture of adjacent vertebral body. *Am J Neuroradiol* 2004 ; 25 : 175-180.
13. **Linn J, Birkenmaier C, Hoffmann RT, Reiser M, Baur-Melnyk A.** The intravertebral cleft in acute osteoporotic fractures : fluid in magnetic resonance imaging-vacuum in computed tomography ? *Spine* 2009 ; 34 : E88-93.
14. **Maldague BE, Noel HM, Malghem JJ.** The intravertebral vacuum cleft : a sign of ischemic vertebral collapse. *Radiology* 1978 ; 129 : 23-29.
15. **Malghem J, Maldague B, Labaisse MA et al.** Intravertebral vacuum cleft : changes in content after supine positioning. *Radiology* 1993 ; 187 : 483-487.
16. **McKiernan F, Faciszewski T.** Intravertebral clefts in osteoporotic vertebral compression fractures. *Arthritis Rheum* 2003 ; 48 : 1414-1419.
17. **McKiernan F, Jensen R, Faciszewski T.** The dynamic mobility of vertebral compression fractures. *J Bone Miner Res* 2003 ; 18 : 24-29.
18. **Nieuwenhuijse MJ, Van Erkel AR, Dijkstra PD.** Cement leakage in percutaneous vertebroplasty for osteoporotic vertebral compression fractures : identification of risk factors. *Spine J* 2011 ; 11 : 839-848.
19. **Peh WC, Gelbart MS, Gilula LA, Peck DD.** Percutaneous vertebroplasty : treatment of painful vertebral compression fractures with intraosseous vacuum phenomena. *Am J Roentgenol* 2003 ; 180 : 1411-1417.
20. **Sarli M, Perez Manghi FC, Gallo R, Zanchetta JR.** The vacuum cleft sign : an uncommon radiological sign. *Osteoporos Int* 2005 ; 16 : 1210-1214.
21. **Sun G, Jin P, Li M, Liu XW, Li FD.** Height restoration and wedge angle correction effects of percutaneous vertebroplasty : association with intraosseous clefts. *Eur Radiol* 2011 ; 21 : 2597-2603.
22. **Theodorou DJ.** The intravertebral vacuum cleft sign. *Radiology* 2001 ; 221 : 787-788.
23. **Voggenreiter G.** Balloon kyphoplasty is effective in deformity correction of osteoporotic vertebral compression fractures. *Spine* 2005 ; 30 : 2806-2812.
24. **Wang G, Yang H, Chen K.** Osteoporotic vertebral compression fractures with an intravertebral cleft treated by percutaneous balloon kyphoplasty. *J Bone Joint Surg* 2010 ; 92-B : 1553-1557.
25. **Wiggins MC, Sehizadeh M, Pilgram TK, Gilula LA.** Importance of intravertebral fracture clefts in vertebroplasty outcome. *Am J Roentgenol* 2007 ; 188 : 634-640.