



## Surgical treatment of tennis elbow : Percutaneous release of the common extensor origin

Tufan KALELI, Cagatay OZTURK, Aytun TEMIZ, Onur TIRELIOGLU

Twenty six patients who had undergone percutaneous release of the common extensor tendon for lateral epicondylitis were investigated. Fourteen were female and twelve were male. The mean follow-up period was 32 months. Symptoms had been present for an average of 8.9 months. Before the surgery, all the patients were surgically treated with conservative methods ; only those that did not respond to conservative methods were surgically treated. The common extensor origin was released percutaneously. Pain relief was achieved on average eight weeks after surgery. The clinical results were evaluated in terms of pain, activity level and patient satisfaction. The results were excellent in twenty-four patients, good in one and poor in one. Release of the common extensor origin appears as a commendable treatment in patients with lateral epicondylar pain not relieved by conservative management.

### INTRODUCTION

Lateral epicondylitis, also known as 'tennis elbow', is a common and well known condition that causes pain on the lateral aspect of the elbow. It was first described in 1873 by Runge. The incidence of tennis elbow in the population varies from 1 to 3% (20). It is not exclusively secondary due to tennis and is seen in people who do heavy manual works (6).

Symptoms may include local tenderness over the lateral epicondyle, pain in the extensor muscles induced by gripping or resisted extension movements of the wrist (11). On examination, pain may be exacerbated by resisted wrist extension in the pronated position. It is generally worse with the

elbow in full extension. The range of motion of the wrist and elbow is complete (16).

The diagnosis of tennis elbow is made clinically by means of physical examination and patient history. Other possible causes of lateral elbow pain should be excluded. More than 90% of patients with tennis elbow respond to medical treatment (7). Surgery is reserved for resistant cases that have failed a minimum six months course of conservative treatment. Numerous surgical procedures have been described for lateral epicondylitis (4, 5, 7). In recent years, several studies were reported about the outcomes of percutaneous release of the common extensor origin (2, 15, 18, 21). This study presents our clinical results with this procedure.

### PATIENTS AND METHODS

Percutaneous lateral extensor release was performed in 29 patients for tennis elbow between 1995 and 2002. Clinical results of 26 patients who were followed-up were examined. Fourteen patients (54%) were women

---

*From Uludag University Hospital, Bursa, Turkey.*

Tufan Kaleli, MD, Professor.

Cagatay Ozturk, MD, Registrar.

Aytun Temiz, MD, Registrar.

Onur Tirelioglu, MD, Registrar.

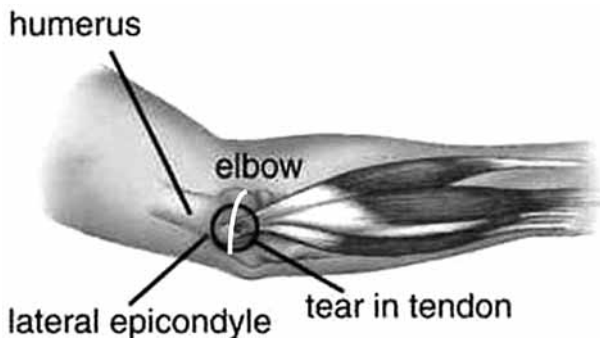
*Uludag University Medical School, Department of Orthopaedic Surgery, Bursa, Turkey.*

Correspondence : Tufan Kaleli, University of Uludag, Faculty of Medicine, Department of Orthopaedic Surgery, 16059, Görükle, Bursa, Turkey.

E-mail : rezocagatay@hotmail.com.

© 2004, Acta Orthopædica Belgica.

---



*Fig. 1.* — Schematic appearance of the pathology in tennis elbow. The white line indicates the skin incision.

and 12 (46%) were men. The mean age of patients was 45.2 years (range : 32 to 58 years). Symptoms were present for an average of 8.9 months. All patients were treated with conservative methods for at least 6 months before they underwent surgery. The indication for percutaneous extensor release was absence of relief with conservative treatment of at least six months duration.

A tourniquet was used in all patients. Under axillary block anaesthesia, the common extensor origin was incised through a 0.5 cm skin incision with a No : 11 surgical blade (fig 1). At the end of the operation, release of the common extensor origin could be checked by palpation over the skin. The tourniquet was released and haemostasis was achieved by pressure on the wound. The incision was sutured. A bulky dressing was applied to the incision. No splint was applied to the upper extremity and the elbow was left free for use.

The follow-up data were obtained from the patients' charts and a questionnaire, and classified according to Grundberg and Dobson (12) (table I).

## RESULTS

The average follow-up period was 32 months (range : 8 to 60 months). During the last examination, pain, activity and patient satisfaction were evaluated (table I) (12). Twenty-four patients were rated as having excellent results. One patient was rated as having a good result and one who was rated as having a poor result underwent a second operation. Lateral epicondylar pain was relieved within an average of 2 months after the surgery. All patients had a full range of elbow motion at follow-up examination. All patients with excellent or good results returned to their former occupations or activities. All were satisfied with the incision scar.

## DISCUSSION

Tennis elbow involves an overuse type injury of the extensor tendons, especially in the extensor carpi radialis brevis. The pathologic finding is fibrous granulation tissue at the origin of the common extensor tendon (9). Histological studies of surgical specimens have confirmed that the pathology consists of vascular infiltration and degeneration of the common tendon origin (7, 16). Subtle instability following lateral ligament complex injury and compression of the anterior branch of the radial nerve are two important entities in the differential diagnosis (14). Some authors claimed that the main pathology in tennis elbow was entrapment of the anterior interosseous branch of the radial nerve and suggested surgical decompression of the nerve (8, 19). However, it is currently accepted that the vast majority of cases of lateral epicondylar pain are related to an overuse injury of the extensor tendon origin.

Table I. — Rating system used to evaluate the results

Rating	Pain	Activity and Patient Satisfaction
Excellent	No pain	Returned to work or activity Patient satisfied
Good	Pain only with heavy use	Returned to work or activity Patient satisfied
Poor	Pain unchanged	Patient dissatisfied

Various surgical techniques have been described for the surgical treatment of tennis elbow such as open surgery for excision of the proximal portion of the annular ligament, open release of the origin of the extensor muscles, excision of the bursa if present, excision of the synovial fringe which is often present, decortication of the lateral epicondyle, and lastly percutaneous release of the common extensor origin (2, 4, 5, 9). The most frequently used procedure is release of the common origin of the extensors using either an open or a percutaneous technique. Release of the common extensor origin is a highly satisfactory procedure for the treatment of lateral epicondylitis unresponsive to conservative treatment: the reported rates of good results have ranged from 54% to 99% (17).

In the open procedure which was first mentioned by Hohman according to Hohl (13), the abnormal tissue which consists of tears involving the common extensor origin and granulation tissue deep to the common extensor origin can be identified. The pathologic area of the extensor origin may be excised, creating a longitudinal defect which may be repaired by suturing. The rates of good results after this procedure have ranged from 77% to 85% (7, 16). However, Goldie (10) who studied the pathologic anatomy of the tennis elbow did not find any tendon tears in his study. The tears involving the common extensor origin described previously may well be secondary to injections of corticosteroids (1, 12).

According to Powell and Burke, percutaneous release of the extensor common origin was first performed by Losee in 1962 (18). This is a technically simple procedure that allows early mobilisation without pain. Seventy to 90% excellent or good results have been reported in the literature (2, 15, 18, 21). Ninety-four percent of the patients in our study group showed excellent or good results.

## CONCLUSION

Most patients with lateral epicondylalgia respond to conservative treatment. In resistant cases in which surgical treatment appears necessary, percutaneous release of the common extensor origin may be considered as a first choice.

## REFERENCES

1. **Balasubramanian P, Prathap K.** The effect of injection of hydrocortisone into rabbit calcaneal tendons. *J Bone Joint Surg* 1972 ; 54-B : 729-734.
2. **Baumgard SH, Schwartz DR.** Percutaneous release of the epicondylar muscles for humeral epicondylitis. *Am J Sports Med* 1982 ; 10 : 233-236.
3. **Bernhang AM.** The many causes of tennis elbow. *NY State J Med* 1979 ; 79 : 1368-1371.
4. **Bosworth DM.** Surgical treatment of tennis elbow : A follow-up study. *J Bone Joint Surg* 1965 ; 55-A : 1533-1536.
5. **Boyd HB, McLeod AC.** Tennis elbow. *J Bone Joint Surg* 1973 ; 55-A : 1183-1186.
6. **Caldwell GL, Safran MR.** Elbow problems in the athlete. *Orthop Clin N Am* 1995 ; 26 : 465-485.
7. **Coonrad RW, Hooper WR.** Tennis elbow : Its course, natural history, conservative and surgical management. *J Bone Joint Surg* 1973 ; 55-A : 1177-1182.
8. **Enzenauer RJ, Nordstrom DM.** Anterior interosseous nerve syndrome associated with forearm band treatment of lateral epicondylitis. *Orthopedics* 1991 ; 14 : 788-790.
9. **Goldberg EJ, Abraham E, Siegel J.** The surgical treatment of chronic lateral humeral epicondylitis by common extensor release. *Clin Orthop* 1988 ; 233 : 208-212.
10. **Goldie I.** Epicondylitis lateralis humeri. *Acta Chir Scand* 1964 ; 339 : 1-119.
11. **Gruchow HW, Pelletier D.** An epidemiologic study of tennis elbow : incidence, recurrence and effectiveness of prevention strategies. *Am J Sports Med* 1979 ; 7 : 234-238.
12. **Grundberg AB, Dobson JF.** Percutaneous release of the common extensor origin for tennis elbow. *Clin Orthop* 2000 ; 376 : 137-140.
13. **Hohl M.** Epicondylitis-tennis elbow. *Clin Orthop* 1961 ; 19 : 232-235.
14. **Morrey BF.** Reoperation for failed treatment of refractory lateral epicondylitis. *J Shoulder Elbow Surg* 1992 ; 1 : 47-53.
15. **Murtagh JE.** Tennis elbow. *Aust Fam Physician* 1978 ; 7 : 1307-1311.
16. **Nirschl RP, Pettrone FA.** Tennis elbow : The surgical treatment of lateral epicondylitis. *J Bone Joint Surg* 1979 ; 61-A : 832-836.
17. **Nollen A.** Ergebnisse der operativen Behandlung der Epicondylitis lateralis humeri. *Orthopäde* 1981 ; 10 : 328-329.
18. **Powell SG, Burke AL.** Surgical and therapeutic management of tennis elbow : An update. *J Hand Ther* 1991 ; 4 : 64-68.
19. **Wilhelm A.** Treatment of therapy refractory epicondylitis lateralis humeri by denervation. *Handchir Mikrochir Plast Chir* 1999 ; 31 : 291-302.
20. **Wittenberg RH, Schaal S, Muhr G.** Surgical treatment of persistent elbow epicondylitis. *Clin Orthop* 1992 ; 278 : 73-80.
21. **Yerger B, Turner T.** Percutaneous extensor tenotomy for lateral epicondylitis. An office procedure. *Orthopedics* 1985 ; 10 : 1261-1263.