



Upper limb flaps for hand reconstruction

Konstantin C. XARCHAS, Christos CHATZIPAPAS, Ourania KOUKOU, Konstantin KAZAKOS

This article reviews three of the most popular upper limb flaps used in hand surgery, namely the posterior interosseous flap, the lateral arm flap and the radial forearm flap. An anatomic study performed with the use of eight fresh cadavers (sixteen upper limbs) is supported by a wide review of the literature. The combined posterior interosseous and lateral arm flap is also discussed. It is concluded that these flaps are easily harvested and dependable and in spite of any disadvantages their combination should be adequate for the treatment of almost any hand injury.

INTRODUCTION

The anatomy of the hand allows cover of small skin defects with a great variety of local pedicle and island flaps. However, for larger defects it is necessary that flaps from distant donor sites be used, either as free or pedicle flaps. Use of the ipsilateral upper limb as a donor site has many advantages. Both donor and recipient sites are located within the same operative field permitting the entire surgical procedure to be performed with the patient under a single regional block anaesthesia, both flap and recipient sites being prepared synchronously in a bloodless field. Also, donor site morbidity is restricted to a single extremity. Orthopaedic surgeons occasionally performing flap surgery for hand reconstruction, need to be familiar with flaps that are dependable and easily harvested. We therefore present a thorough anatomic and bibliographic study of the posterior interosseous, the radial forearm and the lateral arm flap which, as we believe, comprise these qualities.

MATERIAL AND METHODS

Sixteen upper extremities (8 fresh cadavers) were dissected to delineate the anatomy, vascular pattern and reconstructive potential of the flaps. Six cadavers belonged to males and two to females. Mean age was 51.5 years and mean weight 72 kilograms. Each subclavian artery was irrigated with 30 cc normal saline, followed by injection with a silicone rubber compound (Microfil). So, we had the determination of all vascular branches of each upper extremity. As these flaps are situated in different anatomic areas of the upper limb, we were able to dissect and study each one of them for sixteen consecutive times. Dissections were carried out under loupe magnification.

Posterior interosseous forearm (dorsal forearm) flap

Anatomy. This flap is based on the posterior interosseous artery (PIA). The artery is reported to originate from the common interosseous artery and occasionally from the ulnar artery. In our specimens it always originated from the common interosseous artery. After passing between the chorda obliqua and the interosseous membrane, the posterior interosseous artery runs deep to

From the Orthopaedic Department, Democritus University of Thrace, Alexandroupolis, Greece.

Konstantin C. Xarchas, MD, Lecturer.

Christos Chatzipapas, MD, Orthopaedic Registrar.

Ourania Koukou, MD, Orthopaedic Registrar.

Konstantin Kazakos, MD, Assistant Professor.

Correspondence : Konstantin C. Xarchas, Democritus University of Thrace, 6 I. Kaviri Road, 68100 Alexandroupolis, Greece. E-mail : drkcxr@yahoo.com.

© 2004, Acta Orthopædica Belgica.

the supinator and enters the deep extensor compartment of the forearm at an average distance of 8.0 cm from the lateral humeral epicondyle and 14.0 cm from the ulnar head. At the level of the lower border of the supinator muscle it divides into two branches : the interosseous recurrent artery that anastomoses with the posterior branch of the profunda brachii artery at the elbow and the main trunk of the PIA that passes distally in the intermuscular septum between the extensor digiti quinti (EDQ) and the extensor carpi ulnaris (ECU). Approximately 2.0 cm proximal to the distal radioulnar joint, lateral to the ulnar head and underneath the extensor tendons, the posterior interosseous artery anastomoses with the anterior interosseous artery (AIA), the dorsal carpal arch and the vascular plexus surrounding the ulnar head.

The vascular territory of the PIA is the posterior forearm skin extending from 2.0 to 4.0 cm below the interepicondylar line to the wrist. The artery gives off several fasciocutaneous perforators along its length and thus supplies almost the whole width of the skin on the posterior aspect of the forearm. Along its course, it gives several cutaneous branches, two of them being the most substantial : proximal and middle. The proximal cutaneous branch is a large branch, which courses in the intermuscular septum, pierces the deep fascia, and distributes in the subcutaneous tissue with two or three terminal branches. The middle branch originates in the middle third of the forearm, where the PIA becomes superficial. It was present in all of our specimens. At the distal third of the forearm, the PIA gives the following cutaneous branches : at the level of the wrist the artery anastomoses with the perforating branch of the AIA, the dorsal carpal arch, and the vascular plexus surrounding the ulnar head. The posterior interosseous nerve enters the dorsal compartment at the proximal third of the forearm and becomes more superficial as it proceeds distally. The PIA is accompanied by the posterior interosseous nerve, which divides into sensory and motor branches. A small sensory branch accompanies the artery as far distally as the wrist.

Flap elevation (figs 1, 2 and 3). With the elbow in 90° of flexion, the forearm in full pronation and the wrist in neutral position, a line is drawn from the lateral humeral epicondyle to the ulnar styloid apophysis. The entry point of the posterior interosseous vessels into the posterior compartment of the forearm is marked at the union of the middle and proximal third of this line. The center of the flap is designed a little more distally to this, about 8.0 cm distal to the lateral epicondyle. The vascular pedicle is located there. The pivot point of the reversed vascular pedicle is about 1.0 cm proximal to

the ulnar head. The PIA is located in the intermuscular septum between the extensor digiti minimi and extensor carpi ulnaris muscles.

As we usually raise the flap with a distal pedicle, a dorsal skin incision is first made at the level of the distal radio-ulnar joint, to ensure presence of the PIA and its anastomosis to the AIA on which the flap will be based. The flap is then outlined and the incision extended to its lower border and circumferentially to its upper limit through the radial side. The incision is carried down through the deep fascia enveloping the extensor carpi radialis brevis or extensor digitorum communis (EDC) and extensor digiti quinti (EDQ) muscles. The radial side is raised subfascially, taking the deep fascia of the extensor digitorum communis and extensor digiti minimi. Dissection continues from the lateral border of these muscles towards the ulnar side. Radial retraction of the EDQ, EIP (extensor indicis proprius) and EDC exposes the septum and its cutaneous perforators. Here, the fascia divides deeply and inserts into the intermuscular septum. It is within this two-leafed fascial envelope - the anterior leaf is the extensor carpi radialis brevis with the extensor digitorum communis and the extensor digiti quinti fascia and the posterior leaf is the extensor carpi ulnaris fascia - that the PIA lies. All muscular branches of the PIA are ligated and the dissection extends proximally along the septum until a significant cutaneous perforator is seen entering the flap and no further than the distal border of the supinator muscle at the radial side. The PIA is ligated proximal to this perforator. The posterior interosseous nerve lies on the lateral side of the PIA. The nerve is dissected and preserved carefully. The origins of the interosseous recurrent artery and the proximal cutaneous branch are identified. After localising the major perforator and dividing the PIA, the ulnar skin incision is made. To harvest the ulnar half of the flap, dissection is carried into the subfascial plane, again taking the extensor carpi ulnaris fascia. The intermuscular septum and a very thin fascia are raised with the flap. The flap is then elevated from proximal to distal. Ulnar retraction of the ECU exposes the pedicle within the septum, which should be dissected from the ulnar shaft. To safeguard the pedicle and its venae comitantes, a generous cuff of fibrofatty tissue is included around the septum. The last motor branches of the posterior interosseous nerve follow the PIA in the septum deep and close to it. The flap is elevated on the reversed vascular pedicle of the PIA and one additional cutaneous vein and then translocated to the hand through a subcutaneous tunnel, or superficially. If needed (cases with vein congestion), the vascular anastomosis between the

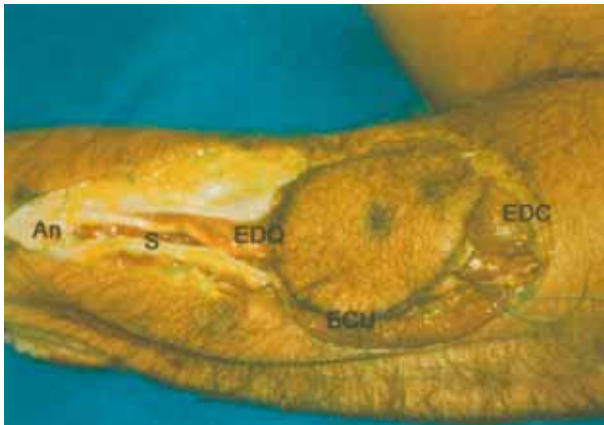

Fig. 1. — Posterior interosseous flap. Initial dissection. EDC : extensor digitorum communis, ECU : extensor carpi ulnaris, EDQ : extensor digiti quinti, S : septum where the PIA runs, An : anastomosis between PIA-AIA and dorsal carpal arch.

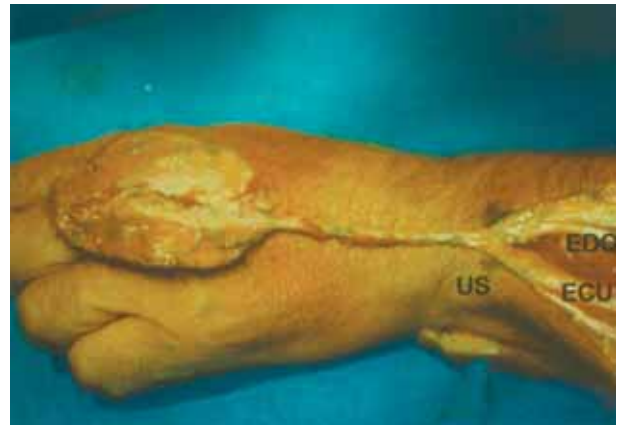

Fig. 3. — Posterior interosseous flap elevated and reversed on its pedicle to reach metacarpo-phalangeal joints. US : ulnar styloid.

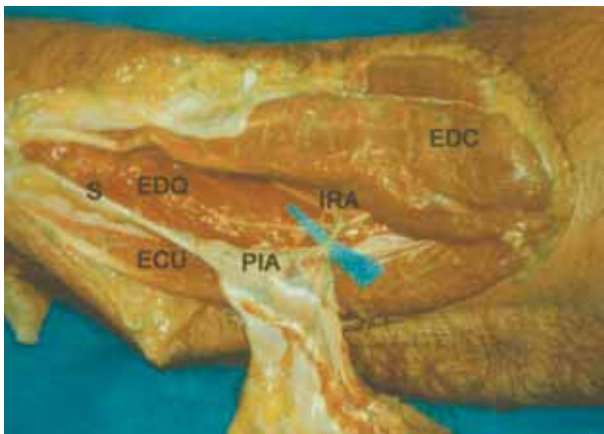


Fig. 2. — Posterior interosseous flap. Dissection completed. IRA : interosseous recurrent artery.

prepared vein and a tributary of the cephalic vein is done easily with loupes.

Lateral Arm Flap

Anatomy. This flap is supplied by septal arteries arising from the posterior radial collateral artery (PRCA), terminal branch of the profunda brachii, which anastomoses with terminal branches of the recurrent radial artery in the subcutaneous tissue of the lateral aspect of the elbow. The anterior radial collateral artery, also a branch of the profunda brachii is not suitable to provide the basis of the flap because of its variation and the

proximity of the radial nerve, which runs in the groove between brachioradialis and brachialis muscle. The posterior radial collateral artery runs downwards between brachialis and triceps. Two nerves should be considered in the flap : A small nerve, arising directly from the radial nerve, which supplies the territory of the flap (posterior cutaneous nerve of the arm) and the posterior cutaneous nerve of the forearm that passes through the deep fascia proximal to the lateral epicondyle and supplies the skin over the posterior aspect of the forearm.

In all 16 specimens, the lateral fascia was perfused by 2 or 3 major septal branches of the PRCA that subsequently supplied the skin. The most proximal branch was closely related to the posterior cutaneous nerve of the forearm. The PRCA originated from the radial groove of the humerus, running in the lateral intermuscular septum between the triceps posteriorly and the brachialis and brachioradialis muscles anteriorly, becoming more superficial as it neared the lateral humeral epicondyle. Dissecting to its origin, an average pedicle length of 7 cm could be obtained. The venous return of this flap is through two systems : the superficial veins, draining to the cephalic vein and the deep system of venae comitantes, which is placed adjacent to the arterial pedicle.

Flap elevation (figs 4 and 5). The insertion of the deltoid and the lateral humeral epicondyle are outlined. A line joining these two landmarks may be extended on to the forearm ; this line is the central axis of the flap. The proximally based flap is outlined on the distal third of the lateral aspect of the arm. It can be extended over the lateral epicondyle. The deep fascia is incised in line with

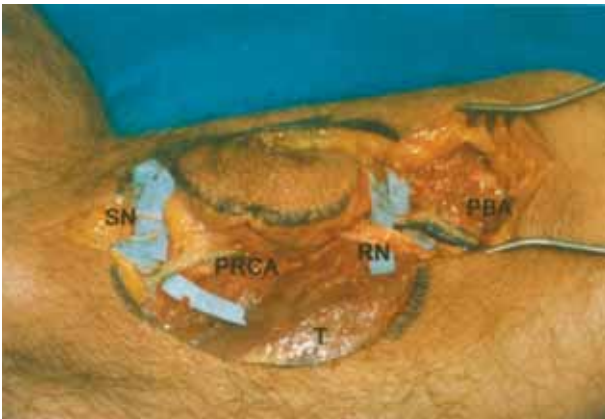


Fig. 4. — Lateral arm flap. Initial dissection. PBA : profunda brachii artery and venae comitantes, RN : radial nerve, T : triceps muscle, PRCA : posterior radial collateral artery, SN : sensory nerves (posterior cutaneous nerves of the arm and forearm).

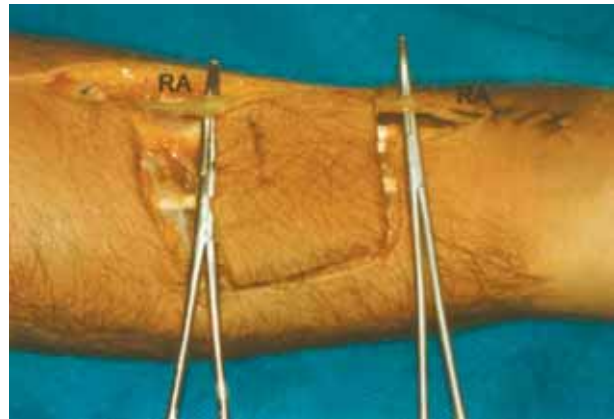


Fig. 6. — Radial forearm flap. Initial dissection. RA : radial artery and venae comitantes.

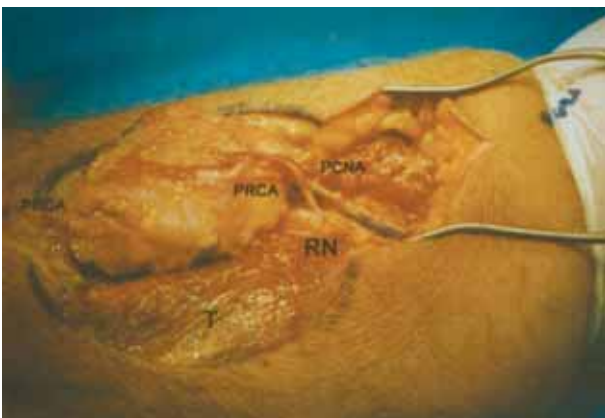


Fig. 5. — Lateral arm flap. Dissection completed. PCNA : posterior cutaneous nerve of the arm arising from radial nerve.

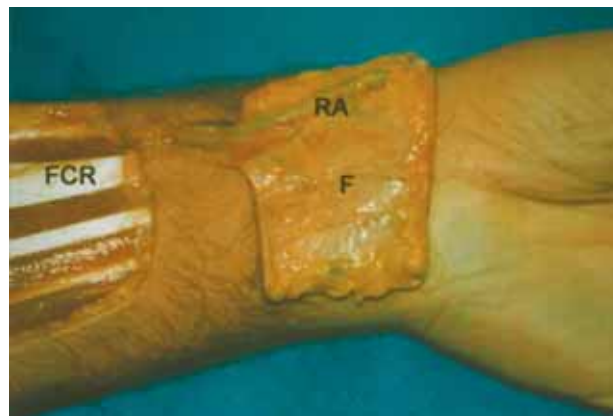


Fig. 7. — Radial forearm flap. Dissection completed, flap elevated and reversed on its (short) pedicle to reach the wrist. The flap can be arranged to reach up to the level of the phalanges (see text). F : fascia carefully elevated with radial artery (RA). FCR : tendon of flexor carpi radialis.

the skin, and the posterior half of the flap is released from the underlying triceps muscle until the septum, which is inserted on the humeral bone, is seen. It separates the anterior and the posterior compartments of the arm and contains the PRCA. The same dissection is performed to separate the anterior part of the flap from the underlying muscles, which are the brachialis, brachioradialis and the extensors. The proximal skin incision is then completed and the plane between the deltoid and the triceps muscles is followed. The triceps and the deltoid muscles are retracted to expose the vascular pedicle

of the flap and the radial nerve. The profunda brachii and its venae comitantes are cautiously separated from the nerve. The descending anterior radial collateral artery is ligated and divided. The two nerves, one of which supplying and the other passing through the flap, are identified. The septum is then incised close to the bone to release the flap. The vessels are ligated distal to the flap. Retraction of deltoid and triceps muscles permits the exposure of the pedicle's origin. The arc of rotation of an island flap allows coverage of the shoulder.

The distally based pedicle flap is also outlined on the distal third of the lateral aspect of the arm but slightly lower towards the elbow. A short distal incision will allow identification and mobilization of the distal pedicle. The posterior incision is made first and deepened to expose the triceps. Anteriorly, the flap is dissected from the brachioradialis to expose the intermuscular septum. The posterior radial collateral artery is ligated at its origin. The septum is released from the humerus. A short fasciosubcutaneous pedicle is dissected and mobilised distal to the flap. It contains the anastomoses between the posterior radial collateral artery and the recurrent radial artery, which supply the flap. The flap can be rotated anteriorly or posteriorly to cover the elbow area.

Obviously the lateral arm flap can only be used in hand surgery as a free flap based on the PRCA and its venae comitantes. Due to the presence of the two sensory nerves it can be used as an innervated or even as a composite free flap if bone underlying the septum is elevated along with it.

Radial forearm (Chinese) flap

Anatomy. This flap is based on the radial artery. This artery may be the only patent vessel to the hand. When it is not, it is the dominant vessel in 12% of hands. The radial artery pursues a relatively superficial course in the forearm from its source at the division of the brachial artery to the point where it passes deep to the tendon of the abductor pollicis longus to reach the anatomic snuff-box. In the proximal forearm it lies on the superficial surface of the pronator teres, just beneath the anterior margin of the muscle belly of the brachioradialis. Leaving the pronator teres, it comes to lie in turn on the radial head of the flexor digitorum superficialis and the flexor pollicis longus, here being palpable through the skin. Throughout its course the artery gives branches to a plexus of vessels in the overlying deep fascia and this plexus supplies the skin of the anterior and radio-dorsal surfaces of the forearm. By similar fascial branches it also supplies the periosteum of the distal half of the radius between the insertions of pronator teres and brachioradialis. This allows construction of osteocutaneous flaps where desired. The artery is accompanied by two or more venae comitantes. The multiple anastomoses between these veins permit reversal of flow in the venae comitantes without valvular obstruction. Thus the artery and veins can be divided proximally and no venous engorgement will result.

The blood supply to the distally based radial forearm fasciocutaneous flap emanates from 6 to 10 septocuta-

neous perforators of the distal radial artery. These perforating vessels "fan out" at the level of the deep fascia to form a rich plexus supplying the forearm fascia, subcutaneous tissue, and skin. We found these vessels to arise from both the radial and ulnar aspects of the radial artery, approximately 1.5 cm proximal to the radial styloid and recur proximally at 0.5 to 1.5 cm intervals. An elaborate venous network accompanies the arterial circulation. Venous drainage is from both the superficial and deep systems. There are multiple anastomoses between these venous channels. One or both venae comitantes ordinarily follow each of the fascial arterial perforators with communicating branches between the venae comitantes allowing reverse flow by means of both "crossover" and "bypass" patterns.

Flap elevation (figs 6 and 7). The radial forearm flap with a distal pedicle is employed for coverage of the thumb-index web space, and both the palm and dorsum of the hand. It is designed and based on the distal perforating vessels of the radial artery and its venae comitantes. The flap is designed slightly larger than the measured defect; this is to ensure inclusion of as many of the distal perforating vessels as possible, accounting for variation in the location of the most proximal of the distal perforating vessels and thus maximising flap vascularity. Allen's test is first performed to ensure patency of the ulnar artery. The route of the radial artery is marked and the flap then drawn on the skin at about the middle third of the forearm's anterior surface. At this point the length of the pedicle required as well as the size of the flap should be estimated. The pivot point is at the level of the radial styloid, just proximal to the division of the radial artery. In case a longer pedicle is required to cover finger defects, the pivot point is transferred to the apex of the first web, this requiring inclusion of the deep branch of the radial artery in the pedicle, ligation of its superficial branch and passage of the pedicle and flap underneath the tendons of the 1st dorsal wrist compartment, which is released off the radial styloid. The first incision is done distally to the flap over the radial vascular axis to expose the pedicle from the pivot point. An incision is also done on the same line, just proximal to the flap, to allow complete control of the radial artery. Superficial veins met at this stage can be ligated. The flap's borders are then incised and dissection started on the ulnar side, carefully including the fascia, until the radial border of the flexor carpi radialis (FCR) is reached. At this point ulnar side dissection is deepened to make sure the radial artery is taken with the septum and fascia, and stopped. On the radial side dissection releases the flap off the brachioradialis (BR) muscle

(which is retracted radially) and is carefully deepened at the muscle's ulnar border to pass beneath the artery. The superficial radial nerve is identified as it emerges from the brachioradialis and carefully preserved. The radial artery and venae comitantes are then clamped proximally and the tourniquet released to ensure adequate flap and hand perfusion. Tourniquet is then re-inflated and the vascular axis divided proximal to the flap. Finally the flap and its vascular axis are released from the underlying flexor muscles (mainly the flexor digitorum superficialis). The flap can easily reach the metacarpophalangeal joints. If further length is required to reach the phalanges, pivot point should be transferred to the apex of the first web by extending the distal incision over the snuffbox and dissecting as already described. The FCR and BR are brought together and the donor site covered with split skin grafts.

DISCUSSION

The first anatomical study on the posterior interosseous flap was published by Penteado *et al* in 1986 (13). The posterior interosseous cutaneous flap was then introduced by Zancolli and Angrigiani (1988) as a reverse island flap (21). This was a major advance, as this flap does not sacrifice a major artery of the hand (11).

We agree with authors who suggest that the posterior interosseous axis is a good first choice as a donor area for distally based flaps for resurfacing of moderate - size defects of the hand. The posterior interosseous flap is presently the only flap that can be harvested from the dorsum of the forearm. The donor site can usually be closed primarily and directly. It is characterised by the expendable vascular pedicle and its thinness (16). Zancolli and Angrigiani (1988), Costa and Soutar (1988) and Angrigiani *et al* (1993) have described the anatomy of the posterior interosseous vascular system (6, 16, 21). It is a dual longitudinal system, with two inflow arteries; the PIA proximally and the recurrent branch of the AIA distally. Though we have no experience with its use as a free flap, according to the literature a posterior interosseous flap should be used as a free flap when: a) the distal pedicle is too small or has been injured, b) the defects to be covered are located at distal fingers or c) there are anatomical variations of the pedicle so that a distal

pedicle cannot be raised without compromising the nerve branches (15). The free flap with extended vascular pedicle is an excellent free flap whose easiness of dissection and low morbidity make it a good choice when limited amounts of thin, pliable skin with a long vascular pedicle are needed (3). It can be transferred easily not only to the dorsum of the hand and first web space, but also to the fingers, foot and other sites. This flap can be used for reconstruction of gliding surfaces of the upper extremities and as a sensory flap using the posterior antebrachial cutaneous nerve. This nerve is a branch of the radial nerve and innervates the same area of skin as the one used by the posterior interosseous flap. The nerve is severed by the elevation of the flap if it is not used for sensory reconstruction (16). The sensate posterior interosseous flap provides better sensory recovery than the non-sensate flap. The flap's disadvantages have been described as follows: There are many anatomic variations including absence of the PIA-AIA anastomosis or a hypoplastic interosseous artery in the middle third that may lead to flap loss in clinical practice. Flap elevation can be tedious and dangerous to the last motor branches of the posterior interosseous nerve and finally the PIA is sometimes more deeply situated between the deep extensor muscles (extensor pollicis longus, abductor pollicis longus and extensor indicis proprius) (7, 8, 12). In our specimens we didn't find any anatomic variations and the PIA was always situated between the extensor digiti minimi and extensor carpi ulnaris tendons-muscles.

The lateral arm free flap can be harvested as a fascial or fasciocutaneous flap. The use of the fascial flap allows a large area of tissue to be harvested and the donor site can be closed primarily with a linear scar. The pliability and thinness of the fascia allows tissue coverage to conform to the contour of the fingers. Also, the fascia creates a gliding surface of tendons and decreases the tendency of adhesion. The flap can be harvested with a part of the triceps tendon as a vascularised tendon graft, posterior cutaneous nerve of the arm as a vascularised nerve graft, or portion of the humerus to replace a missing metacarpal or phalanx. It is similar to the radial forearm flap but based on the pos-

terior radial collateral artery, which is not essential for the vascularity of the hand. This flap is a good choice for covering degloved fingers with intact pulps and defects on the dorsum of the hand (4) but it transfers hair to the palmar surface of hand (14). The flap may be harvested in supine, lateral, or prone position. The dissection is straightforward, with easy tissue planes and a constant anatomy. Disadvantages of the flap include a donor-site scar and anaesthesia of lateral forearm owing to transection of the posterior cutaneous nerve of the forearm. Tissue trimming at the site of transfer may compromise blood supply to the flap. The radial nerve is easy to be identified and retracted during dissection (20). More recently, a distal extension of the lateral arm flap, described as lateral arm/proximal forearm flap was presented with good results (2).

The radial forearm or Chinese flap was originally described as a free flap by Yang *et al* (19) of the Shenyang Military General Hospital (1978) and popularised in the Western world by Song *et al* (1982) who used this flap in 31 cases of head and neck reconstruction (17). Lu *et al* (1982) first described the use of a distally pedicled axial-pattern radial forearm fasciocutaneous flap, including the radial artery and its venae comitantes, for reconstruction of soft-tissue defects of the ipsilateral hand (10). Major disadvantages, however, of the distally based pedicled radial forearm flap are a cosmetically unacceptable donor site and the sacrifice of the radial artery and venae comitantes with permanent loss of the contribution of the radial artery to the circulation of the hand. Though definite vascular changes occur following loss of the radial artery and the long-term effects- especially in cold climates- need further investigation, some authors found that clinical compromise to hand circulation is not significant at a long term follow-up evaluation (9). Our own clinical and anatomic investigations demonstrate that a distally based fasciocutaneous radial forearm flap can most of the times be harvested easily, providing a safe, reliable and quick soft-tissue coverage of the hand. In our opinion, while sacrifice of the radial artery does not generally appear to cause any significant problem, in cases of severe trauma in which only the radial

artery may be functioning, use of the reverse radial forearm flap incorporating the radial artery is contraindicated. Adequate blood supply from the ulnar artery should always be ensured at the beginning and during the operation. Theoretically the flap can be harvested anywhere on the forearm along the axis of the radial artery. Routinely the donor site must be covered with split skin grafts but fascia alone can also be harvested thus reducing donor site morbidity (18).

Finally, a combination flap for the coverage of moderate-to large-sized soft-tissue defects of the hand, formed by the adjacent two cutaneous flaps of the dorsal forearm and lateral arm, was presented in 1995 by Shibata *et al* (15). The dorsal forearm flap based on the posterior interosseous artery is designed over a line connecting the ulnar head and the lateral humeral epicondyle. The lateral arm flap is designed on a line linking the lateral humeral epicondyle and the insertion of the deltoid muscle. These lines make one long straight line with the elbow in extended position. The pivot point of the reversed vascular pedicle is about 1 cm proximal to the ulnar head. In the arm, the fascia of the triceps tendon and muscle is elevated to the lateral intermuscular septum. The posterior cutaneous nerve of the forearm is dissected with the vascular pedicle of the posterior radial collateral artery, providing a sensate flap. The vascular pedicle is traced up to the profunda brachii artery, through the intermuscular septum, between the brachialis and the triceps muscle. In the forearm, cutaneous perforators come up from the posterior interosseous artery in the intermuscular septum between extensor carpi ulnaris and the extensor digiti quinti. The posterior interosseous artery with its venae comitantes is traced distally down to 1 cm proximal to the ulnar styloid. During dissection, the posterior interosseous nerve is carefully identified and isolated from the vessel. The cutaneous veins are also elevated with the vascular pedicle. A large subcutaneous tunnel is then made between the pivot point of the vascular pedicle and the proximal edge of the primary wound. The flap is brought to the wound through the tunnel. The posterior radial collateral artery has to be connected to a convenient recipient artery. It is not necessary for venae comitantes to be

repaired because sufficient venous return can be achieved through the cutaneous vein raised with the reversed vascular pedicle. The reporting authors, used this combination flap in two difficult cases, achieving one-stage soft tissue reconstruction of the hand. We have no experience with this flap, whose elevation appears to be tedious and technically demanding. Still, its application appears to be the final solution for any size of defect in the distal forearm and hand, if one is determined not to go any further than the ipsilateral upper limb.

CONCLUSION

This article is devoted to an update on upper limb flaps and illustrates the innovative strength of this surgical field. It also points out that, through in depth knowledge of the anatomy, flaps may be raised from many anatomic regions of the limb even without disturbing its main vascular axis. Minimising the donor site morbidity while maximising the quality of reconstruction is the primary concern when indications are established for reconstructive hand surgery.

From all of the flaps reviewed, it is important to know how to select the most suitable flap in each case. Aside from the technical expertise of the surgeon, the indication depends on the size and location of the defect. For large defects in any location, the radial forearm flap remains the most reliable and safest choice. For children and women, the authors prefer distant pedicled transfers or free flaps to minimise cosmetic donor site morbidity. For small or medium defects that cannot be managed by a local transposition flap, the indication is based on the location of the wound. The posterior interosseous flap provides a reasonable alternative, for the first web space and neighbouring radial defects or whenever vascularised tendon, nerve, or bone is needed also. Dorsal defects of the hand can be reconstructed with this flap, provided there is no suspicion of injury to the anastomotic dorsal system of the wrist.

Indications depend above all on the surgeon's experience and on the different schools. As always,

the better flap is the one performed by the surgeon who has mastered the particular surgical technique.

REFERENCES

1. **Angrigiani C, Grilli D, Dominikow D, Zancoli EA.** Posterior inter-osseous reverse forearm flap : experience with 80 consecutive cases. *Plast Reconstr Surg* 1993 ; 92 : 285-293.
2. **Brandt KE, Khouri RK.** The lateral arm/proximal forearm flap. *Plast Reconstr Surg* 1993 ; 92 : 1137-1143.
3. **Cavadas PC.** Posterior interosseous free flap with extended pedicle for hand reconstruction. *Plast Reconstr Surg* 2001 ; 108 : 897-901.
4. **Chen HC, El-Gammal TA.** The lateral arm fascial free flap for re-surfacing of the hand and fingers. *Plast Reconstr Surg* 1997 ; 99 : 454-459.
5. **Chen HC, Cheng MH, Schneeberger AG, Cheng TJ.** Posterior inter-osseous flap and its variations for coverage of hand wounds. *J Trauma* 1998 ; 45 : 570-574.
6. **Costa H, Soutar DS.** The distally based island posterior interosseous flap. *Br J Plast Surg* 1988 ; 41 : 221-227.
7. **Dadalt-Filho LG, Ulson HJ, Penteado CV.** Absence of anastomosis between the anterior and posterior interosseous arteries in a posterior interosseous flap : A case report. *J Hand Surg* 1994 ; 19-A : 22-25.
8. **Giunta R, Lukas B.** Impossible harvest of the posterior interosseous artery flap : A report of an individualized salvage procedure. *Br J Plast Surg* 1998 ; 51 : 642-645.
9. **Kleinman WB, O'Connell SJ.** Effects of the fasciocutaneous radial forearm flap on vascularity of the hand. *J Hand Surg* 1993 ; 18-A, 953-958.
10. **Lu KH, Zhong D C, Chen B, Luo JW.** The clinical applications of the reversed forearm island flap (Chinese). *Chin J Surg* 1982 ; 20 : 695.
11. **Martin D, Bakhack J, Casoli V et al.** Reconstruction of the hand with forearm island flaps. *Clin Plast Surg* 1997 ; 24 : 33-48.
12. **Park JJ, Kim J, Chung JI.** Posterior interosseous free flap : Various types. *Plast Reconstr Surg* 1997 ; 100 : 1186-1197.
13. **Penteado CV, Masquelet AC, Chevrel JP.** The anatomic basis of the fasciocutaneous flap of the posterior interosseous artery. *Surg Radiol Anat* 1986 ; 8 : 209-215.
14. **Scheker LR, Kleinert HE, Hanel DP.** Lateral arm composite tissue transfer to ipsilateral hand defects. *J Hand Surg* 1987 ; 12-A : 665-672.
15. **Shibata M, Hatano Y, Iwabuchi Y, Matsuzaki H.** Combined dorsal forearm and lateral arm flap. *Plast Reconstr Surg* 1995 ; 96 : 1423-1429.
16. **Shibata M, Iwabuchi Y, Kubota S, Matsuzaki H.** Comparison of free and reversed pedicled posterior interosseous cutaneous flaps. *Plast Reconstr Surg* 1997 ;

- 99 : 791-802.
- 17. Song R, Gao Y, Song Y, Yu Y, Song Y.** The radial forearm flap. *Clin Plast Surg* 1982 ; 9 : 21-26.
- 18. Weinzweig N, Chen L, Chen ZW.** The distally based radial forearm fasciosubcutaneous flap with preservation of the radial artery : an anatomic and clinical approach. *Plast Reconstr Surg* 1994 ; 94 : 675-684.
- 19. Yang G, Yuzhi G.** Forearm free skin flap transplantation (Chinese). *Natl Med J China* 1978 ; 61 : 139.
- 20. Yousif NJ, Warren R, Matloub HS, Sanger JR.** The lateral arm fascial free flap : Its anatomy and use in reconstruction. *Plast Reconstr Surg* 1990 ; 86 : 1138-1145.
- 21. Zancolli EA, Angrigiani C.** Posterior interosseous island flap. *J Hand Surg* 1988 ; 13-B : 130-135.