



## Osteoid osteoma : CT-guided radiofrequency ablation

Elvira MONTAÑEZ-HEREDIA, José SERRANO-MONTILLA, María Luisa MERINO-RUIZ,  
Francisco AMORES-RAMÍREZ, José VILLALOBOS-MARTÍN

*From the University Hospital Virgen de la Victoria, Málaga, Spain*

Osteoid osteoma is a benign bone tumour ; its main symptom is pain, which is sometimes resistant to analgesic or anti-inflammatory medication. The surgical treatment consists of en bloc excision or curettage of the lesion. Several alternative methods have been proposed, among which CT guided-percutaneous radiofrequency ablation. We report on ten patients who were diagnosed clinically and radiologically as presenting an osteoid osteoma and were treated with this technique, with more than two years follow-up. Results were uniformly excellent. The pain was relieved and the rate of post-operative complications was very low. We recommend percutaneous CT-guided radiofrequency ablation for the treatment of this lesion.

**Keywords :** osteoid osteoma ; radiofrequency ; ablation.

The main symptom is local pain, generally worse during the night, which is relieved with aspirin or other non-steroid anti-inflammatory drugs. It has been hypothesised that the pain is generated by the production of prostaglandins in the osteoid osteoma, which causes local inflammation and vasodilatation. Another source of pain may be the nerve fibres situated in the reactive bone that surrounds the nidus (16).

If pain does not disappear with analgesic and anti-inflammatory medication, interventional treatment is advisable.

Radiofrequency ablation is a treatment situated halfway between less invasive techniques and major surgical resections.

### INTRODUCTION

Osteoid osteoma is a benign bone neoplasm, first described by Jaffe in 1935. It represents approximately 10% of all benign bone tumours. The femur and tibia are involved in 50-60% of cases, the spine in 10%, with its posterior elements affected in 70-100% of cases (12), but in this location osteoblastoma is more common and the size of the tumour is larger (13,19). The lesion may also occur in any part of the skeleton, including the upper extremity (13-31%) and the hand (5%) (20), mainly in the proximal phalanges. In 13% of cases, it is located inside an articulation, mostly at the hip.

■ Elvira Montañez-Heredia, MD, Orthopaedic surgeon.

■ José Serrano-Montilla, MD, Orthopaedic surgeon.

■ María Luisa Merino-Ruiz, MD, Orthopaedic surgeon.

*Department of Orthopaedic Surgery and Traumatology,  
University Hospital Virgen de la Victoria, Málaga, Spain.*

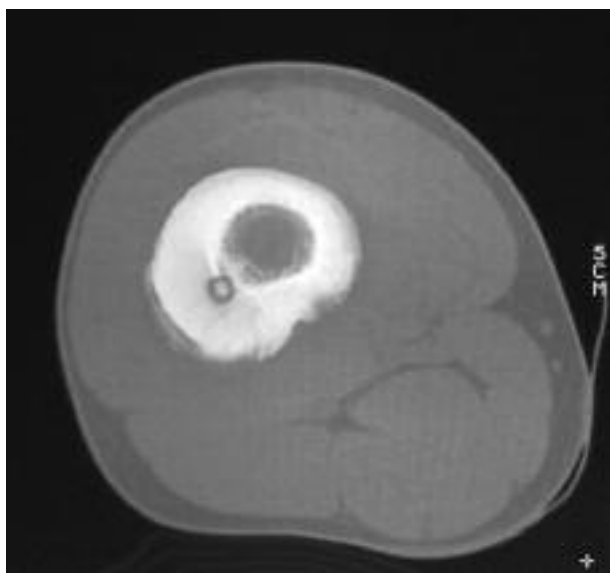
■ Francisco Amores-Ramírez, MD, Radiologist.

■ José Villalobos-Martín, MD, Radiologist.

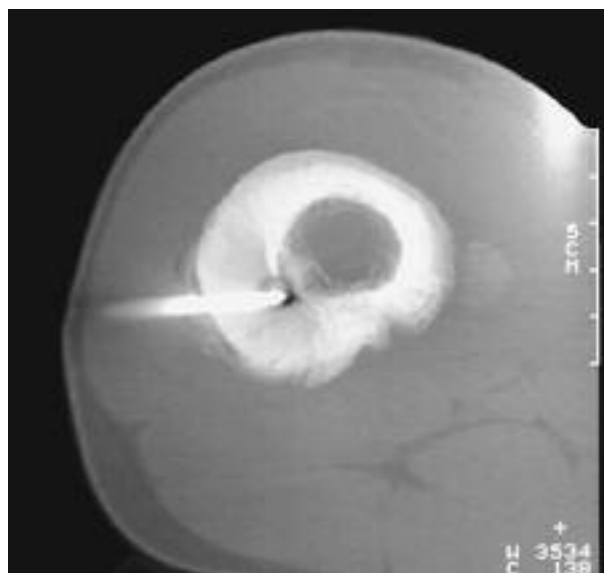*Department of Radiology, University Hospital Virgen de la Victoria, Málaga, Spain.*

Correspondence : José Serrano Montilla, Servicio de Cirugía Ortopédica y Traumatología, Hospital Universitario Virgen de la Victoria, Campus Universitario de Teatinos, s/n, 29010, Málaga, España. E-mail : pepesermon@hotmail.com

© 2009, Acta Orthopædica Belgica.



**Fig. 1.** — CT-scan. Intracortical osteoid osteoma in femoral shaft. We see the nidus with central calcification.



**Fig. 2.** — End of guide-wire inside the nidus, around which we introduce a radiofrequency guide.

At present, radiofrequency has also been used to treat other bone lesions such as bone metastasis, sacrum chordoma, and others (26).

The objectives of this study are to compare the results of our osteoid osteomas series treated with percutaneous radiofrequency ablation to those in other previous reports.

#### MATERIALS AND METHODS

This prospective study was carried out between 2003 and 2006, during which time we treated 10 patients (7 male, 3 female) with a clinical and/or radiological diagnosis of osteoid osteoma. The average age was 21 years (range 17-24 years). All patients had symptoms at the time of treatment. Pain had been present for 12 to 24 months before the radiofrequency ablation (average : 14 months). The lesions were located in the left tibia (3 cases), right tibia (2 cases), left femur (2 cases), right femur (2 cases) and left ulna (1 case). All procedures were carried out in the Radiology Unit of University Hospital Virgen de la Victoria, (Málaga, Spain), with a Somatom 6 Emotion (Siemens) equipment, under sterile conditions and under local anaesthesia and sedation. The team included the orthopaedic surgeon, anaesthetist and radiologist. All patients were informed about their lesion and each one of the alternative treatments. All patients received, understood and signed the consent.

#### TECHNIQUE

After sedation had been applied by means of aseptic techniques, local anaesthetic (Mepivacaine 1%) was injected into the soft tissues covering the lesion, in the place where the incision was made and the guide introduced. A Kirschner wire was introduced into the centre of the nidus under CT-control and a cannulated coaxial broach introduced over the K wire was brought down into the nidus (fig 1,2). Without moving the external system guide, the broach and the wire were removed. The pieces of bone dragged with the broach were sent for histological examination. A radiofrequency probe (15 cm cool-tip RF System electrode with an active end of 1 cm, Covidien Ltd. USA) (fig 3) was introduced through the external guide, and the location of its terminal was confirmed with CT. Next, the electrode temperature was brought to 90°C for 6 minutes, following which the instruments were removed and the skin was closed.

All patients were discharged after a few hours in hospital, without any weight-bearing restrictions. Metamizol caps/8 hours were prescribed as home analgesia if necessary.

## Questionnaire

The patients were followed for at least two years, and were asked to fill out a questionnaire devised by Barei *et al* (3). We carried out pre-operative personal interviews and post-operative telephone and personal questionnaires. The patients had to quantify their pain on a scale from 0 (no pain) to 10 (worst possible pain). We registered the quantity of anti-inflammatory medication with the dosage, and the interference that the pain produced with the patient's current activities.

## RESULTS

### Pre-operative Status

All patients were symptomatic for more than one year before the surgery and they all took anti-inflammatory medication or analgesics. None required the use of narcotic drugs.

### Post-operative Status

The patients received a full check-up before discharge from the hospital, and 48 hours, 3 months, 6 months and 1 and 2 years after the surgery.

None needed analgesics postoperatively during their stay in hospital ; eight out of the ten patients stated that pain was relieved immediately after the treatment. Pain relief was maintained in all cases during the out-patient follow-up period.

Radiological control was not used as a progress indicator of the lesion.

The time interval between the surgical procedure and pain relief was variable. Although 8 out of 10 patients reported immediate relief from pain, pain improvement in the other two was achieved within three weeks. Residual pain was present in only 2 patients, who rated pain at 7/10, and it disappeared within a week.

All patients reported complete pain relief, except one who felt persisting discomfort in his thigh. This patient presented a major cortical reaction in the femur after the radiofrequency procedure. In the end he underwent open surgery with en bloc resection of the cortical bone affected, which



Fig. 3. — Cool-tip RF System electrode

definitively relieved the pain. Histology showed reactive cortical hyperostosis, and the bacteriological study was negative. All patients, except this one, felt complete relief of day pain after the radiofrequency procedure.

All patients have returned without complications to their work or school activities and have participated in sports or hobbies. They no longer take analgesic medication.

We observed post-operative complications, such as hypoaesthesia distal to the site where the radiofrequency guide was introduced (2 cases) and grade 2 skin burn, 3-5 mm diameter, around the site of introduction of the radiofrequency guide in one case of osteoid osteoma of the tibia.

## DISCUSSION

The initial treatment of osteoid osteoma consists of oral administration of anti-inflammatory and/or analgesic drugs. If this is ineffective, surgical treatment is indicated. Conventional surgical treatment consists of en bloc resection or curettage of the lesion, which is not without risks as large surgical resections may be necessary owing to the difficulty in locating the lesion ; this may entail a long hospital stay, require avoidance of weight bearing and, occasionally, internal fixation or a bone graft, with nevertheless a risk for pathological fracture. Specific technical difficulties arise in certain anatomical locations, such as the acetabulum, femoral neck, spine and sacrum.

Technological advances have allowed for the development of various percutaneous procedures to

treat osteoid osteoma (6), such as cryotherapy directed by MRI (27), arthroscopic resection (22), CT-guided burr ablation followed by ethanol injection (1), laser photocoagulation (9), excisional biopsy of the lesion and CT-guided percutaneous radiofrequency ablation (3,15,24). Laser photocoagulation requires expensive equipment (9). Burr ablation of the nidus may locally fragilise the bone ; despite avoidance of weight-bearing, complications have been observed in 24% of cases, including femoral neck fractures and osteomyelitis (25). CT-guided percutaneous radiofrequency ablation is currently the method that is mostly used.

The protocol used in this study with respect to time of application and temperature - 90°C over 6 minutes without refrigeration of the needle – appears to be the most accepted protocol in contrast to other cycles of 8 minutes with a temperature of 50°C. The method used in this study generates less risk of necrosis of surrounding soft tissues (19). Although a temperature of 45°C is fatal for most of the cells (2), it may not be enough to completely destroy the tumour tissue. In fact, when collagen tissues are exposed to high temperatures (from 65°C to 85°C), it has been observed that they undergo rapid denaturation, resulting in collagen denaturation on a microscopic scale and tissue retraction on a macroscopic scale. At constant temperature, the retraction increases as long as the heat exposition does, until it reaches a stable value not causing any more retraction. This final degree of retraction varies depending on the temperature used and the mechanical charges applied to the tissues during heating. An excessive temperature applied over a long time produces tissue hyalinization, a thermal injury and tissue necrosis.

The radiofrequency guide ends in a very thin terminal (17G size), but this is not a problem, as a 3 cm necrosis area is produced around the tip (8) when heating at 90° for 4-6 minutes (3,10,12,15,18), obviating the problem that the guide point has to be exactly inside the nidus.

Since the first applications of radiofrequency ablation in the treatment of osteoid osteoma, very good results have been reported, with a follow-up of 2 months up to one year and with improvement in three out of the first four patients treated (23). It was

at first recommended not to use this technique in lesions close to the neural canal because of the risk of neurological lesion . However, in 1998 Osti and Sebben (17) carried out radiofrequency ablation (RFA) of an osteoid osteoma in a vertebra, demonstrating the possibility to use the technique in such a location, provided that the cortex is intact and acts as a barrier avoiding excessive temperature near the spinal cord, as stressed by Dupuy *et al* (7). Therefore, radiofrequency ablation in the spine appears as a safe technique if the lesion is not adjacent to neural structures and the bone cortex is intact ; in case the lesion is next to the nervous system, the best method is excision biopsy (12).

The most extensive series published belongs to Rosenthal *et al* (24), who treated 263 patients, with a success rate of 89% after an average follow-up of two years, without any significant differences in outcome as compared with open surgery.

In our small series, very good results were achieved, with pain relief in all patients except one who had persisting discomfort not attributable to the lesion ; all have experienced complete disappearance of pain. None of the patients now require analgesic medication. All returned successfully to their work, studies and sport activities.

The downside of this technique is that no tissue specimen is obtained for pathology study. According to current literature, histological confirmation is not mandatory, as the clinical symptoms together with the preoperative diagnostic workup should be sufficient to establish the diagnosis (4,19).

In our experience, complications occurred in two cases : transient local hypoaesthesia, already reported by others (11), was seen in one case and skin burn that healed in two days in a patient with an osteoid osteoma in the subcutaneous part of the tibia. Nevertheless, skin burns, described in literature, can be avoided using radiofrequency bipolar electrodes instead of monopolar electrodes (16). Another problem described consists in lesions of neurovascular structures, as a result of inflammation and oedema that is produced in a closed anatomical area. In tumours close to articular surfaces, there is a risk of thermal injury to the cartilage, but studies are not conclusive because of absence of a long-

term follow-up of the patients that showed incipient degenerative changes (24). In the study made by Papagelopoulos *et al* (18), they treated 16 intra-articular osteoid osteomas of the hip without any complications and pain was relieved in every patient after the procedure.

Specific imaging has proved ineffective to monitor the evolution after treatment. Although post-operative NMR detects temporary changes in the cancellous bone (5), it is not recommended to perform it routinely as elimination of the tumour is only established through disappearance of the pain, irrespective of the imaging.

Recurrence has been reported in some cases in which the nidus was larger than 10 mm, presumably as a result of incomplete ablation of tumorous tissue. Therefore in lesions in which the nidus is larger than 10 mm, it is advisable to carry out several cycles of radiofrequency application in the same procedure, to ensure complete elimination of the lesion, as the radiofrequency guide has an effective area of 10 mm.

## CONCLUSIONS

CT-guided radiofrequency ablation of osteoid osteoma is neither invasive nor damaging. It has achieved a high rate of pain relief with a small morbidity rate in this series. It can be carried out on a one-day clinic basis. In cases in the lower extremity, immediate full-weight bearing is allowed following the procedure. Open surgery should be used only for cases in which the diagnosis is uncertain, or when the lesion is located near an important neurovascular structure and cannot be removed completely (15).

### Acknowledgement

We thank the anaesthesiology department and the radiology department, especially Martin P, Paloma E and Molina F.

## REFERENCES

1. Adam G, Keulers P, Vormerk D, *et al*. [The percutaneous CT-guided treatment of osteoid osteomas : a combined procedure with a biopsy drill and subsequent ethanol injection.] (in German). *Rofo* 1995 ; 162 : 232-235.
2. Arnoczky SP, Aksan A. Thermal modification of connective tissues : basic science considerations and clinical implications. *J Am Acad Orthop Surg* 2000 ; 8 : 305-313.
3. Barei DP, Moreau G, Scarborough MT, Neel MD. Percutaneous radiofrequency ablation of osteoid osteoma. *Clin Orthop* 2000 ; 373 : 115-124.
4. Campanacci M, Ruggieri P, Gasbarrini A, Ferraro A, Campanacci L. Osteoid osteoma direct visual identification and intralesional excision of the nidus with minimal removal of bone. *J Bone Joint Surg* 1999 ; 81-B : 814-820.
5. Cantwell CP, Kerr J, O'Byrne J, Eustace S. MRI features after radiofrequency ablation of osteoid osteoma with cooled probes and impedance-control energy delivery. *AJR Am J Roentgenol* 2006 ; 186 : 1220-1227.
6. Cantwell CP, Obyrne J, Eustace S. Current trends in treatment of osteoid osteoma with an emphasis on radiofrequency ablation. *Eur Radiol* 2004 ; 14 : 607-617.
7. Dupuy DE, Hong R, Oliver B, Goldberg SN. Radiofrequency ablation of spinal tumors : temperature distribution in the spinal canal. *AJR Am J Roentgenol* 2000 ; 175 : 1263-6.
8. Finstein JL, Hosalkar HS, Ogilvie CM, Lackman RD. Case reports : an unusual complication of radiofrequency ablation treatment of osteoid osteoma. *Clin Orthop* 2006 ; 448 : 248-251.
9. Gangi A, Dietemann JL, Clavert JM *et al*. [Treatment of osteoid osteoma using laser photocoagulation : a propos of 28 cases.] (in French). *Rev Chir Orthop* 1998 ; 84 : 676-684.
10. Gibbs CP, Lewis VO, Peabody T. Beyond bone grafting : techniques in the surgical management of benign bone tumors. *Instr Course Lect* 2005 ; 54 : 497-503.
11. Glaibermn CB, Brown DB. Reversible neuropathy caused by overuse following radiofrequency ablation of metastatic pelvic lesions. *J Vasc Interv Radiol* 2004 ; 15 : 1307-1310.
12. Hadjipavlou AG, Lander PH, Marchesi D, Katonis PG, Gaitanis IN. Minimally invasive surgery for ablation of osteoid osteoma of the spine. *Spine* 2003 ; 28 :E 472-477.
13. Jackson RP, Reckling FW, Mantz FA. Osteoid osteoma and osteoblastoma. Similar histologic lesions with different natural histories. *Clin Orthop* 1977 ; 128 : 303-313.
14. Kjar RA, Powell GJ, Schlicht SM, Smith PJ, Slavin J, Choong PF. Percutaneous radiofrequency ablation for osteoid osteoma : experience with a new treatment. *Med J Aust* 2006 5 ; 184 : 563-565.
15. Lindner NJ, Ozaki T, Roedl R, Gosheger G, Winkelmann W, Wortler K. Percutaneous radiofrequency ablation in osteoid osteoma. *J Bone Joint Surg* 2001 ; 83-B : 391-396.
16. Mahnken AH, Tacke JA, Wildberger JE, Gunther RW. Radiofrequency ablation of osteoid osteoma : initial results with a bipolar ablation device. *J Vasc Interv Radiol* 2006 ; 17 : 1465-1470.
17. Osti OL, Sebben R. High-frequency radio-wave ablation of osteoid osteoma in the lumbar spine. *Eur Spine J* 1998 ; 7 : 422-425.

18. **Papagelopoulos PJ, Mavrogenis AF, Kyriakopoulos CK et al.** Radiofrequency ablation of intra-articular osteoid osteoma of the hip. *J Int Med Res* 2006 ; 34 : 537-544.
19. **Portabella F, Serra J, Mast R et al.** [Treatment of osteoid osteoma by CT-guided radiofrequency ablation] (in Spanish). *Rev Ortopedia y Traumatología SECOT* 2004 ; 48 : 31-37.
20. **Ramos L, Santos JA, Santos G, Guiral J.** Radiofrequency ablation in osteoid osteoma of the finger. *J Hand Surg* 2005-A ; 30 : 798-802.
21. **Ramos R, Sánchez-López JM, García-Alonso M.** [Osteoid osteoma of the sacrum. A rare lesion and a difficult diagnosis. Presentation of three cases] (in Spanish). *Reva Ortopedia y Traumatología SECOT* 2003 ; 47 : 350-353.
22. **Resnick RB, Jarolem KL, Sheskier SC, Desai P, Cisa J.** Arthroscopic removal of an osteoid osteoma of the talus : a case report. *Foot Ankle Int* 1995 ; 16 : 212-215.
23. **Rosenthal DI, Alexander A, Rosenberg AE, Springfield D.** Ablation of osteoid osteomas with a percutaneously placed electrode : a new procedure. *Radiology* 1992 ; 183 : 29-33.
24. **Rosenthal DI, Hornicek FJ, Torriani M, Gebhardt MC, Mankin HJ.** Osteoid osteoma : percutaneous treatment with radiofrequency energy. *Radiology* 2003 ; 229 : 171-175.
25. **Sans N, Galy-Fourcade D, Assoun J et al.** Osteoid osteoma : CT-guided percutaneous resection and follow-up in 38 patients. *Radiology* 1999 ; 212 : 687-692.
26. **McGarry SV, Gibbs CP.** Radiofrequency ablation in bone neoplasia. *Curr Opin Orthop* 2005 ; 16 : 484-488.
27. **Skjeldal S, Lilleas F, Folleras G et al.** Real time MRI-guided excision and cryo-treatment of osteoid osteoma in os ischii : a case report. *Acta Orthop Scand* 2000 ; 71 : 637-638.
28. **Soong M, Jupiter J, Rosenthal D.** Radiofrequency ablation of osteoid osteoma in the upper extremity. *J Hand Surg* 2006 ; 31-A : 279-283.