

CASE REPORT

TRAUMATIC HERNIA OF THE ABDOMINAL WALL AFTER PELVIC AND ACETABULAR FRACTURE : A CASE REPORT

O. BORENS¹, J. F. FISCHER¹, V. BETTSCHART², E. MOUHSINE¹

Traumatic hernia of the abdominal wall is a rare and easily missed injury in the presence of major pelvic and abdominal lesions. We present a radiographically documented case of combined pelvic and acetabular fracture with a major contralateral traumatic hernia with avulsion of the internal oblique, the external oblique and the transverse abdominal muscles diagnosed four months after the initial trauma. To our knowledge no similar case has been described in the current literature.

Keywords : traumatic abdominal hernia ; muscle avulsion ; pelvic fracture ; acetabular fracture.

Mots-clés : hernie traumatique de la paroi abdominale ; avulsion musculaire ; fracture du bassin ; fracture du cotyle.

INTRODUCTION

Intraabdominal lesions are very frequent in patients who sustain blunt trauma with a pelvic and/or acetabular fracture. Lesions of the abdominal wall leading to symptomatic herniation are a rare entity however, and only a few articles on this subject can be found in the current literature (2-4, 8). Traumatic abdominal hernia is described by Damschen *et al.* (4) as herniation through disrupted musculature and fascia associated with adequate trauma, without skin penetration and no evidence of a prior hernial defect at the site of the injury. The present report describes a large traumatic abdominal hernia detected four months after a combined pelvic and acetabular fracture on the contralateral side. Before the correct diagnosis had been

established this mass was thought to be a large hematoma.

CASE REPORT

A 37-year-old unrestrained female driver was seen in our emergency department following an accident in which her car rolled several times. Physical and radiographic examination revealed a retrosternal hemomediastinum, bilateral pulmonary contusions and fractures of the left fifth and seventh ribs. Ultrasonographic and CT-scan investigations of the abdomen showed contusions of the liver and spleen and a traumatic rupture of the bladder, as well as fractures of the pelvis and the acetabulum (fracture of the four pubic rami, fracture-dislocation of the left sacroiliac joint, fracture of both columns of the left acetabulum, comminuted fracture of the left iliac wing) (fig. 1). Emergency treatment consisted of bladder suture by the urologists using a lower midline abdominal incision and placement of a transcondylar Steinman pin through the left femur for traction on the left lower extremity.

¹ Department of Orthopedic Surgery and Trauma, Centre Hospitalier Universitaire Vaudois, Lausanne, Switzerland.

² Department of Surgery, Centre Hospitalier Universitaire Vaudois, Lausanne, Switzerland.

Corresponding author : Olivier Borens, Department of Orthopedic Surgery and Trauma, Centre Hospitalier Universitaire Vaudois, Rue du Bugnon 46, 1011 Lausanne, Switzerland. E-mail : Borens@hotmail.com.

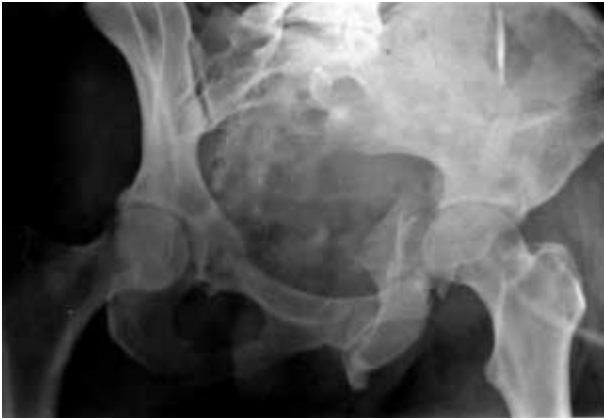

Fig. 1. — Preoperative x-ray of the pelvis showing an AO type C-3 fracture.

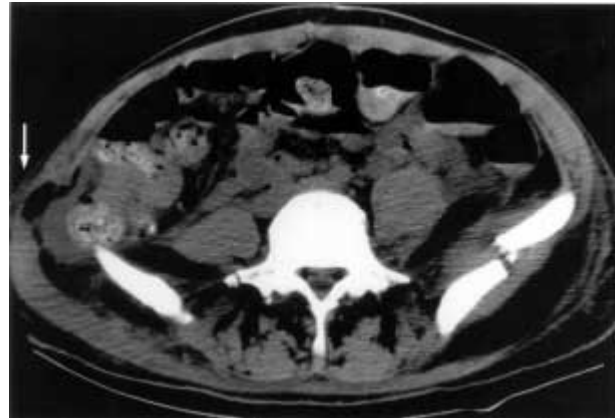


Fig. 3. — Original CT-scan showing the pelvic fracture, ipsilateral hematoma and the contralateral hernia (white arrow shows hernia).

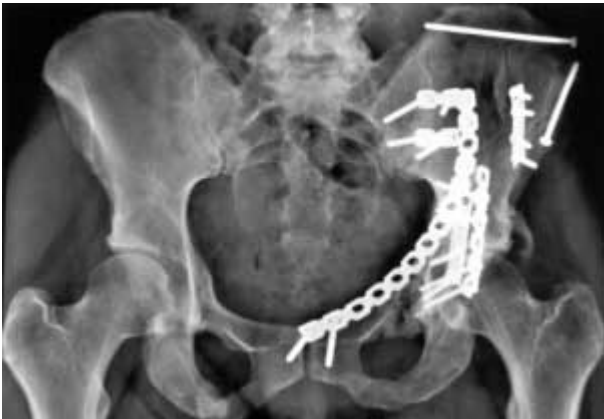

Fig. 2. — Postoperative x-ray of the pelvis

Surgical treatment of the pelvic and acetabular fracture was postponed until the twelfth day after admission owing to pulmonary fat embolism. At that time an open reduction and internal fixation of the iliac wing fracture and the acetabular fracture was done using a combined ilio-inguinal (Letournel) and a Kocher-Langenbeck posterior approach (fig. 2). During follow-up there were no complications of the left-sided pelvic and acetabular fractures and the bladder lesion. Postoperatively a mass the size of a grapefruit could be felt on the right-sided iliac crest without any other clinical findings. This was associated with discomfort and mild pain. The mass was thought to be a hematoma, and no CT-scan was done nor was there a correct interpretation of the initial abdominal CT-scan (fig. 3).

Three months after the accident the patient left our rehabilitation department and was seen one month later at her follow-up visit. She complained about persistent pain about her right iliac crest and the existence of the mass. A new physical exam showed a tender spot on the right iliac crest, and a clear breach in the insertion of the abdominal muscles could be felt. An irreducible bulge was palpated directly under the skin, and a soft-tissue bulge was produced with a Valsalva maneuver. On auscultation bowel sounds were clearly audible. A traumatic herniation through the abdominal wall was then suspected, and an ultrasound and an MRI-scan were done. The MRI confirmed the diagnosis of a complete traumatic herniation of the abdominal wall with a full thickness avulsion from the right iliac-crest of the internal oblique, external oblique and the transverse abdominal muscles along with a herniated segment of colon (figs. 4, 5). Surgery was then recommended for her symptomatic disability and pain. Under general anesthesia the hernia was repaired through an oblique incision centered over the apex of the hernia. On dissecting the subcutaneous fat the hernial sac was seen through a well-defined ring which consisted laterally of the superior margin of the iliac crest and proximally, distally and medially of the three avulsed abdominal muscles. After complete mobilization of the hernial sac, the sac was closed by transosseous refixation of the avulsed abdominal muscles to the pelvis using nonabsorbable sutures.

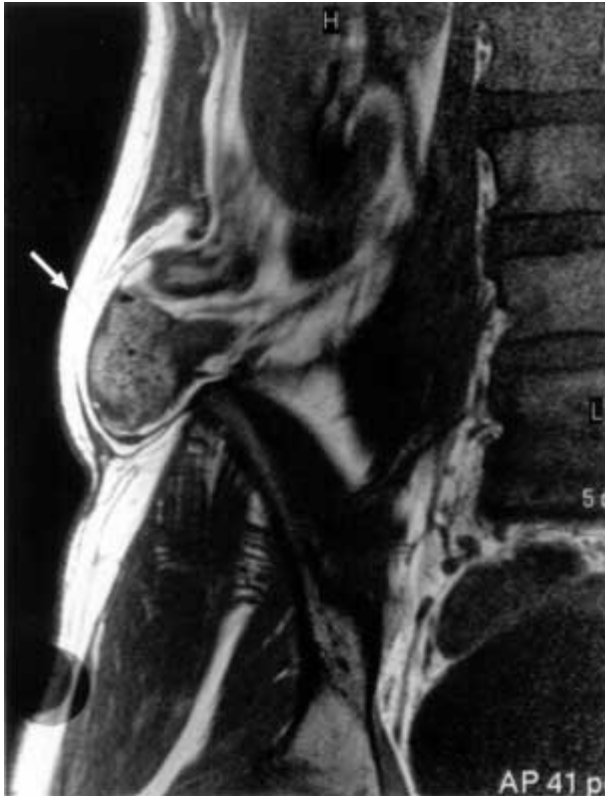

Fig. 4. — MRI 4 months postinjury, frontal view

To further protect our fixation we also used a supplementary prosthetic mesh. The 18 mo. postoperative follow-up was uneventful, and the patient has remained asymptomatic.

DISCUSSION

Although intra-abdominal lesions after blunt abdominal trauma are a fairly common occurrence, traumatic herniation of the abdominal wall is a relatively rare entity (2, 4-8). Several different mechanisms of traumatic herniation of the abdominal wall have been described. As mentioned by Damschen *et al.* (4) and others (1, 10), one known mechanism in patients involved in car crashes and wearing lap belts is a shearing force that passes over the iliac crest, thus causing avulsion of the muscles from their insertions in the pelvis. This is the so-called seatbelt hernia. Another known mechanism is a direct blow to the abdominal wall by a small object like a handlebar (3, 4, 8, 11) or a

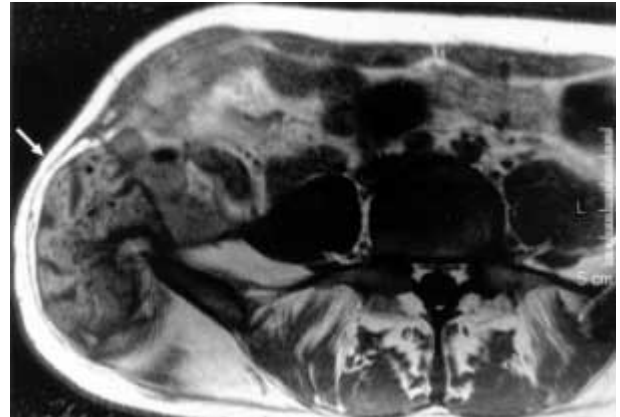

Fig. 5. — Transverse view T1, showing herniation of the abdominal wall, avulsion from the right iliac crest of the internal and external oblique and transverse abdominal muscle and herniated segment of the colon (white arrows show hernia).

hockey-stick, which disrupts the muscular fascia causing the hernia. In these cases, these moderate-sized blunt instruments are not small enough to penetrate the skin but are large enough to widely disperse their kinetic energy (8). Other mechanisms include herniation due to a fall, with acute elevation of intraabdominal pressure as described in World War II paratroopers, or crush injuries causing tangential shearing stresses (5). Our patient was not wearing a lap- or seatbelt, and there were no signs of local bruising or laceration on the right iliac crest.

In our patient it appears that the avulsion of the abdominal muscles was caused by a tearing mechanism secondary to a force on the contralateral side with lateral compression injury of the pelvis and acetabulum, an entity that has not yet been described in the current literature. This lesion is perhaps caused by the relative inelasticity of the abdominal muscles due to the contraction of the abdominal muscles in anticipation of a blow; a mechanism described by Clain (3). After the impact that leads to the pelvic and acetabular fractures, the patient is violently bent to the side of the impact, causing a stretching force that avulses the abdominal muscles of the contralateral side. This type of traumatic hernia does not correspond to any of the three groups of hernias related to pelvic fractures described by Ryan (9) in 1971. Group one are hernias following an anteroposterior force with

rupture of the rectus abdominis muscle, or its tendon, in the region of its attachment to the pubic bone. Group two are hernias due to lateral or vertical forces that cause a direct hernia of the posterior abdominal wall, corresponding to a muscle tearing extension of fractures of the superior ramus of the pubis or body of pubis. The third group are hernias related to a man-made pelvic fracture, such as osteotomy of the pelvis, and are of iatrogenic origin. Several authors mention CT-scan as the most efficient radiological study to detect a hernia of the abdominal wall (2, 5). In our own case that was verified, and we clearly missed the diagnosis on our initial CT-scan. Delayed diagnosis of a traumatic hernia has been described by other authors (6, 7). Kassassey *et al.* (6) established the correct diagnosis in a patient after several months only after a swelling appeared in the flank. The outcome in these cases of delayed diagnosis were, as in our case, favorable as large traumatic hernias rarely lead to incarceration of intraabdominal contents.

In summary, in patients sustaining blunt pelvic trauma by lateral compression (AO type B2, B3 or C3 fractures), avulsion of the abdominal muscles on the contralateral side is possible. A thorough physical exam and adequate evaluation of abdominal pain and tenderness is necessary. Routine plain abdominal radiographs are standard, but any concern requires ultrasound, CT-scan or MRI, and a detailed and correct interpretation of these exams must be done to exclude this unusual lesion.

REFERENCES

1. Appleby J. P., Nagy A. G. Abdominal injuries associated with the use of seatbelts. *Am. J. Surg.*, 1989, 157, 457-458.
2. Breneman F. D., Boulanger B. R., Antonyshyn O. Surgical management of abdominal wall disruption after blunt trauma. *J. Trauma*, 1995, 39, 539-544.
3. Clain A. Traumatic hernia. *Brit. J. Surg.*, 1964. 51. 549-550.
4. Damschen D. D., Landercaasper J., Cogbill T. H., Stolee R. T. Acute traumatic abdominal hernia : Case reports. *J. Trauma*, 1994, 36, 273-276.
5. Drago S. P., Nuzzo M., Grassi G. B. Traumatic ventral hernia : report of case, with special reference to surgical treatment. *Surg. Today*, 1999, 29, 111-114.
6. Kassassey A., Mariette D., Elrody F. Les éventrations traumatiques du flanc. A propos de deux observations. *Ann. Chir.*, 1998, 52, 1065-1068.

7. Martinez B. D., Stubbe N, Rakower S. R. Delayed appearance of traumatic ventral hernia : A case report. *J. Trauma*, 1976, 16, 242-243.
8. Perez V. M., McDonald A. D., Ghani A., Bleacher J. H. O. Handlebar hernia : A rare traumatic abdominal wall hernia. *J. Trauma*, 1998, 44, 568.
9. Ryan E. A. Hernias related to pelvic fractures. *Surg. Gyn. Obstet.*, 1971, 133, 440-446.
10. Wagner A. C. Disruption of abdominal wall musculature : Unusual feature of seat belt syndrome. *Am J. Roentgenol.*, 1979, 33, 753-754.
11. Yarbrough D. R. Intra-abdominal injury with handlebar hernia : Case report and literature review. *J. Trauma*, 1996, 40, 116-118.

SAMENVATTING

O. BORENS, J. F. FISCHER, V. BETTSCHART, E. MOUHSINE. Traumatische herniatie van de buikwand met een bekken- en acetabulum fractuur. Bespreking van een geval.

Traumatische herniatie van de buikwand is zeldzaam en kan gemakkelijk miskend worden in aanwezigheid van majeure abdominale en bekken letsels. We brengen een geval van radiografisch gedocumenteerde bekken- en acetabulum fracturen en een grote contralaterale hernia van de abdominale inhoud door afrukking van de m. obliquus internus, de m. obliquus externus en m. transversus abdominis. De diagnose werd slechts gesteld 4 maand na het trauma, alhoewel het letsel op de eerste documenten was te zien.

RÉSUMÉ

O. BORENS, J. F. FISCHER, V. BETTSCHART, E. MOUHSINE. Hernie traumatique de la paroi abdominale après fracture du bassin et du cotyle : présentation d'un cas.

Les hernies traumatiques de la paroi abdominale sont rares et passent facilement inaperçues en présence de lésions graves du bassin et de l'abdomen. Les auteurs présentent, avec son illustration radiographique, un cas de fracture associée du bassin et du cotyle qui s'accompagnait d'une volumineuse hernie traumatique du côté opposé, par avulsion du petit oblique, du grand oblique et du transverse de l'abdomen ; cette lésion fut diagnostiquée 4 mois après le traumatisme initial. A leur connaissance, aucun cas semblable n'a été décrit à ce jour dans la littérature.