



Idiopathic chondrolysis of the hip A case report

Jens FRANÇOIS, Michiel MULIER

From the University Hospital Pellenberg, Lubbeek (Leuven), Belgium

Idiopathic chondrolysis of the hip is a rare condition occurring mainly in adolescents and is characterised by a rapidly progressive destruction of the articular cartilage in the coxofemoral joint. Patients report intense pain, motion restriction and often limping due to shortening of the limb. The aetiology is not elucidated. Medical imaging techniques form the cornerstone for differential diagnosis. Additionally biological markers for inflammation and infections should be studied. Conservative treatment focuses on pain control and preservation of joint mobility. Because published results of surgical treatment are not conclusive and arthroplasty in young patients is controversial, there is up till now no consensus on the treatment algorithm. Some authors advocate conservative treatment until spontaneous fusion. A case of idiopathic chondrolysis conventionally managed is reported.

Keywords : hip ; chondrolysis ; idiopathic ; child.

for which no cause could be demonstrated. He named this condition *idiopathic chondrolysis of the hip (ICH)*. Since then, other similar cases have been described (2,4,6,8,13,14,18,19). ICH is mainly seen in adolescents and is characterised by a rapidly progressive destruction of the articular cartilage in the coxofemoral joint. Patients report intense pain, motion restriction and often limping due to a shortening of the limb. The aetiology is not elucidated. Bone scans have a high specificity while radiography and MRI have a high sensitivity as complementary diagnostic tools (17). To rule out inflammatory and infectious causes for the hip pain, synovial fluid and biopsy material may be tested (10). In a number of cases the destruction proved to be reversible (14). Conservative treatment focuses on pain relief, traction and physiotherapy (13) and long lasting walking with crutches to alleviate weight bearing (14). The natural history of the disease terminates in spontaneous fusion (19).

INTRODUCTION

Chondrolysis of the hip is defined as an extensive loss of articular cartilage of the femoral head and acetabulum. It is a well-recognised complication in slipped capital femoral epiphysis (SCFE) and has also been described in association with prolonged immobilisation, severe trauma, septic arthritis, rheumatoid arthritis and Stickler syndrome. In 1971 however, Jones (11) reported on a series of similar cases of chondrolysis of the hip,

■ Jens François, MD, Fellow in Orthopaedic Surgery.

■ Michiel Mulier, MD, PhD, Senior Consultant in Orthopaedic Surgery.

Department of Orthopaedic Surgery, UZ Pellenberg, Lubbeek, Belgium.

Correspondence : M. Mulier, MD, PhD, Department of Orthopaedic Surgery, U.Z. Pellenberg, K.U.Leuven, Weligerveld 1, B-3212 Pellenberg, Belgium.

E-mail : michiel.mulier@uz.kuleuven.ac.be.

© 2007, Acta Orthopædica Belgica.

Joint distraction (arthrodiastasis) for an average of 94 days resulted in improvement of movement and a widening of the articular space (2). These findings were later confirmed by Thacker *et al* (20) who recommended hinged distraction arthroplasty as an alternative to arthrodesis. Arthrotomy, capsulotomy and skeletal traction have been used. However, return of normal motion was not seen (13). Intra-articular fusion using external fixation with precise positioning has been used in young patients with incapacitating painful and stiff hip, resulting in pain relief and an increase in activity (18). Up till now there is no consensus with regard to which treatment should be preferred and, if surgical intervention is considered, what the best timing is. This paper reports on a patient who showed similarities with previously described cases of ICH treated conservatively, and has now been followed for more than 7 years.

CASE REPORT

A Caucasian girl, 14 years of age, without previous significant illnesses, consulted an orthopaedic surgeon in April 1997. She presented with a painful left hip, associated with a limp. The pain occurred after a minor bicycle accident, in which she fell on her left knee, two days earlier. Upon examination, the left hip was tender, but showed a normal albeit painful range of motion. Radiographs of both hips and of the left knee were considered normal. She was advised to use two crutches for partial weight bearing and to come back for re-evaluation three weeks later.

Four months later, the girl returned to the same orthopaedic surgeon. Since the first contact there had not been any improvement of the pain. Physical examination showed a positive Trendelenburg sign. Radiographic findings included narrowing of the left coxofemoral joint space and protrusio acetabuli. A Technetium bone scan showed increased isotope uptake over the left hip joint. In addition a nuclear magnetic resonance scan was performed. This showed a considerable amount of fluid in the left coxofemoral joint space and oedema of both femoral head and acetabulum. The treatment was not altered.

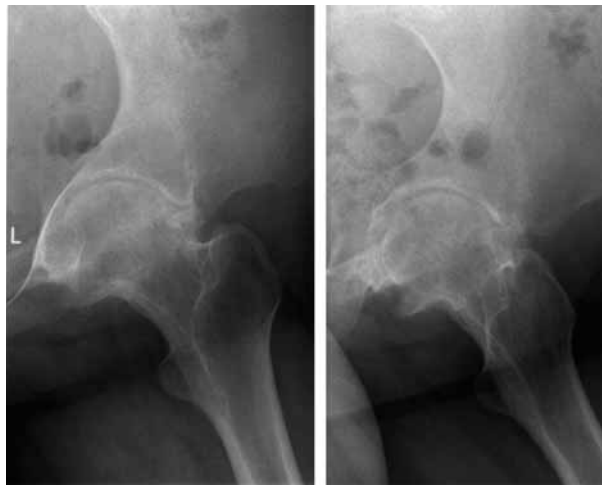

Fig. 1. — Radiograph of the left hip on admission in our institution, showing severe destructive arthritis of the left hip. The articular cartilage has almost vanished and there are signs of severe destruction of the subchondral bone.

When two months later she still complained of pain in the left hip, the girl was admitted for further investigation and treatment with NSAID, skin traction and physiotherapy. Radiological examination of the left hip showed further narrowing of the joint space. CT-scan confirmed the left hip joint effusion and protrusio acetabuli; in addition subchondral cysts in the femoral head and in the acetabulum were visualised, together with some opacities ventral to the femoral head and neck. Osteophytes were also present. She gradually became pain free, but the left hip progressively became stiffer despite the treatment. For this reason she was transferred to our department.

On admission no elective tenderness in the region of the left hip could be elicited. Range of motion was limited to flexion from 20 to 90° and 60° of abduction. Both internal and external rotation were limited and very painful. The radiographic findings of chondrolysis of the left hip joint and bilateral acetabular protrusion were confirmed. Thorough rheumatological work-up and in depth anamnesis revealed that the girl's mother suffered from Crohn's colitis. All laboratory results, including rheumatoid antibodies, antinuclear antibodies and Borrelia serology were within normal limits. A test for HLA B27 was positive. A CT-scan of the

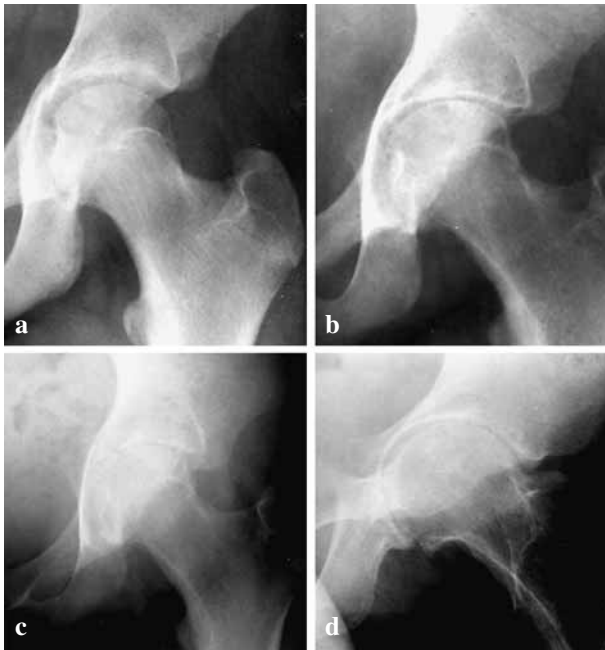


Fig. 2. — Progressive deterioration of the joint space of the left hip as shown by comparison of radiographs taken in April 1997 (a), August 1997 (b), October 1997 (c) and 1998 (d).

sacroiliac joints was normal. A tuberculin PPD intradermal test was negative. Joint fluid was aspirated from the left hip joint and was submitted to biochemical and bacteriological examination, but no infection could be demonstrated. Two weeks later the patient left the hospital. A treatment consisting of NSAID (tolmetine 3×400 mg/d), nightly skin traction and physiotherapy was advised.

During the following months pain remained minimal, but the range of motion was further reduced. In December 1997 an abduction contracture of 10 degrees was measured, which increased to 30 degrees over the next two months. Another four months later the range of motion had become very limited: flexion from 20 to 40 degrees and fixed abduction deformity of 35 degrees, with absence of rotation. On the latest follow-up examination, the situation appeared unchanged. In less than one year the radiographic joint width of the left coxofemoral joint decreased from 4 to 1.5 mm (measured according to Bleck's method) and a pain free fibrous ankylosis of the left hip developed.

Figure 2 shows the progressive deterioration of the joint space over a one-year period. At a follow-up of seven years, no other joints have been affected.

Since our patient presented already with a considerable loss of range of motion of the hip, we thought surgery by means of a capsulectomy would not improve her condition. In accordance to the patient's wish, we therefore preferred to await the spontaneous evolution of this condition, while trying to treat the pain and the functional impairment. At this moment her hip is almost completely ankylosed, unfortunately not in a functional position. However, she is now almost free of pain and walks well without crutches. She seems to have coped with this situation.

DISCUSSION

Patients affected by idiopathic chondrolysis of the hip most frequently consult because of pain in the hip and / or the knee (8). Until today no specific diagnostic criteria exist. In daily clinical practice the diagnosis is made by exclusion of other, more common causes of acute or chronic monoarticular hip pain. Radiographic assessment of the hip with anteroposterior and lateral views, compared with films of the contralateral hip are essential in the diagnostic work-up. Since hip pain of sudden onset in children can be suggestive for slipped capital femoral epiphysis, radiographs in the Lauenstein position must be obtained. During the evolution of ICH, the joint space can either show further narrowing, or recover partially or completely. However there is no correlation between radiographic and clinical recovery. MRI depicts marrow changes earlier than any other imaging method. Bone scans and scintigraphy have a high sensitivity (6,15). Technetium bone scintigraphy typically shows increased uptake in both acetabulum and femoral head.

Protrusio acetabuli (PA) is of noteworthy importance in the radiographic work-up of children with mono-articular hip pain. PA in combination with a progressive loss of coxofemoral joint space, is suggestive for chondrolysis of the hip, whether primary (idiopathic) or secondary. However, PA is a descriptive, radiological phenomenon and is

associated with a large number of other clinical conditions such as hypermobility syndromes (Marfan syndrome, Stickler syndrome, osteogenesis imperfecta, juvenile idiopathic arthritis, systemic, psoriatic or enthesitis related arthritis), infection related arthritis, sickle cell disease, neoplastic disorders, metabolic disorders and iatrogenic causes (e.g. radiotherapy or corticosteroid induced) (1,22).

All biochemical and microbiological tests have to stay within normal limits. This includes inflammatory parameters, bacterial serology, rheumatic antibodies (antinuclear antibodies, rheumatoid factor), cultures of joint fluid aspiration, including Löwenstein (9). Some authors report HLA B27 typing has to be negative as well, although there is no general agreement. We found one single report on a HLA B27-positive patient with ICH. With a follow-up of seven years, no rheumatic involvement in our patient could be demonstrated. Synovial biopsy does not seem to help in the diagnosis as it showed in no instance more than "chronic non-specific synovitis".

In general, trauma is considered to be a separate cause of chondrolysis of the hip. Therefore post-traumatic chondrolysis is strictly excluded in a number of publications. Other authors included patients with minor trauma in their series. It is obvious that fractures and dislocations of the hip can cause direct destruction of the articular cartilage. In 1974 Mankin (15,16) published a study on the reaction of articular cartilage to mechanical trauma. He concluded that only a lesion as deep as the subchondral bone results in such scarring that the joint congruency is disturbed and secondary arthritis is caused. Minor trauma of the hip or pelvis rarely gives rise to such destruction.

Until today no evidence concerning the aetiology of ICH has been presented. Therefore the treatment of this condition has been mainly symptomatic. Anti-inflammatory drugs, both non-steroidal and corticosteroids, have been advocated with success. In addition most authors agree to unload the affected hip joint as soon as possible by means of bed rest and skin traction. The use of crutches is subsequently encouraged. Physiotherapy (continuous passive motion) seems to be important to

preserve a good range of motion, especially in the first few months. Immobilisation of the hip joint must be avoided since this can result in further stiffening and eventually fibrous ankylosis.

The role of surgery is controversial. Section of muscles and tendons, capsulotomies and subtotal capsulectomy have all been performed with variable success (3,13,18,20). Total hip arthroplasty in patients under the age of 20 is controversial, has a high failure rate and is therefore avoided in this patient group (21).

CONCLUSION

Until now the exact aetiology of ICH remains unknown and the diagnosis is mainly made by exclusion of other possible causes of monoarticular hip pain. The diagnosis in our patient was made one year after the onset of the symptoms. The fact that the pain occurred after a minor trauma, that the girl's mother suffers from Crohn's colitis and the positive HLA B27 testing caused confusion in the diagnostic process and partially explains the expectant attitude concerning therapy. ICH remains a mysterious condition of unknown aetiology with deleterious effects upon a young patient's hip. Until more basic knowledge is gained about ICH, it will remain difficult to timely diagnose and accurately treat this condition.

REFERENCES

1. Adib N, Owers KL *et al.* Isolated inflammatory coxitis associated with protrusio acetabuli : a new form of juvenile idiopathic arthritis ? *Rheumatology (Oxford)* 2005 ; 44 : 219-226.
2. Bleck EE. Idiopathic chondrolysis of the hip. *J Bone Joint Surg* 1983 ; 65-A : 1266-1275.
3. Canadell J, Gonzales F, Barrios RH, Amillo S. Arthrodiastasis for stiff hips in young patients. *Int Orthop* 1993 ; 17 : 254-258.
4. del Couz Garcia A, Fernandez PL, Gonzalez MP, Garcia AC, Gonzalez LR, Jimenez JP. Idiopathic chondrolysis of the hip : long-term evolution. *J Pediatr Orthop* 1999 ; 19 : 449-454.
5. Donnan L, Einoder B. Idiopathic chondrolysis of the hip. *Aust N Z J Surg* 1996 ; 66 : 569-571.
6. Duncan JW, Nasca R, Schrantz J. Idiopathic chondrolysis of the hip. *J Bone Joint Surg* 1979 ; 61-A : 1024-1028.

7. **Harland U, Krappel FA.** [Value of ultrasound, CT, and MRI in the diagnosis of slipped capital femoral epiphysis (SCFE).] (German). *Orthopäde* 2002 ; 31 : 851-856.
8. **He RG.** [Idiopathic chondrolysis of the hip-joint : report of two cases and review of the literature.] (Chinese). *Zhonghua Wai Ke Za Zhi* 1993 ; 31 : 599-601.
9. **Hughes RA, Tempos K, Ansell BM.** A review of the diagnoses of hip pain presentation in the adolescent. *Br J Rheumatol* 1988 ; 27 : 450-453.
10. **Johnson K, Haigh SF, Ehtisham, Ryder C, Gardner-Medwin J.** Childhood idiopathic chondrolysis of the hip : MRI features. *Pediatr Radiol* 2003 ; 33 : 194-199.
11. **Jones BS.** Adolescent chondrolysis of the hip joint. *S Afr Med J* 1971 ; 45 : 196-202.
12. **Koot MF, Berendsen HA et al.** [3 adolescents with hip pain caused by idiopathic chondrolysis.] (Dutch). *Ned Tijdschr Geneesk* 1993 ; 137 : 86-90.
13. **Korula RJ, Jebaraj I, David KS.** Idiopathic chondrolysis of the hip : medium- to long-term results. *ANZ J Surg* 2005 ; 75 : 750-753.
14. **Lejman T, Sulko J.** [Idiopathic chondrolysis of the hip.] (Polish). *Chir Narzadow Ruchu Ortop Pol* 2005 ; 70 : 97-100.
15. **Mankin HJ.** The reaction of articular cartilage to injury and osteoarthritis (second of two parts). *N Engl J Med* 1974 ; 291 : 1335-1340.
16. **Mankin HJ.** The reaction of articular cartilage to injury and osteoarthritis (first of two parts). *N Engl J Med* 1974 ; 291 : 1285-1292.
17. **Rachinsky I, Boguslavsky L, Cohen E, Hertzanu Y, Lantsberg S.** Bilateral idiopathic chondrolysis of the hip : a case report. *Clin Nucl Med* 2000 ; 25 : 1007-1009.
18. **Schoenecker PL, Johnson LO, Martin RA, Doyle P, Capelli AM.** Intra-articular hip arthrodesis without subtrochanteric osteotomy in adolescents : technique and short-term follow-up. *Am J Orthop* 1997 ; 26 : 257-264.
19. **Sivanantham M, Kutty MK.** Idiopathic chondrolysis of the hip : case report with a review of the literature. *Aust N Z J Surg* 1977 ; 47 : 229-231.
20. **Thacker MM, Feldman DS, Madan SS, Straight JJ, Scher DM.** Hinged distraction of the adolescent arthritic hip. *J Pediatr Orthop* 2005 ; 25 : 178-182.
21. **Torchia ME, Klassen RA, Bianco AJ.** Total hip arthroplasty with cement in patients less than twenty years old. Long-term results. *J Bone Joint Surg* 1996 ; 78-A : 995-1003.
22. **Van De Velde S, Fillman R et al.** The aetiology of protrusio acetabuli. Literature review from 1824 to 2006. *Acta Orthop Belg* 2006 ; 72 : 524-529.