



Pyogenic spondylitis as a complication of ear piercing : Differentiating between spondylitis and discitis

Miguel SEWNATH, Tina FABER, Rene CASTELEIN

From the University Medical Centre Utrecht, The Netherlands

We report what is, to our best knowledge, the first case of pyogenic spondylitis following ear piercing, a common and popular cosmetic procedure. The spondylitis was adequately treated with antibiotics and brace. The value of additional diagnostic measures in differentiating between spondylitis and discitis is discussed.

Keywords : ear piercing ; pyogenic spondylitis.

INTRODUCTION

Piercing is being viewed as a sign of beauty, individuality, or group identity and therefore it is popular among young people (3, 7). Several complications after ear piercing have been described. Local complications are a split or tear of the earlobe (5). Systemic complications are also known, such as conversion to hepatitis seropositivity or non-menstrual toxic shock syndrome (4, 6). To date no reports of a spondylitis after ear piercing induced bacteraemia have been published. The objective of this case report is to present a case of ear piercing after which a bacteraemia caused osteomyelitis of the distal tibial metaphysis and a lumbar vertebra.

Differentiating between spondylitis and discitis in children can be difficult because of its protean manifestations ; therefore the diagnostic workup is discussed.

CASE REPORT

A 13-year-old male was presented at the Department of Paediatrics at the Wilhelmina Children's Hospital / University Medical Centre Utrecht with low back pain after referral from a nearby community hospital. The patient had a medical history of meningitis with full recovery during the first year of life. He had no allergies, no toxic habits, and was not taking any medications.

Two months previously he had undergone an ear piercing performed at a tattooing and piercing establishment. During the first week following the ear piercing he noticed pain of the ear lobe, which disappeared on taking analgesics (aspirin), the following two weeks he manipulated the ear piercing

■ Miguel SEWNATH, MD, PhD, Resident.

■ Rene CASTELEIN, MD, PhD, Professor and Chair.

Department of Orthopaedics, University Medical Centre Utrecht, The Netherlands.

■ Tina FABER, MD, Staff Member.

Department of Paediatrics, Medical Center Leeuwarden, The Netherlands.

Correspondence : Rene M.C. Castelein, MD, PhD, Department of Paediatric Orthopaedic Surgery, Wilhelmina Children's Hospital, University Medical Centre Utrecht, P.O.B. 85090, 3508 AB Utrecht, The Netherlands.

E-mail : R.M.Castelein@umcutrecht.nl.

© 2007, Acta Orthopædica Belgica.

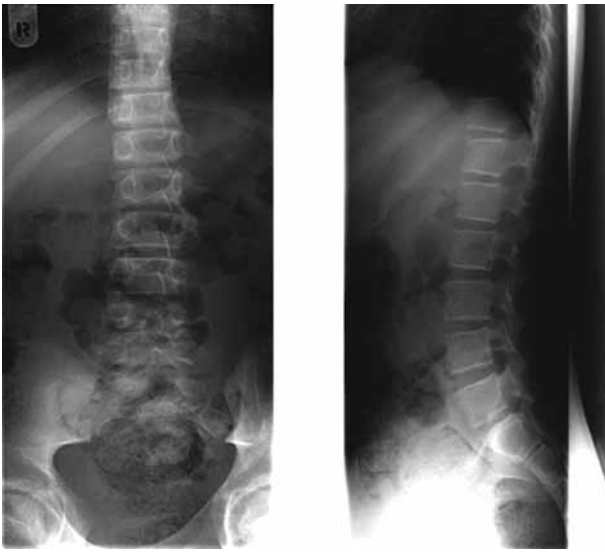


Fig. 1. — A posteroanterior and lateral lumbosacral spine film at presentation to our hospital before the diagnosis of spondylitis was established. There is equal height of both vertebra and disc space at each lumbar level.

with various earrings and apart from a passing erythema and slight discharge he had no further complications during the following weeks. Five weeks after the piercing he spontaneously suffered from a painful, swollen ankle on the right side, which confined him to bed. He had no previous trauma to the ankle.

On examination by the general practitioner there was a slight swelling on the lateral side of the ankle, no redness and a full range of motion. After a few days the ankle pain had subsided but a dull aching, low back discomfort, localised to the right lower back, had developed. There was no irradiation into the leg. He also experienced fever during three days. Sphincter function was not disturbed.

As the back pain worsened, the patient was presented at the nearby hospital. After work-up including an MRI of the spine, there was still uncertainty about the diagnosis; he was therefore referred to our tertiary centre. At presentation we saw a healthy patient with a temperature of 37°C. The physical findings were completely normal as were the findings at neurological examination. The pain of the right ankle had subsided and there was no swelling or tenderness.

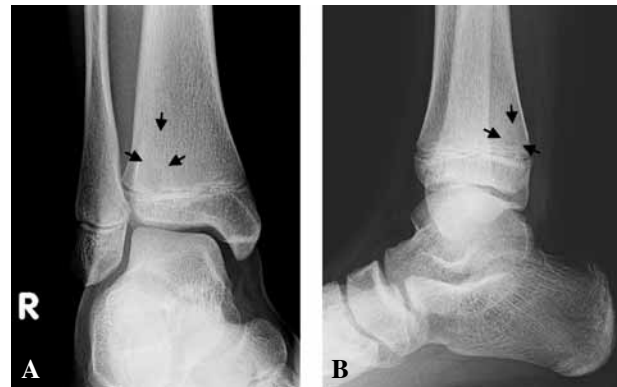

Fig. 2. — Postero-anterior and lateral radiograph of the patient's right ankle just after admission to the hospital and 4 weeks after temporary pain, swelling and erythema of the ankle is shown. The radiograph shows a subtle but circumscribed radiolucent lesion of the lateral (A) and dorsal (B) aspect of the metaphysis.

The leukocyte count was normal (9.000 cells/mm³), erythrocyte sedimentation rate was 40 mm/h and C-reactive protein level was 42 mg/L. Tuberculin skin test and stomach aspirate culture were normal.

Radiographs of the abdomen and chest were normal as was the initial radiographic evaluation of the postero-anterior and lateral lumbosacral spine films (fig 1). The radiograph of the distal part of the lateral tibia however showed a lytic lesion in the metaphysis suggestive for an osteomyelitis (fig 2). A whole body Technetium 99m scan revealed a distinct localised increased isotope uptake at one specific lumbar level in the mineral phase (fig 3). MRI of the lumbar spine displayed on the T1-weighted sagittal image a low-intensity signal at the third lumbar vertebral body and a high-intensity signal on the T2-weighted image, reflecting the increased water in the marrow produced by oedema and hyperaemia (fig 4). Therefore, the diagnosis of spondylitis was confirmed.

Blood cultures that were drawn during two episodes of fever, demonstrated positive cultures for *Staphylococcus aureus*. The patient was thus diagnosed with an osteomyelitis of vertebra L3 and

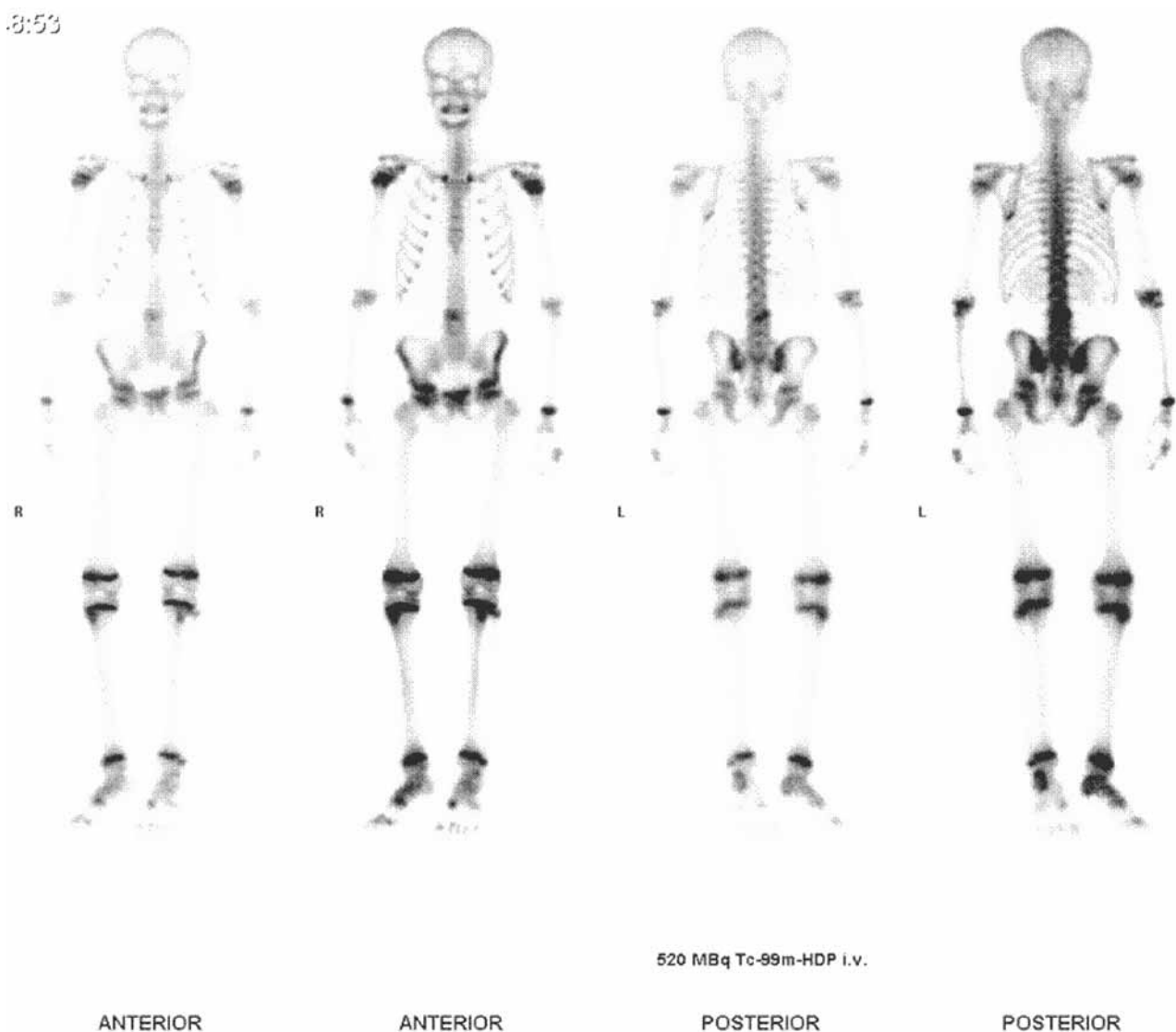

Fig. 3. — Whole body Technetium 99m scan revealed a distinct localised increased isotope uptake at one specific lumbar level in the mineral phase, both on the ventral and dorsal views.

directly thereafter treatment was started with intravenous antibiotics, bed rest and a body cast for comfort. After 7 days the CRP had fallen, all symptoms had disappeared and the patient was discharged from the hospital. Antibiotics were continued orally for an additional 5 weeks.

Laboratory values continued to be normal when the patient visited the outpatient clinic at 6 weeks follow-up and he did not have any signs or symptoms of an ongoing infection, therefore antibiotic

treatment was terminated. Follow-up radiographs of the lumbar spine revealed narrowing of the disc space between vertebra L3 and L4 and distinct irregularities of the endplate of the vertebra L3 (fig 5).

DISCUSSION

An awkward cause of osteomyelitis is presented here. Various scientific studies demonstrate that

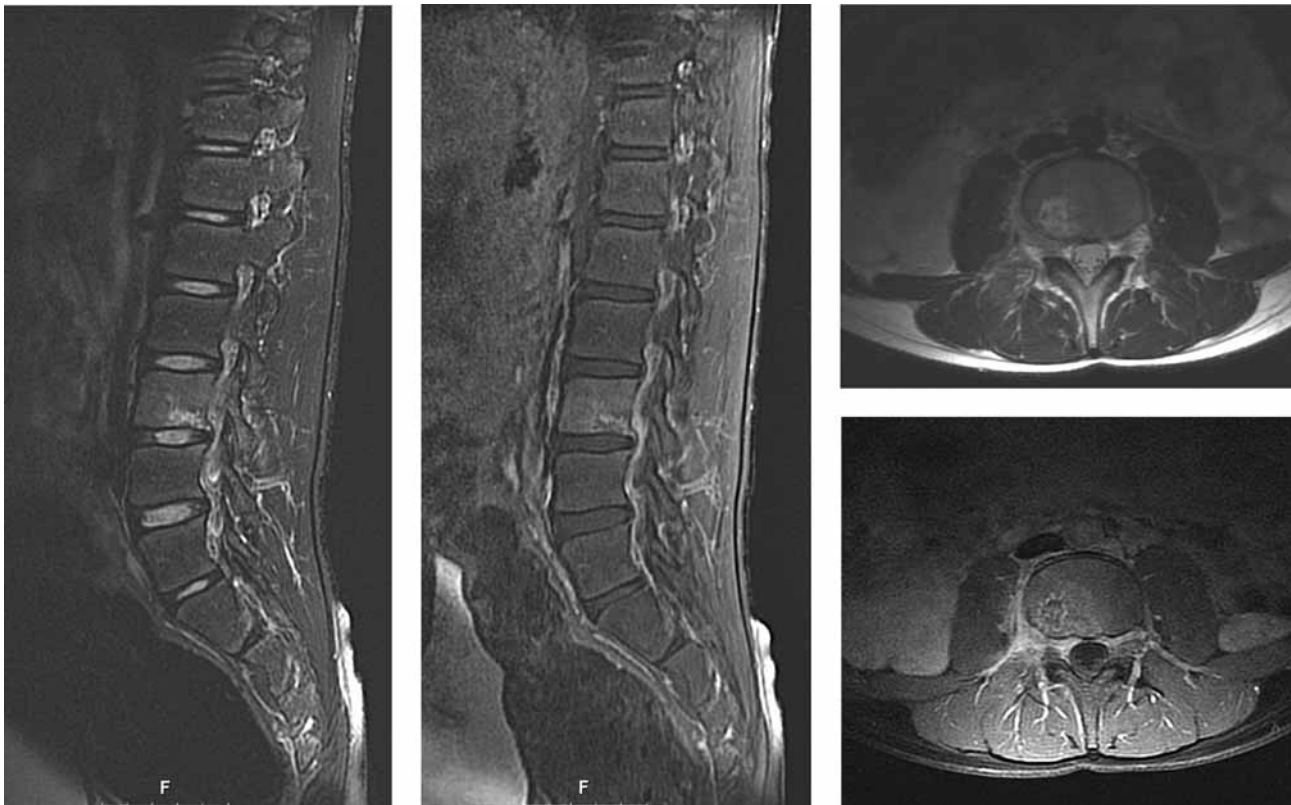


Fig. 4. — The sagittal T2-weighted image (2540/108) shows diffuse heterogeneous enhancement in L3 vertebral body, which is iso-intense to adjacent normal vertebrae and a sharply circumscribed area of inflammation dorsocaudally, which is extending to L3-4 disk space.

Sagittal T1-weighted image (TR/TE, 300/15) shows diffusely decreased signal intensity of vertebra L3.

Axial contrast-enhanced T2-weighted image (600/10) showing higher signal intensities in the infected marrow and soft tissue on the right paravertebral side.

Axial T1-weighted image (3400/84) shows thick and irregular rim enhancement of the inflammatory site in the caudal endplate of vertebra L3.

piercing is not without risks (3, 7). The resulting spondylitis in the above mentioned case report was treated adequately with antibiotics, bed rest and casting and the patient recovered fully. Without proper diagnosis and treatment, i.e. antibiotics, the infection can spread anteriorly and cause a paravertebral abscess or posteriorly and cause an epidural abscess. If the epidural abscess progresses, early paralysis is a possible complication. Late paralysis can be caused by significant kyphosis.

Although not proven by aspiration and culture of the vertebra, the time schedule renders it most likely that the patient suffered from osteomyelitis due to infection after ear piercing. It is generally

accepted that biopsy of the disc in children is not necessary, given the positive blood cultures (1).

At initial presentation the most likely diagnosis was a (primary) discitis, but the treatment options and prognosis differ greatly with (primary) spondylitis. We believe it to be of importance to make this difference since a discitis in a non-septic patient can be treated without antibiotics as opposed to treating a spondylitis ; but what can be of help discriminating these two entities ? In the retrospective series of Fernandez *et al* (2), comparing 36 patients with discitis and 14 patients with spondylitis, the parameters walking disability, back pain and laboratory values were not able to

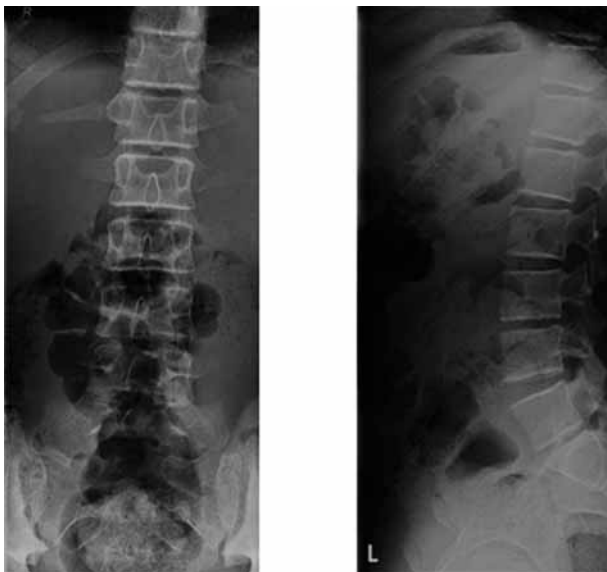

Fig. 5. — A postero-anterior and lateral lumbosacral spine film 10 weeks after onset of low back pain and 6 weeks after initiation of antibiotic treatment is shown. Note the loss of disk height at the L3-4 level.

discriminate. Helpful parameters in diagnosing spondylitis were age (> 3 years), fever, positive blood cultures (with non-contaminants) and lack of radiographic changes at initial presentation.

In our case the patient had non-specific symptoms, he was older than 3 years, and he had been having fever but no changes on initial radiographs of the spine. This validated the ongoing search for a possible source of infection by extending the

investigations with a blood culture and an MRI, resulting in the confirmation of a spondylitis and prompting the use of intravenous antibiotic treatment. Although supportive for the diagnosis, the radionuclide imaging was unnecessary in the ancillary investigations.

In conclusion, given the possible results of the seemingly innocuous cosmetic procedure of piercing, the dangers of piercing have to be considered. Finally, although uncommon in children, beware for spondylitis in older children presenting with fever and back pain, in whom antibiotic treatment is necessary.

REFERENCES

1. Crawford AH, Kucharzyk DW, Ruda R, Smitherman HC Jr. Diskitis in children. *Clin Orthop* 1991 ; 266 : 70-79.
2. Fernandez M, Carrol CL, Baker CJ. Discitis and vertebral osteomyelitis in children : an 18-year review. *Pediatrics* 2000 ; 105 : 1299-1304.
3. Greif J, Hewitt W, Armstrong ML. Tattooing and body piercing. Body art practices among college students. *Clin Nurs Res* 1999 ; 8 : 368-385.
4. Hayes MO, Harkness GA. Body piercing as a risk factor for viral hepatitis : an integrative research review. *Am J Infect Control* 2001 ; 29 : 271-274.
5. Hendricks WM. Complications of ear piercing : treatment and prevention. *Cutis* 1991 ; 48 : 386-394.
6. Sperry K. Tattoos and tattooing. Part II : Gross pathology, histopathology, medical complications, and applications. *Am J Forensic Med Pathol* 1992 ; 13 : 7-17.
7. Stirn A. Body piercing : medical consequences and psychological motivations. *Lancet* 2003 ; 361 : 1205-1215.