



## Flexor tendon synovitis of the hand as first manifestation of atypical tuberculosis

Björn D. KRAPOHL, Fercan KÖMÜRCÜ, Sabine STÖCKL-HIESLEITNER, Maria DEUTINGER

*From the Lainz Hospital, Vienna, Austria*

We present the case of a 73-year old patient suffering from chronic flexor tendon synovitis of the wrist with carpal tunnel syndrome. He underwent synovectomy and median nerve release. Primary bacteriology was negative. Histology of the excised synovia revealed non-caseating granuloma as typical for sarcoidosis. Further screening for sarcoidosis was negative. Culture of a sample harvested from the poorly healing wound was finally positive for *Mycobacterium tuberculosis*. Tuberculostatic treatment was started and the wound gradually healed. To the best of our knowledge, this is the first reported case of atypical non-caseating and sarcoidosis-like granulomas of the flexor tendon synovia of the hand as first manifestation of tuberculosis.

**Keywords** : tuberculosis ; flexor tendon synovitis ; non-caseating granuloma.

syndrome. On radiographs, there were no signs of degenerative arthritis or any other signs of osteo-cartilaginous or ligamentous pathology. Ultrasound showed bulging of soft tissue surrounding the flexor tendons consistent with flexor tendon synovitis.

The inflamed and partially indurated flexor tendon synovial sheath was surgically excised and the median nerve was decompressed in the carpal tunnel (fig 1). The superficial flexor tendon of the index finger was eroded and ruptured. Bacteriology of the native sample of the excised synovium was negative for aerobic and anaerobic bacteria as well as fungi. Histology revealed multiple non-caseating giant cell granulomas with epithelioid cells, directing the further diagnostic procedures towards sarcoidosis (fig 2).

### CASE REPORT

A 73-year old man presented with clinical signs of chronic flexor tendon synovitis of the left wrist and carpal tunnel syndrome. Finger flexion was significantly reduced to about 50% of total range of motion of the metacarpophalangeal, proximal and distal interphalangeal joints. Onset of symptoms had been six months before referral to our unit. The patient reported no signs of any systemic disease. Nerve conduction study confirmed carpal tunnel

■ Björn D. Krapohl, MD, Staff Plastic Surgeon.

■ Fercan Kömürcü, MD, Staff Plastic Surgeon.

■ Maria Deutinger, MD, Chairman, Plastic Surgeon.

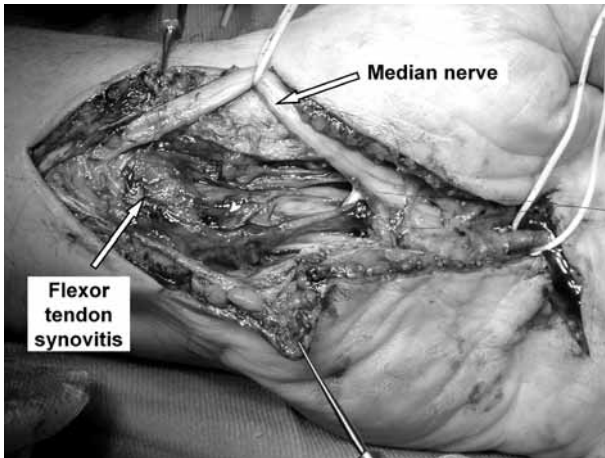
*Department of Plastic and Reconstructive Surgery, Lainz Hospital, Vienna, Austria.*

■ Sabine Stöckl-Hiesleitner, MD, Staff Pathologist.

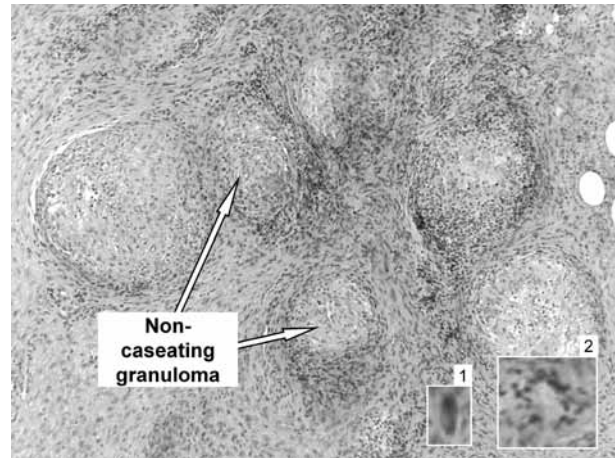
*Department of Pathology and Clinical Bacteriology, Lainz Hospital, Vienna, Austria.*

Correspondence : Björn D. Krapohl, Department of Plastic and Hand Surgery, Military and Governmental Hospital, Scharnhorststraße 13, D-10115 Berlin, Germany. E-mail : snownessi@web.de.

© 2006, Acta Orthopædica Belgica.



**Fig. 1.** — Intraoperative view : Bulging tuberculous flexor tendon synovitis and released median nerve.



**Fig. 2.** — Atypical non-caseating tuberculous granulomas (hematoxylin-eosin staining) : 1) Epithelioid histiocyte, 2) Langerhans' giant cell.

The patient was referred to dermatology, pneumology and rheumatology. Subsequent sarcoidosis screening included chest radiograph, CT-scan, bronchoscopy with tissue biopsy and determination of serum level of angiotensin-converting-enzyme which is elevated in about 80% of sarcoidosis patients. However, all tests were negative for systemic or localized sarcoidosis. After four weeks, the operative wound still presented with delayed healing and clear exudate. Microbiology of a tissue sample harvested from the wound for mycobacterial culture (Löwenstein-Jensen-culture) finally lead to the diagnosis of *Mycobacterium tuberculosis* infection.

Systemic tuberculostatic therapy was started with a combination of isoniazid (400 mg/d), rifampicin (300 mg/d), and pyrazinamid (2 g/d). Within five weeks, exudation stopped and the wound was closed. Finger flexion was still reduced with a total range of motion of 80% compared to the unaffected contralateral right hand.

## DISCUSSION

Tuberculosis may occasionally affect the hands and the synovium can be the site of the disease's primary manifestation (1, 2, 4, 5, 7, 11). This may lead to severe reduction of mobility (1, 5, 7, 11), nerve compression such as carpal tunnel syndrome (1, 2,

11), and tendon ruptures (4). Systemic disease does not necessarily accompany infections of the hand. Caseating giant cell granulomas with epithelioid cells and acid fast bacilli form the typical picture of the disease. The diagnosis is usually based on microbiology. Nevertheless, bacteriology of the native sample may be negative and culture is often required to detect the bacterial infection. The absence of acid-fast bacilli on staining does not rule out mycobacterial infection (12).

Histology of lymph nodes in patients infected by *Mycobacterium tuberculosis* may not show caseating granulomas when the patient is immunosuppressed (8, 9, 10). However, in the connective tissue of the musculoskeletal system, tuberculosis has always been described as presenting a histological picture of caseating granulomas (1, 2, 4, 5, 7, 11). Non-caseating-granulomas have been associated with sarcoidosis. In this case, we first describe flexor tendon synovitis of the hand as first manifestation of atypical tuberculosis, presenting histologically with sarcoidosis-like non-caseating granulomas (6, 14). Differential diagnosis of tuberculosis of the hand includes sarcoidosis, Crohn's disease, brucellosis, and fungal lesions (3). Differentiation between sarcoidosis and tuberculosis may be difficult but is essential since the treatment modalities are absolutely different. Sarcoidosis may require glucocorticoid application which may lead to

exacerbation in case of tuberculosis, and increase the need for surgical intervention (13). In tuberculosis early diagnosis followed by radical surgical debridement and antimycobacterial therapy is essential (2, 3, 12).

### CONCLUSIONS

Synovitis of the hand is a common feature in various inflammatory and infectious conditions. Although the hand is rarely the first site of tuberculosis manifestation, diagnostic screening in synovitis should include microbiological search for *Mycobacterium tuberculosis*. If histology reveals giant cell granulomas with epithelioid cells and if bacteriology of the original sample does not lead to a conclusive diagnosis, microbiological culture is required to finally distinguish between tuberculosis and sarcoidosis related lesions. In any case, sarcoidosis-like non-caseating giant cell granulomas do not rule out tuberculosis.

### REFERENCES

1. **Al-Quattan MM, Bowen V, Manktelow RT.** Tuberculosis of the hand. *J Hand Surg* 1994 ; 19-B : 234-237.
2. **Benkeddache Y, Sidhoum SE, Derridj A.** Various aspects of tuberculosis of the hand : A propos of a series of 45 cases. *Ann Chir Main* 1988 ; 7 : 166-175.
3. **Blue ML, Payne WG, Mannari RI et al.** Mycobacterium kansasii causing carpal tunnel syndrome with concomitant pulmonary mycobacterium tuberculosis infection. *South Med J* 2002 ; 95 : 1095-1098.
4. **Burkhardt E.** Chronic diseases of the synovial sheath (from hand surgery consulting hour). *Beitr Orthop Traumatol* 1972 ; 19 : 377-391.
5. **Bush DC, Schneider LH.** Tuberculosis of the hand and wrist. *J Hand Surg* 1984 ; 9-A : 391-398.
6. **Cashman WF, Nalebuff EA.** Sarcoidosis presenting as a wrist tumour. *Hand* 1976 ; 8 : 155-157.
7. **Elbaz JS, Lambilliotte P, Schaeffer.** Tuberculous synovitis of the hand. *Bull Mem Soc Chir Paris* 1968 ; 58 : 92-103.
8. **Hamada M, Urabe K, Moroi Y et al.** A case of multifocal lupus vulgaris that preceded pulmonary tuberculosis in an immune compromised patient. *J Dermatol* 2004 ; 31 : 124-128.
9. **Huhti E, Brander E, Paloheimo S, Sutinen S.** Tuberculosis of the cervical lymph nodes : a clinical, pathological and bacteriological study. *Tubercle* 1975 ; 56 : 27-36.
10. **Kamboj S, Goel MM, Tandon P et al.** Correlative study of histopathology and bacteriology in patients with tubercular lymphadenitis. *Indian J Chest Dis Allied Sci* 1994 ; 36 : 187-191.
11. **Leclercq D, Lejeune G, Carlier A, Jodogne G.** Spontaneous rupture of the superficial and deep common flexors of the index finger caused by tuberculous synovitis. *Acta Orthop Belg* 1980 ; 46 : 262-271.
12. **Visuthikosol V, Kruavit A, Nitiyanant P, Siriwongpairat P.** Tuberculous infection of the hand and wrist. *Ann Plast Surg* 1996 ; 37 : 55-59.
13. **Wada A, Nomura S, Ihara F.** Mycobacterium kansasii flexor tenosynovitis presenting as carpal tunnel syndrome. *J Hand Surg* 2002 ; 25-B : 308-310.
14. **Yasui N, Tsuyuguchi Y.** Sarcoid disease of the wrist joint. *Hand* 1983 ; 15 : 246-248.