



Navigated total knee arthroplasty : A radiological analysis of 42 randomised cases

Marc MOMBERT, Luc VAN DEN DAELEN, Paul GUNST, Lieven MISSINNE

From the Stedelijk Ziekenhuis Roeselare, Belgium

The purpose of this study was to evaluate the use of a navigation device in a cohort of 42 total knee arthroplasties (TKA). The patients were randomised into two groups. Total knee arthroplasties performed using the conventional technique formed the control group (21 knees) ; the experimental group included 21 knees performed with the aid of a computed navigation system. Postoperative mean values for the various measurements showed no significant difference in component alignment. However, the range of individual measurements for coronal and sagittal plane positioning was smaller in the navigated group, in which there were no outliers. Rotational alignment was not different between the two groups. This confirms the advantages and limitations of navigated TKA presented in larger studies.

Keywords : total knee arthroplasty ; navigation.

INTRODUCTION

Total knee arthroplasty is a complex balancing exercise between stability and mobility. Mobility is achieved by placement of tibial, femoral and patellar components in a congruous fashion and by creating an equal flexion and extension gap in accordance with the implant design. Stability is achieved by correct ligament balancing and bone cuts.

Human inaccuracy in positioning the components with either intramedullary or extramedullary guiding systems may result in significant variations in implant positioning. Long-term results can be

impaired by as little as 4° varus or valgus malalignment. Implant loosening has been reported in only 3% of well aligned TKA's after 8 years follow-up, as opposed to 24% of malaligned prostheses (more than 4° of malalignment) (4).

Perhaps man is simply not capable of avoiding significant error in alignment and computerization is the key. This may be even more true in knees with major deformities and when performing minimally invasive surgery.

Since the first computer assisted TKA was performed in cadavers in 1997 by Saragaglia and Picard (9), technological advances have taken place : we no longer need preoperative CT imaging, and intra-operative digitisation is less time consuming. This has made the technique more appealing for a wider use.

The goal of this study was to report our experience with computer assisted implant navigation in total knee arthroplasty.

■ Marc Mombert, MD, Resident in Orthopaedic Surgery.

■ Luc Van Den Daelen, MD, Orthopaedic Surgeon, Department Head.

■ Paul Gunst, MD, Orthopaedic Surgeon.

■ Lieven Missinne, MD, Orthopaedic Surgeon.

Department of Orthopaedic Surgery Stedelijk Ziekenhuis Roeselare, Roeselare, Belgium.

Correspondence : Marc Mombert, De Willaert 18-1, B-2460 Tielen, Belgium. E-mail : mombertmarc@skynet.be.

© 2007, Acta Orthopædica Belgica.

Table I. — Average preoperative radiographic data of the two groups

	Conventional	SD	Navigated	SD
HKA angle	-3.8°	8.4°	-6.5°	7.7°
HKS angle	7.2°	1.4°	6.4°	1.7°
Tibial slope	83.6°	3.2°	84.8°	3.9°
Insall-Salvati index	1.1	0.1	1.2	0.2

- HKA angle (in degrees) : angle between the mechanical axis of femur and tibia ;
 - HKS angle (in degrees) : angle between anatomical and mechanical axis of femur ;
 - tibial slope (in degrees) : angle between posterior cortex of proximal tibia and tibial baseplate ;
 - Insall-Salvati index : ratio between patellar tendon length and patellar height ;
- SD : standard deviation.

MATERIALS AND METHODS

Forty two patients who underwent a total of 42 primary total knee arthroplasties were prospectively studied after computer randomisation to a conventional group of 21 TKA's (using an intramedullary guiding system) and a navigated group also with 21 cases. The average preoperative radiographic measurements (HKA angle, tibial slope, Insall-Salvati index) were not significantly different between the two groups (table I).

The Scorpio single axis fixed bearing total knee system was implanted in all cases (Stryker, Limerick, Ireland). The design rationale behind the prosthesis is a single condylar radius between 0° and 90° providing a better mid-flexion stability. The VectorVision® TKR Navigation system (BrainLAB AG, Heimstetten, Germany) is a non CT-based navigation system. It acquires real time data by intra-operative digitalisation of axes, landmarks and important bone surface areas with a wireless pointer. It then builds a 3D model of the knee and provides a step-by-step treatment plan by guiding bone cuts.

All patients received identical postoperative rehabilitation programs and were allowed to go home on the sixth postoperative day if they reached full extension and a minimum of 90° of flexion. All patients reached these goals.

Patients were subjected to radiographic and clinical follow-up at 3 months postoperatively. Standard AP and lateral views were taken to assess tibial slope and femoral component orientation in the sagittal plane

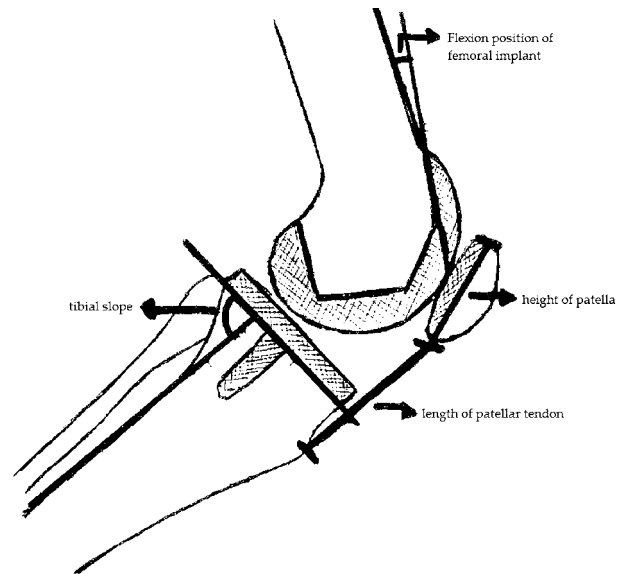


Fig. 1. — Flexion position of femoral component : angle between anterior cortex of the distal femur and longitudinal axis of implant.

Tibial slope : angle between posterior cortex of proximal tibia and tibial baseplate ;

Insall-Salvati index : ratio between patellar tendon length and patella length.

(fig 1), an AP full leg film to measure the HKA angle (fig 2) and a CT-scan to calculate the rotational position of the implants (fig 3 & 4). All measurements were done by an independent radiologist using digital techniques.

RESULTS

Average varus-valgus knee alignment three months postoperatively showed no significant difference between navigated and conventional TKA's (respectively 1.6° and 2.4°) (table I). The 95% confidence interval was smaller in the navigated series (fig 5). There were no outliers in the navigated group, as opposed to 4 cases in the conventional group.

Tibial slope was measured on the standard lateral radiographs ; there was no significant difference between the mean values in the two groups (2.7° downslope in the conventional and 2.8° downslope in the navigated group) (table I). The built-in 3° downslope of the polyethylene insert was not

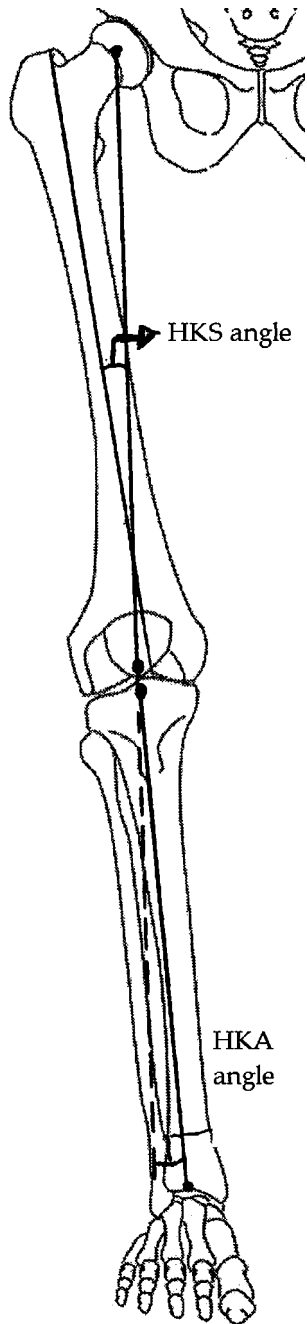


Fig. 2. — HKA angle : angle between mechanical axis of femur and tibia.
HKS angle : angle between mechanical and anatomical axis of femur.

included in this measurement. The range of tibial implant slope was larger in the navigated series (fig 6).

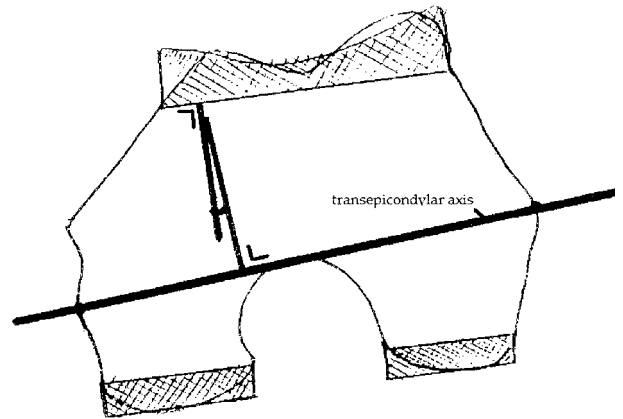


Fig. 3. — Rotational alignment of femoral component : angle between transepicondylar axis of distal femur and transverse axis of implant.

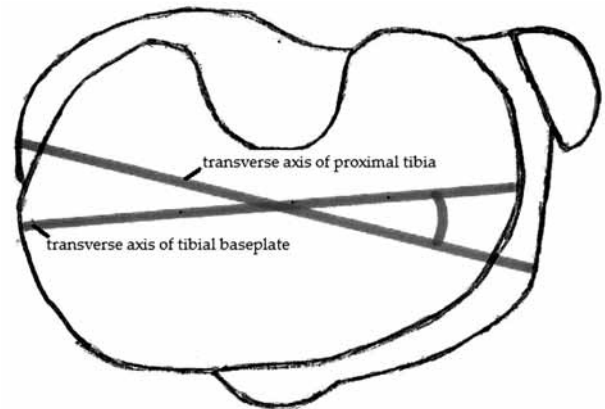


Fig. 4. — Rotational alignment of tibial component : angle between transverse axis of proximal tibia at the level of the tuberosity and transverse axis of baseplate.

The lateral radiograph also allowed to assess the sagittal positioning of the femoral component which was on average 0° in the conventional group and 1.6° of extension in the computer assisted group. The range of femoral component flexion was smaller in the navigated series (fig 7). CT measurement of implant rotation relative to the transepicondylar axis was not significantly different : the femoral component was positioned in 0.5° internal rotation in the conventional group and 1° external rotation in the navigated group ; the tibial component was positioned in external rotation with an average 21° and 21.5° respectively.

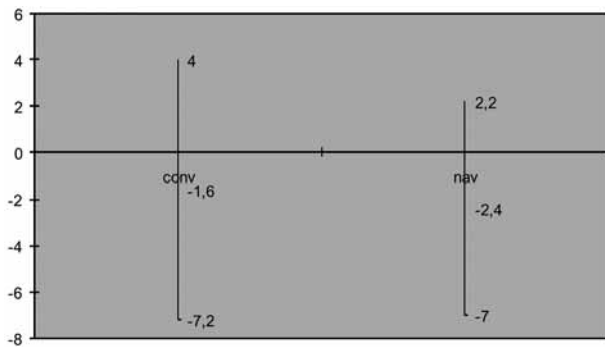


Fig. 5. — Average postoperative varus-valgus alignment and maximum deviations (HKA angle in degrees : mean values and 95% confidence interval). Negative values refer to varus alignment).

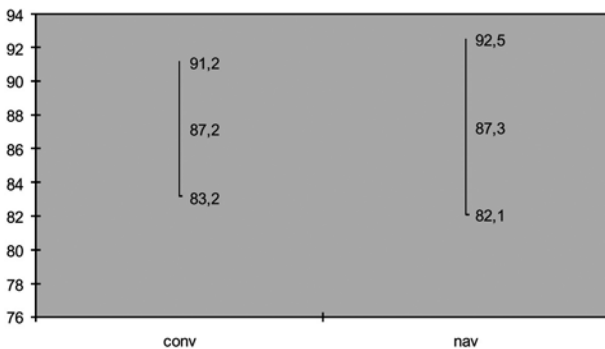


Fig. 6. — Average postoperative tibial slope and maximum deviations (tibial slope in degrees : angle between posterior cortex of proximal tibia and tibial baseplate Mean values and 95% confidence interval. Values below 90° refer to downslope.

The confidence interval was similarly smaller in the navigated TKA's for femoral component positioning. Rotational positioning of the tibial component was not navigated, explaining the similar statistical span of the 2 groups with outliers in both groups, up to 45 degrees of external rotation in one case (figs 8 & 9).

DISCUSSION

Total knee arthroplasty has evolved to the point of becoming a reliable and predictable procedure when certain principles are followed. One of these principles is correct positioning of the components

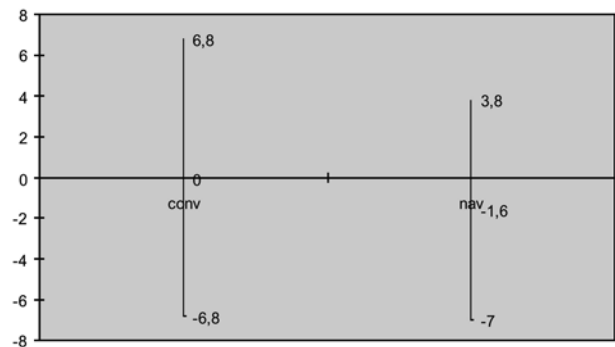


Fig. 7. — Average postoperative flexion position of the femoral component (in degrees) = angle between femoral anterior cortex and longitudinal implant axis. Mean values and 95% confidence intervals. Negative values represent extension position.

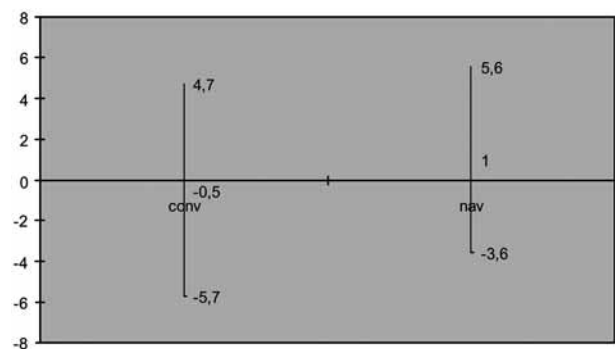


Fig. 8. — Average postoperative rotational alignment of femoral component and maximum deviations (rotational position in degrees : angle between transepicondylar axis of distal femur and transverse axis of implant on CT scan). Mean values and 95% confidence intervals. Negative values represent external rotation.

according to implant design. Owing to improved instrumentation design, variations in placement accuracy can be limited, but recent literature (2, 4, 10) states that even this is not enough and significant malpositioning is possible despite these technical advances. Use of intramedullary alignment jigs may be associated with higher intra-operative blood loss (7). One answer to this was the development of computer navigation technology in total knee arthroplasty. A recent prospective randomised study by Sparmann *et al* (12) confirmed the more reproducible positioning of the implants in the coronal plane. In their series, the coronal alignment was within 2° of neutral alignment in 97.5% of

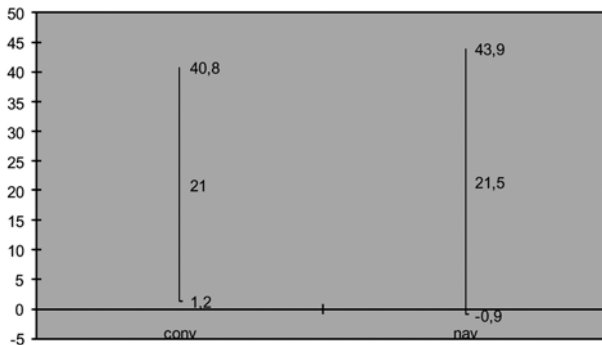


Fig. 9. — Postoperative rotational alignment of tibial component (rotational position in degrees : angle between transverse axis of tibial implant and digital CT based approximation of transverse axis of the proximal tibia at the level of the tibial tuberosity). Mean values and 95% confidence intervals. Negative values represent internal rotation. The rotational position of the tibial implant was not navigated.

navigated knees, versus 77.5% of conventional implantations, and there were no outliers, i.e. with more than 3° deviation, in the navigated group. We can expect navigated knees to have a longer lifespan, since previous studies have demonstrated a correlation between malalignment and polyethylene wear. The sagittal alignment measurements are less accurate because of the small size of standard radiographs, but the same tendencies can be noted between computer assisted surgery and conventional techniques.

An important lesson we learned was that due to bowing of the femur, intramedullary guidance results in a more flexed position of the femur. This means that navigated femoral components were placed with more extension. Taking into consideration the non diverging cuts of the Scorpio design, extension positioning means a higher risk of anterior notching. We therefore changed the standard settings of the navigation computer to a more flexed positioning of the femoral component after examining the preliminary data.

Rotational positioning of the implants is also important. Malrotation, especially internal rotation of the femoral and tibial component is associated with patellar problems such as maltracking with anterior knee pain and even dislocation of the patel-

la (1). Soft-tissue balancing is also influenced by rotational positioning of the components.

Correct rotational positioning of the femoral component using the transepicondylar axis or Whiteside's anteroposterior line, is an arbitrary process because these landmarks are not readily definable and several studies have shown significant intra-observer differences (5, 6). Another way of achieving optimal rotational positioning is the other way around, by using soft tissue balance in extension and flexion – which is however also subjective – to guide rotational positioning of the femoral implant. This method proved more reliable in cadaver studies (8). Tibial rotation can be guided by bony landmarks (such as the medial third of the tibial tuberosity) but major femorotibial rotational mismatch is possible. An easier way to guide tibial rotational alignment is by referencing to the femoral position in 90° of flexion (13). CT scanning is a reproducible technique for measurement of femoral and tibial rotation (3). Navigation for the moment does not have the ability to improve the consistency of rotational alignment, which is still a problem for the tibial implant. Newer techniques that use 3D digitisation of the femoral condyles to calculate rotational alignment do not seem to decrease the inaccuracy range (11).

CONCLUSION

The results of this study of a limited number of cases of navigated versus conventional TKA correlate well with those of larger trials : navigation provides a more consistent positioning of the implants in the coronal and sagittal plane. The average difference in alignment between the two groups is not statistically significant, but the deviations are smaller with navigation. The study also demonstrates the inability of present day navigation to provide similar accuracy in rotational alignment, especially for the tibial component.

The navigation technology allows for more accurate total knee arthroplasty, avoiding the problems associated with malpositioning over the short term. The downside is the cost of the equipment and the longer operating times (although a significant drop of this extra time is seen after the learning curve has

been completed (14). It remains to be demonstrated that navigated TKA's have a longer lifespan due to less mechanical wear and have better functional outcomes due to better soft tissue balancing providing a greater functional range of motion.

Our series will be followed clinically and radiologically over a longer time to be able to evaluate the possible long-term advantages of navigation technology in total knee arthroplasty.

REFERENCES

1. **Barrack RL, Schrader T, Bertot AJ et al.** Component rotation and anterior knee pain after total knee arthroplasty. *Clin Orthop* 2001 ; 392 : 46-55.
2. **Hofmann S, Romero J, Roth-Schiffel E, Albrecht T.** Rotational malalignment of the components may cause chronic pain or early failure in total knee arthroplasty. *Orthopäde* 2003 ; 32 : 469-476.
3. **Jazrawi LM, Birdzell L, Kummer FJ, Di Cesare PE.** The accuracy of computer tomography for determining femoral and tibial total knee arthroplasty component rotation. *J Arthroplasty* 2000 ; 15 : 761-766.
4. **Jeffery RS, Morris RW, Denham RA.** Coronal alignment after total knee replacement. *J Bone Joint Surg* 1991 ; 73-B : 709-714.
5. **Jenny JY, Boeri C.** Low reproducibility of the intra-operative measurement of the transepicondylar axis during total knee replacement. *Acta Orthop Scand* 2004 ; 75 : 74-77.
6. **Jerosch J, Peuker E, Philipps B, Filler T.** Interindividual reproducibility in peri-operative rotation alignment of femoral components in knee prosthetic surgery using the transepicondylar axis. *Knee Surg Sports Traumatol Arthrosc* 2002 ; 10 : 194-197.
7. **Kalairajah Y, Simpson D, Cossey AJ et al.** Blood loss after total knee replacement : effects of computer-assisted surgery. *J Bone Joint Surg* 2005 ; 87-B : 1480-1482.
8. **Katz MA, Beck TD, Silber JS et al.** Determining femoral rotation alignment in total knee arthroplasty : reliability of techniques. *J Arthroplasty* 2001 ; 16 : 301-305.
9. **Saragaglia D, Picard F.** Computer-assisted implantation of total knee endoprosthesis with no preoperative imaging : the Kinematic model. In : Stiehl JB, Konermann WH, Haaker RG (eds). *Navigation and Robotics in Total Joint and Spine Surgery*. Springer, Berlin, 2004, pp 226-233.
10. **Sharkey PF, Hozack WJ, Rothman RH et al.** Why are total knee arthroplasties failing today ? *Clin Orthop* 2002 ; 404 : 7-13.
11. **Siston RA, Patel JJ, Goodman SB et al.** The variability of femoral rotational alignment in total knee arthroplasty. *J Bone Joint Surg* 2005 ; 87-A : 2276-2280.
12. **Sparmann M, Wolke B, Czupalla H et al.** Positioning of total knee arthroplasty with and without navigation support. A prospective, randomised study. *J Bone Joint Surg* 2003 ; 85-B : 830-835.
13. **Uehara K, Kadoya Y, Kobayashi A et al.** Bone anatomy and rotational alignment in total knee arthroplasty. *Clin Orthop* 2002 ; 402 : 196-201.
14. **Walde TA, Burgdorf D, Walde HJ.** Process optimization in navigated total knee arthroplasty. *Orthopedics* 2005 ; 28 : 1255-1258.