



History of radial head prosthesis in traumatology

Roger P. VAN RIET, Francis VAN GLABBEEK

From the University Hospital Antwerp, Antwerp, Belgium

A review of the literature was performed to survey the history of the radial head prosthesis in traumatology. Radial head resection was the treatment of choice before Speed first reconstructed the radial head with a metal prosthesis.

Over the years, the indication for the use of a radial head prosthesis changed from the prevention of heterotopic ossification to the prevention of proximal migration of the radius and instability of the elbow. Currently, the optimal indication for the use of radial head prostheses is a non-reconstructible radial head fracture with associated injuries that would leave the elbow, or forearm unstable if the radial head were resected.

Keywords : radial head ; fracture ; prosthesis.

INTRODUCTION

Radial head prostheses are mainly used in the treatment of non-reconstructible radial head fractures (fig 1). Current designs are relatively new. Short and medium term follow-up studies have shown promising results (29, 63, 70, 87), but only one long-term follow-up study has been published so far (29). Older designs are no longer used due to reports of poor results and numerous complications (9, 10, 47, 56, 64, 76, 99). The goal of this study is to describe the history of the radial head prosthesis in traumatology and its clinical and biomechanical evolution.

MATERIALS AND METHODS

Pubmed™, Medline™ and OldMedline™ searches were done to identify literature relating to the history of radial head prostheses. Literature was limited to those papers describing the use of radial head prostheses. Due to the limited historical timeframe that can be searched via these search engines, references from the existing literature were also searched (55).

The literature was organised using Endnote Software (ISI, Research Soft, Berkeley California, USA). Results are discussed as a chronological review of the relevant literature.

DISCUSSION OF THE LITERATURE

In the early twentieth century, radial head resection became the treatment of choice for displaced radial head fractures (41, 74, 75). In 1924, Speed (74) even stated that: *“In adults, unless the lesion is only a mere crack, there is no doubt that removal of the head is primarily indicated”*. Others reserved

■ Roger P. van Riet MD, PhD.

■ Francis Van Glabbeek MD, PhD.

University Hospital Antwerp.

Correspondence : Dr Roger van Riet, 10 Wilrijkstraat, B-2610 Edegem, Belgium. E-mail : rogervanriet@hotmail.com.

© 2007, Acta Orthopædica Belgica.

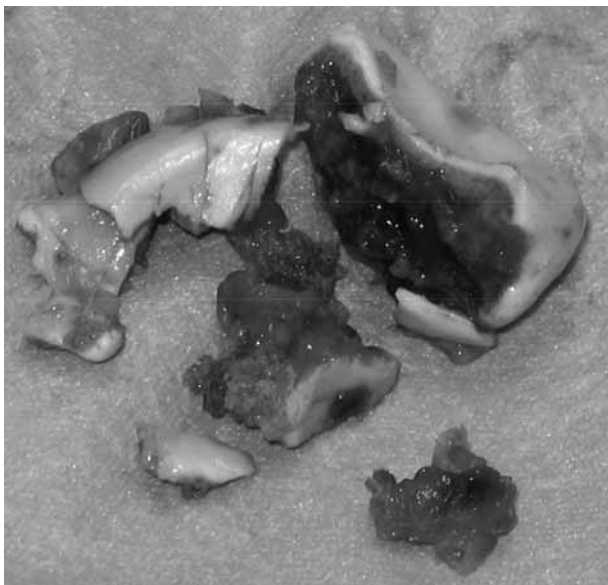


Fig. 1. — Resected fragments of a comminuted radial head fracture. The fracture was complicated by a medial collateral ligament injury and it was judged that this fracture was not amenable to reconstruction. The radial head was replaced with a metal prosthesis.

resection for cases where the radial head fracture caused a functional impairment that was not likely to improve with conservative treatment (17) or when open reduction and internal fixation was not possible (40, 41, 69). Currently, open reduction and internal fixation has become the treatment of choice for displaced radial head fractures (34, 55, 58, 65, 87).

Regrowth of bone at the proximal radius was one of the most feared complications after resection (41, 43, 57, 77). Interposition of soft tissue (43, 67, 75, 77) or bone grafting (77) was therefore suggested and in 1941, Speed (73) was the first to describe the use of a ferrule cap that could be placed over the radial neck, in order to prevent heterotopic bone formation. Interestingly, the caps were made from casts of resected normal heads of the radius, and thus were in essence, 'anatomic' radial head prostheses (73).

Indications slowly changed and ten years later, Carr *et al* (14) were the first to comment that the prosthesis increased elbow stability, when com-

pared to radial head resection. Also in 1951, Essex-Lopresti (22) described two cases where the radial head fractures were associated with a distal radio-ulnar dislocation. Although he did not use a prosthesis in either of these cases, he suggested the temporary use of a radial head prosthesis, until the forearm had healed and became stable (22).

In 1953, Cherry (16) described a second type of radial head prosthesis made of an acrylic resin, to prevent proximal translation of the radius and consequent strain on the distal radio-ulnar joint and to maintain the normal carrying angle of the elbow and prevent cubitus valgus. The use of a radial head prostheses was however still quite rare at that time (1, 18).

The first time the use of a radial head prosthesis was compared to resection of the radial head was in a retrospective study in 1960. Despite a broken stem in one, patients that were treated with prosthetic replacement of the radial head were more satisfied with the procedure, had greater mobility, less pain, and none had wrist symptoms, compared to three patients with wrist pain in the resection group (20).

Prevention of distal radio-ulnar joint subluxation became an accepted indication for radial head replacement (83).

Long-term results of the Speed prosthesis published in 1964 were shown to be similar to those of patients treated with radial head resection, with decreased pronation and supination in the prosthesis group (3).

In 1969, the Swanson Silastic® radial head prosthesis became available (Dow Corning Corporation, USA) (78, 79). Unfortunately the prosthesis did not prevent proximal migration of the radius (5, 48) and a large degree of distortion was found during movement of the elbow (72).

Timing of the prosthetic replacement was first discussed in 1974. Early replacement of the radial head showed better functional results, but good pain relief was still achieved in the late group (72).

The first structural complications with the Swanson prosthesis were reported in 1979. In a series of eighteen patients, the prosthesis had broken in three, subluxed in one and tilted in six (48) (fig 2).

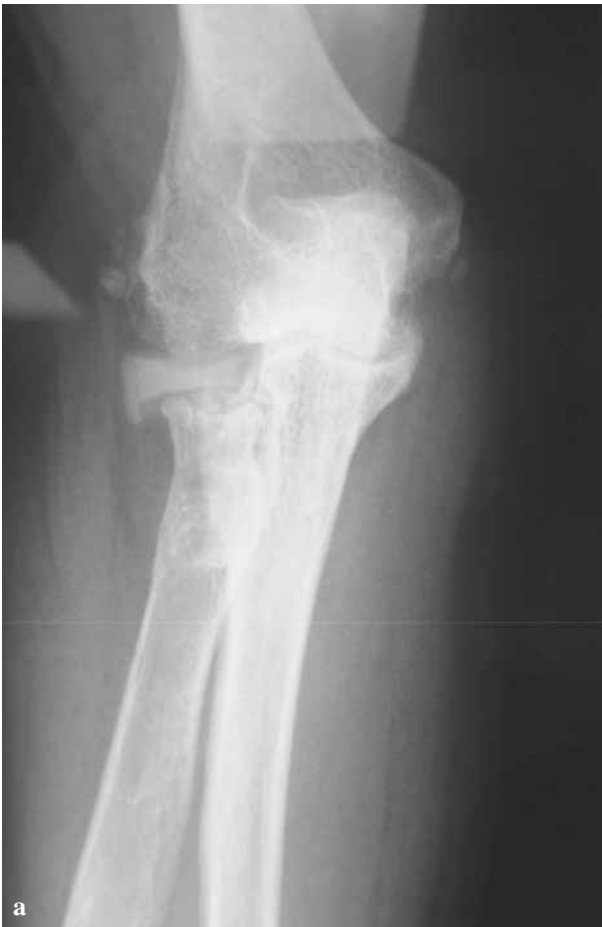


Fig. 2. — a) AP radiograph of a right elbow showing a fractured silastic radial head replacement ; b) Resected silastic radial head replacement showing the intact prosthetic head and the fractured stem.

Besides breakage of the prosthesis (7, 9, 47, 49, 76, 85, 86), giant cell synovitis from silastic particles were shown to be a problem (27, 85, 95, 99). Results of clinical reports were mixed with some showing the silastic prosthesis to yield improved results over radial head resection (7, 21, 42, 80, 86), others showing no difference (23, 96, 97) or poor results following the use of the silastic prosthesis (24, 50, 56, 66, 76). Biomechanical studies showed that radial head replacements could restore some of the stability of the elbow (28, 33, 45, 64), and longitudinal stability of the forearm (13, 28, 32, 68), but that a stiffer implant would be necessary. Due to the abundance of objective data against the Swanson radial head prosthesis, new types of prostheses were developed (30, 38, 39, 46, 52, 53) and indications were again adjusted (56). Morrey *et al* (56) limited the indications for the use of a radial head implant to insta-

bility following radial head resection and acute dissociation of the distal radio-ulnar joint.

The development and clinical trial of a vitallium prosthesis (Howmedica, London, UK), were described by Knight *et al* (46) in 1993. Loosening of the prosthesis was described in two patients and the authors commented that replacement was not clearly better than resection for simple radial head fractures (46).

Judet *et al* (38, 39) introduced a bipolar prosthesis in the literature in 1994 with promising results. The 'floating' radial head prosthesis (Tornier SA, Saint-Ismier, France) is made of cobalt-chrome, has a collared stem with a 15° neck shaft angle and consists of 2 parts connected by a spherical joint allowing 35° of uniplanar motion in any direction (38) (fig 3).

In 1996, Charnley *et al* (15) used the floating radial head prosthesis after release of the elbow for heterotopic ossification following head injury. No recurrence of the heterotopic ossification was found at a follow-up of 3.5 years (15). Interestingly, prevention of heterotopic ossification was the main indication for Speed to use a radial head prosthesis (73).

Allograft replacement of the radial head was published in 1997 (54, 82). One of the allografts dislocated three weeks following surgery, while the

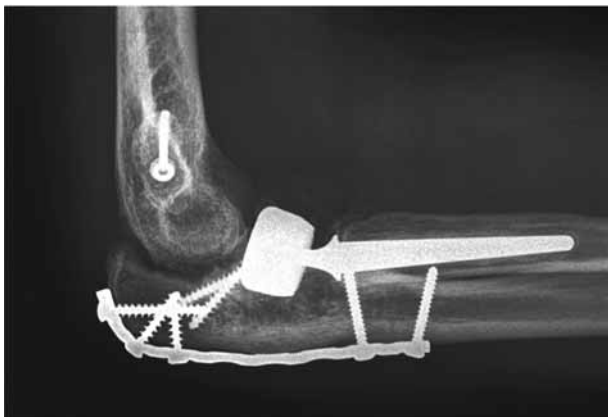

Fig. 3. — Lateral postoperative radiograph of a complex elbow reconstruction following trauma. The radial head was replaced with a 'floating radial head prosthesis' (Tornier SA, Saint-Ismier, France).

arm was still in a long arm cast. Another concern was degeneration and collapse of the graft that was found in follow-up radiographs (82). No long-term results were published.

In contrast to the results of radial head prostheses, excellent long-term (average follow-up of 17 years) results of resection of the radial head, were published in 1997 (98).

In 1999, Beredjikian *et al* (6) reported on another problem with metal radial head replacements. Anatomic data were compared with commercially available titanium radial head implants. In 39% (18 of 46) of the cases, even the smallest prosthetic stem would not fit into the radial intramedullary canal. The length of the radius could not be restored in any of the cases in which a prosthesis could be fitted (6).

In 2000 'safe and effective' short-term results were found with a new type of metal radial head prosthesis used for non-reconstructible radial head fractures (52, 53). Short-term results of the floating radial head prosthesis were also promising and the prosthesis was found to restore clinical stability (63, 70). However, degenerative changes of the elbow were found in approximately 50%, while the prosthesis had to be removed in a patient due to pain and functional impairment at the elbow (70).



Fig. 4. — a) Modular radial head replacement (Evolve, Wright Medical Technology Inc., Arlington, TN, USA). Head and stem sizes can be determined individually and prosthetic components are interchangeable to accommodate the anatomy ; b) Evolve radial head prosthesis 'in situ'.

The first long-term results of a 'monoblock' metal radial head prosthesis (Smith & Nephew, Inc., Memphis, TN, USA) were published in 2001. The authors advocated the use of a metal prosthesis if the elbow was shown to be unstable following radial head resection, and concluded that radial head resection was still a valid treatment option in the otherwise stable elbow (29).

Further anatomical studies defined the dimensions of the proximal radius (19, 62, 81, 94). The radial head and neck relationship was found to be variable (93) and a modular type of radial head prosthesis was recommended (44) (fig 4). The anatomic radial head was found to be elliptical in shape (94)

and although this has so far not had any implications in prosthesis design, biomechanical testing showed altered ulnohumeral kinematics due to the fact that prostheses do not duplicate the elliptical shape of the anatomic radial head (92).

Biomechanical studies found that metal radial head prostheses could improve stability (37, 45), but could not completely restore normal valgus stability of the medial collateral ligament (36, 60). This was also concluded in a retrospective clinical review of patients (31). Others showed radial head prosthetic replacement to improve longitudinal forearm stability (84), and decrease proximal migration of the radius (59), but not to restore stability to normal, in experimentally induced Essex-Lopresti lesions.

Despite these somewhat disappointing biomechanical results, radial head prostheses have gained widespread acceptance. The radial head has been shown to be particularly important in non-reconstructible fractures that are complicated by ligamentous injury or other associated fractures, such as in the so-called "terrible triad fractures", with radial head and coronoid fractures and an associated lesion of the medial collateral ligament (51, 65). These associated injuries have recently been shown to be extremely common in radial head fractures (35, 91). Short- to midterm clinical results in this complex group of patients have been shown to be good to excellent in the majority of patients in mostly small patient series (2, 4, 11, 25, 61). Secondary radial head replacement has also been shown to yield good short-term results in a small group of patients in the treatment of sequelae of radial head fractures (11).

Although the designs and materials of modern radial head replacements have improved dramatically in recent years, the surgical technique has largely remained unchanged. Failure of the prosthesis is rare but reports of complications have been presented recently. These include loosening and dislocation of the prosthesis (26) but the main problem is mismatch in sizing the prosthesis with the native radial head. Ulnohumeral kinematics and load transfer have been shown to be adversely affected if radial neck length is not restored within 2.5 mm of the native radial head length (88, 89). This

has clinically been shown to lead to decreased range of motion and elbow pain necessitating removal of the prosthesis in some cases (8, 11, 100). Erosion of the capitellum has been shown in patients following removal of the prosthesis (8, 11) and has also been described radiographically with associated pain in the elbow (90).

CONCLUSION

Radial head prostheses have found a definite place in the treatment of complex radial head fractures. Materials and designs have improved and even the indication has changed since Speed implanted his first prosthesis (73), from prevention of bone formation to prevention of instability of the elbow (65). Biomechanical research has shown that there remains room for improvement (60) and results of the use of a radial head prosthesis have thus far not been shown to be superior to radial head resection in simple fractures.

Radial head prostheses should however be used when a radial head resection would likely cause detrimental effects to the elbow or wrist, and the majority of patients with a non-reconstructible radial head fracture has been shown to have associated lesions to the elbow (35, 91). Pre- and intraoperative assessment of elbow and forearm stability (4, 12, 71) should be included in the treatment protocol to definitely determine the indication. Certain complications described can be prevented if the radial head is replaced using anatomic guidelines (19, 88, 89).

After a thorough review of the literature we believe that the use of current radial head prostheses can be advantageous to the patient. Newer designs and surgical techniques will have to prove their merit and this could potentially broaden the indications and improve future results.

REFERENCES

1. Arner O, Ekengren K, von Schreeb T. Fractures of the head and neck of the radius. A clinical and roentgenographic study of 310 cases. *Acta Chir Scand* 1956 ; 112 : 115-134.
2. Ashwood N, Bain GI, Unni R. Management of Mason type-III radial head fractures with a titanium prosthesis,

- ligament repair, and early mobilization. *J Bone Joint Surg* 2004 ; 86-A : 274-280.
3. **Baciu C, Brosteanu G, Füllop A, Chicu-Isac E.** Les fractures de la tête radiale chez l'adulte. Résultats éloignés après résection parcellaire, résection totale et arthroplastie avec endoprothèse en vitallium. *Acta Orthop Belg* 1964 ; 30 : 420-437.
 4. **Bain GI, Ashwood N, Baird R, Unni R.** Management of Mason type-III radial head fractures with a titanium prosthesis, ligament repair, and early mobilization. Surgical technique. *J Bone Joint Surg* 2005 ; 87-A Suppl 1 : 136-147.
 5. **Beck E.** Silasticprothese zum Ersatz des resezierten Speichenköpfchens bei Trümmerbrüchen. *Arch Orthop Unfallchir* 1974 ; 80 : 143-152.
 6. **Beredjikian PK, Nalbantoglu U, Potter HG, Hotchkiss RN.** Prosthetic radial head components and proximal radial morphology : A mismatch. *J Shoulder Elbow Surg* 1999 ; 8 : 471-475.
 7. **Berger M, Urvoy P, Mestdagh H.** Étude comparative du traitement des fractures de la tête radiale par résection ou par implant en silastic de Swanson. *Ann Radiol (Paris)* 1991 ; 34 : 330-337.
 8. **Birkedal JP, Deal DN, Ruch DS.** Loss of flexion after radial head replacement. *J Shoulder Elbow Surg* 2004 ; 13 : 208-213.
 9. **Bohl WR, Brightman E.** Fracture of a silastic radial-head prosthesis : Diagnosis and localization of fragments by xerography. A case report. *J Bone Joint Surg* 1981 ; 63-A : 1482-1483.
 10. **Boulas HJ, Morrey BF.** Biomechanical evaluation of the elbow following radial head fracture. Comparison of open reduction and internal fixation vs. excision, silastic replacement, and non-operative management. *Chir Main* 1998 ; 17 : 314-320.
 11. **Brinkman JM, Rahusen FT, de Vos MJ, Eygendaal D.** Treatment of sequelae of radial head fractures with a bipolar radial head prosthesis : Good outcome after 1-4 years follow-up in 11 patients. *Acta Orthop* 2005 ; 76 : 867-872.
 12. **Calfree R, Madom I, Weiss AP.** Radial head arthroplasty. *J Hand Surg* 2006 ; 31-A : 314-321.
 13. **Carn RM, Medige J, Curtain D, Koenig A.** Silicone rubber replacement of the severely fractured radial head. *Clin Orthop* 1986 ; 209 : 259-269.
 14. **Carr CR, Howard JW.** Metallic cap replacement of radial head following fracture. *W J Surg Obst Gyn* 1951 ; 59 : 539-546.
 15. **Charnley G, Judet T, de Loubresse CG, Piriou P.** Articulated radial head replacement and elbow release for post head-injury heterotopic ossification. *J Orthop Trauma* 1996 ; 10 : 68-71.
 16. **Cherry JC.** Use of acrylic prosthesis in the treatment of fracture of the head of the radius. *J Bone Joint Surg* 1953 ; 35-B : 70-71.
 17. **Cutler C.** Fractures of the head and neck of the radius. *Ann Surg* 1926 ; 8 : 267-278.
 18. **Dickey LE, Barnes WP.** A salvage procedure for certain fractures of the radial head. *South Med J* 1964 ; 57 : 711-713.
 19. **Doornberg JN, Linzel DS, Zurakowski D, Ring D.** Reference points for radial head prosthesis size. *J Hand Surg* 2006 ; 31-A : 53-57.
 20. **Edwards GE, Rostrup O.** Radial head prosthesis in the management of radial head fractures. *Can J Surg* 1960 ; 3 : 153-155.
 21. **Edwards GS, Jr, Jupiter JB.** Radial head fractures with acute distal radioulnar dislocation. Essex-Lopresti revisited. *Clin Orthop* 1988 ; 234 : 61-69.
 22. **Essex-Lopresti P.** Fractures of the radial head with distal radio-ulnar dislocation. *J Bone Joint Surg* 1951 ; 33-B : 244-247.
 23. **Ferlic DC, Patchett CE, Clayton ML, Freeman AC.** Elbow synovectomy in rheumatoid arthritis. Long-term results. *Clin Orthop* 1987 ; 220 : 119-125.
 24. **Frankle MA, Koval KJ, Sanders RW, Zuckerman JD.** Radial head fractures associated with elbow dislocations treated by immediate stabilization and early motion. *J Shoulder Elbow Surg* 1999 ; 8 : 355-360.
 25. **Frosch KH, Knopp W, Dresing K et al.** A bipolar radial head prosthesis after comminuted radial head fractures : Indications, treatment and outcome after 5 years. *Unfallchirurg* 2003 ; 106 : 367-373.
 26. **Gabrion A, Havet E, Bellot F et al.** Recent fractures of the radial head associated with elbow instability treated with floating Judet prosthesis. *Rev Chir Orthop Reparatrice Appar Mot* 2005 ; 91 : 407-414.
 27. **Gordon M and Bullough PG.** Synovial and osseous inflammation in failed silicone-rubber prostheses. *J Bone Joint Surg* 1982 ; 64-A : 574-580.
 28. **Gupta GG, Lucas G, Hahn DL.** Biomechanical and computer analysis of radial head prostheses. *J Shoulder Elbow Surg* 1997 ; 6 : 37-48.
 29. **Harrington IJ, Sekyi-Otu A, Barrington TW et al.** The functional outcome with metallic radial head implants in the treatment of unstable elbow fractures : A long-term review. *J Trauma* 2001 ; 50 : 46-52.
 30. **Harrington IJ, Tountas AA.** Replacement of the radial head in the treatment of unstable elbow fractures. *Injury* 1981 ; 12 : 405-412.
 31. **Holmenschlager F, Halm JP, Winckler S.** Les fractures fraîches de la tête radiale. Résultats de la prothèse à cupule flottant de Judet. *Rev Chir Orthop* 2002 ; 88 : 387-397.
 32. **Hotchkiss RN, An KN, Sowa DT et al.** An anatomic and mechanical study of the interosseous membrane of the forearm : Pathomechanics of proximal migration of the radius. *J Hand Surg* 1989 ; 14-A : 256-261.
 33. **Hotchkiss RN, Weiland AJ.** Valgus stability of the elbow. *J Orthop Res* 1987 ; 5 : 372-737.

34. Ikeda M, Sugiyama K, Kang C *et al.* Comminuted fractures of the radial head. Comparison of resection and internal fixation. *J Bone Joint Surg* 2005 ; 87-A : 76-84.
35. Itamura J, Roidis N, Mirzayan R *et al.* Radial head fractures : MRI evaluation of associated injuries. *J Shoulder Elbow Surg* 2005 ; 14 : 421-424.
36. Jensen SL, Olsen BS, Tyrdal S *et al.* Elbow joint laxity after experimental radial head excision and lateral collateral ligament rupture : Efficacy of prosthetic replacement and ligament repair. *J Shoulder Elbow Surg* 2005 ; 14 : 78-84.
37. Johnson JA, Beingessner DM, Gordon KD *et al.* Kinematics and stability of the fractured and implant-reconstructed radial head. *J Shoulder Elbow Surg* 2005 ; 14 : 195S-201S.
38. Judet T, Garreau de Loubresse C, Piriou P, Charnley G. A floating prosthesis for radial-head fractures. *J Bone Joint Surg* 1996 ; 78-B : 244-249.
39. Judet T, Massin P, Bayeh PJ. Prothèse de tête radiale à cupule flottante dans les traumatismes récents et anciens du coude : Résultats préliminaires. *Rev Chir Orthop Reparatrice Appar Mot* 1994 ; 80 : 123-130.
40. Kaplan EB. Surgical approach to the proximal end of the radius and its use in fractures of the head and neck of the radius. *J Bone Joint Surg* 1941 ; 23 : 86-92.
41. Key JA. Treatment of fractures of the head and neck of the radius. *J Am Med Assoc* 1931 ; 96 : 101-104.
42. Khurana JS, Kattapuram SV, Becker S, Mayo-Smith W. Galeazzi injury with an associated fracture of the radial head. *Clin Orthop* 1988 ; 234 : 70-71.
43. King BB. Resection of the radial head and neck. An end-result study of thirteen cases. *J Bone Joint Surg* 1939 ; 21 : 839-857.
44. King GJ, Zarzour ZD, Patterson SD, Johnson JA. An anthropometric study of the radial head : Implications in the design of a prosthesis. *J Arthroplasty* 2001 ; 16 : 112-116.
45. King GJ, Zarzour ZD, Rath DA *et al.* Metallic radial head arthroplasty improves valgus stability of the elbow. *Clin Orthop* 1999 ; 368 : 114-125.
46. Knight DJ, Rymaszewski LA, Amis AA, Miller JH. Primary replacement of the fractured radial head with a metal prosthesis. *J Bone Joint Surg* 1993 ; 75-B : 572-576.
47. Mackay I, Fitzgerald B, Miller JH. Silastic radial head prosthesis in rheumatoid arthritis. *Acta Orthop Scand* 1982 ; 53 : 63-66.
48. Mackay I, Fitzgerald B, Miller JH. Silastic replacement of the head of the radius in trauma. *J Bone Joint Surg* 1979 ; 61-B : 494-497.
49. Mayhall WS, Tiley FT, Paluska DJ. Fracture of silastic radial-head prosthesis. Case report. *J Bone Joint Surg* 1981 ; 63-A : 459-460.
50. Maynou C, Mestdagh H, Forgeois P, Berger M. Étude comparative du traitement des fractures de la tête radiale par résection radiale ou par implant en silastic de Swanson. *Acta Orthop Belg* 1996 ; 62 : 105-111.
51. McKee MD, Pugh DM, Wild LM *et al.* Standard surgical protocol to treat elbow dislocations with radial head and coronoid fractures. Surgical technique. *J Bone Joint Surg* 2005 ; 87-A Suppl 1 : 22-32.
52. Moro JK, Werier J, MacDermid JC *et al.* Arthroplasty with a metal radial head for unreconstructible fractures of the radial head. *J Bone Joint Surg* 2001 ; 83-A : 1201-1211.
53. Moro JK, Werier J, Patterson JD, King GJ. Outcome of metal radial head arthroplasty in acute radial head fractures. *J Bone Joint Surg* 2000 ; 82-B Supp I : 4-5.
54. Morrey BF. Complex instability of the elbow. *J Bone Joint Surg* 1997 ; 79-A : 460-469.
55. Morrey BF. Radial head fracture. In : *The elbow and its disorders*. B. F. Morrey Ed. Saunders W.B., Philadelphia, pp 341-364.
56. Morrey BF, Askew L, Chao EY. Silastic prosthetic replacement for the radial head. *J Bone Joint Surg* 1981 ; 63-A : 454-458.
57. Neuwirth AA. Nonsplinting treatment of fractures of the elbow joint. *J Am Med Assoc* 1942 ; 12 : 971-972.
58. Patterson JD, Jones CK, Glisson RR *et al.* Stiffness of simulated radial neck fractures fixed with 4 different devices. *J Shoulder Elbow Surg* 2001 ; 10 : 57-61.
59. Pfaeffle HJ, Stabile KJ, Li ZM, Tomaino MM. Reconstruction of the interosseous ligament unloads metallic radial head arthroplasty and the distal ulna in cadavers. *J Hand Surg* 2006 ; 31-A : 269-278.
60. Pomianowski S, Morrey BF, Neale PG *et al.* Contribution of monoblock and bipolar radial head prostheses to valgus stability of the elbow. *J Bone Joint Surg* 2001 ; 83-A : 1829-1834.
61. Pomianowski S, Sawicki G, Orlowski J *et al.* Bipolar radial head prosthesis – own design. *Chir Narzadow Ruchu Ortop Pol* 2003 ; 68 : 53-57.
62. Popovic N, Djekic J, Lemaire R, Gillet P. A comparative study between proximal radial morphology and the floating radial head prosthesis. *J Shoulder Elbow Surg* 2005 ; 14 : 433-440.
63. Popovic N, Gillet P, Rodriguez A, Lemaire R. Fracture of the radial head with associated elbow dislocation : Results of treatment using a floating radial head prosthesis. *J Orthop Trauma* 2000 ; 14 : 171-177.
64. Pribyl CR, Kester MA, Cook SD *et al.* The effect of the radial head and prosthetic radial head replacement on resisting valgus stress at the elbow. *Orthopedics* 1986 ; 9 : 723-726.
65. Ring D, Jupiter JB, Zilberfarb J. Posterior dislocation of the elbow with fractures of the radial head and coronoid. *J Bone Joint Surg* 2002 ; 84-A : 547-551.

66. **Rochwerger A, Bataille JF, Kelberine F et al.** Analyse rétrospective d'une série de 78 fractures de la tête radiale opérées. *Acta Orthop Belg* 1996 ; 62 : 87-92.
67. **Schwartz RP, Young F.** Treatment of fractures of the head and neck of the radius and slipped radial epiphysis in children. *Surg Gyn Obst* 1933 ; 57 : 258-266.
68. **Sellman DC, Seitz WH Jr., Postak PD, Greenwald AS.** Reconstructive strategies for radioulnar dissociation : A biomechanical study. *J Orthop Trauma* 1995 ; 9 : 516-522.
69. **Sever JW.** Fractures of the head and neck of the radius. *J Am Med Assoc* 1925 ; 84 : 1551-1555.
70. **Smets S, Govaers K, Jansen N et al.** The floating radial head prosthesis for comminuted radial head fractures : A multicentric study. *Acta Orthop Belg* 2000 ; 66 : 353-358.
71. **Smith AM, Urbanosky LR, Castle JA et al.** Radius pull test : Predictor of longitudinal forearm instability. *J Bone Joint Surg* 2002 ; 84-A : 1970-1976.
72. **Sommelet J, Schmitt D, Boileau F et al.** Le remplacement prothétique de la tête radiale chez l'adulte. *Rev Chir Orthop Reparatrice Appar Mot* 1974 ; 60 : 451-463.
73. **Speed K.** Ferrule caps for the head of the radius. *Surg Gynecol Obstet* 1941 ; 73 : 845-850.
74. **Speed K.** Fracture of the head of the radius. *Am J Surg* 1924 ; 38 : 157-159.
75. **Speed K.** Traumatic lesions of the head of the radius. Relation to elbow joint dysfunction. *Surg Clin North Am* 1924 ; 4 : 651-666.
76. **Stoffelen DV, Holdsworth BJ.** Excision or silastic replacement for comminuted radial head fractures. A long-term follow-up. *Acta Orthop Belg* 1994 ; 60 : 402-407.
77. **Sutro CJ.** Regrowth of bone at the proximal end of the radius following resection in this region. *J Bone Joint Surg* 1935 ; 17 : 867-878.
78. **Swanson AB.** *Flexible implant resection arthroplasty in the hand and extremities.* In : Ed. Mosby, St. Louis, pp 268.
79. **Swanson AB.** Flexible implant resection arthroplasty of the elbow. In : *Orthopaedic surgery and traumatology.* Ed. Excerpta Medica, Amsterdam, pp 894-895.
80. **Swanson AB, Jaeger SH, La Rochelle D.** Comminuted fractures of the radial head. The role of silicone-implant replacement arthroplasty. *J Bone Joint Surg* 1981 ; 63-A : 1039-1049.
81. **Swieszkowski W, Skalski K, Pomianowski S, Kedzior K.** The anatomic features of the radial head and their implication for prosthesis design. *Clin Biomech* 2001 ; 16 : 880-887.
82. **Szabo RM, Hotchkiss RN, Slater RR Jr.** The use of frozen-allograft radial head replacement for treatment of established symptomatic proximal translation of the radius : Preliminary experience in five cases. *J Hand Surg* 1997 ; 22-A : 269-278.
83. **Taylor TFK, O'Connor BT.** The effect upon the inferior radio-ulnar joint of excision of the head of the radius in adults. *J Bone Joint Surg* 1964 ; 46-B : 83-88.
84. **Tejwani SG, Markolf KL, Benhaim P.** Graft reconstruction of the interosseous membrane in conjunction with metallic radial head replacement : A cadaveric study. *J Hand Surg* 2005 ; 3A : 335-342.
85. **Trepman E, Ewald FC.** Early failure of silicone radial head implants in the rheumatoid elbow. A complication of silicone radial head implant arthroplasty. *J Arthroplasty* 1991 ; 6 : 59-65.
86. **van Beek AJ, Meijer WS, de Mol BAJM.** Het gebruik van siliconprothesen bij communiteive fracturen van het caput radii. *Ned Tijdschr Geneesk* 1986 ; 130 : 1797-1800.
87. **Van Glabbeek F, Van Riet R, Verstreken J.** Current concepts in the treatment of radial head fractures in the adult. A clinical and biomechanical approach. *Acta Orthop Belg* 2001 ; 67 : 430-441.
88. **Van Glabbeek F, Van Riet RP, Baumfeld JA et al.** Detrimental effects of overstuffing or understuffing with a radial head replacement in the medial collateral-ligament deficient elbow. *J Bone Joint Surg* 2004 ; 86-A : 2629-2635.
89. **Van Glabbeek F, van Riet RP, Baumfeld JA et al.** The kinematic importance of radial neck length in radial head replacement. *Med Eng Phys* 2005 ; 27 : 336-342.
90. **van Riet R, Van Glabbeek F, Verborgt O, Gielen J.** Capitellar erosion caused by a metal radial head prosthesis : A case report. *J Bone Joint Surg* 2004 ; 86-A : 1061-1064.
91. **van Riet RP, Morrey BF, O'Driscoll SW, Van Glabbeek F.** Associated injuries complicating radial head fractures : A demographic study. *Clin Orthop* 2005 ; 441 : 351-355.
92. **van Riet RP, Van Glabbeek F, Baumfeld JA et al.** The effect of the orientation of the non-circular radial head on elbow kinematics. *Clin Biomech* 2004 ; 19 : 595-599.
93. **van Riet RP, Van Glabbeek F, Neale PG et al.** Anatomical considerations of the radius. *Clin Anat* 2004 ; 17 : 564-569.
94. **van Riet RP, Van Glabbeek F, Neale PG et al.** The non-circular shape of the radial head. *J Hand Surg* 2003 ; 28-A : 972-978.
95. **Vanderwilde RS, Morrey BF, Melberg MW, Vinh TN.** Inflammatory arthritis after failure of silicone rubber replacement of the radial head. *J Bone Joint Surg* 1994 ; 76-B : 78-81.
96. **Vichard P, Tropet Y, Dreyfus-Schmidt G et al.** Treatment of isolated fractures of the proximal end of the radius in adults. Remarks concerning 168 cases. *Ann Chir Main* 1987 ; 6 : 189-194.
97. **Vichard P, Tropet Y, Dreyfus-Schmidt G et al.** Fractures of the proximal end of the radius associated

with other traumatic lesions of the upper limb. A report of seventy-three cases. *Ann Chir Main* 1988 ; 7 : 45-53.

98. Wallenbock E, Potsch F. Resection of the radial head : An alternative to use of a prosthesis ? *J Trauma* 1997 ; 43 : 959-961.

99. Worsing RA, Engber WD, Lange TA. Reactive synovitis from particulate silastic. *J Bone Joint Surg* 1982 ; 64-A : 581-585.

100. Wretenberg P, Ericson A, Stark A. Radial head prosthesis after fracture of radial head with associated elbow instability. *Arch Orthop Trauma Surg* 2006 ; 1-5.