



## Early results with the thrust plate prosthesis in young patients with osteoarthritis of the hip

Sanjeev SHARMA, Gopalkrishna VERMA, Kingsley PAUL DRAVIRAJ, Manjit BHAMRA

*From Rotherham General Hospitals (NHS) Trust, Rotherham, U.K*

**The purpose of this study was to evaluate the results of the Thrust Plate Prosthesis as a treatment option for osteoarthritis of the hip in young patients.**

**Of the fifty patients (63 hips) reviewed, 31 (62%) were males and 19 (38%) females. Pre-operative diagnosis included primary osteoarthritis (23), developmental dysplasia (8), avascular necrosis (7), Perthes (4), post-traumatic arthritis (3), rheumatoid arthritis (2), ankylosing spondylitis (1), psoriatic arthropathy (1) and slipped upper femoral epiphysis (1). All components were implanted uncemented with metal-on-metal articulation. The average follow-up was 4.04 years (range 12 months-8.5 years).**

**The mean age of the patients was 42.3 years (range 21-57 years). The mean pre-operative Harris Hip Score was 41.9 (range 12-89) and at final follow-up 89.91 (range 41-100). In 25 hips with  $\geq 5$ yr follow-up, the average HHS at final follow-up was 84.5 (range 50-100). Complications included dislocation (2), transient sciatic nerve palsy (1), discomfort from lateral strap (2), implantation of wrong femoral head (1), revision (3=4.76%) and implant loosening (4) (6.35%).**

**The thrust plate prosthesis is a useful alternative in young patients with hip arthritis and the results are comparable with other uncemented hip replacements. The added advantage is preservation of the proximal femoral bone stock, which can prove useful in future revisions.**

### INTRODUCTION

Wolff's law states that the internal architecture of bone is determined by the direction and magni-

tude of external forces applied to it. The presence of a rigid prosthetic stem exerts a stress shielding effect on the proximal femur. Experimental stress analysis of the proximal femur both with and without a cemented intra-medullary stem has shown stress reduction of up to 60% in the surrounding bone of the proximal part of the implanted stem (10). This leads to significant loss of bone stock in the proximal femur. In an endeavour to retain the physiological stress pattern and bone stock as far as possible, the thrust plate prosthesis (TPP) was developed by Jacob and Huggler (10).

The principle of the thrust plate prosthesis is to transfer the resulting forces from the hip joint via a thrust plate directly to the femoral neck and above all to the cortical bone of the calcar (12). This force transfer is as close to physiological as possible,

---

■ Sanjeev Sharma, Senior House Officer, Orthopaedics.

■ Gopalkrishna Verma, Senior House Officer, Orthopaedics.

■ Kingsley Paul Draviraj, Senior House Officer, Orthopaedics.

■ Manjit Bhamra, Consultant Orthopaedic Surgeon.

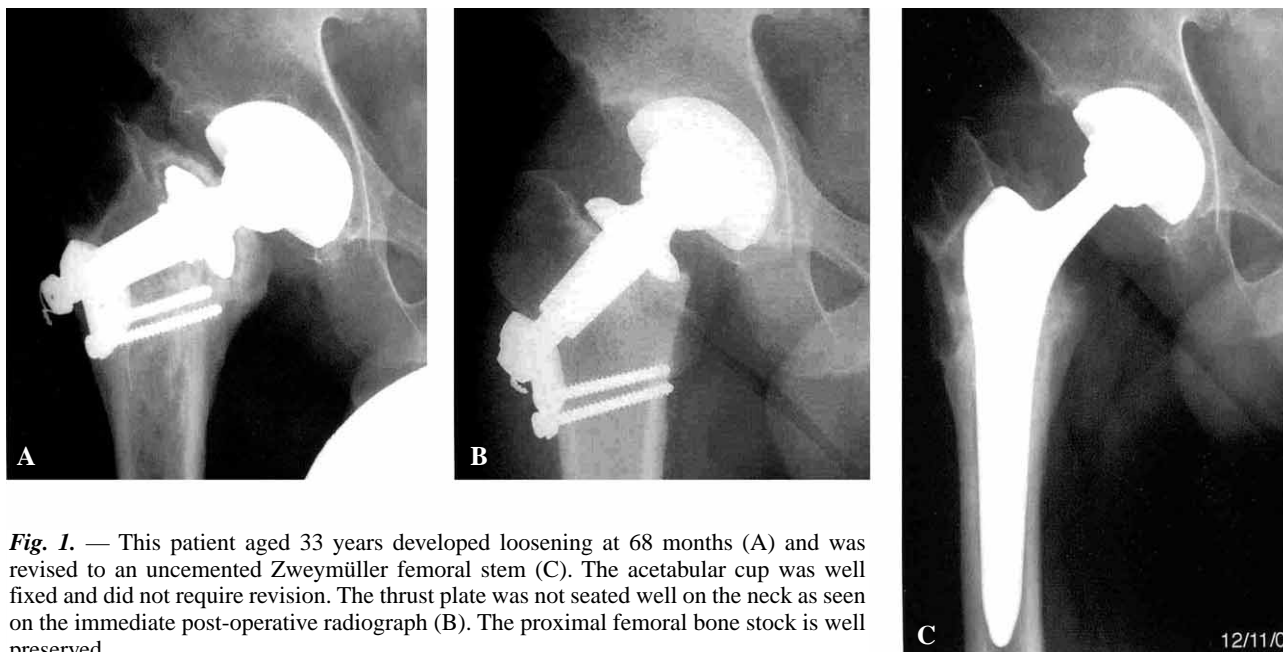
*Department of Orthopaedic Surgery, Rotherham General Hospital, Rotherham, U.K.*

Correspondence : Manjit Bhamra, MBChB ChM MED FRCS.

Department of Orthopaedic Surgery, Rotherham General Hospitals (NHS) Trust, Moorgate Road, Rotherham S60 2UD, U.K. E-mail : manjit.bhamra@rothgen.nhs.uk.

© 2005, Acta Orthopædica Belgica.

---



**Fig. 1.** — This patient aged 33 years developed loosening at 68 months (A) and was revised to an uncemented Zweymüller femoral stem (C). The acetabular cup was well fixed and did not require revision. The thrust plate was not seated well on the neck as seen on the immediate post-operative radiograph (B). The proximal femoral bone stock is well preserved.

according to the biomechanical experiments of Jacob and Huggler (10). The plate has a central orifice to accept the mandrel, which carries the prosthetic femoral head. The rigid mandrel is anchored by a single bolt to a strap, which is held onto the lateral femoral cortex just below the innominate tubercle by two cortical screws (fig 1). The extreme stiffness of the mandrel and central bolt ensures that the femoral neck will not distort under stress and keep the cranial periphery of the thrust plate seated firmly on the neck during weight bearing. The osseous incorporation of the TPP and the adaptation of bone to local force transmission in the calcar area depend on a normal bone quality. Fink *et al* (7) found a high failure rate (14.8% at an average of 26 months) of this prosthesis when used in patients with polyarthritis. In patients with avascular necrosis of femoral head, they found an overall failure rate of 9.7% at an average of 4.8 years using the same prosthesis (8). We present short-term results of this implant in 50 patients with hip osteoarthritis.

#### PATIENTS AND METHODS

A retrospective analysis was carried out for the patients who underwent TPP between 1995 and 2003 in

the department. Fifty-four such patients were operated upon, including 34 males and 20 females. Three patients died (2 males and 1 female) and one (male) was lost to follow-up. Fifty patients were therefore available for review with 31 (62%) males and 19 (38%) females. Thirty-seven (74%) underwent unilateral procedures and 13 (26%) underwent bilateral (b/l) procedures taking the total number of devices available for review to 63. Among the unilateral procedures 22 patients were operated on the right side and 15 on the left. In 3 patients (out of 13 b/l) both hips were operated in the same sitting.

Pre-operative diagnosis included :

Primary osteoarthritis	23
Developmental dysplasia of hip	8
Avascular necrosis of the femoral head	7
Perthes disease	4
Post-traumatic arthritis	3
Rheumatoid arthritis	2
Ankylosing spondylitis	1
Psoriatic arthropathy	1
Slipped upper femoral epiphysis	1

Fourteen patients had had a previous operative intervention – core decompression (3), shelf procedure (1), intraarticular steroid injection (7), Heyman & Herndon procedure (2), and arthroscopic removal of loose body (1) [This patient had suffered from posterior dislocation of hip in the past, which was reduced closed].

All patients underwent CT scanning to assess the head-neck anteversion angle, an angle of more than 25° was considered excessive and the TPP was not offered to those patients.

### Technique

All the operations were performed by a senior surgeon using the postero-lateral approach. The acetabular component (Fitmore) was fixed with cementless technique with or without a screw for additional stability. After resection of the femoral head, a drill guide was used to drill a central hole through the lateral femoral cortex and into the cancellous bone of the femoral neck. This provided a guide for face milling of the resected neck to create an appropriate seat for the thrust plate and for reaming the central channel for the mandrel. The mandrel was anchored to a lateral strap by a single bolt. The strap itself was then fixed to the proximal femur by two screws in all cases. All the joints had a metal-on-metal Metasul™ articulation.

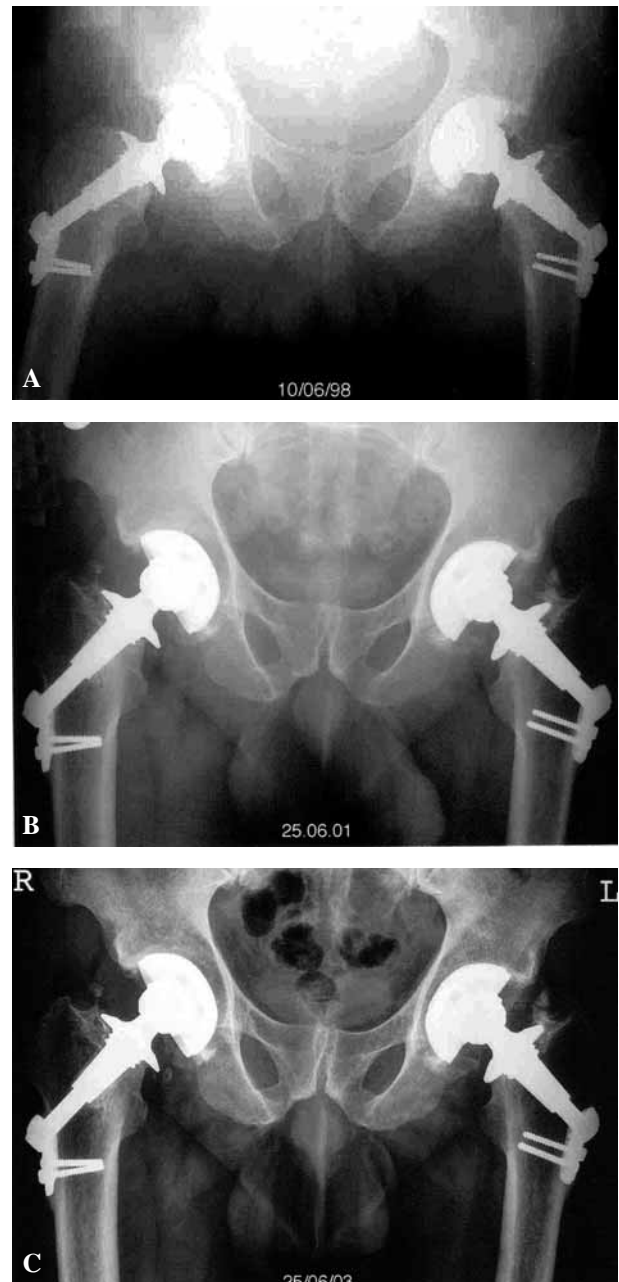
The post-operative regime was similar to any other total hip replacement. The patients were followed regularly at 6 weeks, 3 months, 6 months, 1 year and then every two years thereafter. The average follow-up was 4.04 years with a range of 12 months to 8.5 years.

### RESULTS

The mean age of the patients was 42.3 years (range 21-57 years). The mean follow-up was 4.04 years (range 1-8.5 years). Twenty five hips had a follow-up of  $\geq 5$  years (average 6.28 years, range 5-8 1/2 years) (fig 2). The mean pre-operative Harris Hip Score (HHS) was 41.9 points (range 12-89). The mean HHS at final follow-up was 89.91 (range 41-100). In 25 hips with  $\geq 5$ yr follow-up the average hip score was 84.5 (range 50-100).

The acetabular cup consisted of a Fitmore shell in 62 cases and a CLS expansion in 1 case. The most common thrust plate size was 40 (30 hips) followed closely by 44 (27 hips). The most common bolt sizes were 70 and 78 (18 and 17 patients respectively).

Two hips dislocated in the early post-operative period. One patient collapsed due to cardiac ischaemia, was resuscitated immediately and transferred to the intensive therapy unit. The dislocated hip was reduced closed after the patient was stable. The other dislocated during routine mobilisation



**Fig. 2.** — This patient aged 48 years underwent bilateral TPP at the same sitting (A). Subsequent radiographs at 3 years (B) and 5 years (C) follow-up do not show any signs of loosening at five years.

and was reduced by open reduction. The acetabular cup was found to have an excessive anteversion, which was corrected. Both of these patients did not have any further problems, the former is now 5.25 yrs and the latter 4.25 yrs post surgery. One

Table I. — Details of patients who underwent revision surgery for implant loosening

Patient No.	Age	Gender	Diagnosis	Duration to failure and component failed	Revision implant used
1	52	M	Primary OA	21 months, Femoral component	Zweymuller, cementless
2	33	M	Perthes Disease	68 months, Femoral component	Zweymuller, cementless
3	48	F	Acetabular Dysplasia	39 months, Femoral component	Zweymuller, cementless

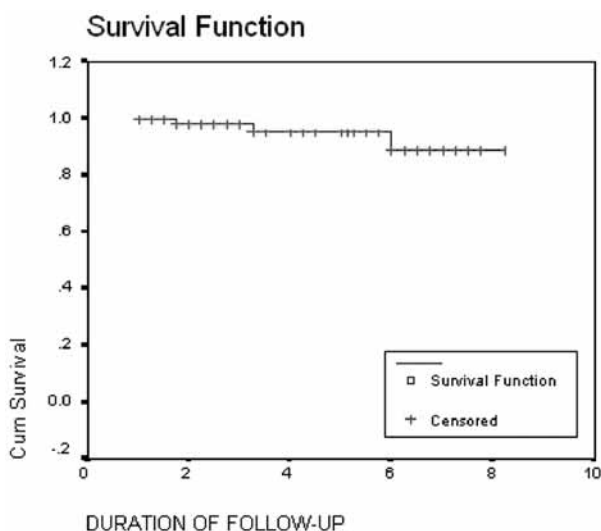


Fig. 3. — Kaplan-Meier survival curve for 63 thrust plate prostheses.

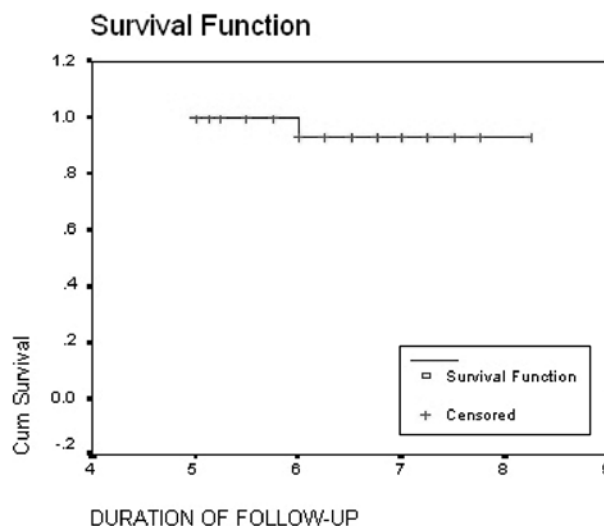


Fig. 4. — Kaplan-Meier survival curve for 25 Thrust Plate Prostheses with ≥ 5 years follow-up.

patient had a transient neurapraxia of the sciatic nerve, which recovered completely by 6 weeks.

Aseptic implant loosening occurred in four (6.35%) patients. Three of them were revised, details of which are mentioned in table I. In the one not revised, breakage of screws fixing the lateral strap to the femoral shaft, was noticed at 1.5 yrs. The patient is 8 1/2 yrs post surgery now and does not want a revision. The HHS of this patient is 62 but she is coping well with activities of daily life at present. The cause for revision in all the three was progressive radiolucency in zones 1 and 2 of the femur as described for TPP by Fink *et al* (8). This led to migration of the mandrel into varus. The per-operative findings in all three included loose femoral component (no or minimal osteo-integration of mandrel) with a well-fixed acetabular component. One common feature was the preservation of upper femoral bone stock, which made implantation of an uncemented femoral stem easy (fig 1).

In one patient a wrong femoral head (Protasul™ instead of Metasul™) was implanted, which was corrected by repeat surgery within a few days. Two patients complained of discomfort at the lateral aspect of the thigh, from the strap. In both of these cases pain occurred in the initial year following surgery and settled spontaneously in one case and needed local steroid injection in the other. None of the patients suffered from infection (superficial or deep) or problems with wound healing.

**Statistics**

The average survival time was 8.07 years (95% CI- 7.54 to 8.61 years) with median survival time 8.50 years (fig 3).

For patients followed-up for ≥ 5 years the average survival time was 8.33 years (95% CI 7.89 to 8.78 years) with median survival time of 8.5 years (fig 4).

## DISCUSSION

The treatment of hip arthritis in young patients is challenging. Problems of total hip arthroplasty in younger patients are related to their high demand life styles. This leads to greater stresses on the implant and an increased chance of early failure. Considering their age, these patients are likely to need a revision procedure later in their lifetime. Therefore, an implant that minimises loss of bone stock at the primary procedure presents a theoretical advantage. Although the first implantation of a TPP was performed in 1978 (12) there are few clinical outcome reports in literature (1, 7, 8, 12, 19, 20). As a consequence the prosthesis has not gained widespread acceptance among hip surgeons.

Implant failure due to aseptic loosening is by far the most significant issue when treating patients in this age group. The failure rate of TPP in the present study was 6.35% at an average of 4 years and 8% at an average of 6.3 years. The mode of failure in all three patients was due to varus angulation of the mandrel and radiolucency beneath the thrust plate (zone 1 and 2). These rates are comparable to earlier reports of failure of this prosthesis : Fink *et al* (8) – 9.7% in 72 hips with osteonecrosis at 4.8 years ; Fink *et al* (7) 14.8% in 47 hips with polyarthritis at 26 months ; Huggler *et al* (12) 21% in 115 hips at a maximum follow-up of 9 years ; Zelle BA (19) 6.9% in 58 hips. The most encouraging results with the use of this prosthesis have been reported by Buergi *et al* (1). In their case series of 102 hips they have reported a 2% rate of aseptic loosening at an average of 4.8 years. Their detailed description of the types of bone remodelling around the prosthesis and their mechanisms is interesting. Of particular interest was the observation of bone growth over the thrust plate, engulfing its laterocranial lip without any signs of loosening which was observed in some patients in our series as well, although we do not know the significance of this finding. Our higher rate of failure compared to their series may reflect the learning curve required in the proficient use of this technically demanding procedure. The mode of failure of the prosthesis in all these studies has been consistent, i.e. radiolucency beneath the thrust plate in zones 1 and 2.

The main technical difficulty in using this prosthesis is the exact seating of the thrust plate in order to restore the femoral neck-shaft angle. To ensure near physiological loads on the proximal femur, the TPP should be implanted at an inclination angle of 125-135° (9). Implantation of the TPP in varus position leads to shearing forces, resulting in caudal slipping of the thrust plate. The disadvantages of valgus implantation include deviation of the plate at the lateral femur, decreased range of motion of the hip joint and unphysiological loads on the proximal femur (10). Although meticulous pre-operative planning is helpful, to reproduce the pre-operative measurements at the time of surgery is technically difficult. Patients with excessive anteversion, short femoral neck and an excessive valgus of the femoral neck are not suitable for this procedure.

Discomfort from the lateral strap is another problem with the use of TPP (7). This occurs due to the irritation of the fascia lata by the lateral strap or the bolt. Although the present generation (3<sup>rd</sup>) of implant is made of titanium alloy with a smaller lateral strap, some patients still complain of difficulty in lying on the operated side. Two patients in our group complained of this problem.

We have come across two other complications reported in literature with the use of this prosthesis. Fink *et al* (6) reported a spontaneous fracture of the femur below the tip of the lateral plate in a patient with rheumatoid arthritis without any evidence of inferior bone quality or improper angle of implantation. Zelle *et al* (18) reported an unacceptably high rate of dislocation (8.6%) in their series using TPP. They, however, attributed this to the fact that all dislocations occurred in patients who had undergone previous surgeries to their hip.

Several authors have reported poor results after total hip arthroplasty in young patients (2, 9, 14, 16, 18). Kim *et al* (15) in a study of 78 uncemented stemmed prosthetic hip replacements with metal on polyethylene articulation found significant periprosthetic osteolysis in 20.5% at an average of 7.2 years. Dorr *et al* (4) reported 19% revision rate in 31 hips in patients less than 45 years old with more than 5 years follow-up. The results in the same cohort of patients in Dorr *et al*'s study (5) at an average follow-up of 9.2 years revealed a

revision rate of 33%. This shows that the results tend to deteriorate as the length of follow-up increases in younger patients.

The problem of osteolysis leading to failure has renewed the interest in metal-on-metal articulation in total hip replacements. The results of metal-on-metal articular resurfacing have been encouraging with a revision rate of 0.02% at an average of 3.3 years (3). The use of this articulation has reduced the incidence of osteolysis and thereby revision in both cemented (2% revision at an average of 5.2 years) (6) and uncemented total hip replacements (no revision at an average of 5 years) (17). The failure rate of TPP is higher when compared to these series. With renewed interest in metal-on-metal hip resurfacing arthroplasty, the indications of TPP have reduced and such has been the case in our practice as well. However, it is our experience that on occasion it has not been possible to implant a surface replacement and the TPP was an alternative conservative total hip replacement.

The limitation of our study is the duration of follow-up with a maximum available average follow-up of 6.3 years (in 25 hips). There is sufficient evidence in the literature that suggests that hip implants which have good early results may show deterioration in results and survivorship with long-term follow-up.

To summarise, we believe that TPP is a feasible implant for the treatment of young patients with osteoarthritis of the hip joint. The advantage of the thrust plate prosthesis, in the authors' opinion, is the preservation of proximal femoral bone stock thereby facilitating the conversion to an intramedullary anchored prosthesis in the event of patient needing a revision procedure. The disadvantages are technical difficulty in restoring the femoral neck-shaft angle, lateral thigh pain and a higher failure rate when compared to hip resurfacing arthroplasty. The long-term results will have to be evaluated in further trials.

## REFERENCES

- Buergi ML, Stoffel KK, Jacob HAC.** Radiological findings and clinical results of 102 Thrust-Plate femoral prostheses : a follow-up of 2-8 years. *J Arthroplasty* 2005 ; 20 : 108-117.
- Chandler HP, Reineck T, Wixson RL, McCarthy JC.** Total hip replacement in patients younger than thirty years old : A five-year follow-up study. *J Bone Joint Surg* 1981 ; 63-A : 1426-1434.
- Daniel J, Pynsent PB, McMinn DJW.** Metal-on-metal resurfacing of the hip in patients under the age of 55 years with osteoarthritis. *J Bone Joint Surg* 2004 ; 86-B :177-183.
- Dorr LD, Takei GK, Conaty JP.** Total hip arthroplasty in patients less than forty-five years old. *J Bone Joint Surg* 1983 ; 65-A : 474-479.
- Dorr LD, Luckett M, Conaty JP.** Total hip arthroplasties in patients younger than 45 years : A nine to ten year follow-up study. *Clin Orthop* 1990 ; 260 : 215-219.
- Dorr LD, Wan Z, Longjohn DB, Dubois B, Murken R.** Total hip arthroplasty with use of the Metasul metal-on-metal articulation. Four to seven-year results. *J Bone Joint Surg* 2000 ; 82-A : 789-798.
- Fink B, Siegmüller C, Schneider T, Conrad S, Schmielau G, Rütther W.** Short- and medium-term results of the thrust plate prosthesis in patients with polyarthritis. *Arch Orthop Trauma Surg* 2000 ; 120 : 294-298.
- Fink B, Schneider T, Conrad S, Marcus J, Protzen M, Rütther W.** The thrust plate prosthesis in patients with aseptic osteonecrosis of the femoral head. *Arch Orthop Trauma Surg* 2002 ; 122 : 499-505.
- Halley DK, Wroblewski BM.** Long-term results of low-friction arthroplasty in patients 30 years of age or younger. *Clin Orthop* 1986 ; 211 : 43-50.
- Jacob HAC, Huggler AH.** An investigation into biomechanical causes of prosthesis stem loosening within the proximal end of the human femur. *J Biomechanics* 1980 ; 13 : 159-173.
- Huggler AH, Jacob HAC.** *The Thrust Plate Prosthesis.* Springer, Berlin Heidelberg New York, 1996, pp 25-47.
- Huggler AH, Jacob HAC, Bereiter H, Haferkorn M, Ryf C, Schenk R.** Long-term results with the uncemented thrust plate prosthesis (TPP). *Acta Orthop Belg* 1993 ; 59 : 215-223.
- Jacob HAC, Huggler AH.** A new approach towards hip-prosthesis design. *Arch Orthop Trauma Surg* 1980 ; 97 : 141-144.
- Kim YH, Kim VEM.** Uncemented porous-coated anatomic total hip replacement : Results at six years in a consecutive series. *J Bone Joint Surg* 1993 ; 75-B : 6-13.
- Kim Y-H, Oh JH, Oh SH.** Cementless total hip arthroplasty in patients with osteonecrosis of the femoral head. *Clin Orthop* 1995 ; 320 : 73-84.
- Sharp DJ, Porter M.** The Charnley total hip arthroplasty in patients under age 40. *Clin Orthop* 1985 ; 201 : 51-56.
- Wagner M, Wagner H.** Medium-term results of a modern metal-on-metal system in total hip replacement. *Clin Orthop* 2000 ; 379 : 123-133.

18. **White SH.** The fate of cemented total hip arthroplasty in young patients. *Clin Orthop* 1988 ; 231 : 29-34.
19. **Zelle BA, Gerich TG, Bastian L, Shuler FD, Pape HC, Krettek C.** Total hip arthroplasty in young patients using the thrust plate prosthesis : Clinical and radiological results. *Arch Orthop Trauma Surg* 2004 ; 124 : 310-316.
20. **Steens W, Rosenbaum, Goetze, Gosheger, Daele RVD, Steinbeck J.** Clinical and functional outcome of the thrust plate prosthesis : short- and medium-term results. *Clin Biomechanics*. 2003 ; 18 : 647-654.