



Possible anatomic structures causing entrapment neuropathies of the median nerve : An anatomic study

Burak BILECENOGLU, Aysun Uz, Nazim KARALEZLI

From Ankara University School of Medicine, Ankara, Turkey

This study aimed at identifying the anatomic structures which may be responsible for entrapment neuropathies of the median nerve. Thirty upper extremities of 15 formalin fixed adult cadavers were dissected from the axilla to the distal forearm under Zeiss Opmi 9 – FC microscope. We encountered seven different anatomic structures that may compress the median nerve. These structures are the brachialis muscle, Struther's ligament, the bicipital aponeurosis, pronator teres, flexor digitorum superficialis, the accessory head of plexor pollicis longus (Gantzer's muscle) and vascular structures. The supracondylar process, which we did not encounter in our dissection, has been reported as another cause.

Based on our dissection findings and on literature, the median nerve can be compressed by seven different structures from the axilla to the distal forearm.

Knowledge of the course of the median nerve and its relations with the adjacent anatomic structures facilitates determination of the exact cause of entrapment and allows for a safe surgery.

from the medial and lateral cords of the brachial plexus. They fuse to form the median nerve anterior to the axillary artery. In the arm, the course of the median nerve is closely related to the brachial artery (2, 5, 16, 28, 29, 39, 42, 43). Generally, it does not give any muscular branch in the arm, except for a variable branch to the pronator teres given off proximal to the elbow joint (5, 39, 42). Along with the brachial artery, it travels between the brachialis muscle and the medial intermuscular septum. At the distal humerus both median nerve and brachial artery pass through the antecubital fossa underneath a fibrous sheath, the bicipital aponeurosis, which originates from the biceps tendon and the fascia of the flexor-pronator mass (2, 5, 16, 39, 42). It then passes between the two heads of the pronator teres. Within this muscle it gives off the anterior interosseous (AIN) branch. The nerve then courses between the flexor digitorum profundus (FDP) and flexor digitorum superficialis (sublimis) (FDS) in

INTRODUCTION

Disorders of the peripheral nervous system are common. Among these disorders, entrapment neuropathies, i.e. cases in which the nerve is compressed by adjacent anatomic structures, are frequently encountered by the clinician (22).

Classically, the median nerve receives fibers from C6, C7, C8 and T1, and supplies motor, sensory and sympathetic nerve fibers to the upper limb. It is formed in the axilla by a branch each

■ Burak Bilecenoglu, MD, Research Assistant.

■ Aysun Uz, MD, Associate Professor.

Department of Anatomy, Ankara University School of Medicine, Ankara, Turkey.

■ Nazım Karalezli, MD.

Department of Orthopaedic Surgery, Municipality of Health, Ankara Training and Research Hospital, Ankara, Turkey.

Correspondence : Burak Bilecenoglu, Department of Anatomy, Ankara University School of Medicine, Sıhhiye 06100, Ankara, Turkey. E-mail : bbilecenoglu@yahoo.com.

© 2005, Acta Orthopædica Belgica.

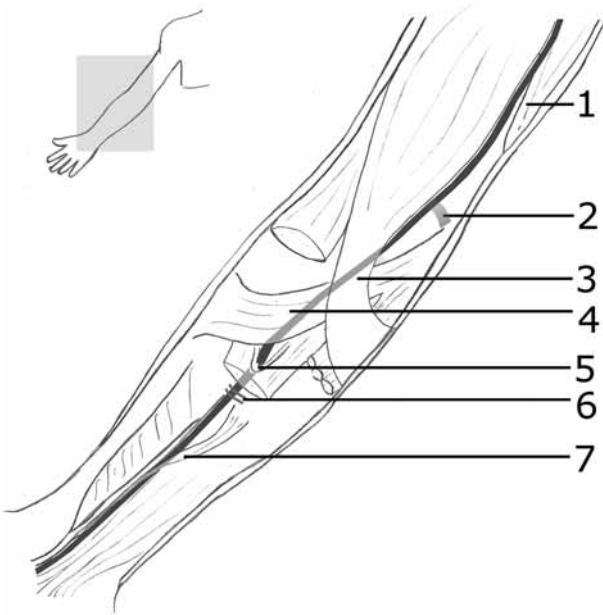


Fig. 1. — Possible compression sites for the median nerve : brachialis (1), Struthers' ligament (2), bicipital aponeurosis (3), pronator teres (4), flexor digitorum superficialis (5), vascular structures (6), accessory head of flexor pollicis longus (Gantzer's muscle) (7).

the forearm. Just above the wrist the nerve emerges to lie between the FDS and flexor carpi ulnaris (FCU). Here it gives off the palmar cutaneous branch which supplies the skin of the central portion of the palm. It then passes through the carpal tunnel into the hand, where it divides into a muscular branch and palmar digital branches (2, 5, 16, 28, 29, 39, 42, 43).

There are many reports about specific entrapment neuropathies, especially carpal tunnel syndrome, but studies of the structures related to the entrapment neuropathies of the median nerve in the forearm are scarce. In this study we aimed at pinpointing the anatomic structures which may cause entrapment neuropathies of the median nerve. To the best of our knowledge, this has not been reported in the literature so far.

MATERIALS AND METHODS

Thirty upper limbs of 15 formalin-fixed adult cadavers were dissected in this study. Dissections were performed under Zeiss Opmi 9 – FC dissection micro-

scope. The median nerve of each upper limb was explored from the axilla to the distal forearm and was examined in detail to determine its course and the possible structures that could lead to entrapment neuropathies of the median nerve. Anatomical variations and accessory structures related to the median nerve were noted.

RESULTS

From the axilla to the carpal tunnel we encountered seven different anatomic structures that can compress the median nerve (fig 1).

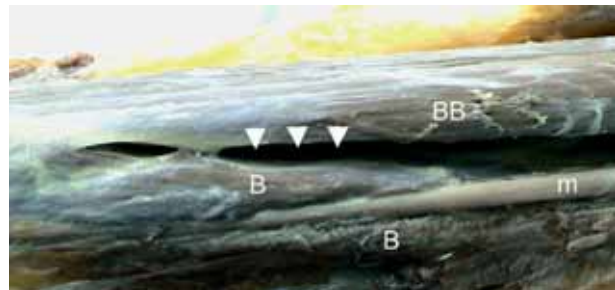


Fig. 2. — Proximal part of the elbow joint (right arm). m : median nerve, B : brachialis, BB : biceps brachii, arrowheads : normal course of the median nerve between brachialis and biceps brachii.



Fig. 3. — Right elbow. m : median nerve, PT : pronator teres (cut), FPL : flexor pollicis longus, FDP_{I-II} : flexor digitorum profundus, FDS : flexor digitorum superficialis, PL : palmaris longus, FCR : flexor carpi radialis. FDS, PL and FCR are retracted to show the abnormal branching pattern of the median nerve after the dissection of Struthers' ligament. Note the muscular branches to FDS arises from the superficial branch of the median nerve. Also the anterior interosseous nerve divides into two branches and lies between FPL, FDP_I and FDP_{II}.

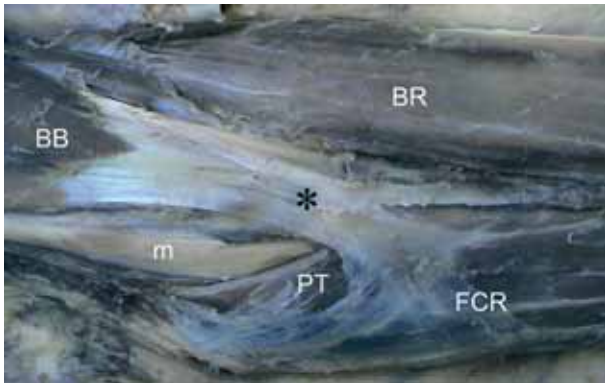


Fig. 4. — Left elbow. m : median nerve, BB: biceps brachii, asterisk : aponeurosis musculi bicipitis brachii (lactus fibrosus), FCR: flexor carpi radialis, PT: pronator teres, BR: brachioradialis.

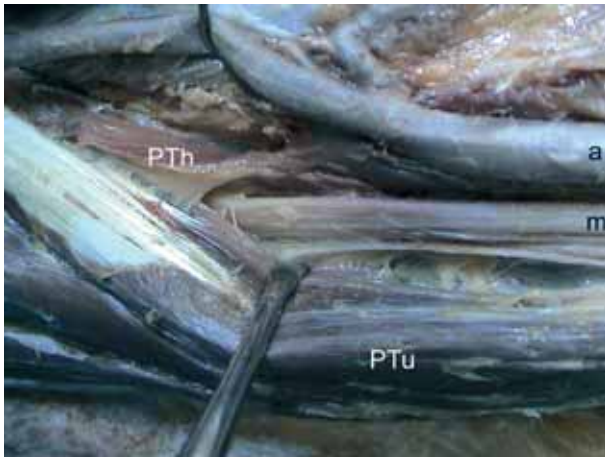


Fig. 5. — Right elbow. m : median nerve, PTh : humeral head of pronator teres, PTu : ulnar head of pronator teres, a : brachial artery. Figure showing the median nerve passing between PTh and PTu. PTu is retracted medially to gain a better view.

1-Brachialis muscle : In our dissections we encountered a variation of the median nerve at the level of the brachialis in one of the upper limbs in which the nerve was separated from the brachial artery and passed through the antecubital fossa piercing the muscle. This anatomic variation was considered as a possible cause for entrapment (fig 2).

2-Ligament of Struther : We encountered this ligament in one of the upper limbs in which it was

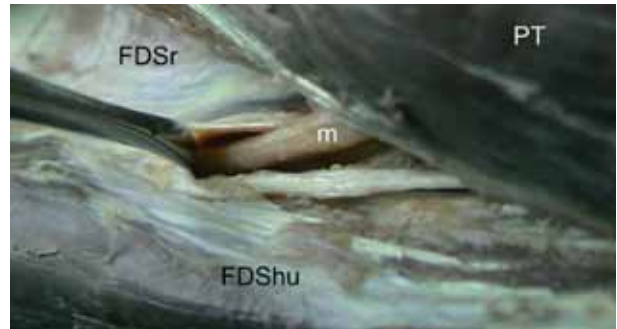


Fig. 6. — Right elbow, middle layer. m : median nerve, FDSr : radial head of flexor digitorum superficialis, FDSHu : humero-ulnar head of flexor digitorum superficialis, PT : pronator teres. Figure showing the median nerve passing through the fibrous tunnel between FDSr and FDSHu known as “Sublimis bridge”. PT retracted radially and sublimis bridge retracted distally to gain better view.

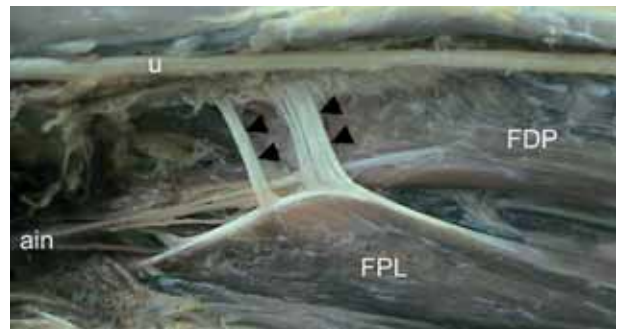


Fig. 7 — Right forearm, deep layer. FPL : flexor pollicis longus, FDP : flexor digitorum profundus, arrowheads : accessory head of the FPL seen as tendinous slips, ain : anterior interosseous nerve, u : ulnar nerve.

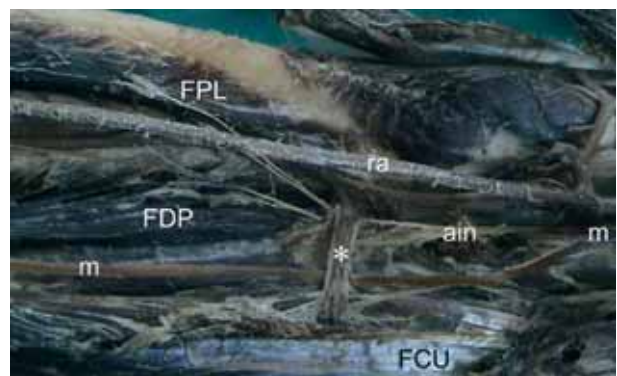


Fig. 8. — Right forearm, deep layer. m : median nerve, ain : anterior interosseous nerve, ra : radial artery, FPL : flexor pollicis longus, FDP : flexor digitorum profundus, FCU : flexor carpi ulnaris, asterisk : vascular band. Figure showing the vascular band crossing the median and anterior interosseous nerve.

present 4 cm above the elbow joint, coursing from the brachialis to the medial epicondyle to form a fibrous tunnel. In this cadaver the median nerve also had a different branching pattern (fig 3). After leaving the cubital fossa, the median nerve divides into multiple branches and finally two anterior interosseous nerves leave the main trunk and lie between deep flexor muscles, dividing the FDP into two parts. A few muscular branches also originate from the superficial branch.

3-Bicipital aponeurosis (lacertus fibrosus) : The bicipital aponeurosis originates from the biceps tendon and the fascia of the flexor-pronator mass (fig 4). Both the median nerve and brachial artery pass through the antecubital fossa underneath the bicipital aponeurosis (2, 5, 16, 42).

4-Heads of pronator teres : The median nerve passes between the humeral and ulnar heads of pronator teres as it leaves the cubital fossa (2, 5) (fig 5). In one of the upper limbs the pronator teres had only the humeral head and the median nerve was coursing between the humeral head and fibrofatty tissue underneath the muscle.

5-Sublimis bridge of flexor digitorum superficialis (FDS arch) : The median nerve usually passes under a fibrous band that forms between the humero-ulnar and radial head of flexor digitorum superficialis (formerly known as flexor digitorum sublimis) (2, 5, 42) (fig 6). In one of the upper limbs studied, the FDS did not have the radial head and the sublimis bridge failed to form.

6-Accessory head of flexor pollicis longus (Gantzer's muscle) : Gantzer's muscle is an accessory head of the FPL that usually originates from the medial epicondyle or the coronoid process and lies on the ulnar side of the FPL (1, 34). In our dissections we encountered Gantzer's muscle in 20% of the upper limbs (n = 6), however in one of the upper limbs its tendinous course was extremely different. It turned to the radial side and fused to the FPL just after its origin and it was markedly compressing the anterior interosseous nerve, especially when the forearm was in supination (fig 7).

7-Vascular structures : We encountered a vascular band in 33% of the upper limbs (n=10) crossing both the median nerve and anterior interosseous nerve anteriorly (fig 8).

DISCUSSION

Nerves of the upper extremity have considerable mobility throughout their length. Compression by adjacent structures may tether a nerve and restrict its mobility, thereby causing stretching in response to joint motion (7, 16).

The distribution of the median nerve in the arm is usually not subject to variations (28, 35, 43). Such variations of the nerve and adjacent structures may present clinically or may be observed at surgery, autopsy or cadaveric dissection. For a correct diagnosis of entrapment neuropathies, these variations must always be kept in mind.

The median nerve may be compressed above the elbow because of an accessory tendon which arises from the brachialis in 10% of the cases (13). According to some authors the muscle fibers which arise from the brachialis connect to some of the fibers of biceps brachii and end in the bicipital aponeurosis and compress the median nerve (5). On the other hand some authors advocate that the fibers originate from the brachialis muscle (13). Variations in the muscular or tendinous part of the brachialis may give rise to entrapment neuropathy. Normally, the median nerve courses in the groove between biceps brachii and brachialis (2, 5, 45). However, in our dissections we encountered a variation of the median nerve at the level of the brachialis in one of the upper limbs, in which the nerve separated from the brachial artery and passed through the antecubital fossa piercing the muscle (fig 1). This anatomic variation was considered a possible cause for entrapment.

The fibrous tunnel under Struther's ligament is usually present in humans proximal and anteromedial to the medial epicondyle (12, 16, 35). This ligament is sometimes present with a supracondylar process. The median nerve and brachial artery pass through this fibrous tunnel and may be compressed in it (8, 12, 17, 47, 48). In the presence of this structure, the median nerve has abnormal branching in the forearm (17). We encountered this ligament in one of the upper limbs in which it was present 4 cm above the elbow joint, arising from the brachialis and attached to the medial epicondyle, forming a fibrous tunnel. In this cadaver the median nerve had

a different branching pattern. After leaving the cubital fossa, PT and FDS, the median nerve divides into multiple branches and finally two anterior interosseous nerves leave the main trunk and they lie between deep flexor muscles dividing the FDP into two parts. Also some muscular branches originate from the superficial branch (fig 3).

The lacertus fibrosus (bicipital aponeurosis) (fig 4) takes origin from the biceps tendon and the fascia of the flexor-pronator mass (2, 5, 16, 42). This fibrous structure courses ulnarly and ends in the deep fascia of the forearm with a triangular shape. The lacertus fibrosus is an important structure because it protects the median nerve and brachial artery which pass underneath it. In some cases the biceps brachii ends in the bicipital aponeurosis (37, 41). This structure compresses the median nerve especially in the hyperflexed position of the elbow. The brachial artery also passes under the bicipital aponeurosis, but compression problems are uncommon because the lateral part of this structure under which the artery passes is wider (4, 6). A tunnel formed by the medial head of a 4-headed biceps brachii proximal to the bicipital aponeurosis, in which the median nerve and brachial artery pass, was reported as a variation (30). In another study, an accessory head of the biceps brachii ended in the ulnar head of the pronator teres and this head formed a tunnel for the median nerve and brachial artery (36).

The pronator syndrome is due to compression of the median nerve as it passes between the humeral and ulnar heads of the pronator teres (23). It has been shown that the median nerve passes between the two heads of pronator teres in more than 80% of the cases (fig 5) (2, 5, 29). Other causes of entrapment of the median nerve related to the pronator teres are that it may have a short or tendinous ulnar head, there may be a variation in the origin of the ulnar head, part of the ulnar head may arise from FDS, and the median nerve may also pierce the humeral head of pronator teres. According to these authors the ulnar head of the muscle may not be present in 22% of the cases, while the humeral head is always present (32). Also the median nerve may be compressed when the insertion of the humeral head of pronator teres is very proximal (9, 10). In

rare instances, a fibrous band originating from the humeral head may take the median nerve in it and pushes the nerve anterior to the medial epicondyle, causing entrapment neuropathy (18, 49). In some studies it has been shown that accessory fibers arising from brachialis, biceps brachii, Gantzer's muscle or FDS may cause entrapment neuropathy. They compress the nerve not directly but by narrowing the space through which they pass together with the nerve (10, 23, 33, 46). In one of the upper limbs dissected, the pronator teres had only the humeral head and the median nerve was passing between the humeral head and the fibrofatty tissue under the muscle.

The median nerve passes under the sublimis bridge that is formed by the radial and the humero-ulnar heads of the FDS (fig 6) (2, 5, 29, 42). Entrapment neuropathy of the median nerve frequently occurs in this region. A fibrous band arising from FDS to brachialis has been described, with the median nerve passing under the band, where it may be compressed (31). In 97.7% of the upper limbs FDS had two heads and the median nerve passed under the sublimis bridge but in one of the upper limbs the FDS did not have the radial head and the sublimis bridge failed to form.

The accessory head of flexor pollicis longus (Gantzer's muscle) has been implicated as one of the causes of anterior interosseous nerve compression in the proximal forearm (fig 7) (11, 15, 19, 24, 34). The incidence of Gantzer's muscle was reported to be between 45% and 74% (1, 9, 11, 19, 20, 21, 26, 27, 34, 44). These diverging figures might be due to the fact that the muscle is mostly fused with muscles of the superficial flexor group. Gantzer's muscle usually passes between the superficial branch of the median nerve and the anterior interosseous nerve; but rarely it passes superficial to both nerves (44). The most frequent sites of origin of the muscle that have been reported are the medial humeral epicondyle (1, 19, 27), a well-developed connecting fascia within the pronator teres and flexor muscles in the proximal forearm (21), FDS (20) and both the medial epicondyle and coronoïd process (11, 26). However, the most frequent site of the origin of the muscle has also been report-

ed to be the coronoid process in 87.5% (34). In the forearm the muscle ends in the ulnar part of flexor pollicis longus (1, 19) or ends in two tendinous slips, one of which connects to flexor pollicis longus, whereas the other courses to join the tendon of the flexor digitorum profundus to the index finger (34). In our dissections we encountered Gantzer's muscle in 20% of the upper limbs (n = 6) however in one of the upper limbs its tendinous course was extremely different from the literature (fig 7): it turned to the radial side and fused to the FPL just after its origin, and it was compressing the anterior interosseous nerve especially when the forearm was in supination.

Vascular variations in the forearm have been reported in the literature. The most frequent variations are reported at the bifurcation of the brachial artery and the collateral arteries (14, 40, 50). Rarely, branches of the median nerve can be compressed under vascular bridges (31, 40). Another structure that has not been defined clearly but is mentioned in textbooks (35) is a vascular band, which we encountered in 33% of our cadavers (n = 10). The band was between the anterior interosseous vessels (artery and veins) and radial vessels (artery and veins), crossing both the median nerve and the anterior interosseous nerve anteriorly; this band may cause entrapment neuropathy of the median nerve (fig 8).

The supracondylar process, which we did not encounter in our dissections, represents an anatomical variation that is almost always present in lemurs, but is found in only 0.3% to 2.7% of humans, especially in Caucasians (3, 12, 25). Solieri in 1929 was the first to describe the supracondylar process as the primary cause of an irritation of the median nerve in a patient with paraesthesia of the hand. The median nerve or very occasionally the ulnar nerve may be compressed in this fibro-osseous tunnel, creating the clinical symptoms of the "supracondylar process syndrome" (39). The bony formation starts from a large base, about 5-7 cm proximal to the medial epicondyle on the anteromedial aspect of the distal humerus and is directed distally like a beak (38). It connects to the medial epicondyle by a fibrous band known as Struther's ligament, previously described.

In this study, we want to survey all of the possible anatomic regions related to entrapment neuropathy of the median nerve to facilitate diagnosis and treatment. According to our dissections and to articles in the literature, the median nerve may be compressed by seven different structures from the upper arm to the carpal tunnel (fig 1).

In general, radiographic information is of limited value in the diagnosis of upper extremity compression neuropathies. However, plain radiographs in two orthogonal planes should be obtained to rule out possible bony causes of nerve dysfunction (16). Magnetic resonance imaging and computed tomography seldom have a role in the diagnosis of these conditions. Electrodiagnostic testing remains the diagnostic gold standard, yet it entails a number of pitfalls and is highly operator dependent. For this reason clinicians must be familiar with the anatomic structures that may cause this pathology, as these neuropathies can easily be treated with release of the offending structures, once they have been identified.

REFERENCES

1. **Al-Qattan MM.** Gantzer's muscle : An anatomical study of the accessory head of the flexor pollicis longus muscle. *J Hand Surg* 1996 ; 21-B : 269-270.
2. **Arinci K, Elhan A.** *Anatomi*, 2nd edition, Güneş Kitabevi, Ankara, 2001, pp 162-171.
3. **Barnard BL, McCoy MS.** The supracondyloid process of the humerus. *J Bone Joint Surg* 1946 ; 28-A : 845-850.
4. **Bassett FH 3rd, Spinner RJ, Schroeter TA.** Brachial artery compression by the lacertus fibrosus. *Clin Orthop* 1994 ; 307 : 110-116.
5. **Berry MM, Standring SM, Bannister LH.** Nervous system. In Williams PL, Bannister LH, Berry MM *et al* (eds). *Gray's Anatomy*. 38th edition. Churchill Livingstone, London, 1995, pp 1270-1272.
6. **Biemans RG.** Brachial artery entrapment syndrome. Intermittent arterial compression as a result of muscular hypertrophy. *J Cardiovasc Surg (Torino)* 1977 ; 18 : 367-371.
7. **Birch R, Bonney G, Parry CBW.** *Surgical Disorders of the Peripheral Nerves*. Churchill Livingstone, Edinburgh, London, 1998, pp 282-285.
8. **Crotti FM, Mangiagalli EP, Rampini P.** Supracondyloid process and anomalous insertion of pronator teres as sources of median nerve neuralgia. *J Neurosurg Sci* 1981 ; 25 : 41-44.

9. **Dellon AL.** Musculotendinous variations about the medial humeral epicondyle. *J Hand Surg* 1986 ; 11-B : 175-181.
10. **Dellon AL, Mackinnon SE.** Musculoaponeurotic variations along the course of the median nerve in the proximal forearm. *J Hand Surg* 1987 ; 12-B : 359-363.
11. **Dykes J, Anson BJ.** The accessory tendon of the flexor pollicis longus muscle. *Anat Rec* 1944 ; 90 : 83- 89.
12. **Elhan A, Güngör T.** *Processus Supracondylaris konusun-da inceleme.* Ankara Üniversitesi Tıp Fakültesi Mecmuası 1978, cilt : 31, sayı : IV, 1381-1392.
13. **Flory PJ, Berger A.** The Accessory Brachial Tendon - a rare cause of pronator teres syndrome. *Handchir Mikrochir Plast Chir* 1985 ; 17 : 270-272.
14. **Funk GF, Valentino J, McCulloch TM et al.** Anomalies of forearm vascular anatomy encountered during elevation of the radial forearm flap. *Head Neck* 1995 ; 17 : 284-292.
15. **Gardner-Thorpe C.** Anterior interosseous nerve palsy : Spontaneous recovery in two patients. *J Neurol Neurosurg Psychiatry* 1974, 37 : 1146-1150.
16. **Green DP, Hotchkiss RN, Pederson WC.** *Green's Operative Hand Surgery.* 4th edition. Philadelphia, Churchill Livingstone, 1999, vol2 : pp1417-1422.
17. **Gunther SF, DiPasquale D, Martin R.** Struther's ligament and associated median nerve variations in a cadaveric specimen. *Yale J Biol Med* 1993 ; 66 : 203-208.
18. **Gunther SF, DiPasquale D, Martin R.** The internal anatomy of the median nerve in the region of the elbow. *J Hand Surg* 1992 ; 17-A : 648-656.
19. **Hemmady MV, Subramanya AV, Mehta IM.** Occasional head of flexor pollicis longus muscle : A study of its morphology and clinical significance. *J Postgrad Med* 1993 ; 39 : 14-16.
20. **Jones M, Abrahams PH, Sañudo JR, Campillo M.** Incidence and morphology of accessory heads of flexor pollicis longus and flexor digitorum profundus (Gantzer's muscles). *J Anat* 1997 ; 191 : 451-455.
21. **Kida M.** The morphology of Gantzer's muscle, with special reference to the morphogenesis of the flexor digitorum superficialis. *Kaibogaku Zasshi* 1998 ; 63 : 539-546.
22. **Kothari MJ.** Hospital Physician. *Neurology Board review Manual Neurology* 2001 ; 6 : 1-15.
23. **Lacey SH, Soldatis JJ.** Bilateral pronator syndrome associated with anomalous heads of the pronator teres muscle : a case report. *J Hand Surg* 1993 ; 18-A : 349-351.
24. **Lahey MD, Aulicino PL.** Anomalous muscles associated with compression neuropathies. *Orthop Rev* 1986 ; 15 : 199-208.
25. **Lubahn JD, Cermak BM.** Uncommon nerve compression syndromes of the upper extremity. *J Am Acad Orthop Surg* 1998 ; 6 : 378-386.
26. **Malhotra VK, Sing NP, Tewari SP.** The accessory head of the flexor pollicis longus muscle and its nerve supply. *Anat Anz* 1982 ; 151 : 503-505.
27. **Mangini U.** Flexor pollicis longus muscle. *J Bone Joint Surg* 1960 ; 42-A : 467-470.
28. **McNamara B.** Clinical anatomy of the median nerve. *ACNR* 2003 ; 2 : 19-20.
29. **Moore KL, Dalley AF.** *Clinically Oriented Anatomy.* 4th edition. Lippincott Williams and Wilkins, Montreal, 1999, 711-717.
30. **Nakatani T, Tanaka S, Mizukami S.** Bilateral four-headed biceps brachii muscles : the median nerve and brachial artery passing through a tunnel formed by a muscle slip from the accessory head. *Clin Anat* 1998 ; 11 : 209-212.
31. **Neal KM, Rayan GM.** Anterior interosseous nerve syndrome : a case report. *J Okla State Med Assoc* 2002 ; 95 : 253-256.
32. **Nebot-Cegarra J, Perez-Berrueto J, Reina de la Torre F.** Variations of the pronator teres muscle : predispositional role to median nerve entrapment. *Arch Anat Histol Embryol* 1991-1992 ; 74 : 35-45.
33. **Nebot-Cegarra J, Reina-de la Torre F, Perez-Berrueto J.** Accessory fasciculi of the human pronator teres muscle : incidence, morphological characteristics and relation to the median nerve. *Anat Anz* 1994 ; 176 : 223-227.
34. **Oh CS, Chung IH, Koh KS.** Anatomical study of the accessory head of the flexor pollicis longus and the anterior interosseous nerve in the asians. *Clin Anat* 2000 ; 13 : 434-438.
35. **Omer GE, Spinner M, Van Beek AL.** *Management of Peripheral Nerve Problems.* 2nd edition. Philadelphia, W.B. Saunders Company, 1994, 511-516.
36. **Ozan H, Atasever A, Sinav A et al.** An unusual insertion of accessory biceps brachii muscle. *Kaibogaku Zasshi* 1997 ; 72 : 515-519.
37. **Pećina MM, Krmpotić-Nemanić J, Markiewitz AD.** *Tunnel syndromes.* Peripheral nerve compression syndromes, 3rd ed. Boca Raton, CRC Press, 2001, 85-88.
38. **Pecina M, Boric I, Anticevic D.** Intraoperatively proven anomalous Struther's ligament diagnosed by MRI. *Skeletal Radiol* 2002 ; 31 : 532-535.
39. **Pick TP, Howden R (eds).** *Gray's Anatomy, Descriptive and Surgical.* 15th Edition. Finland, Chancellor Pres, 1994, 752-753.
40. **Proudman TW, Menz PJ.** An anomaly of the median artery associated with the anterior interosseous nerve syndrome. *J Hand Surg* 1992 ; 17 : 507-509.
41. **Rodriguez-Vazquez JF, Merida-Velasco JR, Jimenez-Collado J.** Unusual variation of a third head of the biceps brachii muscle. *Anat Anz* 1999 ; 181 : 573-575.
42. **Rosse C, Gaddum-Rosse P.** *Hollinshead's Textbook of Anatomy.* 5th edition. Philadelphia, Lippincott-Raven, 1997, 255.
43. **Saeed M, Rufai AA.** Median and musculocutaneous nerves : Variant formation and Distribution. *Clin Anat* 2003 ; 16 : 453-457.
44. **Shirali S, Hanson M, Branovacki G, Gonzalez M.** The flexor pollicis longus and its relation to the anterior and

- posterior interosseous nerves. *J Hand Surg* 1998 ; 23 : 170-172.
- 45. Sakul BU, Türkaslan A.** Variations of the median and musculocutaneous nerves. *J Ankara Med School* 1991 ; 13 : 259-262.
- 46. Tağil SM, Uz A, Karahan ST.** Dört başlı m. pronator teres olgusu. *Ankara Üniversitesi Tıp Fakültesi Mecmuası* 2002 ; 55 : 93-96.
- 47. Talha H, Enon B, Chevalier JM et al.** Brachial artery entrapment : compression by the supracondylar process. *Ann Vasc Surg* 1987 ; 1 : 479-482.
- 48. Thomsen PB.** Processus supracondyloidea humeri with concomitant compression of the median nerve and the ulnar nerve. *Acta Orthop Scand* 1977 ; 48 : 391-393.
- 49. Tulwa N, Limb D, Brown RF.** Median nerve compression within the humeral head of pronator teres. *J Hand Surg* 1994 ; 19 : 709-710.
- 50. Wozniak W, Bruska M, Markowski M.** A case of high origin of the common interosseous artery. *Folia Morphol (Warsz)* 1998 ; 57 : 389-391.