



Anconeus muscle transposition for failed surgical treatment of tennis elbow : preliminary results

Ilse DEGREEF, ANTOON VAN RAEBROECKX, LUC DE SMET

From the Orthopaedic Department, Pellenberg University Hospital, Lubbeek, Belgium

The authors conducted a retrospective study on their first 10 patients treated with an anconeus muscle transposition after failed surgery for chronic lateral epicondylitis. All patients had initially been treated conservatively, and subsequently with a classical or percutaneous release of the common extensor origin. The secondary procedure involved wide excision of the common extensor origin, débridement of the lateral epicondyle and rotation of the anconeus muscle into the defect. At follow-up the results were excellent in 3 patients, good in 4 and poor in 3. This appears as a valid salvage procedure for lateral epicondylitis, since the operation was performed as a second or even a third approach.

INTRODUCTION

Many surgical procedures for tennis elbow are currently advocated. The classical "release and slide" concept was originally described by Hohmann in 1933.

Variations were described over the next years, including partial resection of the epicondyle, partial resection of the annular ligament, partial excision of the synovium, drilling of the lateral epicondyle, percutaneous and endoscopic release, denervation, and distal lengthening of tendons. All these procedures were said to have a success rate between 80 and 97%. In the past, revision surgery consisted of a new, more extensive débridement with excision of scar tissue.

In 1998 a new procedure was published by Almquist (1). Using the anconeus muscle as a vascularized flap, a more extensive débridement of the common extensor tendon became possible. The results were promising, as well in primary as in secondary cases. The authors used this method only as a salvage procedure.

MATERIAL AND METHODS

There were 10 patients, 6 women and 4 men. Their mean age was 44 years. All had been treated with a percutaneous or a mini open release. All of them still experienced pain ; tenderness was localized over the radial epicondyle. A local infiltration with cortisone and lidocaine had to resolve their pain, to make them candidates for revision surgery. An interval of 6 months was required before revision was undertaken.

The anconeus muscle has 3 arterial pedicles (fig 1) :
1. The main arterial pedicle is the medial collateral artery (mca). It originates from the deep brachial artery

-
- Ilse Degreef, MD, Orthopaedic Surgeon.
 - Antoon Van Raebroeckx, MD, Resident.
 - Luc De Smet, MD, PhD, Orthopaedic Surgeon, Surgeon-in-Chief.

Department of Orthopaedic Surgery, UZ Pellenberg, Lubbeek, Belgium.

Correspondence : L. De Smet, UZ Pellenberg, Weligerveld 1, B-3212 Pellenberg (Lubbeek), Belgium.
E-mail : luc.desmet@uz.kuleuven.ac.be.

© 2005, Acta Orthopædica Belgica.

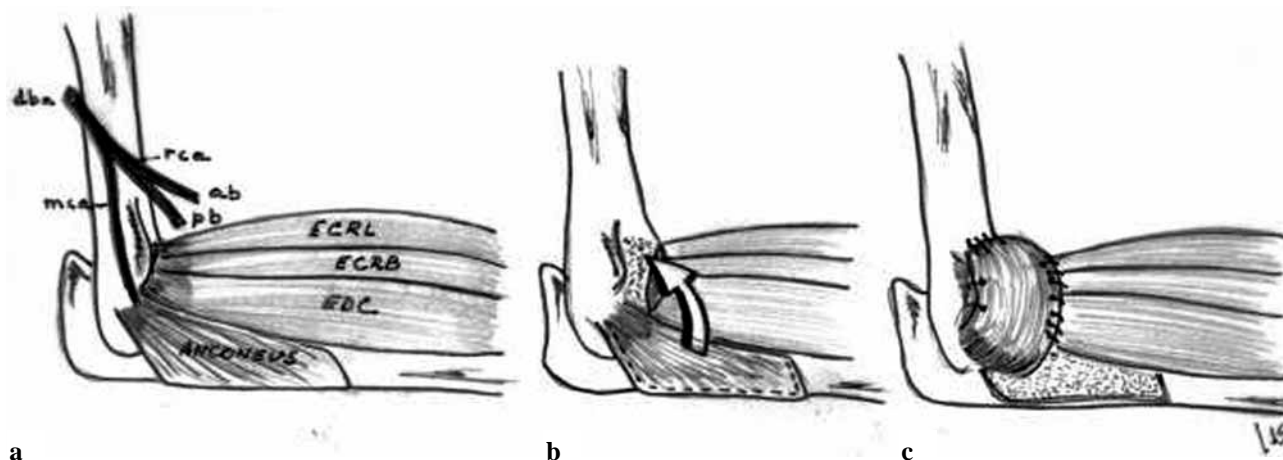


Fig. 1. — Operative technique

a) anatomy : dba : deep brachial artery – mca : medial collateral artery – rca : radial collateral artery (ab : anterior branch / pb : posterior branch) – ECRL : extensor carpi radialis longus muscle – ECRB : extensor carpi radialis brevis muscle – EDC : extensor digitorum communis muscle ; b) after release of the common extensor origin, the anconeus muscle is detached from the ulna ; c) rotated muscle flap in place.

(dba). It travels to the muscle together with the nerve to the anconeus muscle (a motor branch from the radial nerve) between the lateral and medial heads of the triceps muscle. 2. The posterior branch (pb) of the radial collateral artery (rca) is a terminal branch of the deep brachial artery (dba). It provides the superficial part of the anconeus muscle. 3. The recurrent posterior interosseous artery (not reproduced in fig 1) originates either from the ulnar artery or from the posterior interosseous artery. It enters the muscle from distally in a retrograde direction on its deep surface. It is ligated to facilitate rotation of the muscle.

As described by Almquist (1) (fig 1) a 5-cm lateral incision was made over the epicondyle. Dissection was performed subcutaneously, defining the anconeus muscle origin on the posterior border of the ulna and its insertion on the lateral epicondyle. The superficial aponeurosis was divided longitudinally, exposing the deep structures. A wide en-bloc excision of the common extensor tendon origin was undertaken, proceeding anteriorly to the fleshy border of the extensor carpi radialis longus muscle, distally to the fleshy portion of the extensor carpi radialis brevis and extensor digitorum communis muscles at the level of the radial head, posteriorly to the thin, firm aponeurosis of the extensor carpi ulnaris tendon, and proximally to the lateral epicondyle. This excision involved approximately 4 cm² of aponeurosis. If a sclerotic epicondyle was present, it was rongeuired to

cancellous bone. The anconeus muscle was mobilised by releasing its origin on the ulna distally and dissecting cautiously proximally. Distally, a small artery (the recurrent posterior interosseous artery, originating from the ulnar artery or from the posterior interosseous artery) parallel to and running on the surface of the ulna deep to the anconeus, was encountered and ligated. The anconeus fibers were elevated from the ulna until the neurovascular bundle was reached : the medial collateral artery (mca) originating from the deep brachial artery (dba), and the nerve to the anconeus, originating from the radial nerve just proximal and posterior to the annular ligament, between the radius and ulna. The posterior margin of the anconeus was further mobilized, producing a 5 to 7 cm² structure which could be mobilised ; this was rotated into the defect created by the excision of the common extensor origin. The anconeus muscle was finally sutured into place with absorbable mattress sutures. The tourniquet was released, and the vascularity of the muscle was ascertained. Closure of the approach was made in layers. Immediate mobilisation was permitted postoperatively.

The criteria of Roles and Maudsley (4) were used to evaluate the outcome : Excellent : no pain, full movement, full activity ; Good : occasional discomfort, full movement and full activities ; Fair : some discomfort after prolonged activity ; Poor : pain limiting activities. The minimum follow-up was one year.

RESULTS

Return to work varied from 6 weeks to change of job because of insufficient improvement after the revision surgery. There were 3 excellent, 4 good and 3 poor results. One superficial wound infection was noted. Donor site related weakness or instability were not encountered.

DISCUSSION

Pankovich in 1977 (3) described the anconeus flap as a means to facilitate the approach to the radiocapitellar area, without using it however for transposition and coverage.

Up to now the anconeus transfer has been described only twice (1, 5) as a useful option for tennis elbow treatment. In 1998 Almquist (1) used anconeus muscle transposition in 31 patients as a primary procedure and in 14 patients as a revision procedure. In 1999 Schmidt (5) described the anatomy of the anconeus flap, and reported 6 salvage operations for failed tennis elbow surgery, with the

anconeus flap. Only one other large recent series is dealing with the surgical treatment of failed tennis elbow surgery : Organ *et al* (2) operated on 34 patients. A simple re-do débridement was done, without anconeus transposition. They obtained 83% of good and excellent results .

REFERENCES

1. **Almquist EE, Necking L, Bach AW.** Epicondylar resection with anconeus muscle transfer for chronic lateral epicondylitis. *J Hand Surg* 1998 ; 23-A : 723-731.
2. **Organ SW, Nirschl RP, Kraushaar BS, Guidi EJ.** Salvage surgery for lateral tennis elbow. *Am J Sports Med* 1997 ; 25 : 746-750.
3. **Pankovich AM.** Anconeus approach to the elbow and the proximal part of the radius and ulna. *J Bone Joint Surg* 1977 ; 59-A : 124-126.
4. **Roles NC, Maudsley RH.** Radial tunnel syndrome. Resistant tennis elbow as a nerve entrapment. *J Bone Joint Surg* 1972 ; 54B : 499-508.
5. **Schmidt CC, Kohut GN, Greenberg JA, Kann SE, Idler RS, Kiefhaber TR.** The anconeus muscle flap : its anatomy and clinical application. *J Hand Surg* 1999 ; 24-A : 359-369.