



Medial patellofemoral ligament reconstruction for recurrent patellar instability

Yoshinori MIKASHIMA, Masashi KIMURA, Yasukazu KOBAYASHI, Hiroto ASAGUMO, Taisuke TOMATSU

Department of Orthopaedic Surgery, Gunma Sports Medicine Research Center, Gunma, Japan

The purpose of this study was to determine the value of reconstruction of the medial patellofemoral ligament (MPFL) in the treatment of recurrent patellar dislocation and subluxation.

We retrospectively reviewed 40 randomised patients with recurrent patellar dislocation or subluxation, who had undergone realignment surgery from July 1999 to December 2001. Group E consisted of 20 patients who had undergone an Elmslie-Trillat procedure. In Group M, also consisting of 20 patients, the Elmslie-Trillat procedure was combined with reconstruction of the MPFL. Pre and postoperative data were collected and compared.

At follow-up after 2 years, the apprehension sign remained positive in 6 knees of Group E, but in none of Group M. On a stress skyline radiograph, stability was significantly better in Group M than in Group E.

Based on these findings, it appears that reconstruction of the MPFL is a useful addition to the treatment of recurrent patellar dislocation and subluxation.

INTRODUCTION

More than 100 different surgical techniques for the treatment of recurrent patellar dislocation or subluxation have been described during the past 100 years (4, 6, 9, 11). Surgical methods can be classified as proximal realignment, distal realignment, proximal and distal realignment, lateral retinacular release, and medial retinacular plication (2, 10).

Campbell developed the Campbell procedure as a method of proximal realignment and reported that it was useful in patients who have attenuated or relaxed medial capsular structures, normal quadriceps alignment, minimal or no significant degenerative changes, and rare recurrence of patellar dislocation (2). A technique of quadricepsplasty (distal and lateral transfer of the insertion of the vastus medialis muscle combined with lateral retinacular release) was also reported by Madigan *et al* as a method of proximal realignment (11). Insall and Hughston both described a procedure for proximal realignment (2). The procedures designed by Roux and Goldthwait, Galeazzi, Hauser, and Elmslie and Trillat (2) are typical distal realignment procedures.

■ Yoshinori Mikashima, MD, Orthopaedic Registrar.

■ Masashi Kimura, MD, Orthopaedic Surgeon, Chairman.

■ Yasukazu Kobayashi, MD, Consultant Orthopaedic Surgeon.

■ Hiroto Asagumo, MD, Consultant Orthopaedic Surgeon.

Department of Orthopaedic Surgery, Gunma Sports Medicine Research Center, Gunma, Japan.

■ Taisuke Tomatsu, MD, Professor of Orthopaedics.

Department of Orthopaedic Surgery, Institute of Rheumatology, Tokyo Women's Medical University, Kawata chou, Shinjuku, Tokyo, Japan.

Correspondence : Yoshinori Mikashima, T 198-0021, Takagi Hospital, Imadera 5-18-19, Oumz City, Tokyo, Japan. E-mail : mikashima@mwb.biglobe.net.jp

© 2004, Acta Orthopædica Belgica.

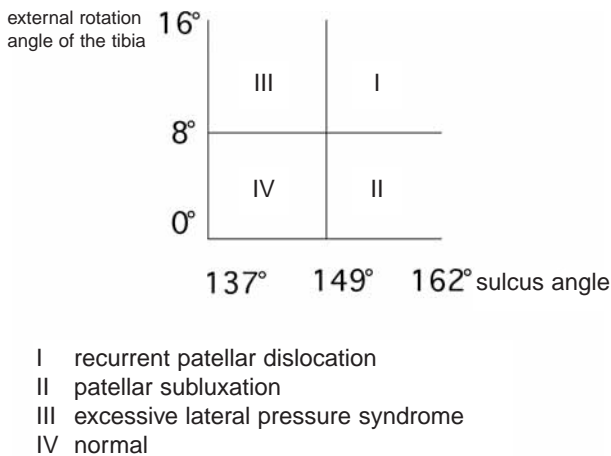


Fig. 1. — Tanaka's classification of our patients

Although most authors report that the results are usually satisfactory and recurrence is uncommon, various problems remain. These include recurrence of dislocation, persistent patellofemoral instability without redislocation, patellofemoral osteoarthritis, loss of flexion, and medial subluxation (1, 8, 10).

Recently, the medial patellofemoral ligament (MPFL) has been recognised as an important stabiliser of the patella, preventing lateral dislocation.

In this study, we aimed at evaluating the value of MPFL reconstruction for the treatment of recurrent patellar dislocation.

PATIENTS AND METHODS

We retrospectively reviewed 40 patients with recurrent patellar dislocation, with a minimum follow-up of two years after surgery. We classified the patients into 4 groups according to sulcus angle and tibial external rotation angle (fig 1 : Tanaka's classification (15)). Type I includes knees with a large sulcus angle and a large external rotation angle of the tibia. Type II includes knees with a large sulcus angle and a small external rotation angle of the tibia. Type III includes knees with a small sulcus angle and a large external rotation angle of the tibia. Type IV includes knees with a small sulcus angle and a small external rotation angle of the tibia. We performed distal realignment mainly for type I, proximal realignment mainly for type II. We randomly selected 20 patients (20 knees ; group E) who had undergone an

Elmslie-Trillat distal realignment, and 20 patients (20 knees ; group M) who had undergone MPFL reconstruction associated with an Elmslie-Trillat distal realignment. In group E, there were 5 men and 15 women with a mean age at surgery of 26.4 ± 9.7 years (range : 14 to 45 years), with a mean follow-up of 41.0 ± 8.7 months (range : 28 to 52 months). In group M, there were 6 men and 14 women with a mean age at surgery of 26.0 ± 10.0 years (range : 16 to 55 years), and a mean follow-up of 31.7 ± 10.5 months (range : 24 to 44). All patients were Japanese. Generalised joint laxity was present in 7 patients of group E, and in 8 patients of group M.

The mean sulcus angle on skyline view was $145.2^\circ \pm 6.1^\circ$ (range, 137° to 159°) in group E and $145.7^\circ \pm 7.3^\circ$ (range, 138° to 162°) in group M. The mean external rotation angle of the tibia on axial computed tomography (CT) was $10.1^\circ \pm 3.1^\circ$ (range : 4° to 14°) in group E and $9.5^\circ \pm 4.6^\circ$ (range : 0° to 18°) in group M.

Two year after surgery both groups were evaluated, and findings were compared. Postoperative assessment included postoperative complications, persisting symptoms mainly patella apprehension, quadriceps and hamstrings strength (Cybex®), range of movement, evaluation according to Hall *et al* (6), and the pre- and postoperative Kujala (16) score including a variety of symptoms and signs of patellar instability with a maximal score of 100 points. Radiographs and axial CT scans were obtained.

Radiological assessment included a standard Merchant view and a skyline view in 30° flexion with 2 kgf stress. We used Merchant's view to measure the tilting angles and lateral shift ratios. The lateral and medial stress shift ratios (14) were obtained from stress radiographs (fig 2 a, b, fig 3). The findings were compared to those made on stress radiographs in 60 normal knees (group N : 30 normal knees of males and 30 normal knees of females), and the non-operated knees in groups E and M. An axial CT was also obtained to measure the patellar tilt and patellar shift (9) (fig 4). We used Student's t-test for statistical comparison.

RESULTS

Apprehension sign

The apprehension sign remained positive in 6 knees in group E, whereas it was negative in all knees in group M.

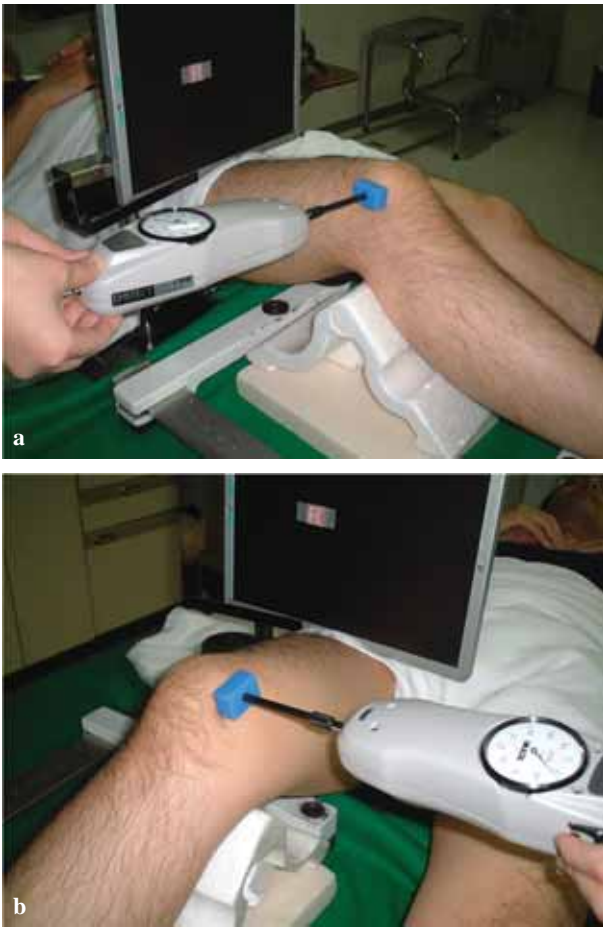

Fig. 2. — **a.** Skyline view in 30° flexion with 2 kg stress to measure medial stress shift ratio ; **b.** Skyline view in 30° flexion with 2 kg stress to measure lateral stress shift ratio.

Restoration of quadriceps and hamstrings

The mean power of the quadriceps postoperatively compared with that in the untreated knee was 66.8% ± 7.2% in group E and 75.3% ± 23.3% in group M. The mean power of the hamstrings was 81.7% ± 13.8% in group E, 73.3% ± 26.7% in group M. There was no significant difference between the two groups (quadriceps : p = 0.45, hamstrings : p = 0.09).

Range of movement

All patients in both groups achieved a full range of movement. The interval until patients acquired

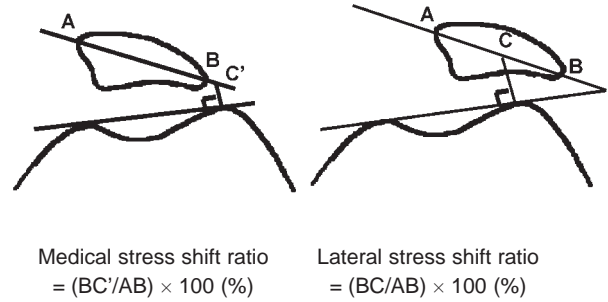


Fig. 3. — Medial and lateral stress shift ratios

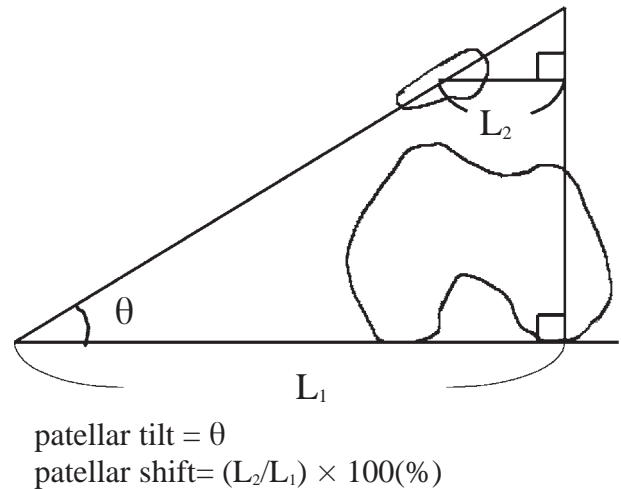


Fig. 4. — Patellar tilt and patellar shift on CT

full range of movement was 2.1 ± 0.6 months (range : 1.5 to 3.0) in group M, versus 3.0 ± 1.3 months (range : 1.5 to 5.0) in group E. The patients in group M seemed to take longer to acquire a full range of movement than those in group E.

Assessment by the method proposed by Hall et al and Kujala score

On the assessment following Hall *et al*, there were 6 knees assessed as excellent, 13 knees as good, 1 knee as fair, and 0 knees as poor in group E, while 13 knees were assessed as excellent,

Table I. — Assessment on radiographs and computed tomography

	Group E (n = 11)	Group M (n = 14)
X ray : tilting angle before surgery	16.5° ± 5.3°	16.9° ± 7.0°
after surgery	10.1° ± 4.9°	8.5° ± 4.1°
X ray : lateral shift ratio before surgery	21.0% ± 6.3%	21.2° ± 11.4%
after surgery	12.3% ± 3.1%	9.2° ± 3.5%
CT patellar tilt before surgery	27.3° ± 5.3°	28.3° ± 7.8°
after surgery	13.2° ± 5.6°	10.6° ± 3.1°
CT patellar shift before surgery	23.2% ± 5.9%	29.5% ± 12.3%
after surgery	9.1% ± 6.4%	9.1% ± 3.2%

7 knees as good, and 0 knees as either fair or poor in group M.

The mean Kujala score was 79.6 ± 21.7 points (range : 56 to 100) in group E, 89.0 ± 13.6 points (range : 63 to 100) in group M, while the scores before surgery were 30.5 ± 5.4 points (range : 21 to 36) in group E and 30.1 ± 7.5 points (range : 19 to 38) in group M. There was no significant difference between the two groups (p = 0.08). One knee in group E and three knees in group M scored 100 points.

Radiological assessment (table I, II)

On radiological assessment, the mean tilting angle two years after surgery was 10.1° ± 4.9° in group E, 8.5° ± 4.1° in group M, while the tilting angle before surgery was 16.5° ± 5.3° in group E, and 16.9° ± 7.0° in group M. There was no significant

difference between the two groups (p = 0.48). The mean lateral shift ratio after surgery was 12.3% ± 3.1% in group E, 9.2% ± 3.5% in group M ; the corresponding figures before surgery were 21.0% ± 6.3% in group E, and 21.2% ± 11.4% in group M. There was no significant difference between the two groups (p = 0.11).

The mean medial stress shift ratio in group N was 8.9% ± 3.8% [men : -9.7% ± 3.8%, women : -7.9% ± 3.7%]. The corresponding values were 9.4% ± 4.9% in group E (surgically treated side), and 8.1% ± 8.2% in group M (surgically treated side). There was no significant difference between group E (surgically treated side) and group M (surgically treated side) in the mean medial stress shift ratio (p = 0.27). The corresponding values were 11.4% ± 6.0% in group E (untreated side) and 3.6% ± 12.1% in group M (untreated side). There was no significant difference between the surgically treated side and untreated side in either group (group E : p = 0.28, group M : p = 0.06).

The mean lateral stress shift ratio in group N was 15.5% ± 5.5% [men ; 14.4% ± 4.5%, women 15.7% ± 6.7%]. The corresponding value in group E (surgically treated side) was 31.5% ± 9.7%, while that in group M (surgically treated side) was 14.5% ± 5.3%. There was a significant difference between group E (surgically treated side) and group M (surgically treated side) in the mean lateral stress shift ratio (p = 0.03). There was no significant difference between group M (surgically treated side) and group N (p = 0.17). In group M, there was a significant difference between the surgically treated side and the untreated side in the mean lateral stress shift ratio (p = 0.01), but there was no significant difference in group E (p = 0.21).

Table II. — Assessment on stress radiograph

	group N (n = 30) men	group N (n = 30) women	group N (n = 60) men and women	group E (n = 11) untreated side	group M (n = 14) untreated side	group E (n = 11) surgically treated side	group M (n = 14) surgically treated side
stress radiograph : medial stress shift ratio	-9.7% ± 3.8%	-7.9% ± 3.7%	-8.9% ± 3.8%	11.4% ± 6.0%	3.6% ± 2.1%	9.4% ± 4.9%	8.1% ± 8.2%
stress radiograph : lateral stress shift ratio	14.4% ± 4.5%	15.7% ± 6.7%	15.0% ± 5.5%	33.6% ± 6.8%	32.2% ± 10.1%	31.5% ± 9.7%	14.5% ± 5.3%

Assessment on axial CT (table I)

The mean patellar tilt two years after surgery was $13.2^\circ \pm 5.6^\circ$ in group E and $10.6^\circ \pm 3.1^\circ$ in group M, while that before surgery was $27.3^\circ \pm 5.3^\circ$ in group E and $28.3^\circ \pm 7.8^\circ$ in group M. There was no significant difference in either group ($p = 0.47$). The mean patellar shift after surgery was $9.1\% \pm 6.4\%$ in group E and $9.1\% \pm 3.2\%$ in group M, while that before surgery was $23.2\% \pm 5.9\%$ in group E and $29.5\% \pm 12.3\%$ in group M. There was no significant difference in either group ($p = 0.66$).

Postoperative complications

No postoperative complication were noted in either group.

DISCUSSION

Although more than 100 different surgical techniques for the treatment of patellar instability have been described over the past 100 years, various problems continue to be raised. Recently, the medial patellofemoral ligament (MPFL) has been recognised as an important stabiliser of the patella, preventing lateral dislocation. The MPFL extends from the superior two-thirds of the medial patellar margin to an insertion distal to the adductor tubercle and proximal to the posterior aspect of the femoral attachment of the medial collateral ligament (MCL), with superficial fibres extending to the posterior capsule of the knee (13). Since the 1990s, the importance of the MPFL has been gradually recognised. Based on recent biomechanical studies, the MPFL is accepted as the primary restraint among the medial patellar stabilisers (3, 5, 7). Conlan *et al* (3) reported that the MPFL provided 53% of the total medial restraining force. Hautamaa *et al* (7) and Desio *et al* (5) reported 55% and 60%, respectively. Nomura *et al* (13) reported that none of 49 knees with recurrent dislocation of the patella had a normal MPFL. In that report, 9 knees showed loose femoral attachment, 29 knees showed scar tissue formation or abnormal scar branch formation, 11 knees had absent MPFL, among the 49 knees in total.

We initially used the Elmslie-Trillat technique for distal realignment, but hypermobility of the patella was not fully corrected in some patients, who complained of persistent patella apprehension (6 patients). Therefore, since January 2001 we added reconstruction of the MPFL to the Elmslie-Trillat technique. Not one patient in this group had persistent patella apprehension.

There were no significant differences in tilting angles or lateral shift ratios on radiographs, medial stress shift ratios on stress films or patellar tilt or patellar shift on axial CT. However, lateral stability on the stress films in group M (surgically treated side) was significantly better than in group E (surgically treated side). In group M, stability of the surgically treated side was significantly better than on the untreated side, while there was no significant difference in group E. There was no significant difference between group M and group N regarding lateral stability.

We concluded that reconstruction of the MPFL is a useful adjunction to the treatment of recurrent patellar dislocation.

Many aspects of the reconstruction of the MPFL remain to be further examined such as tension, position, and location of fixation of the reconstructed MPFL. We should also investigate the material (autogenous tendon or artificial ligament), the volume and length of the reconstructed MPFL, as well as the laxity and resistance to rupture of the reconstructed MPFL.

REFERENCES

1. Aichroth PM, Al-Duri Z. Dislocation and subluxation of the patella : an overview. In : Aichroth PM, Al-Duri Z (eds). *Knee Surgery*. Martin Dunitz, London. 1992 ; pp 354-379.
2. Barney L, Freeman I. Recurrent dislocation. In : *Campbell's Operative Orthopaedics*. Seventh edition, Mosby, Philadelphia 1987 ; 52 : pp 2173-2184.
3. Conlan T, Gaeth WP Jr, Lemons JE. Evaluation of the medial soft-tissue restraints of the extensor mechanism of the knee. *J Bone Joint Surg* 1993 ; 75-A : 682-693.
4. Deie M, Ochi M, Yasumoto M *et al*. Reconstruction of the medial patellofemoral ligament for the treatment of habitual or recurrent dislocation of the patella in children. *J Bone Joint Surg* 2003 ; 85-B : 887-890.

5. **Desio DS, Burk RT, Bachus KN.** Soft tissue restraint to lateral patellar translation in human knee. *Am J Sports Med* 1998 ; 26 : 59-65.
6. **Hall JE, Micheli LJ, McManama GB.** Semitendinosus tenodesis for recurrent subluxation or dislocation of the patella. *Clin Orthop* 1979 ; 144 : 31-35.
7. **Hautamaa PV, Fithian DC, Kaufmann KR et al.** Medial soft tissue restraints in lateral patellar instability and repair. *Clin Orthop* 1998 ; 349 : 174-182.
8. **Hughston JC, Deese M.** Medial subluxation of the patella as a complication of lateral retinacular release. *Am J Sports Med* 1998 ; 16 : 383-388.
9. **Inoue M, Shino K, Maeda A et al.** Computed tomographic evaluation of realignment surgery for patellar subluxation. *Seikeisaigakeka* (in Japanese) 1994 ; 37 : 43-47.
10. **Insall JN.** Disorders of the patella. In : Insall JN (ed). *Surgery of the Knee*. Churchill Livingstone, New York, 1984, pp 191-260.
11. **Madigan R, Wissinger HA, Donaldson WF.** Preliminary experience with a method of quadricepsplasty in recurrent subluxation of the patella. *J Bone Joint Surg* 1975 ; 57-A : 600.
12. **Nomura E, Inoue M.** Surgical technique and rationale for medial patellofemoral ligament reconstruction for recurrent patellar dislocation. *Arthroscopy* 2003 ; 19 : E47 : 1-9.
13. **Nomura E, Donald CF, Elizabeth EA.** The significance of the medial patellofemoral ligament in patellar dislocation. *Seikeigeka* (in Japanese) 2002 ; 53 : 1 : 1-7.
14. **Ochi M, Murakami Y, Deie M, Ikuta Y.** Roentgenographic examination of subluxation and instability of the patella. *J Joint Surg* (in Japanese) 1996 ; 15 : 53-61.
15. **Tanaka K, Kimura M, Hasegawa J.** Study for patellofemoral malalignment. *Tokyo hiza kansetugakkai kaishi* (in Japanese) 1990 ; 11 : 44-51.
16. **Urtho M, Kujala MD.** Scoring of patellofemoral Disorders. *Arthroscopy* 1993 ; 9 : 159-163.