



Acutrak fixation of comminuted distal radial fractures

Kirti MOHOLKAR, Tagdh O'SULLIVAN

From Waterford Regional Hospital, Waterford, UK

The authors describe a new technique of fixation of comminuted displaced distal radial fractures in young adults. A 40-year-old man fell from a ladder and injured his wrist. He sustained a comminuted fracture of the distal radius. The fracture was opened through a volar incision and the three rotated, unreduced fragments were reduced and fixed with three Acutrak (Acumed Inc., Beaverton, OR, USA) screws. A removable splint was applied to the wrist for one week, following which the wrist was mobilised. Six months later at a routine follow-up the patient had full functional use of the wrist. The purpose of this technical note is to discuss the fracture, the fixation technique, and the management of this subtype of distal radial fractures in young adults.

INTRODUCTION

Distal radial fractures are estimated to account for more than one sixth of the fracture cases seen in emergency rooms (14, 16, 19). Intraarticular fractures especially in young adult patients continue to pose a therapeutic challenge. These injuries are a result of high-energy impact. The carpus is driven into the distal end of the radius, resulting in comminution of its articulated surface. Intraarticular distal radial fractures are inherently unstable, are difficult to reduce anatomically and to immobilise with closed plaster support, and are associated with a high incidence of complications (1, 7, 10, 11, 12). Treatment of such injuries is difficult especially if the comminuted fragments are articular, small and

displaced. The results of closed reduction, percutaneous pin fixation, pins and plaster, and internal and external fixation have been variable (2, 3, 4, 5, 7, 8, 9, 10, 11, 15, 17). More recently there has been a mention of arthroscopy (18) and low profile plates (13) being used to aid the reduction in fixing these fractures.

This paper aims to describe a new technique for fixation of intraarticular distal radial fractures in young adults, which allows early mobilisation of the wrist.

CASE REPORT

A 40-year-old man was up on a ladder in a holiday home when the ladder slipped and he landed on his outstretched arm. He sustained an intraarticular fracture of his distal radius and ulna with the wrist in the classical dinner fork deformity (fig 1a, b).

He was brought to the local casualty unit where he was found to have acute median nerve compression symptoms. The wrist was manipulated under

■ Mr. Kirti Moholkar, FRCSI, Specialist Registrar.

■ Mr. Tagh O'Sullivan, FRCSI, Orthopaedic Consultant.

Department of Orthopaedics, Waterford Regional Hospital, Waterford, UK.

Correspondence : Mr. Kirti Moholkar, 26 Hilton Crescent, Prestwich, Manchester M25 9NQ, U.K.

E-mail : kmoholkar@hotmail.com.

© 2004, Acta Orthopædica Belgica.

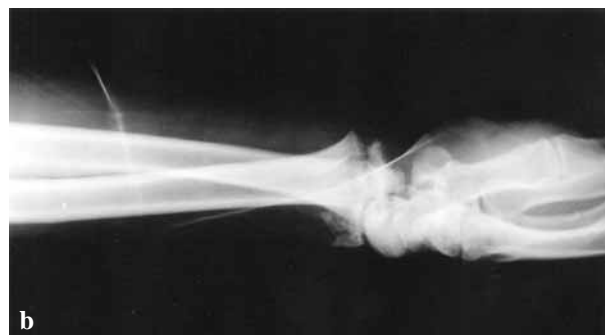
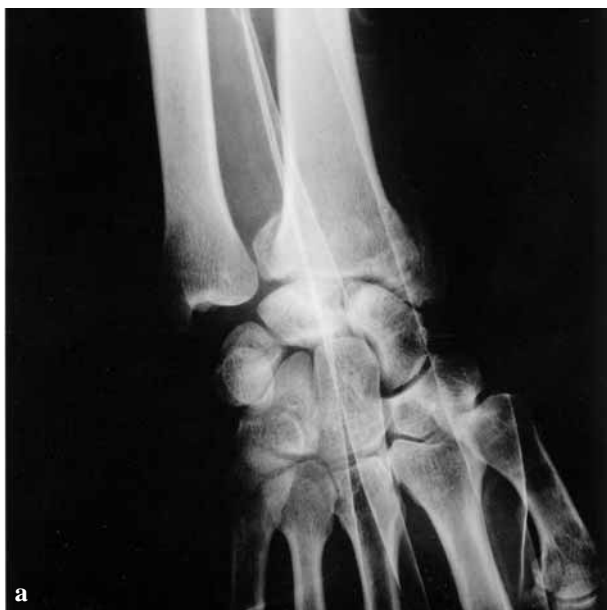

Fig. 1. — AP (a) and lateral (b) view of the wrist

sedation. The manipulation relieved his median nerve symptoms and the patient was transferred to the regional orthopaedic centre for further treatment. He was taken to the theatre immediately and the wrist was examined under anaesthetic and radiographic control and was found to be unstable. The fracture was opened through a 5 centimetre volar incision. There were three irreducible intra-articular volar fragments, which were lying completely rotated. These fragments were derotated and reduced. It was very difficult to keep these fragments reduced and held with K-wires or a buttress plate. The fracture pattern had three main fragments and these were reduced and fixed with a headless compression screw system. Stab incisions were made at the radial styloid and over the 3rd dorsal compartment of the wrist. The fracture fragments were held accurately reduced and cannulated Acutrak (Acumed Inc., Beaverton, OR, USA) screws were inserted. The fracture was found to be stable with dynamic movement of the wrist under radiographic control. The wound was sutured and the wrist was placed in a removable wrist splint.

The patient was seen the following week in the clinic ; the wound was healing satisfactorily. The

splint was removed and physiotherapy initiated. He resumed office work in 6 weeks. At 6 months, the fracture had healed (fig 2). He had full painless range of motion of the wrist and was enjoying leisurely activities including a weekend round of golf.

DISCUSSION

The treatment outcome of a distal radial fracture is largely determined by the pattern of the injury. Anatomical restoration of the articular surface, which is the goal of treatment, is necessary to minimise the risk of post-traumatic arthritis (6). Percutaneous and limited open fixation of fractures of the distal radius is an important method of treatment for many unstable fractures such as unstable dorsal bending fractures, shearing fractures of the radial styloid and lunate facet, and simple articular fractures (6). This modality of fixation is indicated when the articular fragments lie completely loose with an intact dorsal radial cortex acting as a buttress to stabilise them.

Acutrak screw fixation is recommended for young adult patients with comminuted displaced intra-articular distal radial fractures. These screws are tapered, fully threaded, cannulated and headless. They are designed with variable thread pitch, have a tapered profile, which causes the threads to constantly purchase new bone. With these screws the fracture can lie anywhere along the length of the screw which optimises the compression and pullout strength of the screw. This type of fixation is advantageous for various reasons. Firstly it is a

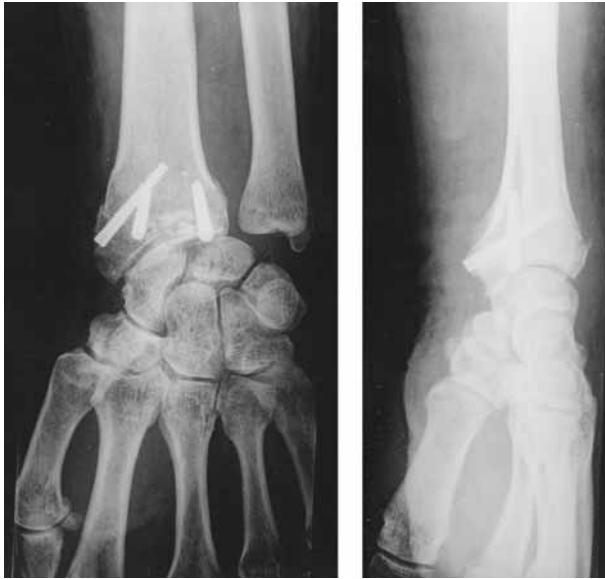

Fig. 2. — Healed fracture at 6 months

minimally invasive technique and does not involve a large exposure or periosteal stripping. The wrist can be mobilised early; therefore the risk of post-traumatic stiffness is minimised. There is minimal chance of infection and the screws are buried in the bone hence there is no need for removal of implants.

The aims of treatment of distal radial fractures are to allow early functional recovery of the limb, to improve the long-term function of the wrist, and to prevent cosmetic deformity. Various fixation methods are currently in use like cast, percutaneous wires, plates and screws and external fixators. In spite of this vast armamentarium, the treatment outcome of this complex injury is ill understood. The fracture pattern should be studied in detail before choosing any treatment modality or fixation method to predict the treatment outcome.

The technique of Acutrak screw fixation is for intraarticular distal radial fractures in young adults with no dorsal comminution. In osteoporotic bones the screws do not have good purchase and in highly comminuted fractures the screws alone would not provide adequate fixation. Whilst the long-term results of this single patient study are still awaited,

it does appear that adequate anatomical reconstruction and early mobilisation could prove to be beneficial to treat this subgroup of distal radial fractures. Further research is needed to assess the treatment outcome of fractures treated by Acutrak screws on a large number of patients.

REFERENCES

1. **Alffram PA, Bauer GCH.** Epidemiology of the fractures of the forearm: A biomechanical investigation of bone strength. *J Bone Joint Surg* 1962; 44-A: 105-114.
2. **Axelrod TS, McMurtry RY.** Open reduction and internal fixation of comminuted, intraarticular fractures of the distal radius. *J Hand Surg* 1990; 15-A: 1-11.
3. **Bacorn RW, Kurtzke JF.** Colles' fracture. A study of two thousand cases from the New York State Workman's compensation Board. *J Bone Joint Surg* 1953; 35-A: 643-658.
4. **Bassett RL.** Displaced intraarticular fractures of the distal radius. *Clin Orthop* 1987; 214: 148-152.
5. **Bradway JK, Amadio PC, Cooney WP.** Open reduction and internal fixation of displaced, comminuted intra-articular fractures of the distal end of the radius. *J Bone Joint Surg* 1989; 71-A: 839-847.
6. **Carter PR, Frederick HA, Laseter GF.** Open reduction and internal fixation of unstable distal radius fractures with a low-profile plate: a multicenter study of 73 fractures. *J Hand Surg* 1998; 23A: 300-307.
7. **Chapman DR, Bennett JB, Bryan WJ, Tullos HS.** Complications of distal radial fractures: Pins and plaster treatment. *J Hand Surg* 1982; 7: 509-512.
8. **Cole JM, and Obletz BE.** Comminuted fractures of the distal end of the radius treated by skeletal transfixion in plaster cast: An end-result study of thirty-three cases. *J Bone Joint Surg* 1966; 48-A: 931-945.
9. **Colles A.** On the fracture of the carpal extremity of the radius. *Edinb Med Surg J* 1814; 10: 182-186.
10. **Cooney WP, Dobyns JH, Linscheid RL.** Complications of Colles' fractures. *J Bone Joint Surg* 1980; 62-A: 613-619.
11. **Cooney WP, Linscheid RL, Dobyns JH.** External pin fixation for unstable Colles' fractures. *J Bone Joint Surg* 1979; 61-A: 840-845.
12. **Frykman G.** Fracture of the distal radius including sequelae-shoulder-hand-finger syndrome, disturbance in the distal radio-ulnar joint, and impairment of nerve function: A clinical and experimental study. *Acta Orthop Scand* 1967; 108: 1-153.
13. **Geissler WB.** Arthroscopically assisted reduction of intra-articular fractures of the distal radius. *Hand Clin* 1995; 11: 19-29.
14. **Golden GN.** Treatment and prognosis of Colles fracture. *Lancet* 1963; 1: 511-514.

15. **Grana WA, Kopta JA.** The Roger Anderson device in the treatment of fractures of the distal end of the radius. *J Bone Joint Surg* 1979 ; 61-A : 1234-1238.
16. **Hollingsworth R, Morris J.** The importance of the ulnar side of the wrist in fractures of the distal end of the radius. *Injury* 1976 ; 7 : 263-266.
17. **Leibovic SJ, Geissler WB.** Treatment of complex intra-articular distal radius fractures. *Orthop Clin North Am* 1994 ; 25 : 685-706.
18. **Leung KS, Shen WY, Tsang KH et al.** An effective treatment of comminuted fractures of the distal radius. *J Hand Surg* 1990 ; 15-A : 11-17.
19. **Owen RA, Melton LJ, Johnson KA et al.** Incidence of Colles fractures in North American Community. *Am J Pub Health* 1982 ; 75 : 606-607.