

INTRACARPAL LIGAMENTOUS LESIONS ASSOCIATED WITH FRACTURES OF THE DISTAL RADIUS : OUTCOME AT ONE YEAR. A PROSPECTIVE STUDY OF 95 CASES

J. LAULAN, J. P. BISMUTH

Intracarpal ligamentous lesions associated with fractures of the distal radius (FDR) are frequent. The prevalence of these lesions has been assessed either by arthrography or by arthroscopy, but their outcome remains unknown. We carried out a radiographic study to assess the incidence of intracarpal ligamentous lesions with scapholunate (SL) and/or lunotriquetral (LT) dissociation and their outcome at one year. These lesions were termed "dissociative ligamentous lesions" (DLL).

This prospective series consisted of 102 consecutive FDR's. The initial xrays, immediate postoperative xrays and xrays at 1 year were studied. We studied the relationships of the bones of the first carpal row, abnormal joint space widening, Gilula's lines and the values of the intracarpal angles. The evolution of the carpal height ratio between day 0 and one year was studied.

Complete xrays were available for 95 patients. There were 9 epiphyseal, 45 metaphyseal and 41 mixed fractures. DLL's were diagnosed in the early stages in 40 patients. There were 29 isolated SL lesions, 2 isolated LT lesions and 9 cases of associated SL and LT lesions. At 1 year, the diagnosis was confirmed in all these cases but a further case of SL dissociation was diagnosed. At 1 year, 61% of DLL's showed significant loss of carpal height and were considered as progressive. There was an association between the type of fracture and the presence or absence of DLL ($p = 0.02$).

This study, based on radiographic analysis alone, showed 43% DLL's. The majority could be identified immediately. These findings are similar to those in recent arthrographic or arthroscopic studies, but the interest of plain radiographic study is to diagnose only those lesions having a definite effect on the carpus ("static instability"). At 1 year, 61% of lesions diagnosed have significantly affected carpal height.

Keywords : fractures of the distal radius ; dissociative instability ; scapholunate instability, triquetrolunate instability.

Mots-clés : fractures du radius distal ; instabilité dissociative ; instabilité scapho-lunaire ; instabilité triquéro-lunaire.

The association of ligamentous lesions of the wrist and fractures of the distal radius (FDR) is now well documented (13, 14, 19, 22). The prevalence of ligamentous lesions ranges from 0.5 to 75% according to the studies (2, 18, 19).

The incidence of intracarpal ligamentous lesions may be higher in articular fractures (19, 20). Mayfield *et al.* (12), and more recently Saffar (20), have emphasized the unique nature of the mechanism of radial styloid fractures and rupture of the scapholunate interosseous ligament. Ligamentous lesions may also be observed with metaphyseal fractures (5, 18).

Recent arthrographic (5) and arthroscopic studies (18) found ligamentous lesions in nearly 75% of FDR's. Over half of the lesions reported involved the triangular ligament complex. The prevalence of scapholunate (SL) and triquetrolunate (TL) injuries was about 40%. However, the significance of the abnormalities observed on arthro-

Hand Surgery Unit, Orthopedic Department, Centre Hospitalier Universitaire Trousseau, F-37044 Tours, France.

Correspondence and reprints : J. Laulan, Unité de Chirurgie de la Main, Service d'Orthopédie 1, CHU Trousseau, F-37044 Tours, France.

graphy is debatable (1, 7). Inversely, arthrography fails to detect ligamentous attenuation, whereas in fact simple attenuation of the SL ligament may result in SL instability (10). Above all, acute diagnosis of ligamentous injuries by arthrography or arthroscopy does not allow prediction of its potential severity and its outcome.

Ligamentous lesions that may be associated with dissociative instability (11) have certain specific features. On the one hand, instability, whether SL or TL, requires not only a tear of the corresponding interosseous ligament but also lesions involving capsular ligamentous structures (6, 21). Capsular ligaments can in fact heal by immobilization alone, and if there is no carpal malalignment, conservative treatment seems appropriate (16, 17). On the other hand, their radiographic criteria are well defined (8, 11, 21). Their repercussions on the carpus can be studied by measuring the carpal height ratio (CHR) by the method of Nattrass *et al.* (15), for which the normal value is 1.57 ± 0.05 . It also seems that the development of secondary arthritis is linked to carpal malalignment and/or carpal collapse, and the likelihood of secondary arthritis is only clearly documented for dissociative instability (3, 11, 24).

For these various reasons, we carried out a radiographic study of these lesions in a prospective series of FDR's. Our aims were to define the value of plain radiographs in the initial diagnosis and to study the outcome over one year of the lesions diagnosed.

MATERIAL AND METHODS

Over a seven-month period, all FDR's that required surgical reduction and fixation were included in a prospective study. This consecutive series consisted of 125 cases which were assessed clinically and radiologically at one, six and twelve weeks. At one year, 103 FDR's were evaluated, as 22 patients were lost to follow-up. The patients were reviewed by an independent examiner.

The initial radiographic investigation included anteroposterior and lateral views of both wrists. Anteroposterior and lateral views of the fractured side were taken immediately after surgery and after each examination. We analyzed the following parameters: Gilula's lines, radiolunate angle, SL space, SL angle, TL space

and CHR according to the method of Nattrass *et al.* (15). Carpal height measurement is reliable only on postoperative views and could therefore not be done in wrists treated by external fixation. Changes in the CHR between initial views and those obtained at 1 year were noted. In agreement with Nattrass *et al.*, a decrease in CHR was considered significant if it was greater than 0.04. The ligamentous lesion was then considered progressive.

SL involvement was diagnosed based on the appearance of SL dissociation (scaphoid flexed and triquetrolunate unit in extension), an SL gap > 2 mm, an abnormality of Gilula's lines above the SL space and/or an SL angle $> 65^\circ$ (11, 20, 21). TL involvement was diagnosed based on the appearance of TL dissociation (triquetrum in extension and SL unit in flexion), abnormality of the TL space (widened or not parallel), and/or an abnormality of Gilula's lines above it (11, 20, 21) (fig. 1). A double, perilunate (PL) ligamentous lesion was diagnosed based on signs suggesting both SL and TL dissociation. The lesions diagnosed in this way were named "dissociative ligamentous lesions" (DLL).

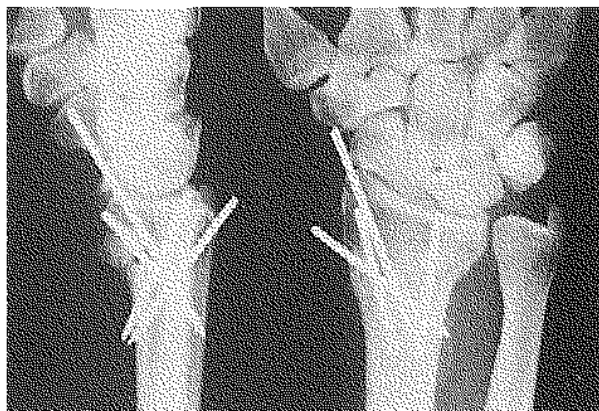


Fig. 1. — Triquetrolunate instability associated with extra-articular fracture of the distal radius (postoperative xrays).

We also noted age, sex, profession, type of fracture (extra-articular, intra-articular or mixed), the severity of the fracture (it was considered severe if metaphyseal comminution involved at least half the circumference and/or there was joint impaction) and the treatment applied (K-wires, external fixation or other). Ulnar styloid fracture was sought, and its displacement (> 2 mm) if any was noted. Associated lesions were also noted. The clinical outcome at 1 year was evaluated using objective parameters (mobility and grip strength

compared with the uninjured opposite wrist) and subjective parameters (pain and patient satisfaction). Mobility took into account flexion, extension, pronation and supination and was classified in 3 groups. Mobility was considered good if loss of function was less than 25% in each of the 4 sectors. It was fair if loss was more than 25% in any sector and poor if loss was more than 50% in any sector. The same thresholds of 25 and 50% were used for grip strength measured using a Jamar dynamometer. Wrist pain was classified in 3 groups : no pain, occasional pain after strenuous use, or permanent, disabling pain. The site of pain was noted : radiocarpal, distal radio-ulnar, distal radiocarpal and radio-ulnar, diffuse. Lastly, the patient was asked if he or she was satisfied, moderately satisfied, or dissatisfied with the result. For clinical evaluation of algodystrophy (AD) a semiquantitative score was used (9). Reactional disorders were classified in 4 groups : active, transient, doubtful and absent AD. The radiologic result was classified in 3 groups according to norms based on the literature and previously published (9).

Statistical analysis

The relations between the various parameters, according to type, were studied using the chi-square test (with Yates' correction if necessary), the t-test or analysis of variance (ANOVA) or the Kruskal-Wallis test.

RESULTS

One patient required revision surgery during the study, and functional results at 1 year were assessed in 102 fractures. Seven patients were excluded because angle measurements could not be made on their radiographs. The study thus comprised 95 patients.

The population consisted of 61 women and 34 men. Their mean age was 55 years (range 17 to 93 years), with a mean age of 60 years for the women and 46 years for the men. There were 9 intra-articular, 45 extra-articular and 41 mixed fractures. Fifty-one were treated by K-wires, 33 by external fixation and 11 by an anterior plate. There were 61 ulnar styloid fractures of which 41 (67%) were displaced.

At 1 year, mobility was good in 39%, fair in 38% and poor in 23% of cases. Grip strength was

good in 64%, fair in 23% and poor in 13%. Radiologic results at 1 year were good in 33%, fair in 37% and poor in 30%. Concerning subjective functional results, 86% of patients had no wrist pain, 12% had occasional pain after strenuous use, and 2% considered their pain disabling. The patient considered the result satisfactory in 73% of cases, tolerable in 23% and poor in 4%.

The initial radiographic images suggested DLL in 40 cases : 4 on preoperative views, 15 on postoperative views and in 21 cases on both. These related to 27 women and 13 men, mean age 57 years, with 29 SL, 2 TL and 9 double PL dissociations. Sixteen SL dissociations were diagnosed from the association of a widened joint space with another sign (lunate in extension, 8 ; step-off in Gilula's lines, 6 ; and association of both signs in 2 cases) and 13 from the presence of 1 sign (widened joint space, 10 ; increased SL angle, 3). TL involvement was diagnosed once because of patent TL dissociation and once from the association of TL space widening with step-off on Gilula's lines. PL instability was diagnosed in 9 cases on the basis of apparent TL dissociation associated with SL space widening ; in 3 cases there was also an SL step-off.

At 1 year, one more case was diagnosed. This was an SL dissociation which was not visible on the initial views. The various DLL's according to the type of fracture are shown in table I.

Table I. — Distribution of the various dissociative ligamentous lesions diagnosed in 95 patients with fractures of the distal radius, according to the type of fracture

Type of DLL	Type of fracture		
	Epiphyseal	Metaphyseal	Mixed
absent	2	31	21
SLI	6	7	17
TLI	0	1	1
PLI	1	6	2

DLL, dissociative ligamentous lesion ; SLI, scapholunate instability ; TLI, triquetrolunate instability ; PLI, perilunate instability.

CHR was measured at 1 year in the whole series. It was measured on the postoperative radiographs of 62 patients, 33 having been treated

Table II. — Mean values (+/- SD) of carpal height ratio, measured by the method of Nattrass *et al.* in the different groups of patients with distal fractures of the radius

	Total pop.	DLL absent	DLL present
Initial xray	1.59 (0.08)	1.60 (0.06)	1.56 (0.07)
Xray at one year	1.56 (0.09)	1.60 (0.06)	1.51 (0.09)

DLL : dissociative ligamentous lesion

by external fixation. Mean CHR values are shown in table II. In the absence of DLL, the mean CHR was 1.60 at day 0 and at 1 year. It was 1.56 at day 0 and 1.51 at one year in patients with DLL. The difference between the two groups was already significant at day 0 ($p = 0.05$) and was highly significant at 1 year ($p < 0.0001$).

Thirteen of the 41 cases with DLL were treated by external fixation. They included 11 SL dissociations, one TL and one PL dissociation. The decrease in CHR was thus measured for 28 of the 41 cases. In 17 cases (12 SL and 5 PL dissociations) CHR loss exceeded 0.04. At 1 year in this group the CHR was abnormal (< 1.52) in 12 cases (10 SL dissociations and 2 PL dissociations).

At 1 year, the mean CHR was 1.57 (± 0.09) in nonprogressive DLL and 1.48 (± 0.06) in progressive DLL. The difference was significant ($p < 0.0001$). Among the 54 patients in whom DLL was not diagnosed, the CHR was abnormal from the outset in 3 (1.50), but it remained unchanged at 1 year. The decrease in CHR could be measured in 34 of these 54 cases; the difference was greater than 0.04 in a single case and the value at 1 year remained greater than 1.52.

No correlation was found between DLL and the age ($p = 0.54$) or sex ($p = 0.42$) of the patient, nor between DLL and overall radiologic result, objective (mobility and grip strength) or subjective (pain and satisfaction) functional results, or development of AD ($p = 0.88$). There was however a correlation between the type of fracture and DLL, which was significantly more frequent in fractures with an intra-articular component ($p < 0.05$) and displaced ulnar styloid fractures ($p < 0.02$). Twenty-three of the 30 SL dissociations were associated with an epiphyseal fracture and

6 of the 9 PL dissociations with an extraarticular fracture. The series was however too small for the correlation between type of fracture and type of DLL to reach significance.

There was a correlation between a decrease in CHR and type of fracture ($p = 0.05$), as articular fractures were significantly correlated with progressive DLL's ($p = 0.02$).

DISCUSSION

FDR's are frequently associated with DLL's and must be considered as lesions involving both bone and ligaments. Nearly all DLL's can be diagnosed on initial or immediate postoperative radiographs. Most lesions are progressive and have significant repercussions on carpal height at 1 year. Their incidence is higher and the risk of progression is greater if the fracture is intra-articular.

The significance of abnormalities seen on arthrography is debatable (1, 7), and arthroscopy cannot be routinely carried out in all FDR's. Neither of these investigations can inform us as to the potential severity of the lesions and the risk of progression. We believe it difficult to detect instability on arthroscopy although this is proposed by some authors (4, 18). In this context, it seems to us important to take into account and treat only those lesions which are likely to have repercussions on carpal statics or to lead to arthritis over the medium and long term.

Rosenthal *et al.* in a retrospective radiographic study found only 7.4% of DLL (19). Later, various arthrographic (5) or arthroscopic studies (18, 23) found an incidence ranging from 33 to 43%. Our study, based on plain radiographs, found a similar figure of 43%. Nearly three-quarters of the DLL's we diagnosed were SL dissociations and, unlike the study of Fontes *et al.* (5), the incidence of TL dissociation was low. A standard plain radiograph is probably not sufficiently sensitive for the diagnosis of an isolated TL lesion (20). Inversely, an isolated tear at the level of a TL ligament is of limited value, and the findings in the various studies show large variations in the incidence of TL lesions (5, 18). Lastly, it has never been demonstrated that TL lesions without carpal ma-

lignment may progress towards arthritis ; they can be treated by simple immobilization (17).

Early diagnosis was possible in 98% of cases since only 1 further case was diagnosed at 1 year. This is comparable with the results of Rosenthal *et al.* (19). There is no reason to believe that severe DLL may have gone undetected in the other cases. Thus in the great majority of cases, plain anteroposterior and lateral radiographs seem to us sufficient to diagnose DLL that may require treatment.

Our results confirm that the incidence of DLL is higher if the FDR is intra-articular (20). However, two-thirds of associated SL and TL lesions are associated with extra-articular metaphyseal fractures that may result from a different mechanism. Lastly, we found a highly significant correlation between DLL and displaced ulnar styloid fracture. This association had already been noted by Saffar (20).

No correlation was found between DLL and the functional result at 1 year. This is in contrast with the findings of Tang *et al.* (22), but their series consisted only of SL dissociations selected for their severity, and all the FDR's had received only conservative treatment.

The mean CHR (15) was significantly lower in the group with DLL. This difference tended towards significance initially and was highly significant at 1 year. Except for one case without DLL whose CHR was greater than 1.52 at 1 year, the CHR decreased only in the DLL group. These findings retrospectively validate our criteria and the diagnostic value of plain radiographs.

Among the cases of DLL whose progression could be studied, 61% were associated with a significant decrease in CHR at 1 year. The risk of progression of DLL is higher if the fracture is intra-articular. However, even retrospectively, no other elements made it possible to predict which lesions might progress.

REFERENCES

1. Cantor R., Stern P., Wyrick J., Michaels S. The relevance of ligament tears or perforations in the diagnosis of wrist pain : An arthrographic study. *J. Hand Surg.*, 1994, 19-A, 945-953.
2. Castaing J. Les fractures récentes de l'extrémité inférieure du radius chez l'adulte. *Rev. Chir. Orthop.*, 1964, 50, 583-696.
3. Clément P., Laulan J., Sicre G. Les lésions triquétrounaires et leurs séquelles dans les luxations péri-lunaires du carpe. *La Main*, 1998, 3, 109-118.
4. Dautel G., Goudot B., Merle M. Arthroscopic diagnosis of scapho-lunate instability in the absence of X-ray abnormalities. *J. Hand Surg.*, 1993, 18-B, 213-218.
5. Fontes D., Lenoble E., De Somer B., Benoit J. Lésions ligamentaires associées aux fractures distales du radius. A propos de 58 arthrographies peropératoires. *Ann. Chir. Main*, 1992, 11, 119-125.
6. Horii E., Garcia-Elias M., An K., Bishop A., Cooney W., Linscheid R., Chao E. A kinematic study of lunotriquetral dissociations. *J. Hand Surg.*, 1991, 16-A, 355-362.
7. Kirschenbaum D., Sieler S., Solonick D., Cody R. Arthrography of the wrist. Assessment of the integrity of the ligaments in young asymptomatic adults. *J. Bone Joint Surg.*, 1995, 77-A, 1207-1209.
8. Larsen C., Mathiesen F., Lindequist S. Measurements of carpal bone angles on lateral wrist radiographs. *J. Hand Surg.*, 1991, 16-A, 888-893.
9. Laulan J., Bismuth J. P., Sicre G., Garaud P. The different types of algodystrophy after fracture of the distal radius. *J. Hand Surg.*, 1997, 22-B, 441-447.
10. Lavernia C., Cohen M., Taleisnik J. Treatment of scapholunate dissociation by ligamentous repair and capsulodesis. *J. Hand Surg.*, 1992, 17-A, 354-359.
11. Linscheid R., Dobyns J., Beabout J., Bryan R. Traumatic instability of the wrist. Diagnosis, classification and pathomechanics. *J. Bone Joint Surg.*, 1972, 54-A, 1612-1632.
12. Mayfield J., Johnson R., Kilcoyne R. Carpal dislocations : Pathomechanics and progressive perilunar instability. *J. Hand Surg.*, 1980, 5, 226-241.
13. Melone C. Articular fractures of the distal radius. *Orthop. Clin. North Am.*, 1984, 15, 217-236.
14. Mudgal C., Hastings H. Scapholunate diastasis in fracture of the distal radius. Pathomechanics and treatment options. *J. Hand Surg.*, 1993, 18-B, 725-729.
15. Natrass G., King G., McMurtry R. An alternative method for determination of the carpal height ratio. *J. Bone Joint Surg.*, 1994, 76-A, 88-94.
16. Palmer A., Dobyns J., Linscheid R. Management of post-traumatic instability of the wrist secondary to ligament rupture. *J. Hand Surg.*, 1978, 3, 507-532.
17. Reagan D., Linscheid R., Dobyos J. Lunotriquetral sprains. *J. Hand Surg.*, 1984, 9-A, 502-514.
18. Richards R., Bennett J., Roth J., Milne K. Arthroscopic diagnosis of intra-articular soft tissue injuries associated with distal radial fractures. *J. Hand Surg.*, 1997, 22-A, 772-776.
19. Rosenthal D., Schwartz M., Phillips W., Jupiter J. Fractures of the radius with instability of the wrist. *Am. J. Radiol.*, 1983, 141, 113-116.
20. Saffar P. L'instabilité du carpe post-traumatique. In :

- Cahier d'enseignement de la Société Française de Chirurgie de la Main, Expansion Scientifique Française. Paris, 1989, 1, pp. 31-51.
21. Taleisnik J. The wrist. Churchill Livingstone, New York, 1985, p. 442.
 22. Tang J., Gu Y., Zhang Q. Can cast immobilisation successfully treat scapholunate dissociation associated with distal radius fractures? *J. Hand Surg.*, 1996, 21-A, 583-590.
 23. Thomas C., Dupuy M., Voche P., Dautel G., Dap G., Merle M. Lésions ligamentaires du poignet et fractures fraîches du radius. A propos d'une série prospective de 15 arthroscopies. Presented at the 28th Congress of the S.F.C.M. (G.E.M.), Paris, December 1992.
 24. Watson H., Ballet F. The SLAC wrist: Scapholunate advanced collapse pattern of degenerative arthritis. *J. Hand Surg.*, 1984, 9-A, 358-365.

SAMENVATTING

J. LAULAN, J. P. BISMUTH. Intercarpale ligamentaire letsels in associatie met distale radiusfracturen: resultaten na 1 jaar: een prospectieve studie van 95 gevallen.

Ligamentaire carpusletsels zijn vaak aanwezig bij fracturen van de distale radius. Het voorkomen van deze letsels kan worden vastgesteld door artrografie of door arthroscopie. Het eindresultaat van die letsels is onbekend. Doel van deze studie is om de dissociatieve ligamentaire letsels (de scapholunare en de triquetrolunare ligamentaire letsels) na te kijken en te volgen over 1 jaar.

De reeks bestaat uit 102 consecutieve gevolgde distale radiusfracturen. De analyse wordt uitgevoerd met de initiële radiografieën, postoperatoire resultaten onmiddellijk en na 1 jaar. De verhouding van de verschillende carpusbeentjes, de aanwezigheid van een abnormaal interval, de Gilula-lijnen, en de intercarpale hoeken. Ook de hoogte van de carpus tussen dag 0 en 1 jaar werd nagekeken.

Bij 95 gevallen was het dossier radiografisch bruikbaar. Er waren 9 epifysaire, 45 metafysaire en 41 gemengde fracturen. De diagnose van dissociatieve ligamentair letsel werd vastgesteld bij 40 gevallen onmiddellijk posttraumatisch. Het betrof hier 29 scapholunare, 2 triquetrolunare en 9 dubbele letsels. Het type fractuur en de aanwezigheid van ligamentaire letsels was gecorrelleerd ($P = 0,02$). Na 1 jaar werd de diagnose bevestigd in alle gevallen maar 1 supplementair scapholunair letsel werd gediagnosticeerd. Bij 61% der gevallen met ligamentaire letsels was de carpushoogte afgenomen. Deze studie weerhield 43% ligamentaire letsels waarvan

de meerderheid onmiddellijk posttrauma werd gediagnosticeerd. Deze resultaten zijn vergelijkbaar met de recente artrografische en arthroscopische studies. Het belang van deze radiografische studie is enkel om deze letsels te diagnosticeren met een duidelijke statische instabiliteit van de carpus: deze welke een invloed hebben op de carpus. Na 1 jaar is 61% van de gediagnosticeerde letsels geassocieerd aan een verminderde carpushoogte.

RÉSUMÉ

J. LAULAN, J.-P. BISMUTH. Lésions ligamentaires intra-carpiennes associées aux fractures du radius distal: devenir à un an. Étude prospective de 95 cas.

Les lésions ligamentaires intra-carpiennes sont fréquemment associées aux fractures du radius distal (FRD). La prévalence de ces lésions a été précisée soit par arthrographie soit par arthroscopie, mais le devenir des lésions observées reste inconnu. Le but de ce travail était d'étudier l'incidence des lésions ligamentaires dissociatives (LLD), scapho-lunaire (SL) et / ou triquetrolunare (TL), par une étude radiographique et de préciser leur devenir à un an.

La série prospective était constituée de 102 FRD consécutives. L'analyse a porté sur les radiographies initiales, post-opératoires immédiates et à 1 an. Ont été étudiées: la position relative des différents os de la première rangée, la présence d'un écart anormal, les lignes de Gilula et les valeurs angulaires intra-carpiennes. L'évolution du rapport de hauteur du carpe, entre J0 et 1 an, a été étudiée.

Les incidences radiographiques étaient exploitables dans 95 dossiers. Il y avait 9 fractures épiphysaires, 45 fractures métaphysaires et 41 fractures mixtes. Le diagnostic de LLD a été posé 40 fois dans la période initiale. Il y avait 29 lésions SL isolées, 2 lésions TL isolées et 9 cas de lésions doubles, SL et TL. Le type de fracture et la présence ou non de LLD étaient liés ($p = 0,02$). A 1 an, tous les diagnostics ont été confirmés mais un cas supplémentaire de lésion SL a été diagnostiqué. A 1 an, 61% des LLD étaient associées à une perte significative de la hauteur du carpe.

Cette étude retrouve 43% de LLD dont la majorité peut être diagnostiquée d'emblée. Ce résultat est proche de ceux d'études arthrographiques ou arthroscopiques récentes, mais l'intérêt d'une étude radiographique simple est de ne diagnostiquer que les lésions ayant un retentissement certain sur le carpe («instabilités statiques»). A 1 an, 61% des lésions diagnostiquées sont associées à un collapsus carpien.