

# A METHOD TO MEASURE ACETABULAR CUP ANTEVERSION AFTER TOTAL HIP REPLACEMENT

L. FABECK<sup>1</sup>, D. FARROKH<sup>2</sup>, M. TOLLEY<sup>3</sup>, P. Y. DESCAMPS<sup>1</sup>, M. GEBHART<sup>4</sup>, P. DELINCÉ<sup>1</sup>

The authors propose a simple and practical method to measure radiologically the angle of ante- or retroversion of the acetabular cup using a goniometer. It only necessitates an anteroposterior radiograph centered on the femoral head and another one centered on the pubic symphysis. Special x ray equipment, compass, conversion table, mathematical formulas, or a pocket calculator are not required.

The opening of the prosthetic cup is projected on the film as an ellipse. According to the rules of descriptive geometry, the true size of the angle of anteversion is easily obtained. The geometric constructions consist in drawing four lines. The adequate positioning on a hip radiograph of the protractor, drawn on the goniometer, permits the direct reading of the true and planar anteversion angles of the cup.

**Keywords :** hip, cup, anteversion, prosthesis, acetabulum.

**Mots-clés :** hanche, cupule, antéversion, prothèse, cotype.

---

## INTRODUCTION

Although the optimal degree of anteversion of the acetabular cup is not clearly defined, varying from 10 to 20° (4, 5), most authors find a link between dislocation of the hip prosthesis or loosening of the acetabular component and incorrect orientation of the cup with respect to a transverse plane (1, 2, 5, 10, 16).

Different methods have been developed to evaluate the acetabular ante- or retroversion. Unfortunately these methods require complicated manipulations on the x ray table (6, 7), mathematical formulas or the use of conversion tables (1, 9, 10, 15).

By geometrical projection, the metallic ring or the edge of the cup allows simple measurement of the cup anteversion from an anteroposterior (AP) radiograph. We describe a simple technique of measurement that enables the orthopedist or the radiologist to routinely evaluate the cup position without requiring special radiographic views.

## MATERIAL AND METHODS

### Definition of the true and planar angles of anteversion

The acetabular cup position can be defined by two angles: abduction and anteversion. The abduction angle can be defined as the inclination of the cup on the transverse plane of the individual. For the anteversion angle, Ackland *et al.* (1) have described the true and planar angles, depending on the axis of reference chosen.

The intersection between a first plane  $\pi$  defined by the cup edge and a second plane  $\theta$ , transverse to the body, is line  $g$  (fig.1a). The intersection between this transverse plane and a parasagittal plane  $\lambda$ , is line  $f$ . The angle between both lines is the true anteversion angle  $\alpha$ .

---

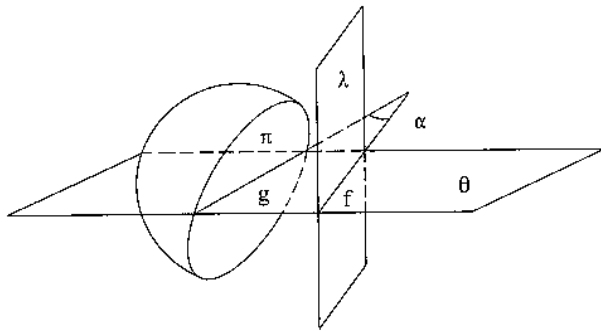
<sup>1</sup> Department of Orthopedic Surgery and Traumatology, Centre Hospitalier Universitaire Saint-Pierre, Bruxelles, Belgium.

<sup>2</sup> Department of Radiology, CHU Saint-Pierre, Bruxelles, Belgium.

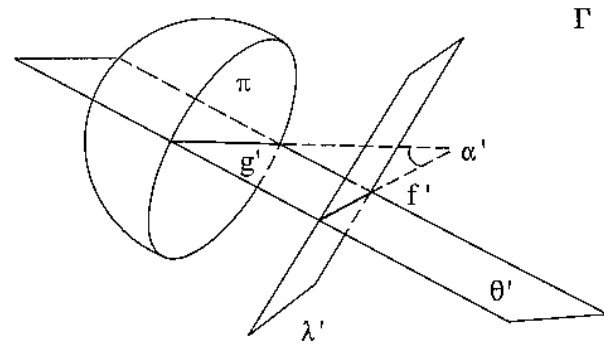
<sup>3</sup> Department of Analytical Mechanics, Université Libre de Bruxelles, Bruxelles, Belgium.

<sup>4</sup> Department of Orthopedic Surgery and Traumatology, Bordet Institute, Bruxelles, Belgium.

Correspondence and reprints: Fabeck L., Department of Orthopedic Surgery, CHU Saint Pierre, 322 rue Haute, 1000 Bruxelles, Belgium.



**Fig. 1a.** — Definition of the true anteversion angle  $\alpha$  in the transverse plane  $\theta$  of the body ;  $\pi$  : plane of the cup opening ;  $\lambda$  : parasagittal plane ;  $g$  : intersection between planes  $\pi$  and  $\theta$  ;  $f$  : intersection between planes  $\theta$  and  $\lambda$ .



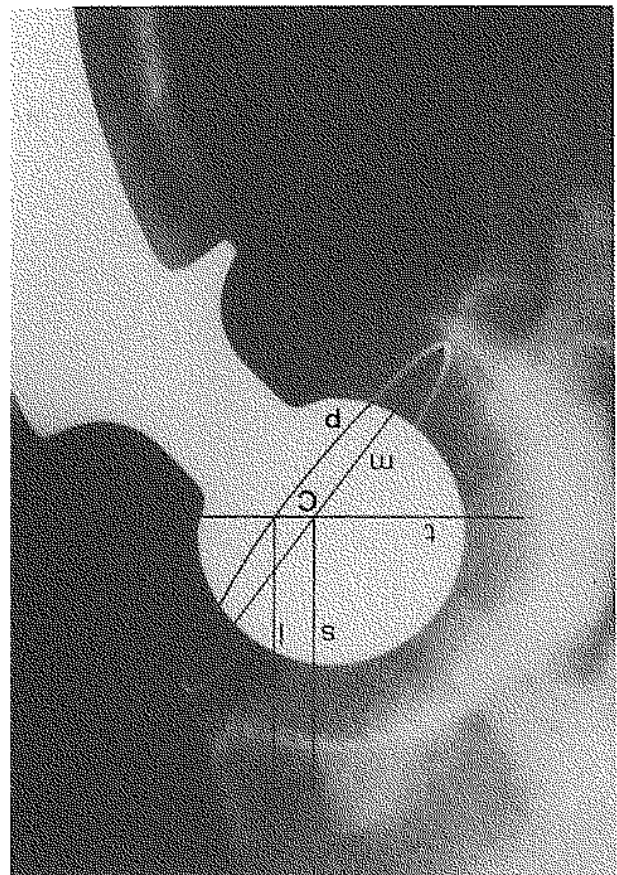
**Fig. 1b.** — Definition of the the planar anteversion angle  $\alpha'$  in the plane  $\theta'$ , perpendicular to the cup opening  $\pi$  ;  $\Gamma$  : frontal plane ;  $\lambda$  : plane perpendicular to plane  $\theta'$  and to the frontal plane  $\Gamma$  ;  $g'$  : intersection between planes  $\pi$  and  $\theta'$  ;  $f'$  : intersection between planes  $\theta'$  and  $\lambda'$ .

We can also define the cup transverse plane  $\theta'$ , simultaneously perpendicular to the cup opening plane  $\pi$  and to the patient's coronal plane,  $\Gamma$  (fig. 1b). The version of the cup in this plane produces a somewhat different relative angle, which Ackland *et al.* (1) define as planar anteversion. The line  $g'$  is defined by the intersection of the plane  $\theta'$  and the plane  $\pi$ . A third plane  $\lambda'$ , simultaneously perpendicular to the frontal plane  $\Gamma$  and to the cup transverse plane  $\theta'$ , intersects the plane  $\theta'$  along the line  $f'$ . The angle between lines  $g'$  and  $f'$  is the planar anteversion angle  $\alpha'$ .

The true anteversion angle  $\alpha$  varies with the lateral inclination of the cup, but the planar anteversion angle  $\alpha'$  is independent of it.

**Constructions for the measurement of the true angle of anteversion**

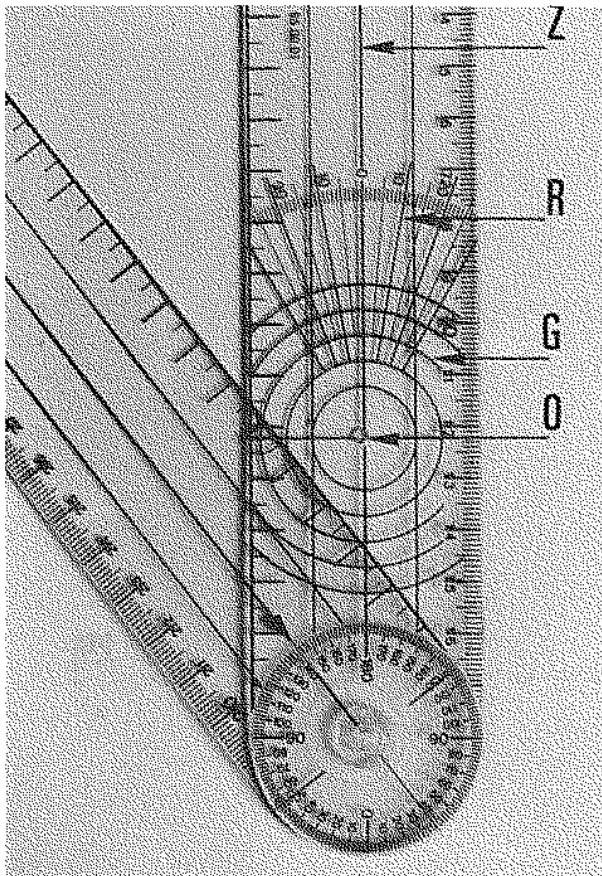
The radiograph is obtained with the patient standing upright. A plumb line is placed against the vertical x ray film as the reference perpendicular to the ground. The x ray tube is focused on the prosthetic femoral head, perpendicular to the coronal plane of the patient. The acetabular cup is a hemisphere and the cup opening is a circle that becomes an ellipse when projected on an AP radiograph of the hip. We can select as an ellipse the projection of the equatorial wire ring or that of the edge of the cup. Due to the opacity of the prosthetic femoral head, parts of this ellipse may be missing. It is not necessary to complete all obscured portions of the ellipse because an ellipse is symmetrical. Only one side is needed for the geometric constructions. The side with the shorter missing part is chosen (fig. 2).




**Fig. 2.** — Frontal projection of the cup ; the major axis  $m$ , its center  $C$  and the line  $t$  are drawn. From the intersection points between line  $t$  and, respectively, the center  $C$  and the completed hemiellipse, two lines,  $s$  and  $l$ , perpendicular to  $t$ , are drawn ;  $p$  : completed part of the ellipse.

The determination of the true anteversion angle proceeds as follows (fig. 2): the major axis of the ellipse,  $m$ , is drawn, and its center  $C$  is marked on the x ray film. The transverse line  $t$ , which is perpendicular to the x ray trace of the plumb line and corresponds to the projection of the transverse plane  $\theta$  of the body, is drawn through the center  $C$ . A first line  $s$ , perpendicular to  $t$  and passing through the ellipse center  $C$ , is drawn. A second line,  $l$ , perpendicular to  $t$  and passing through the intersection of the transverse line  $t$  with the ellipse or the completed part of the ellipse, is drawn (fig. 2).

On one arm of the goniometer (Protek, Bern, Switzerland), there is a protractor with concentric circles (fig. 3). Some circle radii are drawn, and one of them corresponds to the "zero degree" line. To measure the version angle, this axis is positioned on the major axis  $m$ , and its origin is centered on the center  $C$  of the ellipse (fig. 4). The circle on the goniometer



*Fig. 3.* — Goniometer with protractor. Z: the "zero degree" line of the protractor, R: radius of the protractor, G: concentric circles, O: center of the circles.

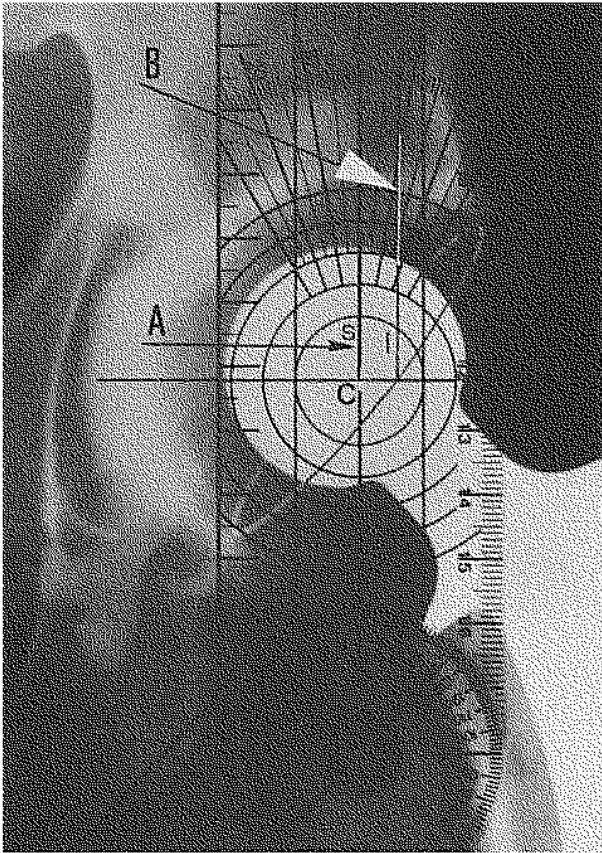


*Fig. 4.* — The center  $O$  of the protractor is centered on  $C$ , the "zero degree" line is positioned on major axis  $m$  and the circle passing through the top of the ellipse is noted (arrow); this position of the goniometer also allows the measurement of the planar anteversion angle. Here, it is  $10^\circ$ .

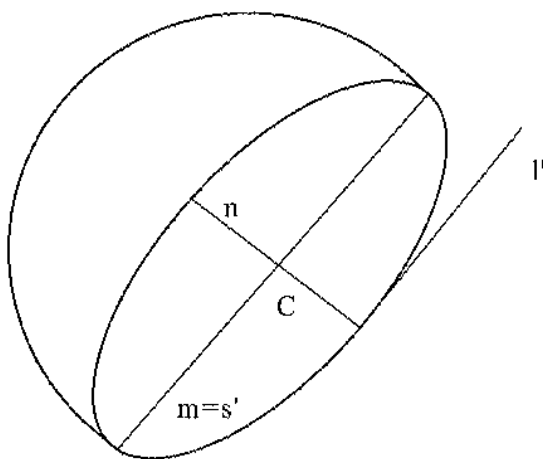
passing through the top of the ellipse is noted. Sometimes, this circle must be interpolated. Afterwards, the "zero degree" line is rotated around the center  $C$  and is positioned on the line  $s$  (fig. 5). The intersection point, between the chosen or interpolated circle and the line  $l$ , belongs to a radius of the protractor. This radius, passing through this point and the center  $C$ , allows the direct evaluation of the true anteversion angle.

#### Constructions for the measurement of the planar angle of anteversion

The determination of the planar anteversion angle  $\alpha'$  on the AP radiograph proceeds as follows (fig. 6): Instead of drawing the transverse line  $t$ , use the minor



**Fig. 5.** — The zero degree line of the protractor (arrow A) is positioned on line s. The intersection point (arrow B) between the chosen optimal circle and the line l' belongs to an extrapolated radius of the protractor and permits a reading of the true anteversion angle. Here, it is  $12^\circ$ .



**Fig. 6.** Frontal projection of the cup and drawing of the lines for the measurement of the planar anteversion angle (legend in the text).

axis, n, and draw the two perpendicular lines to it as described above. The first line  $s'$ , passing through C, corresponds to the major axis, m. The second line  $l'$  is drawn perpendicularly to the minor axis, at the intersection of the latter with the ellipse. The protractor axis corresponding to the "zero degree" line is positioned on the major axis m and its origin centered on the center C of the ellipse (fig. 4). The circle passing through the top of the ellipse is noted. The intersection of the line  $l'$  and this circle allows determination of a point and then direct evaluation of the planar anteversion  $\alpha'$  on the protractor.

Until this point, it cannot be stated that the cup is in an ante- or retroverted position. This problem can be solved by using a second radiograph that is an AP view of the pelvis with the beam centered on the pubic symphysis. An anteverted ellipse will close, a retroverted ellipse will enlarge during focusing (1).

The validity of this method has been demonstrated by measurements on radiographs taken of a cadaver pelvis with an acetabular cup implanted at various degrees of anteversion. The cup anteversion was fixed by an external system of protractor permitting the direct observation of the planar anteversion of the cup. The cup was inserted into the acetabulum at eight different degrees of anteversion ( $0^\circ$ ,  $5^\circ$ ,  $10^\circ$ , ...  $35^\circ$ ) with a constant lateral inclination ( $45^\circ$ ). For each cup position, an AP radiograph was taken. The angle of version  $\alpha'$  was calculated as described above by two of us. The two sets of radiological planar anteversion measurements were compared to the predetermined degrees of cup anteversion. Intra- and interobserver comparisons of the radiological measures were made.

The method was also verified in vivo. Four prosthetic hips were examined radiologically and by computed tomography for the investigation of recurrent dislocation. The anteversion was evaluated directly on the CT-scan views and with our method on the x ray film.

## RESULTS

The intraobserver mean differences for the radiological reading were, respectively for the two observers,  $0.8^\circ$  (SD : 0.163) and  $0.9^\circ$  (SD : 0.125) (NS). The interobserver difference for the radiologic measurements was on average  $1^\circ$  (SD : 0.189) and always less than  $2^\circ$ . The difference of version calculated on the x ray film and on the CT scan slices was on average  $2^\circ$  (SD : 0.4).

## DISCUSSION

A variety of methods has been proposed to measure the anteversion angle of the acetabular cup after total hip replacement (1, 8, 9, 13, 15). Some authors use fluoroscopy (6, 7) or multiple radiographs (10, 16) with various degrees of obliquity, until the lines of the ellipse overlap, to determine the angle of anteversion. These methods involve time and radiation. Others estimate the version of the cup with geometrical formulas, but this necessitates complicated calculations or conversion tables (1, 8, 9). Our method is based on a geometrical construction (12) and requires an instrument used routinely by all orthopedists and radiologists.

In the normal adult hip, the angle of acetabular anteversion was found to change in a linear fashion with the pelvic tilting, varying by 0.5% for 1% of pelvic inclination (14, 15). For this reason, the radiograph is taken with the patient upright to avoid the pelvic tilt following the decrease in lordosis introduced by the supine position.

If the top of the ellipse does not correspond exactly to a goniometer circle, we have to interpolate one. Then, it is important to choose an instrument with a large number of circles on the goniometer protractor to increase the measurement precision. Moreover, it is often necessary to interpolate, but in a small range, the radius of the protractor. These two estimations become easy with practice, and besides these interpolations, the simplicity and the rapidity of the method are positive factors for a routine use. The small interobserver variations and the differences with the CT-scan measurements indicate the relative accuracy of our method in comparison with others (11, 15).

The present method can be used for all types of acetabular cups. If no metal marker is present, the ellipse sides can be easily determined by the difference of contrast between the anterior and posterior edges of the polyethylene cup, describing an ellipse.

Therefore, the method described must be applied with caution to sockets with an augmented posterior lip because the cup opening has lost its

symmetry. In this case, we recommend evaluating only the version of the cup with a radiolucent metallic ring. The known angular value of the posterior lip has to be added to the anteversion angle measured.

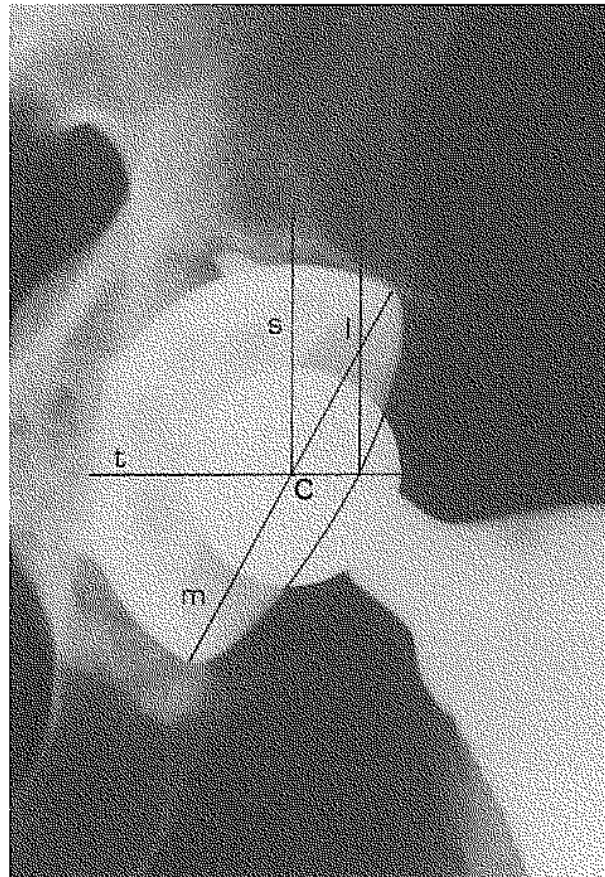


Fig. 7. — Application of the technique to the metal-backed cup.

The method is also applicable to metal backed cups (fig. 7). The posterior hemielliptic edge of the metallic shell is distinctive, and in this case, it is still possible to draw the major axis of the hemiellipse and mark its center. We can draw the tracing of the patient transverse plane, *t*, or as the ellipse is symmetrical on both sides of the major axis, we can draw the minor axis *n*. The constructions are the same as described above, but the possible posterior lip of the polyethylene cup must also be taken into account.

## CONCLUSION

The position of a total hip prosthesis component is one of the elements which determine the post-surgical prognosis. Using elementary constructions of descriptive geometry and a goniometer, we can easily reposition the cup in space. With two radiographs, one centered on the prosthetic femoral head and a second one on the pubic symphysis, ante- or retroversion of the acetabular cup is easily evaluated.

### *Acknowledgments*

We are grateful to Mrs J. Grimonprez, G. Vandeveldel and Dr A. Declunder for their technical collaboration and to Professor Rooze for the anatomical specimens.

## REFERENCES

1. Ackland M. K., Bourne W. B., Uthoff H. K. Anteversion of the acetabular cup. Measurement of angle after total hip replacement. *J. Bone Joint Surg.*, 1986, 68-B, 409-413.
2. Ali Khan M. A., Brakenbury P.H., Reynolds I. Dislocation after total hip replacement. *J. Bone Joint Surg.*, 1981, 63- B, 214- 218.
3. Anda S., Svenningsen S., Grontvedt T., Bebum P. Pelvic inclination and spatial orientation of the acetabulum. A radiographic, computed tomographic and clinical investigation. *Acta Radiol.*, 1990, 31, 389-393.
4. Delagoutte P., Mainard D., Dupuy M., Peltre G., G'Sel C. Etude des descellements et de l'usure des prothèses totales de hanche. *Rev. Chir. Orthop.*, 1991, 77, 25-33.
5. Fontes D., Benoit J., Lortat-Jacob A., Didry R. La luxation des prothèses totales de hanche. Modélisation mathématique, approche biomécanique. *Rev. Chir. Orthop.*, 1991, 77, 151-162.
6. Ghelman B. Three methods for determining anteversion and retroversion of a total hip prosthesis. *Am. J. Radiol.*, 1979, 133, 1127- 1134.
7. Ghelman B. Radiographic localization of the acetabular component of a hip prosthesis. *Radiology*, 1979, 130, 540-542.
8. Gore D. R., Murray M. P. Gardner G., Sepic S. Roentgenographic measurements after Müller total hip replacement. *J. Bone Joint Surg.*, 1977, 59-A, 948-953.
9. Herrlin K., Petersson H., Selvik G. Comparison of two- and three-dimensional methods for assessment of orientation of total hip prosthesis. *Acta Radiol.*, 1988, 29, 357-361.

10. Lewinnek G. E., Lewis J. L., Tarr R., Compere C. L., Zimmerman J. R. Dislocations after total hip replacement arthroplasties. *J. Bone Joint Surg.*, 1978, 60-A, 217-220.
11. Lokietek W., Legaye J., Bary J. M., De Cloedt P., Trigaux J. L'évaluation radiologique de l'antéversion de la cupule dans les prothèses totales de hanche. *Acta Orthop. Belg.*, 1987, 53, 462-465.
12. Meunier P., Lefevre C., Le Saout J., Kerboul B., Riot O., Meriot P. Une méthode simple de la mesure de l'antéversion du cotyle à partir d'une radiographie de hanche de face. *J. Radiol.*, 1987, 68, 799-804.
13. Mian S. W., Truchly G., Pflum F. A. Computed tomography measurement of acetabular cup anteversion and retroversion in total hip arthroplasty. *Clin. Orthop.*, 1993, 276, 206-209.
14. Thoren B., Sahlstedt B. Influence of pelvic position on radiographic measurements of the prosthetic acetabular component. An experimental study on a pelvic model. *Acta Radiol.*, 1990, 31, 133-136.
15. Visser J. D., Konings J. G. A new method for measuring angles after total hip arthroplasty. A study of the acetabular cup and femoral component. *J. Bone Joint Surg.*, 1981, 63-B, 556-559.
16. Woo R. Y. J., Morrey B. F. Dislocations after total hip arthroplasty. *J. Bone Joint Surg.*, 1982, 64-A, 1295-1306.

## SAMENVATTING

*L. FABECK, D. FARROKH, M. TOLLEY, P. Y. DESCAMPS, M. GEBHART, Ph. DELINCÉ. Meetmethode voor de anteversiehoek van de acetabulumcup.*

Een eenvoudige en praktische methode wordt voorgesteld voor de radiologische meting van de ante- of retroversie van de acetabulumcup. Hiervoor zijn slechts twee radiografieën nodig, één gecentreerd op de femurkop en de andere op de pubis. Geen enkele radiologische uitrusting, compas, conversietafel, wiskundige formule zijn vereist.

De opening van de prothesecup projecteert zich zoals een ellips op de radiografische film. Door het toepassen van beschrijvende geometrische regels, wordt de reële waarde van de anteversiehoek bekomen. De geometrische constructie beperkt zich tot het tekenen van vier lijnen. Adekwate positionering van de goniometer op de radiografie, laat de rechtstreekse aflezing toe van de werkelijke en de vlakke anteversiehoek.

**RÉSUMÉ**

*L. FABECK, D. FARROKH, M. TOLLEY,  
P. Y. DESCAMPS, M. GEBHART, Ph. DELINCÉ.  
Méthode de mesure de l'angle d'antéversion de la  
cupule acétabulaire.*

Une méthode simple et pratique est proposée pour la mesure radiologique de l'anté- ou rétroversion de la cupule acétabulaire. Elle nécessite uniquement deux radiographies, l'une centrée sur la tête fémorale et

l'autre sur la symphyse pubienne. La méthode ne requiert aucun équipement radiologique particulier, ni compas, table de conversion, formule mathématique. L'ouverture de la cupule prothétique se projette comme une ellipse sur le film radiographique. En appliquant des règles de géométrie descriptive, la valeur réelle de l'angle d'antéversion est obtenue. Les constructions géométriques se résument à tracer quatre traits. Le positionnement adéquat sur la radiographie du rapporteur dessiné sur le goniomètre, permet la lecture directe des angles d'antéversion vraie et plane.