

THE FLOATING RADIAL HEAD PROSTHESIS FOR COMMUNUTED RADIAL HEAD FRACTURES : A MULTICENTRIC STUDY

S. SMETS¹, K. GOVAERS², N. JANSSEN³, R. VAN RIET¹, M. SCHAAP¹, F. VAN GLABBEEK¹

We report our experience with the floating radial head prosthesis of Judet for comminuted fractures of the radial head.

We present the results in 15 patients with a mean follow-up of 25.2 months. Thirteen prostheses were inserted for acute Mason III fractures of the radial head, and 2 were inserted for chronic problems after radial head fracture. According to the Mayo Elbow Performance Index there were 7 excellent, 3 good, 1 fair and 2 poor results in the group with acute injuries. In this group, one prosthesis was removed after 8 months for severely decreased elbow function. In the group with chronic problems, there were 2 fair results. There were no dislocations or prosthesis fractures. None of the prostheses showed signs of loosening. Three patients in the acute group developed wrist pain, and in one patient in the chronic group, preexisting wrist pain disappeared after insertion of the radial head prosthesis.

Our short-term results suggest that the floating radial head prosthesis is a suitable solution for early or delayed treatment of Mason type III fractures, either isolated or associated with more complex injuries.

Keywords : radial head ; prosthesis ; replacement ; fracture ; ulnar variance ; elbow degeneration.

Mots-clés : tête radiale ; prothèse ; remplacement ; fracture ; variance cubitale ; arthrose du coude.

The Mason classification (1954) (15) as modified by Johnson (1962) (10) is usually used for radial head fractures. Type I fractures can be treated conservatively. Type II fractures can be treated conservatively or with open reduction and internal fixation. Type III and IV fractures have been treated for a long time with early excision of the radial head. This type of treatment may give acceptable results (6, 7), but may be associated with certain problems: cubitus valgus, proximal migration of the radius, wrist or elbow pain (6, 7, 20, 21).

To try to avoid these problems radial head replacement was developed with varying rates of success (4, 5, 23, 24). The most popular of those was the Swanson silicone radial head prosthesis, despite several reports of fractures (16, 19) and synovitis (8). Carn *et al.* (3) showed that a silicone radial head prosthesis is not able to transfer load from the radius to the capitellum like a normal radial head. For this reason people searched for more rigid radial head prostheses such as the Vitallium radial head prosthesis developed by Knight *et al.* (13) and the cobalt chrome floating radial head prosthesis developed by Judet *et al.* (11).

We present our short-term experience with the floating radial head prosthesis developed by Judet *et al.* (11).

INTRODUCTION

Fractures of the radial head usually result from indirect trauma, i.e. a fall on the outstretched hand with the forearm in semipronation (1). They may be isolated, but are frequently associated with more complex injuries such as dislocations of the elbow and fractures of the proximal ulna.

¹ Department of Orthopedics and Trauma, University Hospital, Antwerp, Belgium

² Department of Orthopedics and Trauma, General Hospital St.-Blasius, Dendermonde, Belgium.

³ Department of Orthopedics and Trauma, General Hospital O.L.V.- Middelares, Deurne, Belgium.

Correspondence and reprints : S. Smets, Department of Orthopedics and Trauma, University Hospital, Wilrijkstraat 10, 2650 Edegem, Belgium

PATIENTS AND METHODS

Between November 1995 and July 1999, 18 floating radial head prostheses (Tornier SA, Saint-Ismier, France) were inserted in three orthopaedic departments : University Hospital of Antwerp, General Hospital O.L.V. Middelaars Deurne and General Hospital Saint-Blasius Dendermonde, Belgium.

After written informed consent, 15 patients agreed to participate in this study. The review of the patients took place after an average follow-up of 25.2 months (range 5 to 48 months). This review consisted of an interview with questionnaire, a physical examination of both wrists and elbows and lateral and anteroposterior radiographs of both wrists and elbows.

In this study we looked for the postoperative clinical and radiographic outcome of the bipolar radial head prosthesis, and we also looked for the development of positive ulnar variance at the wrist and development of wrist pain.

Assessment of elbow performance

We used the Mayo Elbow Performance index (18) (table I) as the scoring system for the clinical outcome of the floating radial head prosthesis. We also used a visual analogue scale for pain at the elbow and for overall patient satisfaction. Radiographic assessment consisted of grading the degenerative changes of the elbow on an anteroposterior and a lateral radiograph of both elbows. The grading system as described by Morrey *et al.* (19) was used (table II.).

Table I. — Mayo Elbow Performance Index (18)

Function	Points	Definition	(Points)
Pain	45	None	45
		Mild	30
		Moderate	15
		Severe	0
Motion	20	Arc > 100 degrees	20
		Arc 50-100 degrees	15
		Arc < 50 degrees	5
Stability	10	Stable	10
		Moderate instability	5
		Gross instability	0
Function	25	Comb hair	5
		Feed	5
		Hygiene	5
		Shirt	5
		Shoe	5
Total	100		

Table II. — Radiographic evaluation of elbow degeneration described by Morrey *et al.* (19)

Grade 1 = normal elbow
Grade 2 = minimum joint narrowing with minimum osteophyte formation
Grade 3 = moderate joint narrowing with moderate osteophyte formation
Grade 4 = severe degenerative changes with gross destruction of the joint

Assessment of wrist pain and ulnar variance

For assessment of wrist pain we used a visual analogue scale in combination with physical examination. The ulnar variance was measured for both wrists on an anteroposterior radiograph of the wrist.

Age and gender

There were 6 men and 9 women with a mean age of 46 years and 5 months (range 20 to 64 years). The right side was involved in 10 patients and the left side in 5. The dominant side was involved in 11 patients.

Type of injury

Thirteen prostheses were inserted for acute injuries. All 13 acute injuries consisted of a Mason type III fracture of the radial head: 4 were isolated fractures, 5 were associated with a posterolateral elbow dislocation, 3 were associated with a fracture of the proximal ulna and one was associated with an avulsion fracture of the capitellum. All acute injuries were treated within 7 days after trauma (fig. 1).

There was one delayed procedure 5 months after a Mason type III fracture of the radial head, because of the development of avascular necrosis of the radial head.

One radial head prosthesis was inserted 3 years, 8 months after excision of the radial head for a Mason type III fracture, because the patient developed wrist pain after the radial head resection.

Operative technique

All implants were inserted through a Kocher lateral approach. All prostheses were floating radial head prostheses (Tornier S.A., Saint-Ismier, France) and were inserted as described by Judet *et al.* (11). Associated fractures were treated simultaneously with open reduction and internal fixation with a plate, except for the avulsion fracture of the capitellum, which was treated conservatively.

Table III. — Detailed overview of clinical and radiographic results

Case	Age (years)	Sex	Side/dominance	Mason type	Associated injuries	Treatment	Follow-up (months)	Motion (F/E/P/S)	Mayo Elbow Perf. Index	Ulnar Var. (mm)	Elbow degeneration (grade)
1	55	F	R/+	III	Elbow dislocation	RHP	32	140/-10/90/90	100	L:1/R:1	L:2/R:2
2	52	F	R/+	III	Elbow dislocation	RHP	9	140/-40/85/90	85	L:0/R:0	L:3/R:3
3	20	F	R/+		Resection of radial head	RHP	16	130/-25/90/90	70	L:0/R:3	L:1/R:3
4	64	F	R/+	III	Avulsion fracture capitellum	RHP	48	135/-5/80/90	85	L:0/R:0	L:1/R:2
5	44	F	L/-	III	AVN radial head	RHP	10	140/-5/90/90	70	L:1/R:1	L:1/R:1
6	48	M	L/+	III	—	RHP	40	140/-10/90/85	100	L:2/R:2	L:2/R:2
7	30	M	R/+	III	—	RHP	29	140/0/85/90	100	L:0/R:0	L:1/R:1
8	56	M	L/-	III	—	RHP	6	140/-5/80/90	100	L:1/R:2	L:1/R:1
9	57	M	L/-	III	Fracture proximal ulna	RHP+ORIF ulna	40	140/-25/0/0	100	L:0/R:-3	L:1/R:1
10	57	M	R/+	III	—	RHP	16	140/-5/80/90	95	L:1/R:1	L:1/R:3
11	30	M	L/-	III	Fracture proximal ulna	RHP+ORIF ulna	9	130/-45/80/80	95	L:1/R:0	L:3/R:1
12	62	F	R/+	III	Fracture proximal ulna	RHP+ORIF ulna	46	140/-10/80/90	85	L:2/R:0	L:1/R:3
13	22	F	R/+	III	Elbow dislocation	RHP	29	128/-30/90/90	50	L:0/R:0	L:2/R:3
14	36	F	R/+	III	Elbow dislocation	RHP	21	120/-20/90/90	70	L:0/R:2	L:1/R:3
15	64	F	R/+	III	Elbow dislocation	RHP	37	130/-5/80/90	70	L:0/R:0	L:1/R:2




Fig. 1a. — Preoperative anteroposterior and lateral x-ray of a Mason type III fracture of the radial head.

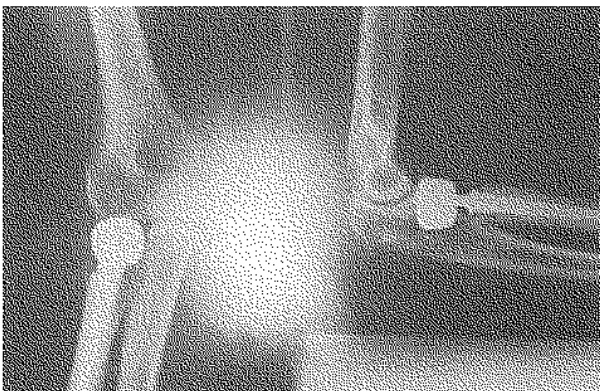


Fig. 1b. — Postoperative anteroposterior and lateral x-ray after treatment with a floating radial head prosthesis.

In 5 patients there was an associated posterolateral elbow dislocation which was reduced in emergency in each patient, followed by the radial head replacement within 7 days. In these patients the lateral collateral ligament was not repaired if damaged.

Postoperative care

Immediate mobilisation under supervision of a physiotherapist was started in all patients. Nonsteroidal anti-inflammatory drugs were used in combination with ice packs.

RESULTS

A detailed overview of the clinical and radiographic results is listed in table III.

Complications

There was one patient with transient posterior interosseous nerve palsy that resolved spontaneously 4 months after injury, and one patient with transient radial nerve palsy who recovered spontaneously within 3 months after injury. In one patient the prosthesis was removed in another hospital after 8 months because of disabling reduction of flexion of the elbow. One patient developed a proximal radioulnar synostosis.

Motion

Active flexion of the elbow ranged from 120 to 140° (mean 135.5°). Extension deficit ranged from 0 to 45° (mean 16.3°). Active pronation ranged from 0 to 90° (mean 79.3°) and supination ranged from 0 to 90° (mean 83°).

Score

According to the Mayo Elbow Performance Index there were 7 excellent results, 3 good, 1 fair and 2 poor results in the group with acute injuries. The radial head prosthesis was removed in one of the two patients with a poor result, after which the result became fair. The two patients with a chronic injury both had a fair result. Radiographic grading of the degenerative changes of the elbow revealed 4 grade 1, 4 grade 2, 7 grade 3 and no grade 4 degenerations. In 8 patients there was an increase in degenerative changes as compared with the contralateral elbow.

Wrist pain and ulnar variance

There were 3 patients who developed wrist pain after insertion of a floating radial head prosthesis. Of those 3 only one had a difference in ulnar variance compared to the other side (case 14 : ulnar variance zero on the left side and + 2 mm on the right side).

There was one patient in whom preexisting wrist pain disappeared after insertion of a floating radial head prosthesis. The wrist pain in this patient had developed after resection of the radial head for a Mason type III fracture.

The ulnar variance ranged from -3 to +3 mm. In our small group of patients there seemed to be no correlation between ulnar variance and wrist pain. There was a difference in ulnar variance in 6 patients compared with the other side. One developed a negative ulnar variance of 3 mm, the other five developed a positive ulnar variance ranging from 1 to 3 mm. Only one of these six patients had wrist pain.

DISCUSSION

According to Amis *et al.* (2) 70% of an axial force applied to the hand passes to the capitellum

as long as the force is in line with the forearm. A lateral component to the force vector causes 100% of the force to pass to the capitellum with tension on the medial collateral ligament. After radial head excision, forces concentrate on the lateral edge of the coronoid process. Medial collateral ligament tension prevents valgus deformity. If the medial collateral ligament is ruptured, excision of the radial head leaves no restraint to valgus deformity, because the radial head is an important secondary restraint to valgus forces and it becomes the main stabiliser if the medial collateral ligament is ruptured. King *et al.* (12) showed that a metallic radial head prosthesis improves the valgus stability in the medial collateral deficient elbow to the same level as with an intact radial head. A silicone radial head prosthesis on the other hand gives almost no improvement in valgus stability. In our study we saw no problems of instability and no redislocations of the elbow after insertion of a floating radial head prosthesis.

Proximal migration of the radius is a known problem following radial head excision. It can give wrist pain due to distal radioulnar joint subluxation (17). There is however no consensus between authors that there is a correlation between the degree of proximal migration and the onset of symptoms of wrist pain (17, 20). In our study only three patients developed wrist pain. Only one had a difference in positive ulnar variance compared to the contralateral side. All three received workers' compensation and had all three either a fair or poor overall result. We have not found other clear explanations for their wrist pain. There was one patient who developed wrist pain after previous radial head excision. This pain disappeared after insertion of a floating radial head prosthesis.

Judet *et al.* (11) saw no radiological changes at the elbow after radial head replacement in their study. We had however a few patients in which there was an increase in degenerative changes. It is not clear whether this was caused by the trauma itself or by the fact that there had been too little bone resection at the radius with overstuffing of the radiohumeral joint.

Judet *et al.* (11) had 2 excellent and 3 good results in their study of acute injuries. Hessmann *et*

al. (9) had 4 good, 7 satisfactory and 2 poor results in their study of acute injuries in 13 patients. Popovic *et al.* (22) had 4 excellent, 4 good, 2 fair and 1 poor results in Mason type IV fractures. Our results are comparable with 7 excellent, 3 good, 3 fair and 2 poor results.

With our experience we believe that the floating radial head prosthesis is a good treatment for Mason type III fracture isolated or associated with fractures of the proximal ulna or elbow dislocations, especially if the medial collateral ligament is disrupted.

Our short-term results (mean follow-up 25.2 months) look promising, and we will continue our follow-up to look for the mid-term and long-term results.

REFERENCES

- Amis A. A., Miller J.H. The mechanisms of elbow fractures: An investigation using impact test *in vitro*. *Injury*, 1995, 26, 163-168.
- Amis A. A., Dowson D., Wright V., Miller J. H. The derivation of elbow joint forces and their relation to prosthesis design. *J. Med. Eng. Technol.*, 1979, 3, 229-234.
- Carr R. M., Medige J., Curtain D., Koenig A. Silicone rubber replacement of the severely fractured radial head. *Clin. Orthop.*, 1986, 209, 259-269.
- Carr C.R. Metallic cap replacement of the radial head. *J. Bone Joint Surg.*, 1971, 53-A, 1661, (abstr.).
- Cherry J. C. Use of acrylic prosthesis in the treatment of fractures of the head of the radius. *J. Bone Joint Surg.*, 1953, 35-B, 70-71.
- Coleman D. A., Blair W. F., Shurr D. Resection of the radial head for fracture of the radial head : long-term follow up of seventeen cases. *J. Bone Joint Surg.*, 1987, 69-A, 385-392.
- Goldberg I., Peylan J., Yosipovitch Z. Late results of excision of the radial head for an isolated closed fracture. *J. Bone Joint Surg.*, 1986, 68-A, 675-679.
- Gordon M., Bullough P. G. Synovial and osseous inflammation in failed silicone rubber prostheses : a report of six cases. *J. Bone Joint Surg.*, 1982, 64-A, 574-580.
- Hessman M., Runkel M., K uchle R., Aue G., Rommens P. M. Comminuted radial head fractures : Can the bipolar head prosthesis (Judet) solve the problem ? *The Elbow-Advances in Biomechanics and Surgical Techniques*. D usseldorf, March 2-5, 2000, Elbow Section of the German Society for Shoulder and Elbow Surgery.
- Johnson G. W. A follow up of one hundred cases of fracture of the head of the radius with review of the literature. *Ulster Med. J.* 1962, 31, 51-56.
- Judet T., Garreau de Loubresse G., Piriou P., Charnley G. A floating radial head prosthesis for radial head fractures. *J. Bone Joint Surg.*, 1996, 78-B, 244-249.
- King G. J. W., Zarzour Z. D. S., Rath D. A., Dunning C. E., Patterson S. D., Johnson J. A. Metallic radial head arthroplasty improves valgus stability of the elbow. *Clin. Orthop.* 1999, 368, 114-125.
- Knight D. J., Rymaszewski L. A., Amis A. A., Miller J. H. Primary replacement of the fractured radial head with a metal prosthesis. *J. Bone Joint Surg.*, 1993, 75-B, 572-576.
- Mackay I., Fitzgerald B., Miller J. H. Silastic replacement of the head of the radius in trauma. *J. Bone Joint Surg.*, 1979, 61-B, 494-497.
- Mason M. L. Some observations on fractures of the head of the radius with a review of one hundred cases. *Br. J. Surg.*, 1954, 42, 123-132.
- Mayhall W. S. T., Tiley F. T. , Paluska D. J. Fracture of silastic radial-head prosthesis: case report. *J. Bone Joint Surg.*, 1981, 63-A, 459-460.
- Mc Dougal A., White J. Subluxation of the inferior radioulnar joint complicating fracture of the radial head. *J. Bone Joint Surg.*, 1957, 39-B, 278-287.
- Morrey B. F., An K. N., Chao E. Y. Functional evaluation of the elbow. In : *The Elbow and its Disorders*, Morrey B. F., Philadelphia, Saunders W. B., 1993, 86-97.
- Morrey B. F., Askew L., Chao E. Y. Silastic prosthesis replacement for the radial head. *J. Bone Joint Surg.*, 1981, 63-A, 454-458.
- Morrey B. F., Chao E. Y., Hui F. C. Biomechanical study of the elbow following excision of the radial head. *J. Bone Joint Surg.*, 1979; 61-A, 63-68.
- Pomianowski S., O'Driscoll S. W., Morrey B. F., Neale P. G., Park M. J., An K. N. The influence of forearm rotation on the laxity and stability of the elbow joint. *The Elbow-Advances in Biomechanics and Surgical Techniques*. D usseldorf, march 2-5, 2000, Elbow Section of the German Society for Shoulder and Elbow Surgery.
- Popovic N., Gillet P., Rodriguez A., Lemaire R. Fracture of the radial head with associated elbow dislocation: results of treatment using a floating radial head prosthesis. *J. Orthop. Trauma*, 2000, 14, 171-177.
- Speed K. Ferrule caps for the head of the radius. *Surg. Gyn. Obstet.*, 1941, 73, 845-850.
- Swanson A. B., Jaeger S. H., La Rochelle D. Comminuted fractures of the radial head : the role of silicone-implant replacement arthroplasty. *J. Bone Joint Surg.*, 1981, 63-A, 1039-1049.

SAMENVATTING

S. SMETS, K. GOVAERS, N. JANSEN, R. VAN RIET, M. SCHAAP, F. VAN GLABBEEK. De bipolaire radiuskopprothese voor comminutieve radiuskopfracturen : een multicentrische studie.

We melden onze ervaring met de bipolaire radiuskopprothese van Judet bij comminutieve radiuskopfracturen.

We geven de postoperatieve resultaten van 15 patiënten met een gemiddelde opvolging van 25,2 maanden. 13 prothesen werden geïmplanteerd voor acute fracturen type Mason III van de radiuskop en 2 werden geïmplanteerd voor chronische problemen na een radiuskopfractuur. Gebruik makend van de Mayo Elbow Performance Index waren er 7 excellente, 3 goede, 1 matig en 2 slechte resultaten in de groep met de acute letsels. In deze groep werd 1 prothese verwijderd na 8 maanden wegens ernstig gedaalde elleboogfunctie. In de groep met chronische letsels waren er 2 matige resultaten. In onze studie was er postoperatief geen luxatie of fractuur van de prothese. Geen enkele prothese toonde tekens van loslating. 3 patiënten in de acute groep ontwikkelden polspijn en bij 1 patiënt in de groep met chronische letsels verdween de polspijn na implantatie van de radiuskopprothese.

Onze korte termijnresultaten suggereren dat de bipolaire radiuskopprothese een goede oplossing is voor vroegtijdige of laattijdige behandeling van Mason type III radiuskopfracturen, zowel bij geïsoleerde fracturen als bij fracturen geassocieerd met meer complexe letsels.

RESUME

S. SMETS, K. GOVAERS, N. JANSEN, R. VAN RIET, M. SCHAAP, F. VAN GLABBEEK. La prothèse flottante de tête radiale dans le traitement des fractures comminutives de la tête radiale : étude multicentrique.

Les auteurs rapportent leur expérience de la prothèse flottante de tête radiale de Judet dans le traitement des fractures comminutives de la tête radiale.

Ils présentent les résultats de 15 patients avec un suivi moyen de 25,2 mois. Treize prothèses ont été implantées pour des fractures de la tête radiale de type Mason III et 2 autres pour des problèmes chroniques secondaires à une fracture de la tête radiale.

En utilisant le Mayo Elbow Performance Index, il y avait 7 résultats excellents, 3 bons, 1 médiocre et 2 mauvais résultats dans le groupe des fractures récentes. Dans ce groupe, une prothèse a été enlevée après 8 mois à cause d'une dégradation sévère de la fonction du coude. Les deux patients opérés pour un problème chronique ont eu un résultat médiocre.

Les auteurs n'ont pas observé de luxation ni de fracture ou de descellement des prothèses. Trois patients dans le groupe des fractures récentes ont développé un douleur du poignet et dans le groupe des problèmes chroniques, une douleur du poignet secondaire à une résection ancienne de la tête radiale a disparu après l'implantation d'une prothèse de la tête radiale.

Ces résultats à court terme suggèrent que la prothèse flottante de tête radiale est une solution acceptable pour le traitement immédiat ou secondaire des fractures Mason type III isolées ou associées à d'autres lésions du coude.