

RADIAL HEAD DISLOCATION WITH PLASTIC DEFORMATION OF THE ULNA IN CHILDREN A RARE AND FREQUENTLY MISSED CONDITION

S. KEMNITZ¹, F. DE SCHRIJVER¹, L. DE SMET¹

Although often reported in the literature, 'isolated' traumatic radial head dislocation in children is a rare condition which has not been studied extensively. There is very often a delay in diagnosis and treatment.

Lincoln and Mubarak described the 'ulnar bow sign' in 1994. They accurately described the plastic deformation of the ulna and explained how to make a correct diagnosis from the radiographs. Probably most 'isolated' radial head dislocations in children are associated with plastic deformation of the ulna as stated in 1984 by Dubuc et al. (2). The recognition of these "plastic" Monteggia fractures is mandatory, as action on the ulna plays a central role in the treatment. On the other hand, the 'ulnar bow sign' may be used to detect subtle changes in the position of the radial head.

We present 4 cases of chronic radial head dislocation associated with plastic deformation of the ulna. Open reduction of the radial head and reconstruction of the annular ligament was performed. An osteotomy of the ulna was deemed necessary in 3 cases.

Keywords : radial head dislocation ; Monteggia fracture ; ulnar bow sign ; plastic deformation ; elbow.

Mots clés : luxation de la tête radiale ; fracture de Monteggia ; déformation plastique de l'ulna ; coude.

INTRODUCTION

Dislocations of the elbow in children occur in only 6% of all injuries around the elbow. In this group, traumatic radial head dislocations are very rare and mostly associated with a fracture of the ulna (Monteggia fracture). So-called 'isolated' radial head dislocations are extremely rare and often missed in the emergency room (1-4). There are

numerous reports in the literature describing isolated radial head dislocation (1-4, 6, 9, 11, 13, 15). One report accurately described the plastic deformation of the ulna and provided a useful diagnostic tool: the ulnar bow sign (8). A line drawn on the posterior border of the ulna, from the olecranon to the distal metaphysis of the ulna on a lateral radiograph of the elbow, normally intersects with the ulnar diaphysis, because of the physiological posterior bowing of the ulna. If there is plastic deformation of the ulna, the ulnar diaphysis deviates more than 1 millimetre from this line

Lincoln and Mubarak hypothesize that all 'isolated' radial head dislocations in children are in fact associated with plastic deformation of the ulna. When treating a child with radial head dislocation and plastic deformation of the ulna, the surgeon should address both problems.

MATERIAL AND METHOD

Four children with chronic anterior dislocation of the radial head and plastic deformation of the ulna were seen. The average age at injury was six years (range: five to seven years). There were two girls and two boys. The average delay to correct diagnosis was three months (range: six weeks to five months). One boy previously had an open reduction and repair of the annular liga-

¹ Department of Orthopaedic Surgery, U.Z. Pellenberg, Weligerveld, 1, B-3212 Lubbeek (Pellenberg)

Correspondence and reprints : Luc De Smet, Department of Orthopaedic Surgery, University Hospital of Pellenberg, Weligerveld 1, 3212 Lubbeek (Pellenberg)

ment, but the radial head dislocated again in the immediate postoperative period. The ulnar bow sign was positive in all 4 patients.

Open reduction of the radial head was performed in all 4 patients. The radial head was found buttonholed through the annular ligament in one patient and the annular ligament could be repaired. In the other three patients, the annular ligament was reconstructed using a lateral slip of the triceps fascia (5). In one patient the deformity of the ulna was minor, the reduction of the radial head was stable and osteotomy of the ulna was not performed. In the other three patients, an opening wedge osteotomy of the proximal ulna was judged necessary. The osteotomy was stabilised with an angulated plate and screw fixation. In all 4 cases, the reduction was protected with a transarticular K-wire from the capitulum into the radius. An above-elbow plaster was applied in all cases for a period of three to eight weeks, at which stage the K-wires were removed.

RESULTS

We had no complications and all three ulnar osteotomies healed perfectly. On the postoperative radiographs, the radial head was anatomically reduced in all cases. Normal elbow function with full flexion, extension, pronation and supination was recovered after six to twelve months in three children. The patient who had open reduction of the radial head and reconstruction of the annular ligament without osteotomy of the ulna regained full flexion and extension but pronation and supination remained limited: at two years follow-up the pronation lacked 25° and the supination 10°.

DISCUSSION

Traumatic radial head dislocations in children are very rare (2, 3, 6, 11, 13, 15). They are probably in most cases associated with plastic deformation of the ulna. These plastic types of Monteggia fractures can easily be detected if one uses two criteria to evaluate the radiographs of an injured elbow: the radiocapitular line and the ulnar bow sign (fig. 1).

This is a typical history of a young child who falls on the outstretched hand and injures his elbow. In the emergency room the child refuses to move the arm and complains of pain in the elbow. The

arm is kept in slight flexion and pronation. Usually it is not possible to obtain good AP and lateral radiographs. No obvious injuries are usually noted and the child is dismissed with a collar and cuff and analgesics. The parents are told that the child should be re-examined in a couple of days if the pain does not subside. But often the pain does subside after a few days and the child starts to use his arm again. All that is left is a minor loss of range of motion, especially in supination. Because of persisting limitations, new radiographs are taken later on. The radial head dislocation then becomes obvious.




Fig. 1. — Bilateral lateral radiograph of the elbow: On the right side (above) the dislocation of the radial head is easy to detect, using the radiocapitular line (A). On the same radiograph the ulnar bow sign indicates the plastic deformation of the right ulna (B).

A good AP and lateral radiograph of the elbow is mandatory in every case. If this is not possible because of pain, the patient should be reviewed later. On the AP and lateral view a line drawn through the axis of the radius should always run through the capitulum (6). If this is not the case, the radiohumeral joint is distorted. An AP and lateral view of the entire ulna and radius should be taken to exclude a Monteggia fracture. The ulnar bow sign (8) is a very useful tool to detect a plastic deformity of the ulna. This plastic deformity of the ulna has to be corrected as well or the dislocation will recur. The ulnar bow sign should be checked in every child with elbow trauma. Differential diagnosis must be made with:

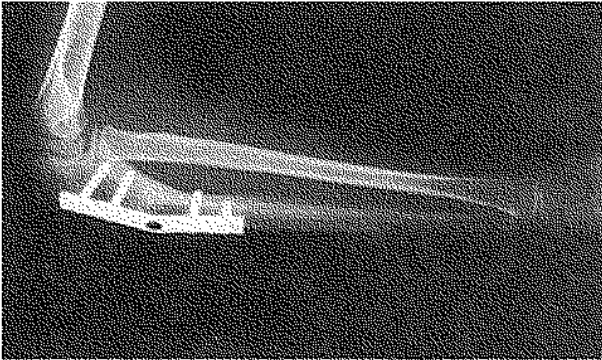


Fig. 2. — Lateral radiograph of an elbow after osteotomy of the ulna, stabilised with a plate and screw fixation. The radial head is reduced and the physiological ulnar bowing has been restored.

Congenital dislocation of the radial head :

Congenital radial head dislocation is usually bilateral. It is present at birth. There is no history of trauma or acute onset of pain. Usually the capitulum is hypoplastic and the ulnar condyle is prominent. The radial head is domeshaped and the neck is long and narrow (6, 9). The problem is that all of these changes may occur in a chronic dislocated radial head as well.

Pulled elbow "Pronation douloureuse" :

Usually these children are younger and the pain is less severe. The radial head is often reduced during the positioning in the radiology department. If not, gentle supination and direct pressure over the radial head will reduce the radial head and the pain will subside quickly. The normal position of the radial head must be visualised on a good AP and lateral radiograph of the elbow. If this is not possible, the child must come back after a couple of days.

Monteggia fracture :

If a radial head dislocation is seen on the radiograph of the elbow, a radiograph of the complete ulna and radius is mandatory.

If a plastic Monteggia fracture is diagnosed, closed reduction of the ulna under general anaesthesia may correct the deformity in the acute situation. Slight overcorrection of the deformity during manipulation is advised and usually the ulna must

be fractured in order to achieve this (4, 7). Usually the mechanism of injury is a hyperextension pronation injury (6, 15). The classical manoeuvre for reduction is supination-flexion for an anterior dislocation and pronation-flexion for a posterior dislocation (6, 13, 15).

Classically the arm is kept in flexion and supination in the plaster (3, 11, 13), because the distance between the ulna and the radius is the highest in supination and the interosseous membrane is under maximal tension. A recent study by McDonald *et al.* (10) has shown that pronation can also be used to achieve and maintain the reduction. Probably the neutral position is the safest position and should be sufficient to keep the reduction if the ulna is corrected sufficiently. This position has the lowest risk of causing restriction of pronation or supination and is therefore recommended (4, 7). Three to four weeks of plaster immobilisation should suffice and early mobilisation is recommended (6,13,15).

No immediate treatment and late excision of the radial head is reserved only for chronic cases with deformities of the radial head or radiohumeral joint (5).

The deformity of the ulna must be addressed (1, 12, 14). Through a lateral incision a corrective opening wedge osteotomy of the proximal ulna is performed and a plate and screw fixation is used (4). The plate is bended to 15° (1, 4) (fig. 2). Once the ulna is corrected, the radial head should 'fall' into its normal position. At this stage additional reconstruction of the annular ligament with a strip of the triceps is possible but may be dispensed with. A plaster cast is applied for three weeks, following which the K-wire should be removed and early mobilisation should be started.

Open reduction of the radial head without osseous correction of the ulnar deformity is no longer considered as an appropriate treatment (1, 12, 14).

REFERENCES

1. Bouyala M., Bollini G., Jacquemier M., Chrestian P., Tallet J.M., Tisserand P., Moutet A. Le traitement des luxations anciennes de la tête radiale chez l'enfant par l'ostéotomie haute du cubitus. *Rev. Chir. Orthop.*, 1988, 74, 173-182.

2. Dubuc J.E., Rombouts J.J., Vincent A. Les luxations de l'extrémité proximale du radius chez l'enfant. Acta Orthop. Belg., 1984, 50, 815-836.
3. Hamilton W., Parkes J.C. Isolated dislocation of the radial head without fracture of the ulna. Clin. Orthop., 1973, 97, 94-96.
4. Hirayama T., Takemitsu Y., Yazuhide Y., Mikita A. Operation for chronic dislocation of the radial head in children. J. Bone Joint Surg., 1987, 69-B, 639-642.
5. Hresko M.T., Rosenberg B.N., Pappas A.M. Excision of the radial head in patients younger than 18 years. J. Ped. Orthop., 1999, 19, 106-113.
6. Hudson D.A., De Beer J. Isolated traumatic dislocation of the radial head in children. J. Bone Joint Surg., 1986, 68-B, 378-381.
7. Inoue G., Shionoya K. Corrective ulnar osteotomy for malunited anterior Monteggia lesions in children. Acta Orthop. Scand., 1998, 69, 73-76.
8. Lincoln T.L., Mubarak S.J. Isolated traumatic radial head dislocation. J. Pediatr. Orthop., 1994, 14, 454-457.
9. Lloyd-Roberts G.C., Bucknill T.M. Anterior dislocation of the radial head in children. J. Bone Joint Surg., 1977, 59-B, 402-407.
10. McDonald J., Whitelaw C., Goldsmith L.J. Radial subluxation: comparing two methods of reduction. Acad. Emerg. Med., 1998, 69, 715-718.
11. Rombouts J.J., Dubuc J.E. Les luxations de la cupule radiale chez l'enfant. Louvain Médical, 1992, 111, 77-81.
12. Tajima T., Yoshizu T. Treatment of long standing dislocation of the radial head in neglected Monteggia fractures. J. Hand Surg., 1995, 20-A, S91-S94.
13. Vesely D.G. Isolated traumatic dislocation of the radial head in children. Clin. Orthop., 1967, 50, 31-36.
14. Von Laer L., Pirwitz A., Hasler C.C. Late Monteggia fractures. Techn. In Orthop., 2000, 15, 27-29.

SAMENVATTING

S. KEMNITZ, F. DE SCHRIJVER, L. DE SMET.
Geïsoleerde radiuskop luxatie bij kinderen: een zeldzame en vaak gemiste diagnose.

Ondanks meerdere publicaties blijft de "geïsoleerde" luxatie van de radiuskop bij kinderen zeldzaam. De diagnose wordt vaak laatstijdig gesteld. In 1994 beschreven Lincoln en Mubarak het "ulnar bow" teken. Zij beschreven correct de plastische deformatie van de

ulna en hoe de radiografieën dienen te worden geïnterpreteerd. Zoals Dubuc in 1984 reeds aanhaalde, zijn waarschijnlijk alle zogenaamde geïsoleerde luxaties van de radiuskop geassocieerd met een plastische deformatie van de ulna. Het herkennen van deze plastische Monteggia is primordiaal, gezien de behandeling van de ulna deformatie van essentieel belang is. Anderzijds is het "ulnar bow" teken een manier om sublaxaties van de radiuskop te ontdekken.

Wij beschrijven 4 zo'n gevallen, heelkundig behandeld. In 3 ervan werd een ulna osteotomie nodig geacht.

RESUME

KEMNITZ S., DE SCHRIJVER F., DE SMET L. Fracture «isolée» de la tête radiale chez l'enfant associée à une déformation plastique de l'ulna, une lésion rare et souvent méconnue.

La luxation traumatique «isolée» de la tête radiale chez l'enfant est une lésion rare, souvent rapportée dans la littérature mais qui a été peu étudiée. Elle est en fait généralement associée à une déformation plastique de l'ulna, également d'origine traumatique. On note fréquemment un retard dans le diagnostic et le traitement. Lincoln et Mubarak ont décrit en 1994 le signe de l'incurvation ulnaire. Ils ont décrit de façon précise la déformation plastique de l'ulna et ont expliqué comment poser le diagnostic à partir des radiographies. La plupart des fractures «isolées» de la tête radiale chez l'enfant sont probablement associées à une déformation plastique de l'ulna, comme l'avaient suggéré en 1984 Dubuc et coll. La reconnaissance de ces fractures de Monteggia avec déformation plastique est essentielle, car la correction de la déformation de l'ulna joue un rôle essentiel dans le traitement. D'autre part, le signe de l'incurvation ulnaire peut permettre de détecter des modifications subtiles dans la position de la tête du radius.

Les auteurs présentent 4 cas de luxation chronique de la tête radiale, associée à une déformation plastique de l'ulna. La tête radiale a été réduite à ciel ouvert, le ligament annulaire a été reconstruit et une ostéotomie de l'ulna a été jugée nécessaire dans trois cas.