

Can we DAIR in FRI ? Debridement techniques in osteomyelitis

J. NEYT¹, J. VICTOR², O. CORNU³

¹Head of Clinic, Bone and Soft Tissues Infection Unit, University Hospitals of Ghent, Belgium; ²Head of Service, Department of Orthopaedic Surgery and Traumatology, University Hospitals of Ghent, Belgium; ³Head of Service, Department of Orthopaedic Surgery and Traumatology, University Hospitals of Catholic University of Louvain, St-Stevenswoluwe, Belgium.

Correspondence at: Jeroen GV Neyt, Dept of Orthopaedic Surgery, C Heymanslaan 10, 9000 Ghent. Tel.: +32 9 3321258
Email: jeroen.neyt@uzgent.be

The concept of Debridement, Antibiotics and Implant Retention (DAIR) is well known in periprosthetic joint infections. Extrapolating this concept to fracture related infections is mired in controversies. Characteristics of the metal implant, duration of infection, state of fracture healing, microbiological profile etc. appear to play a role in the decision making process whether or not to keep, adjust, exchange or remove (infected) metalwork. More than likely it is the quality of source control by meticulous debridement having a major impact whether a DAIR approach to FRI could result in a successful outcome.

INTRODUCTION

In light of the keynote lectures given at the Annual Meeting of the SOBCOT/BVOT, a session had been dedicated to fracture-related infections on Friday the 28th of April, 2023. Appropriate diagnosis making and the choice of treatment strategies remain challenging in fracture-related infections (FRI). This paper aims to review present research and insights to date. Already presented at the BVOT Convention in Oostend in 2019, an important seminal twin publication provides a very good framework to start off with^{1,2}. Even in light of the observation that closed fractures end up with an infection in a mere 1-2%, the latter results in prolonged hospital stay, additional surgical procedures and costly investigations^{3,4}. For open fractures the outcome is definitely dire in terms of morbidity and return to work⁵. Additionally, fracture treatment increasingly relies on metal fixation even in an elderly frail population, hence FRI rates are on the upward trend^{6,7}. Antimicrobial resistance is on the rise and rightly declared by the WHO as a worldwide existential risk⁸.

DISCUSSION

Outlining the risk of secondary infection in fracture fixation

The Gustilo-Anderson classification for open fractures still stands robustly⁹. Fractures in the

proximal and distal tibia are reputed for a reason. The soft tissue envelope in a multi-trauma, combat, blast, terror setting or in a previously irradiated zone is suboptimal and the risk for infected non-unions after fixation of open fractures easily doubles. Further, diabetes, elderly age, IV drug abuse and even social class are patient-related risk factors at acute trauma presentation¹⁰. Some risk factors however can be mitigated such as timely administration of antibiotics within 6 hours in open fractures combined with a thorough debridement¹¹. Also smoking cessation definitely aids in reducing fracture-related infections¹². The findings of the seminal papers on biofilm behavior by Bill Costerton et al.¹³ as well as by Anthony Gristina¹⁴ could readily be applied on metalwork in fracture fixation¹. Host defences faced with a foreign body and germ inoculation trigger a cytokine cascade resulting in additional tissue damage. Leucocytes produce TNF-alpha, IL-1 and IL-6 which in turn stimulate osteoclasts via a RANK mechanism leading ultimately to mechanical failure¹⁵. Surface topology, chemical composition, charge physics and hydrophobicity play a role but there are no superior infection-free fixation materials yet¹⁶. The presence of internal dead space by e.g. the use of cannulated nails and screws and disruption of the overlying viable soft tissues do not forbode well. Fracture instability though is a ticket for FRI development due to disruption of revascularity efforts and dead space¹⁷ (Fig. 1 with permission).

Classification of FRI

Several attempts to classify fracture-related infection have been developed related to time period after index procedure, the route of infection, clinical severity and status of healing amongst others¹⁸. Authors postulated that time of presentation of the FRI correlated with a distinct microbiome i.e. early/acute within 2 weeks more prevalence of Staph Aureus, Gram Negative microbes and Strept Pyogenes , delayed presentation (3-10 weeks) with Coagulase negative Staphylococci and late onsets (after 10 weeks) with Staph Aureus, Staph Epidermidis and Pseudomonas Aeroginosa¹⁹ but lately this division has been questioned²⁰. In the beginning of our third millennium Cierny et al and McPherson et al published a classification based on systemic conditions and local factors for FRI respectively PJI dividing FRI patients cohort in Host Types A (good), B and C (bad)^{21,22}. In 2019 the Oxford Group proposed the BACH classification for osteomyelitis of long bones with four key variables (B one involvement, A ntimicrobial option, C overage by soft tissue, H ost status) with a traffic light banding²³. However it is the multicenter research project by

Metsemakers et al. in 2018 that finally put the definition of FRI on center stage²⁴.

Treatment strategies for Fracture-related Infection

Underpinning a successful outcome are four pillars namely eradication of infection, guidance of fracture healing , preservation of limb function and prevention of infection relapse²⁵. For this purpose, achieving mechanical stability is the key along optimization of the nutritional status and remediation of co-morbidities. Knowledge about the metal implant type, the presence of bone defects and joint involvement should aid in evaluating the response to treatment²⁶. Despite a very helpful paper by Depypere et al about strategies to retain (DAIR), remove or exchange metal implant(s), there is still a paucity of high quality studies because of all the variables in play such as implant type, construct stability, challenges to assess fracture consolidation, anatomical location, soft tissue quality, debridement options , time period between fracture fixation and FRI remedial surgery²⁷. Prada et al. interestingly stated as well that the risk for an FRI did rather depend on the time delay between injury and arrival in a trauma center²⁷.

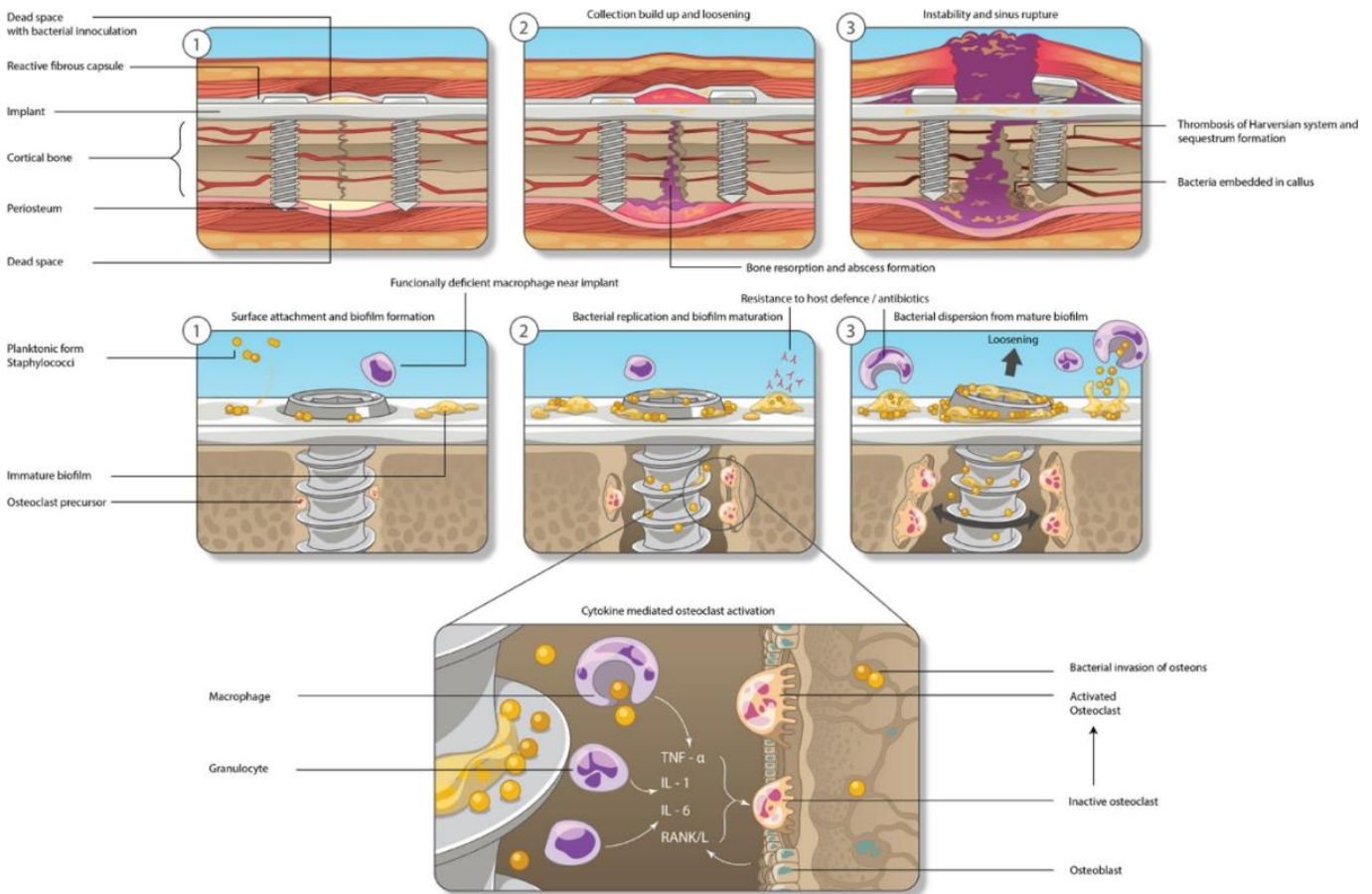


Fig. 1 — High definition slide or pdf - from Fang et al.¹

In acute FRI (25%) it is critical to differentiate between superficial versus deep surgical site infection, to pick up deep collections by means of US or CT²⁸. In superficial instances, treatment strategy could consist of empirical IV antibiotic administration whilst with persistent wound discharge or breakdown or in the presence of collections, the implant might be retained on condition of a thorough debridement combined with antimicrobials (DAIR). In the time period of 3 to 10 weeks after fracture fixation, a DAIR procedure should result in fracture consolidation in approximately 70% of cases and in infection eradication in 50% with a strategy to eventually remove the metalwork at fracture healing state. Failure after DAIR relates to smoking, diabetes mellitus, other significant co-morbidities, in open fracture settings and in *Pseudomonas Aeruginosa* infections. In failure, the best strategy is to remove metalwork and replace with an external fixator system²⁹. In late FRI (more than 10 weeks after the index fracture fixation) with delayed union, fracture stability cannot be achieved by bracing or other conservative means. Surgical strategy relies on removal of (loosened) metalwork and sequestrum and application of an external fixator. If the latter is not possible, the use of stable bridging implants is recommended. In up to 40%, the FRI can be eradicated whilst fracture union subsequently occurs in 66 to 100% of cases³⁰. If and when the diagnosis of an FRI is made in a presumably consolidated fracture setting, union is best assessed by means of a CT scan with Metal Artefact Reduction Sequencing software. Removal of the implant and deep biofilm sampling for culturing is the preferred strategy³¹. A prospective clinical trial study on 229 FRI patients in Basel found that with early FRI's, a DAIR procedure was chosen in 86% of cases (failure rate 14%). In the delayed (3-10 weeks) cohort, fifty-eight percent of cases underwent DAIR surgery (failure 12%). Only in 10% of late cases was a DAIR procedure carried out at a price of 33% of failure related to low virulent and anaerobic germs. The authors advised to limit a DAIR option to a time period of maximum 10 weeks after FRI presentation. Unknowns such as bone viability, construct stability and correct assessment of soft tissue quality remain hence the importance to involve the multidisciplinary team with vascular and plastic surgeons, members of infectiology and microbiology and nutritional teams³². Defining FRI is one challenge, defining success of FRI treatment with DAIR is another. A Dutch group of trauma surgeons made an attempt by stating that fracture consolidation should be present once the ossified callus bridged at least

three cortices on radiographs combined with a stable and painless bone construct at attempted angulation on clinical examination. These criteria combined with the observation of resolving signs and symptoms of infection should establish primary success of the DAIR strategy³³.

Techniques of Debridement

There is a very good reason why the Dominique-Jean Larrey Award is the NATO's highest medical honour bestowed annually by the Chiefs of Military Medical Services. Dr Larrey was an exemplary surgeon of the Napoleonic era who developed the concept of debriding or rather decompression or disentangling tight fascial compartments³⁴. It is only from the First World War that the term -mistakenly seen as based on the French word *débris*- developed into the surgical procedure of removal of nonviable and foreign material from the wound³⁵.

The abbreviation IDDI in particular refers to the combination of I ncision, D rainage, D ebridement and I rrigation instead of routinely using the term 'wash-out'³⁶. Biofilm stuck on surfaces cannot just be washed away just the same as algae and plants on rocks in a fast flowing river³⁷. At the DAIR debridement stage, a thorough survey and assessment of the metalwork is required by testing, pushing and pulling loose metal components and by evaluation of biofilm build up under plates, in screw heads, inside nails. Screw trajectory management deserves special attention i.e. after sequential loosened screw removal, the screw tunnel is to be curetted, cleaned and over drilled and then again filled with new larger or cancellous screws. Alternatively, hitherto empty plate holes could be utilized. Anyway, implant construct and fracture stability is paramount and -if in any doubt- removal of internal metalwork should be followed by application of an available external fixation system²⁵. Reducing the biofilm burden ('the source control') is achieved by Me-blue identification and removal of devitalized tissue, debris, scar, pus pockets and cavities and literally surgically brushing the metalwork with respect to healthy skin and soft tissue at wound margins³⁸. The 'paprika' sign should aid to delineate healthy vital bone from dead structures in a limb without tourniquet use but picking up this sign is not always reliable to distinguish. An intra-operative fluorescence imaging technique derived from maxillofacial cancer surgery might assist³⁹. Even a proper debridement might fail to reach out to 'the micro-cavities and cracks in bone' in which germs hide and even duplicate, waiting for the right

time and friendly circumstances to emerge again (Fig. 2 with permission).

Irrigation

Although the last letter of IDDI refers to irrigation, a second survey later might still follow and the cycle repeated. It is important to utilize warm normal saline solutions at low pressure to avoid bacterial seeding into the tissues⁴⁰. Out of the FLOW (Fluid Lavage Open Wounds) trial the message came loud and clear not

to use soap or antibiotic solutions in (open) fractures i.e. the solution to pollution is dilution in combination with thorough debridement techniques⁴¹ but the copious and repeated use of vacuum-assisted closure techniques in this trial has been rightly questioned by Parham and McNally⁴². Mounting evidence indeed demonstrates that prolonged use of VAC's or NPWT potentially induces the FRI to become 'longer and stronger'^{20,43}.

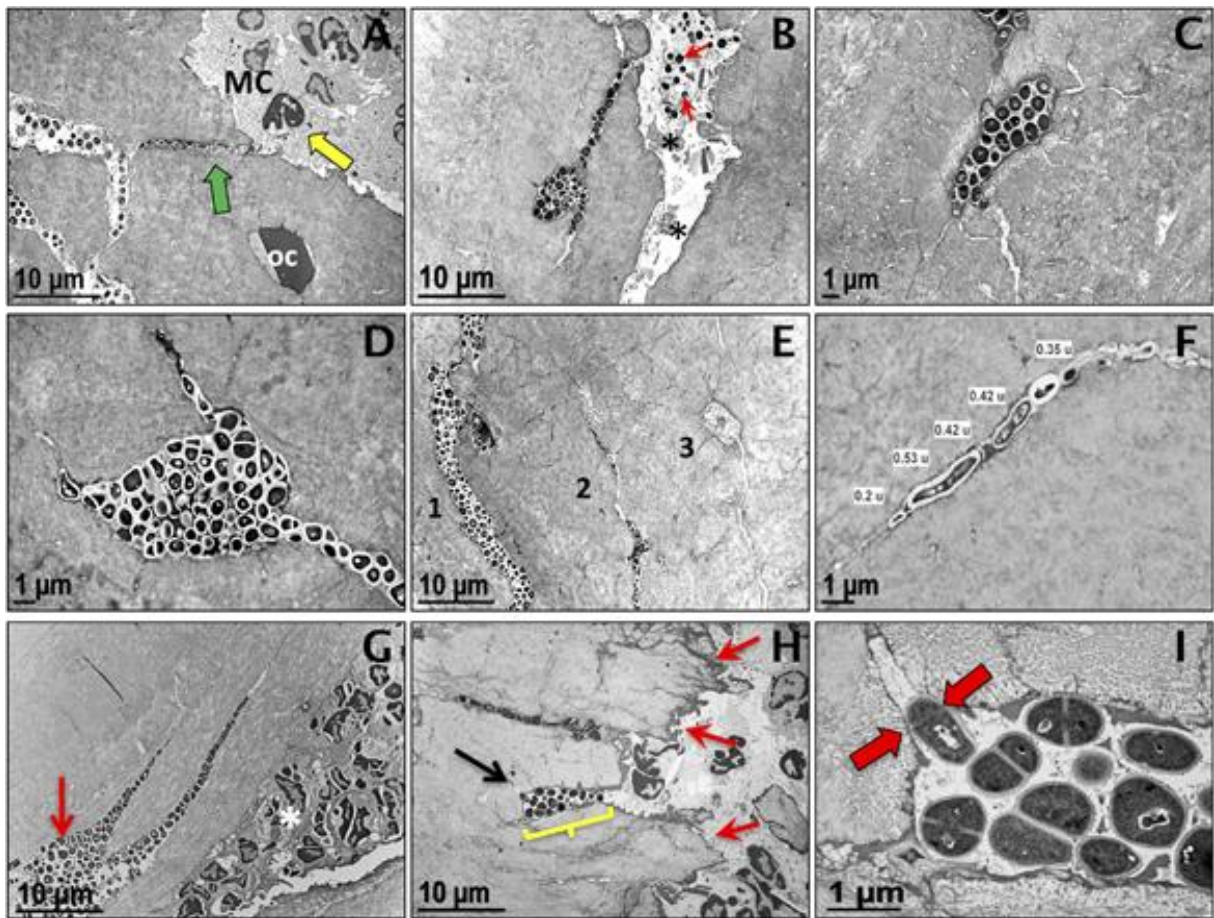


Fig. 2 — TEM evidence of submicron-elongated *S. aureus* in the osteocytic lacunar-canalicular network of infected live bone tissue. Long bones from mice ($n = 5$) infected with a UAMS-1-contaminated tibial pin (A–F, H, I), or a USA300-infected femoral osteotomy (G), were harvested on day 14 postinfection for TEM. (A) Low magnification TEM image ($\times 4000$) of UAMS-1 invasion of live bone tissue (note osteocyte OC) in a canaliculus (green arrow) communicating with the marrow cavity (MC). Also note the proximal neutrophils (yellow arrow) within the marrow. (B) Low magnification TEM image ($\times 4000$) of UAMS-1 invasion of an osteocytic lacunar-canalicular adjacent to a channel infected with *S. aureus* (arrows) containing necrotic cells (*). Higher magnification TEM images (C: $\times 8000$; D: $\times 10,000$) of UAMS-1 colonization of osteocytic lacunae. (E) Low magnification TEM image of three parallel canaliculi in various states of colonization (1: severely infected; 2: moderately infected; and 3: uninfected) by the invading UAMS-1 within the live cortical bone ($\times 3500$). (F) Higher magnification TEM image measuring submicron-elongated UAMS-1 ($\times 15,000$). (G) Similar bacterial invasion of canaliculi adjacent to the osteotomy (red arrow), and neutrophils in the marrow cavity (*) were observed in USA300-infected femurs ($\times 4000$), but not in long bones that received sterile implants (data not shown). (H) Low magnification TEM image ($\times 4000$) documenting cortical bone damage adjacent to the infected tibia pin (red arrows), and a cavity filled with UAMS-1 (yellow bracket) that leads to a canaliculus (black arrow). (I) High magnification TEM of the infected cavity in H demonstrating mitotic *S. aureus* in the live cortical bone ($\times 25,000$). Note that only the bacterium entering the canaliculus has an asymmetric septal plane (red arrows), which is aligned perpendicularly with the canaliculus orifice, perhaps to anchor and propel the emerging daughter cell into the submicron channel in the cortical bone during binary fission.

When to convert a DAIR set up to an External Fixator System

Failure of infection control even with repeated IDDI cycles in combination with adverse local and systemic factors may necessitate a conversion apart from inability to achieve fracture stability with internal metalwork. Once microbial source control is obtained, one could convert fixation back again to an internal construct if desired^{44,45}.

The use of local antimicrobial therapy with DAIR strategies for FRI

Although en vogue and common practice, there is not yet strong evidence available. Local application like in PJI does not seem to produce clinically important systemic toxicity. The use of 'bone cement' or PMMA (Polymethylacrylate) whether in situ, around rods or instead of bone defects like in the Masquelet technique requires some particular attention if mixed with antibiotics. The PMMA cures hot in an exothermic reaction hence best water soluble antibiotics and preferably without vacuum mixing e.g. 40 g PMMA could be mixed with 4 g of Vancomycin and/or 2 g of Gentamycin. In light of the elusion of these antibiotics out of the outer mantle, there is a limited time span on MIC efficacy hence the requirement to combine with high dose systemic antibiotics^{27,46}. Casiraghi et al. found that in FRI of the pelvis and acetabulum, bio-absorbable anti-biotic-loaded calcium sulfate beads could be utilized successfully if combined with serial IDDI cycles⁴⁷.

Outcome of DAIR strategies

A systematic review by Morgenstern et al. involved six studies and 276 patients stating that a DAIR procedure carried out within the first 3 weeks could achieve success in 86 to 100%, within three to ten weeks 82 to 89% and after 10 weeks 67%. However, the authors felt that in these reviewed studies there were issues such as problematic differentiation between early and late onset of the FRI, problems with sample sizes and FRI definitions as well as rather low quality methodology⁴⁸.

A multi-center study in the Netherlands involving 141 patients showed that there was a 18% recurrence of the FRI within two years in early onset presentation. Further, in 52% of patients more than two surgical remedial procedures were needed⁴⁹. A much larger patient cohort in trauma centers in the UK and the Netherlands was analyzed by McNally et al. involving 433 patients with FRI. Fracture union was achieved in 86%, infection eradication

in 87% of cases and amputation was only needed in 3.3% with a combined strategic approach. Using a VAC resulted in a recurrence of infection. Local antibiotics brought relapse numbers down from 19% to 10%. Interestingly, the success of a DAIR procedure did not depend on the time period since fracture fixation or FRI presentation but rather on appropriate soft tissue cover and the use of local antibiotics. A properly carried out multimodal DAIR strategy resulted successfully in 79% of cases. However, whenever loosened or broken metalwork or broken skin integrity was present, the DAIR outcome would be a failure²⁰.

Summary of evidence for DAIR strategies

Legend : quality of evidence (good, fair, poor)
strength of recommendation (strong for, weak for, weak against, strong against)

- Tailor your strategy according to patient's case and supervised by multidisciplinary team. Unclear about required duration of antibiotic cure (poor, weak for)
- DAIR can be effective, especially if the FRI duration is short (poor, weak for)
- Local antibiotics in whatever format can be effective (poor, weak for)
- Oral antibiotics can be as effective as intravenous ones (good, strong for)²⁷.

Conclusions and take home messages

- *soft-touch surgeons create smelly sores
- *proper IDDI (incision, drainage, debridement and irrigation) makes tidy
- *consider serial TIDDI for pelvic/acetabular FRI
- *be kind to viable tissues
- *the solution to microbial pollution is low-pressure dilution
- *fix the FRI by stable fracture fixation
- *better FLAP than VAC
- *be aware of the characteristics of the bacterial bioburden
- *antibiotics do not replace sloppy surgery.

This paper has been presented in the Key Note Session on FRI on the 28TH of April, 2023 at the Annual SOBCOT/BVOT meeting in Brussels.

REFERENCES

1. Fang C, Wong TM, Lau TW, To KK, Wong SS, Leung F. Infection after fracture osteosynthesis - Part I. J Orthop Surg (Hong Kong). 2017;25(1):2309499017692712.
2. Fang C, Wong TM, To KK, Wong SS, Lau TW, Leung F. Infection after fracture osteosynthesis - Part II. J Orthop Surg (Hong Kong). 2017;25(1):2309499017692714.

3. Trampuz A, Zimmerli W. Diagnosis and treatment of infections associated with fracture-fixation devices. *Injury*. 2006;37(2):S59-S66.
4. Darouiche RO. Treatment of infections associated with surgical implants. *New England Journal of Medicine*. 2004;350(14):1422-9.
5. Napierala MA, Rivera JC, Burns TC, Murray CK, Wenke JC, Hsu JR, et al. Infection reduces return-to-duty rates for soldiers with Type III open tibia fractures. *Journal of Trauma and Acute Care Surgery*. 2014;77(3):S194-S7.
6. Mellstrand-Navarro C, Pettersson H, Tornqvist H, Ponzer S. The operative treatment of fractures of the distal radius is increasing: results from a nationwide Swedish study. *The bone & joint journal*. 2014;96(7):963-9.
7. Ktistakis I, Giannoudi M, Giannoudis PV. Infection rates after open tibial fractures: are they decreasing? *Injury*. 2014;45(7):1025-7.
8. Zanichelli V, Sharland M, Cappello B, Moja L, Getahun H, Pessoa-Silva C, et al. The WHO AWaRe (Access, Watch, Reserve) antibiotic book and prevention of antimicrobial resistance. *Bull World Health Organ*. 2023;101(4):290-6.
9. SPREAD H. Prevention of infection in the treatment of one thousand and twenty-five open fractures of long bones. *J Bone Joint Surg Am*. 1976;58:453-8.
10. Bachoura A, Guitton TG, Smith RM, Vrahas MS, Zurakowski D, Ring D. Infirmary and injury complexity are risk factors for surgical-site infection after operative fracture care. *Clinical Orthopaedics and Related Research*. 2011;469:2621-30.
11. Penn-Barwell J, Murray C, Wenke J. Early antibiotics and debridement independently reduce infection in an open fracture model. *The Journal of Bone and Joint Surgery British volume*. 2012;94(1):107-12.
12. Soni A, Vollans S, Malhotra K, Mann C. Association between smoking and wound infection rates following calcaneal fracture fixation. *Foot & Ankle Specialist*. 2014;7(4):266-70.
13. Costerton JW, Lewandowski Z, Caldwell DE, Korber DR, Lappin-Scott HM. Microbial biofilms. *Annual review of microbiology*. 1995;49(1):711-45.
14. Gristina AG. Implant failure and the immuno-incompetent fibro-inflammatory zone. *Clinical Orthopaedics and Related Research*. 1994;298:106-18.
15. Schmidt AH, Swiontkowski MF. Pathophysiology of infections after internal fixation of fractures. *JAAOS-Journal of the American Academy of Orthopaedic Surgeons*. 2000;8(5):285-91.
16. Rochford E, Richards R, Moriarty T. Influence of material on the development of device-associated infections. *Clinical Microbiology and Infection*. 2012;18(12):1162-7.
17. Rittmann W, Perren S, Rittmann W, Perren S. 1. Introduction and Purpose of the Experiment. *Cortical Bone Healing after Internal Fixation and Infection: Biomechanics and Biology*. 1974:1-3.
18. Romanò CL, Romanò D, Logoluso N, Drago L. Bone and joint infections in adults: a comprehensive classification proposal. *European orthopaedics and traumatology*. 2011;1:207-17.
19. Torbert JT, Joshi M, Moraff A, Matuszewski PE, Holmes A, Pollak AN, et al. Current bacterial speciation and antibiotic resistance in deep infections after operative fixation of fractures. *Journal of orthopaedic trauma*. 2015;29(1):7-17.
20. McNally M, Corrigan R, Sliepen J, Dudareva M, Rentenaar R, IJpma F, et al. What factors affect outcome in the treatment of fracture-related infection? *Antibiotics*. 2022;11(7):946.
21. Cierny Iii G, Mader JT, Penninck JJ. The classic: a clinical staging system for adult osteomyelitis. *Clinical Orthopaedics and Related Research (1976-2007)*. 2003;414:7-24.
22. McPherson EJ, Woodson C, Holtom P, Roidis N, Shufelt C, Patzakis M. Periprosthetic total hip infection: outcomes using a staging system. *Clinical Orthopaedics and Related Research (1976-2007)*. 2002;403:8-15.
23. Hotchen AJ, Dudareva M, Ferguson JY, Sendi P, McNally MA. The BACH classification of long bone osteomyelitis. *Bone & joint research*. 2019;8(10):459-68.
24. Metsemakers W-J, Kortram K, Morgenstern M, Moriarty T, Meex I, Kuehl R, et al. Definition of infection after fracture fixation: a systematic review of randomized controlled trials to evaluate current practice. *Injury*. 2018;49(3):497-504.
25. Rightmire E, Zurakowski D, Vrahas M. Acute infections after fracture repair: management with hardware in place. *Clinical orthopaedics and related research*. 2008;466:466-72.
26. Naique S, Pearse M, Nanchahal J. Management of severe open tibial fractures: the need for combined orthopaedic and plastic surgical treatment in specialist centres. *The Journal of bone and joint surgery British volume*. 2006;88(3):351-7.
27. Prada C, Bengoa F, Bhandari M. The management of fracture related infections: What practices can be supported by high-level evidence? *Journal of Orthopaedic Surgery*. 2022;30(3):10225536221119580.
28. Berrios-Torres SI, Umscheid CA, Bratzler DW, Leas B, Stone EC, Kelz RR, et al. Centers for disease control and prevention guideline for the prevention of surgical site infection, 2017. *JAMA surgery*. 2017;152(8):784-91.
29. Berkes M, Obremskey WT, Scannell B, Ellington JK, Hymes RA, Bosse M, et al. Maintenance of hardware after early postoperative infection following fracture internal fixation. *JBJS*. 2010;92(4):823-8.
30. Olszewski D, Streubel PN, Stucken C, Ricci WM, Hoffmann MF, Jones CB, et al. Fate of patients with a “surprise” positive culture after nonunion surgery. *Journal of orthopaedic trauma*. 2016;30(1):e19-e23.
31. Al-Mayahi M, Betz M, Müller DA, Stern R, Tahintzi P, Bernard L, et al. Remission rate of implant-related infections following revision surgery after fractures. *International orthopaedics*. 2013;37:2253-8.
32. Kuehl R, Tschudin-Sutter S, Morgenstern M, Dangel M, Egli A, Nowakowski A, et al. Time-dependent differences in management and microbiology of orthopaedic internal fixation-associated infections: an observational prospective study with 229 patients. *Clinical Microbiology and Infection*. 2019;25(1):76-81.
33. Hellebrekers P, Leenen LP, Hoekstra M, Hietbrink F. Effect of a standardized treatment regime for infection after osteosynthesis. *Journal of Orthopaedic Surgery and Research*. 2017;12(1):1-11.
34. Haddad FS, Baron Larrey: A role model to be emulated. *Journal of the American College of Surgeons*. 2004;199(3):519.
35. Guthrie H, Clasper J. Historical origins and current concepts of wound debridement. *British Medical Journal Publishing Group*; 2011. p. 130-2.
36. Lowenberg D, Rupp M, Alt V, Browner B, Jupiter J, Krettek C, et al. Understanding and treating chronic osteomyelitis. *Skeletal trauma: basic science, management, and reconstruction*: Elsevier; 2019.
37. Masters EA, Trombetta RP, de Mesy Bentley KL, Boyce BF, Gill AL, Gill SR, et al. Evolving concepts in bone infection: redefining “biofilm”, “acute vs. chronic osteomyelitis”, “the immune proteome” and “local antibiotic therapy”. *Bone research*. 2019;7(1):20.
38. Shaw JD, Brodke DS, Williams DL, Ashton NN. Methylene blue is an effective disclosing agent for identifying bacterial biofilms on orthopaedic implants. *JBJS*. 2020;102(20):1784-91.
39. Rupp M, Henssler L, Brochhausen C, Zustin J, Geis S, Pfeifer C, et al. Can necrotic bone be objectively identified in chronic fracture related infections?—First clinical experience with an intraoperative fluorescence imaging technique. *Injury*. 2020;51(11):2541-5.
40. Draeger RW, Dahners LE. Traumatic wound debridement: a comparison of irrigation methods. *Journal of orthopaedic trauma*. 2006;20(2):83-8.

41. Investigators F. A trial of wound irrigation in the initial management of open fracture wounds. *New England Journal of Medicine*. 2015;373(27):2629-41.
42. Sendi P, McNally MA. Wound Irrigation in Initial Management of Open Fractures. *New England journal of medicine NEJM*. 2016;374(18):1788.
43. Yusuf E, Jordan X, Clauss M, Borens O, Mäder M, Trampuz A. High bacterial load in negative pressure wound therapy (NPWT) foams used in the treatment of chronic wounds. *Wound repair and regeneration*. 2013;21(5):677-81.
44. Paley D, Lamm BM, Katsenis D, Bhave A, Herzenberg JE. Treatment of malunion and nonunion at the site of an ankle fusion with the Ilizarov apparatus. *JBJS*. 2006;88(1):119-34.
45. Foster AL, Moriarty TF, Zalavras C, Morgenstern M, Jaiprakash A, Crawford R, et al. The influence of biomechanical stability on bone healing and fracture-related infection: the legacy of Stephan Perren. *Injury*. 2021;52(1):43-52.
46. Obremskey W, Molina C, Collinge C, Nana A, Tornetta III P, Sagi C, et al. Current practice in the management of open fractures among orthopaedic trauma surgeons. Part A: initial management. A survey of orthopaedic trauma surgeons. *Journal of orthopaedic trauma*. 2014;28(8):e198-e202.
47. Casiraghi A, Galante C, Rohayem M, Vittone G, Domenicucci M, Cattaneo S, et al. Implant retention with serial debridement and use of antibiotic-loaded calcium sulfate beads in acute fracture-related infection (FRI) after pelvic ring or acetabular fractures: A retrospective case series of 7 cases. *Injury*. 2023;54(4):1082-7.
48. Morgenstern M, Kuehl R, Zalavras CG, McNally M, Zimmerli W, Burch MA, et al. The influence of duration of infection on outcome of debridement and implant retention in fracture-related infection: a systematic review and critical appraisal. *The bone & joint journal*. 2021;103(2):213-21.
49. Buijs M, van den Kieboom J, Sliepen J, Wever K, van Breugel J, Hietbrink F, et al. Outcome and risk factors for recurrence of early onset fracture-related infections treated with debridement, antibiotics and implant retention: Results of a large retrospective multicentre cohort study. *Injury*. 2022;53(12):3930-7.