

Observation of the short-term curative effect of using SuperPATH approach to treat elderly femoral neck fractures with schizophrenia

L. MI, Z. YUAN, M. QUE, Y. YANG, S. FANG, X. WANG

Orthopedic Medical Center, Brain Hospital of Hunan Province (The Second People's Hospital of Hunan Province), Changsha, 410007 Hunan, China.

Correspondence at: Xiaoye Wang, Orthopedic Medical Center, Brain Hospital of Hunan Province (The Second People's Hospital of Hunan Province), Changsha, 410007 Hunan, China.

As China enters an aging society, the incidence of femoral neck fractures is increasing year by year. For some patients, total hip arthroplasty (THA) is the treatment of choice for displaced femoral neck fractures. Schizophrenia is a common combination of elderly patients with femoral neck fractures, and there are few reports on the treatment. This study describes the short-term efficacy of the supercapsular percutaneously assisted (SuperPATH) approach in the treatment of patients suffered with displaced femoral neck fractures combined with schizophrenia. A retrospective analysis of 20 elderly patients with displaced femoral neck fractures combined with schizophrenia who underwent THA using the SuperPATH approach. Record demographic data, postoperative reexamination of X-ray film to observe the position and the loosening condition of the prosthesis, the length of hospitalization, complications in the hospital and after discharge. The Harris score of hip joint function was used to evaluate postoperative hip joint function. The average age of the 20 patients was 73.1 years. All patients were followed up by outpatient clinic or telephone. The follow-up time was 3-12 months, with an average of 9.2 months. There was no incision infection, no tissue structure damage such as important nerves and blood vessels, and no complications such as early dislocation, loosening of the joint prosthesis, and deep vein thrombosis of lower extremities. The efficacy of the last follow-up was evaluated according to the Harris score of hip joint function: an average of 91 points (78-98 points); 13 cases were excellent, 5 cases were good, and 2 cases were fair. The SuperPATH approach has the advantages of less surgical damage, shorter recovery time, good surgical safety, preserving the normal tension of the muscles around the hip joint, and reducing the incidence rate of early postoperative dislocation of the joint prosthesis. The THA of the SuperPATH approach can treat patients with displaced femoral neck fractures combined with schizophrenia safely and effectively.

Keywords: Total hip arthroplasty, SuperPATH approach, schizophrenia, short-term curative effect.

INTRODUCTION

With China's aging population, the incidence of femoral neck fractures is increasing year by year. THA is an effective method to treat displaced femoral neck fractures^{1,2}. Schizophrenia is a seriously disabling mental disorder and the cause is not yet clear. According to statistics from authoritative organizations, the lifetime prevalence of schizophrenia in China is about 1%, which accounts for almost 1/2 of the entire hospitalized mental illness group and 3/5 of the population with chronic mental illness^{3,4}. Studies have shown that patients with schizophrenia are more likely to suffer bone mineral density (BMD) reduction and osteoporosis than normal people^{5,6}. Therefore, it is common for patients with schizophrenia to have femoral neck fractures after a fall. Due to their mental illness, patients with schizophrenia have poor compliance with postoperative rehabilitation and limb

management, and the probability of dislocation after hip replacement is much higher than that of normal people. In 2011, the surgical technique and initial experience of the supercapsular percutaneously assisted total hip (PATHO) (SuperPath®, MicroPort Orthopedics Inc., Arlington, TN, USA) was published^{7,8}. This method had a low complication rate, excellent gait kinematics, and low transfusion rate. It shortened the length of hospital stay, and a high proportion of discharge from the hospital⁸. It is especially suitable using THA in schizophrenia patients with displaced femoral neck fractures.

We started using the SuperPATH approach in 2019 to perform THA for 20 schizophrenia patients with displaced femoral neck fractures. The objective of this study was to evaluate the short-term results of the 20 patients that had undergone a THA intervention using the SuperPath approach. We investigated whether

this technique can be used for THA in schizophrenia patients with displaced femoral neck fractures.

MATERIALS AND METHODS

This study retrospectively analyzed 20 schizophrenia patients with femoral neck fractures who were treated with THA using the SuperPATH approach in the Orthopedic Medical Center of our hospital from January 2019 to March 2020. All procedures of the operation were performed by the same group of orthopedic experts, without any intraoperative navigation. This study has been performed in accordance with the ethical standards laid down in the 1964 Declaration of Helsinki and its later amendments. All patients' family members gave written consent.

Among the 20 patients in this study, 13 were women (65%) and 7 were men (35%), 65-79 years old, average 73.1 years old. These patients have been diagnosed with schizophrenia for 15-26 years, with an average of 18.4 years. All patients were diagnosed as undifferentiated schizophrenia. Fracture site was subcapital in 15 cases (75%), transcervical in 5 cases (5%). According to the Garden classification, 3 cases (15%) were type III, and 17 cases (85%) were type IV.

After admission, all patients were given symptomatic treatments such as pain relief and prevention of deep vein thrombosis of the lower extremities. At the same time, psychiatrists were asked to guide treatment and give patients medication to control their mental symptoms. Wait until the patients complete the relevant preoperative examination and have no mental symptoms. Arrange surgical treatment as soon as possible after excluding the patient's surgical contraindications to prevent complications caused by long-term bed rest.

All the patients in the group underwent surgery under general anesthesia. The patients were placed in a lateral decubitus position, with the operative hip at 45° of flexion, and the injured lower limb internal rotation at 10° to 15° and in maximal adduction. The area was disinfected and sterile sheets were laid out. A 6 to 8cm skin incision was performed from the tip of the greater trochanter and extended proximally in line with the femur shaft axis. Incise subcutaneous fat and cut the fascia lata along the direction of the skin incision. Splited the fibers of the gluteus maximus muscle with two pterygoid tip retractors. A blunt Hohmann retractor was placed in the space between the gluteus medius muscle and the gluteus minor muscle to protect the gluteus medius muscle. A blunt Hohmann retractor was placed between the posterior articular capsule and the

external rotator muscle. You can now clearly see the capsule. The joint capsule was cut from the saddle of the femoral neck and extended to the proximal end to the acetabulum. The joint capsule was marked so that it could be identified at the time of suture. The pear fossa, the apex of the greater trochanter of the femur, and the neck of the anterior femur were exposed. Opening of the femoral canal with a sharp starter reamer and the bone chisel expanded the proximal opening. The appropriate medullary cavity file was selected to shape the medullary cavity, and the curette was used to treat the proximal and middle segment of the femur. The medullary cavity file was inserted and the handle removed. The length of the resection of the femoral neck was determined according to the position of the fracture line of the femoral neck fracture. A corkscrew was used for the removal of the femoral head and the diameter of the femoral head was measured. The retractor was placed under the periosteum of the proximal acetabular margin of the incision and the other retractor was placed in the distal joint to remove all the remaining soft tissue on the acetabulum and acetabular lip. An alignment tower was seated in the acetabulum. The leg was placed in extension with a flexed knee to release tension of the sciatic nerve and palpate the femur. Then, 1-2 cm posterior to femur set a 1 cm incision to allow a cannula to pass inside the capsule. The alignment tower was removed leaving the cannula in place. The leg was brought in slight flexion and external rotation to relax the capsule for a better exposure of the acetabulum. The anterior and posterior wall should be seen as well as the transverse ligament and the fosa acetabula for optimal positioning of the cup. The reamer shaft was passed through the cannula and was mated with the acetabular reamers inside the capsule. A reamer basket holder was used to pass the reamer through the main incision. The leg could be moved to assist in proper angle for optimal anteversion. Attached threaded cup adapter to cup and alignment handle. Impacted to medialize cup. Inserted cup impactor to engage cup in 40° of abduction and natural anteversion parallel to the transverse ligament regarding the anterior and posterior wall. Fixation of the cup with screws was now possible through the cannula if needed. A trial liner is inserted or the final liner using the liner impactor and the osteophytes of the acetabulum were removed as well as the cannula. To remove neck/head trials, "classic" luxation to posterior-superior. Associated tapers were dried and cleaned. A modular or a monolithic stem was impacted into the femur. The head was placed on the neck in a classic manner. The assistant moved knee while the surgeon

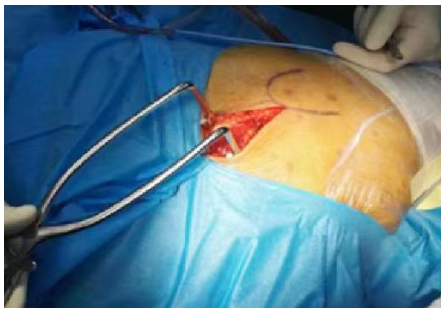

Fig. 1. — Skin incision.

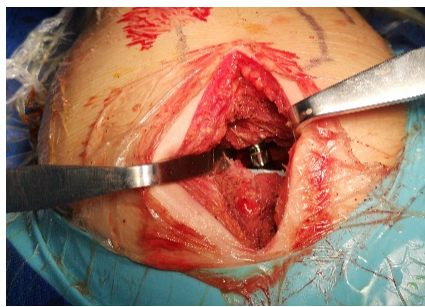


Fig. 2. — Successive rasps were inserted into the femur.

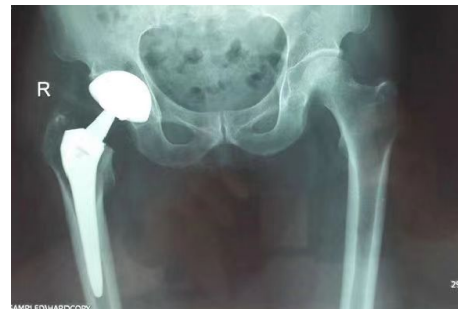

Fig. 3. — Postoperative X-ray.

moved the leg to completely. Stability was checked again. A trial head was inserted into the liner and a trial neck according to the preoperative planning into broach pocket. A blunttrocar was applied against the top of broach to mate. The assistant moved knee or foot while surgeon moved the leg to complete the reposition. Leg length, stability(anterior, posterior, and lateral), range of motion, and impingement are checked. X-ray could be performed to match result with the planning. Check the position of the acetabular component as well as the size und position of the femoral broach. Wash the wound, completely stop the bleeding, suture the joint capsule and all layers, and the operation is over. Final x-ray in a supine position is recommended before the patient leaves the operating room.

After surgery, antibiotics are used to prevent infection, and anticoagulant drugs are used to prevent deep vein thrombosis of the lower extremities. According to the patient's mental symptoms, psychiatrists are invited to consult and give corresponding symptomatic treatment. On the first day after surgery, the patient can get out of bed and move freely. *No special rehabilitation is required after operation.*

RESULT

All patients were followed up by outpatient clinic or telephone. The follow-up time was 3-12 months, with an average of 9.2 months. All patients had no recurrent psychiatric symptoms during follow up period. There was no incision infection, no tissue structure damage such as important nerves and blood vessels, and no complications such as early dislocation, loosening of the joint prosthesis, and deep vein thrombosis of lower extremities. The efficacy of the last follow-up was evaluated according to the Harris score of hip joint function: an average of 91 points (78-98 points); 13 cases were excellent, 5 cases were good, and 2 cases were fair. 2 cases with score lower than 80 mainly showed pain and claudication.

DISCUSSION

Schizophrenia is a serious disabling mental disorder which cause is not yet clear. According to statistics from authoritative organizations, the lifetime prevalence of schizophrenia in China is about 1%⁹⁻¹⁰. While patients with schizophrenia show obvious social dysfunction, they are also accompanied by a series of other health problems of varying degrees¹¹. Clinical studies have shown that the incidence of osteoporosis in patients with schizophrenia is often significantly higher than that of the conventional population, and is characterized by the diversity of attributions. Osteoporosis is very prone to osteoporotic fractures, including femoral neck fractures, which have a serious impact on the quality of life of hospitalized patients with schizophrenia, and could even cause a substantial increase in mortality¹². Total hip arthroplasty is a common surgical procedure for the treatment of displaced femoral neck fractures in the elderly. It can effectively relieve pain, improve the function of injured limbs, significantly improve the quality of life of patients, and reduce mortality¹³⁻¹⁵.

Due to the influence of various factors such as cognitive decline and behavioral disorders, patients with femoral neck fractures and schizophrenia are more likely to suffer from joint prosthesis dislocation and other post-total hip arthroplasty complication than the usual femoral neck fracture. Since the SuperPATH approach for the total hip arthroplasty is a minimally invasive approach, the patient can recover quickly after the operation without destroying the surrounding musculature of the hip joint. The balance of muscle strength around the hip joint after the operation is better than other approaches¹⁶. More and more orthopedic doctors and patients favored¹⁷. Ronald J. Mitchell, et al.¹⁸ believe that the SuperPATH approach for THA appears to be safe and effective in using in femoral neck fragility fractures, resulting in early ambulation and a low dislocation rate. The SuperPATH minimally invasive approach to total hip arthroplasty

is an ideal method for the treatment of femoral neck fractures in the elderly. This method has the advantages of the relatively simple operation, short incision, less blood loss, and less trauma. Xiao-dong Wang et al.¹⁹ found that the patients had short hospitalization times, low hospitalization costs, and good recovery of hip joint function. This is similar to our research results. Research by Xiaoliu Li et al.²⁰ confirmed that patients with SuperPath approach had lower levels of CRP, ESR and CK, better hip function and less pain, as well as better gait condition than patients with conventional posterolateral approach in elderly patients. This is very important for patients with femoral neck fractures with schizophrenia. J. Joseph Gholson, et al.²¹ confirmed that Total joint arthroplasty in patients with schizophrenia had markedly increased complications. It can prevent the patients from inducing psychiatric symptoms caused by schizophrenia due to persistent pain after the operation, and prevent the dislocation of the joint prosthesis caused by the patient's non-cooperation.

SuperPATH approach for total hip arthroplasty for the treatment of femoral neck fractures with schizophrenia also has some shortcomings, such as a long learning curve. In the early stage of the operation of this approach, conditions such as intraoperative femoral fracture and sciatic nerve injury may still occur. The occurrence of these complications may become an important cause of follow-up doctor-patient disputes²². Pengfei Lei et al.²³ demonstrated that for surgeons familiar with the standard posterolateral approach, after 40 operations, they can become more familiar with SuperPATH.

CONCLUSIONS

SuperPATH approach for Total hip arthroplasty provides a new idea for the treatment of elderly schizophrenia patients with femoral neck fractures. It has the advantages of good clinical effects and low risk of postoperative dislocation. It can be safe and effective when applying to elderly patients with schizophrenia and femoral neck fractures. Since this study is a single-center retrospective study, the number of samples is small and the follow-up time is short. In the future, long-term follow-up results from multiple centers and large samples are still needed.

REFERENCES

- Ramadanov N, Toma I, Herkner H, et al. Factors that influence the complications and outcomes of femoral neck fractures treated by cannulated screw fixation. *Sci Rep.* 2020;10:758.
- J. Xie, H. Zhang, L. Wang, et al. Comparison of supercapsular percutaneously assisted approach total hip versus conventional posterior approach for total hip arthroplasty: a prospective, randomized controlled trial. *Journal of Orthopaedic Surgery and Research.* 2017;12(1):138.
- Siu MW, Chong CS, Lo WT. Prevalence and clinicians' awareness of psychiatric comorbidities among first-episode schizophrenia. *Early Interv Psychiatry.*2018;12 (6):1128-1136.
- Juntapim S, Nuntaboot K. Care of patients with schizophrenia in the community. *Arch Psychiatr Nurs.* 2018;32(6):855-860.
- Stubbs B, Gaughran F, Mitchell AJ, et al. Schizophrenia and the risk of fractures:a systematic review and comparative meta-analysis. *General Hospital Psychiatry.*2015;37(2):126-133.
- Correll CU, Detraux J, De Lepeleire J, et al. Effects of antipsychotics, antidepressants and mood stabilizers on risk for physical diseases in people with schizophrenia, depression and bipolar disorder. *World Psychiatry.*2015;14(2):119-136.
- Chow J, Penenberg B, Murphy S. Modified micro-superior percutaneously-assisted total hip: early experiences & case reports. *Curr Rev Musculoskelet Med.*2011;4:146-50.
- Jia Jianbo, Ji Ying, Liu Xinxin, et al. Hip hemiarthroplasty for senile femoral neck fractures: Minimally invasive SuperPath approach versus traditional posterior approach. *Injury.* 2019; 50(8):1452-1459.
- Siu MW, Chong CS, Lo WT. Prevalence and clinicians' awareness of psychiatric comorbidities among first-episode schizophrenia [J].*Early Interv Psychiatry.*2018,12 (6):1128-1136.
- Juntapim S, Nuntaboot K. Care of patients with schizophrenia in the community [J]. *Arch Psychiatr Nurs.*2018,32(6):855-860.
- Marunkevych YY. Peculiarities of suicidal behavior of patients with paranoid schizophrenia with various clinical symptoms [J]. *Wiad Lek.*2018,71(7):1392-1397.
- Seitz DP, Gill SS, Gruneir A, et al. Effects of dementia on postoperative outcomes of older adults with hip fractures: a population-based study[J].*J Am Med Dir Assoc.*2014,15(5): 334-341.
- Jonas SC, Shah R, Al-Hadithy N, et al. Displaced intracapsular neck of femur fracture in the elderly: Bipolar hemiarthroplasty may be the treatment of choice;a case control study[J]. *Injury.* 2015,46(10):1988-1991.
- Taryn E LeRoy, Brett L Hayden, Jason Desmarais, et al. Early Outcome Comparison of the Posterior Approach and the Superior Approach for Primary Total Hip Arthroplasty[J]. *Arthroplast Today.*2020, 13:6(3):508-512.
- David R Maldonado, Cynthia Kyin, Rafael Walker-Santiago, et al. Direct anterior approach versus posterior approach in primary total hip replacement: comparison of minimum 2-year outcomes[J]. *Hip Int.*2021:31(2):166-173.
- Nikolai Ramadanov, Simon Bueschges, Kuiliang Liu, et al. Comparison of short-term outcomes between direct anterior approach (DAA) and SuperPATH in total hip replacement: a systematic review and network meta-analysis of randomized controlled trials [J]. *Journal of Orthopaedic Surgery and Research.*2021(16):324.
- Michelangelo Scaglione, Francesco Casella, Michele Giuntoli, et al. The role of superior capsular approach (SuperPATH) in the treatment of femoral neck fractures with hemiarthroplasty implantation: our experience and review of literature[J]. *Acta Biomed.* 2020 ,91(4):e2020114.
- Ronald J Mitchell, Andrew B Kay, Kevin M Smith, et al. Early results of displaced femoral neck fragility fractures treated with supercapsular percutaneous-assisted total hip arthroplasty[J]. *Arthroplast Today.* 2019,5(2):193-196.
- Xiao-dong Wang, Hai Lan, Zheng-xia Hu, et al. SuperPATH Minimally Invasive Approach to Total Hip Arthroplasty of Femoral Neck Fractures in the Elderly: Preliminary Clinical Results[J]. *Orthop Surg.* 2020,12(1):74-85.
- Xiaoliu Li, Li Ma, Qiang Wang, et al. Comparison of total hip arthroplasty with minimally invasive SuperPath approach vs.

- conventional posterolateral approach in elderly patients: A one-year follow-up randomized controlled research[J]. *Asian J Surg*. 2021,44(3):531-536.
21. J Joseph Gholson, Nicholas A Bedard, S Blake Dowdle, et al. Total Joint Arthroplasty in Patients With Schizophrenia: How Much Does It Increase the Risk of Complications? [J]. *J Arthroplasty* . 2018 Jul;33(7):2082-2086.
 22. Adler RA. Update on osteoporosis in men [J]. *Best Pract Res Clin Endocrinol Metab*,2018,32(5):759-772.
 23. Pengfei Lei, Zhan Liao, Jiang Peng,et al. Assessment of the Learning Curve of Supercapsular Percutaneously Assisted Total Hip Arthroplasty in an Asian Population[J]. *Biomed Res Int*. 2020,2020:5180458.