

GANGLION CYSTS ASSOCIATED WITH CRUCIATE LIGAMENTS OF THE KNEE : A POSSIBLE CAUSE OF RECURRENT KNEE PAIN

F. GARCÍA-ALVAREZ¹, J. M. GARCÍA-PEQUERUL¹, J. L. AVILA¹, J. M. SAINZ², T. CASTIELLA³

Intraarticular ganglia of the knee are uncommon ; however, these ganglion cysts may produce knee discomfort without a clear etiology. We present the cases of 10 patients with ganglion cysts arising from cruciate ligaments of the knee joint who underwent arthroscopic excision after MR examination. The MR findings, clinical features and arthroscopic findings were evaluated comparatively. Diagnoses were confirmed by means of a histological study after arthroscopic excision. The cysts were fluid-filled, with low T1-weighted signal intensity and high T2-weighted signal intensity. Except for two patients with recent accidents, the remaining eight presented chronic pain without any history of trauma. Pain was the most frequent clinical sign. It was associated with knee extension in 3 cases and with flexion in 3 cases. In 7 cases, cysts were exclusively associated with the anterior cruciate ligament (ACL). Only in one case was a cyst associated with an ACL rupture. Four patients presented meniscal lesions. All ganglia appeared solitary in each knee. Postarthroscopy evolution was painless in 8 patients. Histologic diagnoses corresponded to ganglion cysts. The tissues from the patient with the ACL rupture presented a fibrous reaction with myxoid degeneration forming intraligamentary ganglion cysts.

Keywords : ganglion cysts ; cruciate ligaments ; knee arthroscopy.

Mots-clés : kystes ; ligaments croisés ; arthroscopie du genou.

INTRODUCTION

Intraarticular ganglia of the knee are unusual lesions and appear in 1.3% of the patients referred for MR examinations of the knee (3), and in 0.6% of the arthroscopic examinations (2). Ganglion cysts associated with cruciate ligaments may produce knee discomfort without a clear etiology. The aim of the present article was to retrospectively evaluate clinical symptoms, MR and arthroscopic findings of intraarticular knee ganglia associated with cruciate ligaments.

PATIENTS AND METHODS

Ten cases of intraarticular ganglia of the knee associated with the cruciate ligaments (6 men and 4 women) were detected in MR-imaging examinations of symptomatic knees during 1998. These cases were collected from a reference population of over 300,000 people. The patients ranged in age between 25 and 50 years (mean : 33 years).

All MR examinations were interpreted by two radiologists experienced in musculoskeletal MR imaging, and

¹ Orthopedic Surgery and Traumatology

² Radiology Department

³ Pathology Department, Hospital "Lozano Blesa", Zaragoza, Spain.

Correspondence and reprints : F. García-Alvarez García, C/Zumalacárregui 4, 4º, 50006 Zaragoza, Spain.

Table I. — Patients, symptoms and course

Sex	Age years	Antecedents	Symptoms	Ligament injuries	Location	Associated injuries	PO
1 male	26	no trauma	pain blocking in flexion	no	PCL	no	OK
2 female	49	no trauma polyarthritis	extension -10° medial pain	no	ACL	meniscal medial + lateral	OK
3 female	50	no trauma obesity, arthritis	blocking pain	no	distal ACL	no	OK
4 male	29	hyperflexion. obesity	blocking pain	yes ACL rupture	proximal ACL	meniscal medial	ACL deficit
5 female	42	skiing	joint effusion pain	no	ACL	meniscal medial	OK
6 male	50	no trauma	pain + flexion limitation	no	between PCL-ACL	chondral medial	OK
7 male	41	miner	pain downhill walking	no	ACL	meniscal lateral chondral lateral	ACL rupture
8 male	33	no trauma	pain	no	ACL	no	OK
9 male	40	no trauma	recurrent pain	no	ACL	no	OK
10 female	25	no trauma	pain downhill walking	no	PCL	no	OK

were confirmed at arthroscopy and in the histological study after arthroscopic excision. The cysts were fluid-filled, with low T1-weighted signal intensity and high T2-weighted signal intensity.

All patients underwent arthroscopy with excision of ganglia. Samples were sent for histological study. Meniscal tears were repaired. The average follow-up after arthroscopy was 14 months. The ACL rupture case was scheduled for a surgical reconstruction.

RESULTS

Except for two patients with recent accidents, the remaining eight presented chronic pain without any history of trauma (table I). Pain was the most frequent clinical sign. Pain was associated with knee extension in 3 cases and with flexion in 3 cases. Two cases of medial joint line tenderness were associated with meniscal tears. Pain increased with activity, especially with downhill walking.

The patient with recurrent symptoms (case 9) showed no lesions on the MRI, but two months later, in a symptomatic phase, a new MRI showed an intraarticular ganglion associated with the ACL without any other internal lesion. Three patients suffered blocking of the knee in flexion. One patient presented a deficit of extension of 10°. No palpable tumor was found on physical examination. Significant radiological signs of osteoarthritis were noted in 2 cases. In 7 cases, cysts were exclusively associated with the ACL. Only in one case was a cyst associated with an ACL rupture. Four patients presented meniscal lesions, in 2 cases lateral and in 3 cases medial. Two cases (cases 3 and 4) presented an increase in the infrapatellar Hoffa space. Synovial hypertrophy was significant in one of these cases (case 3).

Sizes varied from 10 mm to 38 mm in diameter (fig. 1). Most ganglia were uniloculated and

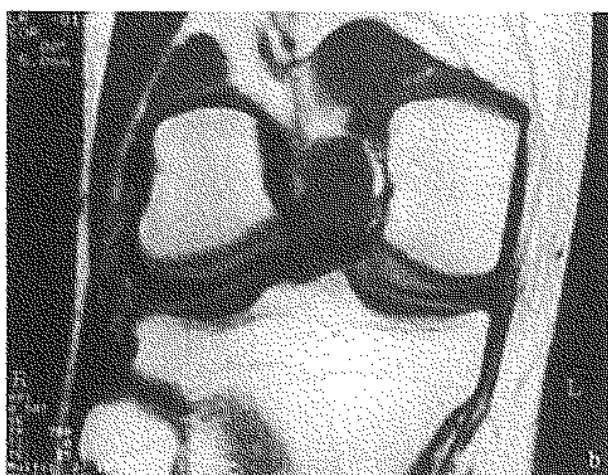
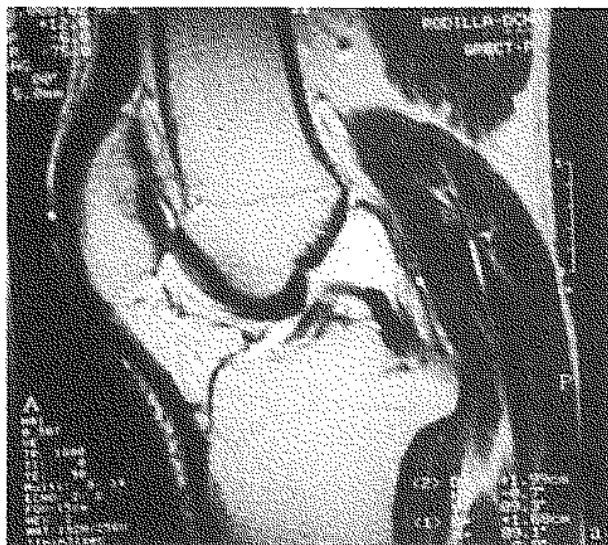
Fig. 1. — A 26-year-old man with a knee that blocked in flexion without instability.

A) High signal intensity ganglion cyst of nearly 38-mm diameter, located in relation with the PCL in a sagittal T2-weighted MR image.

B) Low T1-weighted signal intensity of the ganglion located in the posterior intercondylar region in a coronal MR image.

presented low T1-weighted signal intensity and high T2-weighted signal intensity (fig. 2). None of the ganglia extended intraosseously.

All ganglia appeared solitary in each knee and had thin walls filled with clear fluid. In five patients no specimen could be obtained for histologic diagnosis. Histologic diagnoses corresponded to ganglion cysts. The tissues from the patient with the ACL rupture showed a fibrous reaction with

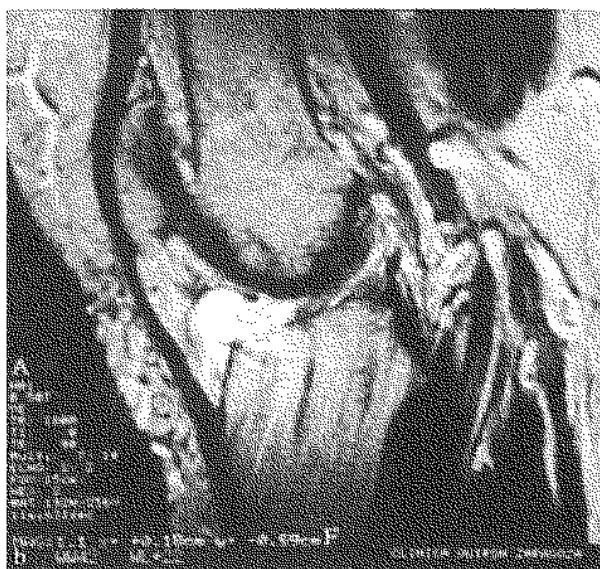
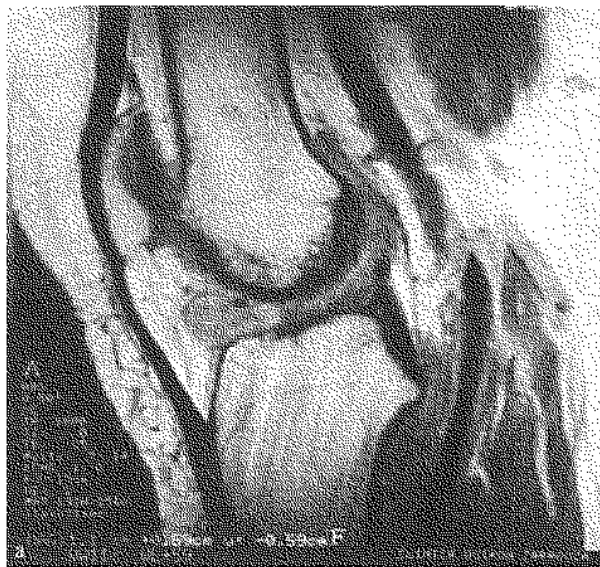


Fig. 2. — A 50-year-old woman with a knee that blocked in flexion without instability.

A) T1-weighted MR image with a low signal intensity ganglion cyst located over the tibial ACL insertion in a sagittal image. An increase in the infrapatellar Hoffa space can be seen.

B) High T2-weighted signal intensity of the ganglia.

myxoid degeneration forming intraligamentary ganglion cysts.

One patient (case 7) suffered an ACL rupture 4 months after arthroscopy. Postarthroscopy evolution was painless in 8 patients; the remaining

2 cases were associated with the ACL rupture. To the best of our knowledge none of the patients has had any recurrence of intraarticular knee ganglia after arthroscopy.

DISCUSSION

Ganglion cysts are benign tumor-like masses that originate from connective tissue (8). Intraarticular ganglia of the knee are noted in 1.3% of the patients referred for MR examinations of the knee (3) and 0.6% on knee arthroscopy (2). Nevertheless these percentages may change according to occupation, sports practiced and age in the patient population. Men predominated in our series, which would agree with the findings of other authors (2, 3).

Ganglia associated with cruciate ligaments of the knee may appear in intact ligaments or with rupture of the ligament, increasing the difficulty of MRI diagnosis in this case. In addition, pericruciate meniscal cysts arising from tears of the posterior horn of the medial meniscus sometimes simulate posterior cruciate ganglion cysts on MRI (4). On T2-weighted images cruciate ganglion cysts are usually homogeneously hyperintense to the skeletal muscle (3, 7, 9); however, hemorrhagic debris within the cyst may produce a heterogeneous signal (7). In ganglia associated with the ACL, sagittal high T2-weighted signal intensity of the ganglia contributed decisively to the differential diagnosis with partial tears of the ligament. For PCL ganglia, a coronal MR image added important information to sagittal images. Our ACL cysts were predominantly spherical in shape. This does not agree with the series of Recht *et al.* (7) where ACL cysts were fusiform.

Some authors have reported that PCL cysts predominate over ACL cysts (7); however, in 7 of our 10 cases, cysts were exclusively associated with the ACL, in the same manner as in Brown and Dandy's series (2). In the literature different percentages appear for lesions associated with intraarticular knee ganglia. Mafulli *et al.* (5) reported three cases of cysts associated with the ACL in athletes with no further knee lesion; in the Brown and Dandy series

(2), half of the patients with intraarticular ganglia did not present other lesions on arthroscopic examination, and Bui-Mansfield and Youngberg (3) found 22% with an associated internal derangement on MR imaging. In our arthroscopic series, only 5 of 10 patients did not show chondral or meniscal lesions associated with ganglia. In the case with associated ACL rupture, occurring 4 months after arthroscopy, we think that the ACL cyst was secondary to the continuous injury over the ligament in this patient, a miner, and not to the surgery. Probably, these ganglion cysts are the inflammatory response to mechanical stimuli such as obesity, skiing, etc. In fact, ganglia usually are located in areas under continuous mechanical stress (5, 8). With repeated activity across these areas, the collagen tissue undergoes mucoid degeneration with the formation of amorphous gelatinous material (8).

Associated with intraarticular ganglia in the knee there are different symptoms related (2), pain on the medial joint line (the most common), on the lateral joint line, mechanical locking and diffuse aching or a sensation of discomfort. Pain was the most frequent clinical sign in our study, generally recurrent pain, and it was associated with extension and flexion and increased with activity, especially with downhill walking. The cases of medial joint line tenderness were associated with meniscal tears. As in other joints, the recurrent character of these intraarticular ganglia may explain symptomatic knees without significant findings after arthroscopy or on MR imaging. Therefore, it is necessary to perform MR imaging during a symptomatic stage.

Postarthroscopy evolution was painless in 7 patients. Therefore we can say that, except for the two cases of instability due to ACL rupture, most patients had excellent results. Similar results were presented by Brown and Dandy (2). Also similar to these authors' study (2) no recurrences after cyst excision were found in our series. CT-guided aspiration has been proposed for the treatment of these cysts (1, 6). Arthroscopy is not a very aggressive procedure; it allows a search for associated injuries and permits their treatment. Therefore we think that

arthroscopy is the method of choice to treat ganglion cysts associated with cruciate ligaments in the knee.

REFERENCES

1. Antonacci V. P., Foster T., Fenlon H., Harper K., Eustace S. Technical report : CT-guided aspiration of anterior cruciate ligament ganglion cysts. *Clin. Radiol.*, 1998, 53, 771-773.
2. Brown M. F., Dandy D. J. Intra-articular ganglia in the knee. *Arthroscopy*, 1990, 6, 322-323.
3. Bui-Mansfield L. T., Youngberg R. A. Intraarticular ganglia of the knee : Prevalence, presentation, etiology, and management. *Am. J. Roentgenol.*, 1997, 168, 123-127.
4. Lektrakul N., Skaf A., Yeh L., Roger B., Schweitzer M., Blasbalg R., Resnick D. Pericruciate meniscal cysts arising from tears of the posterior horn of the medial meniscus : MR imaging features that simulate posterior cruciate ganglion cysts. *Am. J. Roentgenol.*, 1999, 172, 1575-1579.
5. Mafulli N., Binfield P. M., King J. B. Isolated ganglions of the anterior cruciate ligament. *Med. Sci. Sports Exerc.*, 1993, 25, 550-553.
6. Nokes S. R., Koonce T. W., Montanez J. Ganglion cysts of the cruciate ligaments of the knee : Recognition on MR images and CT-guided aspiration. *Am. J. Radiol.*, 1994, 162, 1503.
7. Recht M. P., Applegate G., Kaplan P., Dussault R., Schweitzer M., Dalinka M. K., Resnick D. The MR appearance of cruciate ganglion cysts : A report of 16 cases. *Skeletal Radiol.*, 1994, 23, 597-600.
8. Rozbruch S. R., Chang V., Bohne W. H., Deland J. T. Ganglion cysts of the lower extremity : An analysis of 54 cases and review of the literature. *Orthopedics*, 1998, 21, 141-148.
9. Sumen Y., Ochi M., Deie M., Adachi N., Ikuta Y. Ganglion cysts of the cruciate ligaments detected by MRI. *Int. Orthop.*, 1999, 23, 58-60.

SAMENVATTING

F. GARCÍA-ALVAREZ, J. M. GARCÍA-PEQUERUL, J. L. AVILA, J. M. SAINZ, T. CASTIELLA. Een mogelijke oorzaak van recidiverende knielast : de ganglion kyste van de kruisbanden.

Intra-articulaire kysten zijn zeldzaam in de knie, maar kunnen er klachten veroorzaken zonder duidelijke oorsprong. De auteurs beschrijven 10 gevallen van ganglion kyste van de kruisbanden, gediagnostiseerd op basis van kernspintomografie, en artroscopisch behandeld. De klinische, kernspintomografische en artroscopische bevindingen worden onderling vergeleken. De uitein-

delijke diagnose werd histologisch gesteld na excisie. De kysten hadden een vloeibare inhoud, hypodens op T1-gewogen beelden en hyperdens op T2-gewogen beelden. De patiënten klaagden van chronische pijn zonder traumatische voorgeschiedenis, behalve twee die recent een ongeval hadden gehad. Pijn was de frequentste klacht. Ze trad op bij extensie in 3 gevallen, en bij flexie in 3 andere gevallen. Zeven maal bleef de kyste beperkt tot de voorste kruisband ; slechts in één van deze 7 gevallen was er ruptuur van de kruisband. Vier patiënten hadden ook meniscusletsels. In alle 10 gevallen ging het om een geïsoleerde kyste. Bij 8 patiënten verdwenen de klachten na artroscopische excisie. Histologisch ging het duidelijk om ganglion kysten. Bij de patiënt met voorste kruisbandscheur was er histologisch een fibreuze reactie, naast myxoïde degeneratie verantwoordelijk voor de kystevorming in het ligament.

RÉSUMÉ

F. GARCÍA-ALVAREZ, J. M. GARCÍA-PEQUERUL, J. L. AVILA, J. M. SAINZ, T. CASTIELLA. Le kyste intra-articulaire associé aux ligaments croisés du genou, une cause possible de douleurs récurrentes du genou.

Les kystes intra-articulaires du genou sont rares ; ils peuvent entraîner une gêne locale dont l'étiologie n'apparaît pas clairement. Les auteurs rapportent le cas de 10 patients qui présentaient des kystes développés au niveau des ligaments croisés du genou et qui ont été enlevés par arthroscopie après mise au point IRM. Les auteurs ont confronté les constatations cliniques, en IRM et à l'arthroscopie. Tous les diagnostics ont été confirmés histologiquement après excision par arthroscopie. Les kystes avaient un contenu liquidien, avec un signal de faible intensité en T1 et un signal de haute intensité en T2. Un antécédent traumatique récent n'était relevé que dans deux cas. La douleur était le symptôme le plus fréquent ; elle survenait en extension du genou dans trois cas, en flexion dans trois autres. Le kyste était développé au niveau du seul ligament croisé antérieur dans 7 cas ; dans un cas seulement, ce ligament était rompu. Quatre patients présentaient des lésions méniscales. Dans chaque cas, il s'agissait d'un kyste isolé. L'évolution après arthroscopie s'est faite vers la disparition des douleurs dans 8 cas. Histologiquement, il s'agissait de kystes arthro-synoviaux ; chez le patient qui présentait une rupture du croisé antérieur, on notait une réaction fibreuse avec dégénérescence myxoïde et formation de kystes à l'intérieur du ligament.