



Clinical and radiological characteristics of 82 solitary benign peripheral nerve tumours

Grégoire CHICK, Jan VICTOR, Nadine HOLLEVOET

From the La Tour Hospital, Department of Hand Surgery, Geneva, Switzerland and Ghent University Hospital, Department of Orthopaedics, Ghent, Belgium

Benign peripheral nerve tumours are rare lesions. The surgical treatment and clinical outcomes depend on the resectability. The aim of this retrospective study was to identify clinical or radiological features that may predict the surgical technique that should be used to improve clinical outcome.

Eighty-two patients were diagnosed with solitary benign peripheral nerve tumours. Fifty-five tumours were surgically resectable, and 27 were nonresectable. Pre-operative magnetic resonance imaging and ultrasound were used, which were predictive of the neural origin of the tumours in 87% (39/45) of cases imaged. In 78% (50/64) of cases imaged, an origin from the nerve sheath (peripheral nerve sheath tumour), or from non-neural elements was possible. However, no imaging or clinical criteria were identified that could determine tumour resectability preoperatively. The diagnosis of solitary peripheral nerve tumour still relies on the macroscopic appearance and definitive histology after epineurotomy.

Keywords : Peripheral nerve tumour, Peripheral nerve sheath tumour, Schwannoma, Neurofibroma, Haemangioma, Lipoma, Intraneural cyst

INTRODUCTION

Benign peripheral nerve tumours are rare and are currently classified as soft tissue tumours arising from the nerve or nerve sheath, but other

benign mass lesions may involve peripheral nerves, including ganglion cyst, lipoma, or haemangioma (11,12) (Table I). Tumours that arise from the peripheral neural sheath are known as peripheral nerve sheath tumours (11,12).

The most common presentation of solitary peripheral nerve tumours is localised swelling (14,15), particularly in superficial locations (7). Patients may experience different types of pain, usually localised, especially in case of a deep location (7). However, solitary benign peripheral nerve tumours are rarely responsible for neurological deficits.

Magnetic resonance imaging (MRI) is the standard imaging method to diagnose peripheral nerve tumours (9,19,20). Some MRI findings, such as the target sign, fascicle appearance, and the 'split fat' sign, support the benign nature of the lesion

- Grégoire Chick¹,
- Jan Victor²,
- Nadine Hollevoet²

¹Department of Hand Surgery and Peripheral Nerve Surgery. Hopital de la Tour. Geneva, Switzerland.

²Ghent University Hospital, Department of Orthopaedic Surgery and Traumatology, Gent, Belgium.

Correspondence : Grégoire Chick. Department of Hand Surgery and Peripheral Nerve Surgery. Hopital de la Tour. 1 Avenue J.D. Maillard, 1217 Meyrin Geneva, Switzerland. Tel. : +41 22 719 61 44. Fax : +41 22 719 61 45

E-mail : chick@la-main.ch

© 2020, Acta Orthopædica Belgica.

No benefits or funds were received in support of this study. The authors declare that they have no competing interests.

Acta Orthopædica Belgica, Vol. 86 - 1 - 2020

Table I. — Types, origin, and resectability of solitary benign peripheral nerve tumours

Peripheral nerve sheath tumours		Peripheral non-neural tumours			
Schwannoma	Neurofibroma	Intraneural lipoma	Fibro-lipomatous hamartoma	Intraneural haemangioma	Intraneural ganglion cyst
Resectable	Nonresectable	Resectable	Non-resectable	Non-resectable*	Nonresectable

*Intraneural hemangioma with extrafascicular development are resectable tumours

(1,3). MRI allows for differentiation between a soft tissue tumour compressing the nerve, from a tumour arising within the nerve. The combination of sequences and images after contrast enhancement may assist in the differential diagnosis of the tumour types. In patients with signs of neurological deficit, MRI may also assess the state of the nerve and the impact of denervation on the affected muscles (3). Ultrasound imaging can also refine the diagnosis of solitary peripheral nerve tumours, and can distinguish between soft tissue tumours compressing the nerve and tumours, or other lesions within the nerve. Colour Doppler ultrasound allows an accurate assessment of the intralesional blood flow and can help to differentiate between solid and cystic lesions, as this dynamic imaging method can analyse the entire nerve and identify other tumours (5). Other imaging methods, such as computed tomography (CT) scans are less sensitive and less specific imaging methods for diagnosis of solitary benign peripheral nerve tumours (9).

A correct tumour diagnosis and the relationship of the tumour with the nerve are required to distinguish between resectable and nonresectable tumours, as these factors affect clinical outcome following surgery (Table I). Resectable solitary benign peripheral nerve tumours are located within the epineurium and can be enucleated without disrupting the continuity of the nerve (15). Nonresectable tumours infiltrate all elements of the nerve, resulting in nerve fibre damage on surgical tumour removal. Surgical treatment consists of epineurotomy, preserving nerve continuity, in case of symptoms. Irrespective of the type of tumour, preservation of nerve continuity is the underlying goal for any surgical procedure (7).

The aim of this retrospective study was to identify the preoperative clinical or radiological features that helped to predict the appropriate surgical technique and improved outcomes in 82 patients who were

diagnosed with a solitary benign peripheral nerve tumour.

PATIENTS AND METHODS

Approval for this study was obtained from the local Institutional Review Board. Informed consent was obtained from all patients who participated in this study.

The medical records of patients who underwent surgery for benign solitary peripheral nerve tumour between 1981 and 2011 at the Paris VI University Hospital and the Latour Hospital in Geneva, were studied by the author (GC) in 2017. Malignant tumours, neuromas and multiple tumours, in the context of neurofibromatosis, were excluded (11,12).

Eighty-two patients were included in the study. Results from 47 of these patients have been reported in previous studies (7,8). The following information was obtained from the medical records: sex, age at onset of symptoms, symptoms and their duration and distribution of the solitary peripheral nerve tumours.

Data on preoperative MRI and ultrasound imaging studies were available for 64 patients ; 45 patients had MRI and 19 patients had ultrasound as the sole imaging investigation. Eight other patients with only CT scans were not included in the study, due to the low sensitivity and specificity of this imaging method for these tumours. Of the 82 patients included in the study, no imaging studies were undertaken in nine patients (11%), who had a preoperative clinical diagnosis of nerve entrapment syndrome (four cases) and soft tissue tumour (five cases). MRI and ultrasound imaging were performed at the two different hospitals and interpreted by four different radiologists. Details on the specific types of imaging equipment were not available, in most cases. MRI evaluation consisted of different sequences, including T1-weighted and T2-weighted

fat-saturated postgadolinium MRI, with images in the same plane (usually axial) supplemented by at least one other sequence in an orthogonal (sagittal or coronal) plane. MRI and ultrasound image interpretation provided information on the neural origin of the tumour and the boundary between the tumour and the nerve, the nature of the tumour (fluid, solid with or without fat), and the specific imaging characteristics. The data obtained from the preoperative imaging studies were divided into three different categories: imaging findings that supported the histological diagnosis; uncertain diagnosis but a tumour associated with the nerve; and an uncertain diagnosis.

Histological examination showed that 55 of the solitary benign peripheral nerve tumours were resectable. The histological diagnoses of the resectable tumours included 49 schwannomas, four intraneural lipomas, two intraneural haemangiomas (extrafascicular). Histological examination showed that 27 of the solitary benign peripheral nerve tumours were non-resectable. The histological diagnoses of the non-resectable tumours included eight solitary neurofibromas, five fibrolipomatous hamartomas, one intraneural haemangioma (intrafascicular) and 13 intraneural ganglion cysts (11,12).

The postoperative clinical outcomes after surgical treatment, including residual symptoms, neurological deficits, and tumour recurrences, were also investigated with a mean follow-up between surgery and the last report in the medical files of four years (range, 1-10 years).

Statistical analysis was performed to investigate if clinical or preoperative radiological findings

could predict the nerve origin, type of tumour, and the tumour resectability. Descriptive statistics were presented by the mean and standard deviation (SD) in case of continuous variables. The categorical variables were presented as counts and percentages. Non-parametric Kruskal-Wallis tests were undertaken to compare the means across the types of tumours and to compare the MRI and ultrasound findings and the types of tumours. Two-tailed (two-sided) Fisher's exact test was used for comparisons between two groups of tumours or imaging methods. A P-value <0.05 was considered to be statistically significant.

RESULTS

Patient demographics, clinical presentation and physical examination

The mean age of the 82 patients included in the study was 38 years (range, 4-78 years); there were 49 men and 33 women (Table II).

Patient's age was significantly associated with the type of tumour in this study ($p < 0.001$). The mean age at which patients showed the first clinical signs of intraneural haemangioma or fibrolipomatous hamartomas (17 years) was significantly lower than mean age of other types of solitary benign neural tumour, which was at 40 years ($p < 0.001$). Patients presenting with neurofibromas were significantly younger (26 years) than patients with Schwannomas (41 years) ($p = 0.013$). Intra-neural ganglion cysts and neurofibromas were more common in male patients. However, gender was not significantly associated with tumour type ($p = 0.18$).

Table II. — Patient age, sex, and tumour type

Type of tumour	N (%)	Age (y)			Sex N (%)	
		Mean	Min.	Max.	Female	Male
Schwannoma	49 (60)	41	23	77	25(51)	24(49)
Intraneural ganglion cyst	13 (16)	43.5	27	78	3(23)	10(77)
Neurofibroma	8 (10)	26	10	41.5	1(13)	7(88)
Fibrolipomatous hamartoma	5 (6)	17	5	22	1(20)	4(80)
Intraneural lipoma	4 (5)	41	16	57	2(50)	2(50)
Intra-neural haemangioma	3 (3)	17.5	4	30.5	1(33)	2(67)
Total	82 (100)	38	4	78	33(40)	49(60)

The mean time between onset of symptoms and diagnosis was 30 months (range, 1-192 months) (Table III). This was shortest for intra-neural ganglion cysts compared with fibrolipomatous hamartomas ($p<0.001$), intraneural lipomas ($p=0.004$) and neurofibromas ($p<0.001$). The fibrolipomatous hamartoma cases had the greatest time between the onset of symptoms and diagnosis (72 months) when compared with cases of intra-neural lipoma ($p=0.021$), and schwannoma ($p=0.002$).

The most common symptom reported by patients at initial presentation was pain (54%), followed by localised swelling (35%). Three patients had a neurological deficit, including one case of neurofibroma and two cases of intraneural ganglion cyst. One schwannoma was found coincidentally during surgery, and one intraneural haemangioma was associated with a skin lesion (a blue spot). Patients with intraneural ganglion cysts complained of localised pain in 85% of cases, but not of swelling in comparison with other tumour types ($p=0.004$).

Solitary peripheral nerve tumours were more frequently found in the upper limb (69.5% of cases) (Tables IV and V). Mixed motor and sensory nerves were involved in 80% of cases, by neurofibromas and intra-neural ganglion cysts. In the upper limb,

Table III. — Time between onset of symptoms and diagnosis

Type of tumour (N)	Time between the onset of symptoms and diagnosis (months)		
	Mean	Min.	Max.
Schwannoma (49)	26	2	89
Intraneural ganglion cyst (13)	7	1	25
Neurofibroma (8)	56	4	192
Fibrolipomatous hamartoma (5)	72	40	114
Intraneural lipoma (4)	18	8	30
Intraneural haemangioma (3)	66	3	130
Total (82)	30	1	192

tumours were most frequently located in the median and ulnar nerves (54%). Neurofibromas mainly involved nerve roots and nerves of the brachial plexus in four out of seven cases (57%), and these locations were involved in 11 out of 57 cases (19%) of all tumour cases ($p<0.05$). No nerve roots were involved in peripheral non-neural sheath tumours when compared with tumours that originated from neural sheath elements ($p=0.05$). In the lower limbs, tumours occurred more commonly in the sciatic nerve and its branches (80% of cases), and 64% of these cases involved the common fibular nerve. Intra-neural ganglion cysts were specifically located

Table IV. — Location of nerve tumours in the upper limb

Type of tumour	N	Mixed nerves				Sensory nerves*
		Nerve roots and brachial plexus	Median	Radial	Ulnar	
Schwannoma	35	7	10	2	9	7
Neurofibroma	7	4	2		1	0
Fibrolipomatous hamartoma	5		3		1	1
Intraneural lipoma	4			1	1	2
Intraneural haemangioma	3		1			2
Intraneural ganglion cyst	3		1		2	0
Total upper limb	57	11	17	3	14	12

*Digital nerve, dorsal ulnar sensory nerve, radial sensory nerve.

Table V. — Location of nerve tumours in the lower limb

Type of tumour	Mixed nerves				Sensory nerves	
	N	Sciatic	Common fibular	Tibial	Superficial peroneal	Sural
Schwannoma	14	1	6	2	4	1
Intraneural ganglion cyst	10		10			
Neurofibroma	1	1				
Total lower limb	25	2	16	2	4	1

on the common fibular nerve at the level of the neck of the fibula ($p=0.003$).

Patients experienced preoperative local pain in 67% of cases and paraesthesia or radiating pain in 40% of cases. A positive Tinel's sign on nerve percussion was present in 57% of cases. Only 8.5% of patients reported having no symptoms of pain associated with their tumour. Swelling occurred in 77% of cases and was more common in superficial (sensory) nerve compared with deep (mixed) nerve tumours ($p<0.001$).

In 23 patients (28%) nerve deficits were reported; seven sensory, six motor, and ten sensory-motor nerves, and in 19 (83%) of these cases, tumours were nonresectable. There were no significant differences in clinical symptoms between the different tumour types, except for intraneural ganglion cysts, in which a higher percentage of cases were associated with neurological deficits compared with other types of tumours, as follows: motor deficit in 100% ($p>0.001$), sensory deficit in 50% ($p=0.004$). In the common fibular nerve, ten cases of intra-neural ganglion cysts and six cases of schwannomas were

found. Neurological deficit was observed only in intraneural ganglion cyst cases ($p<0.001$).

In 67 out of the 82 cases (82%) in this study, a solitary peripheral nerve tumour was provisionally diagnosed clinically, due to a palpable mass or a positive Tinel's sign, with four cases presenting with entrapment syndromes and 11 cases presenting as soft tissue tumours. In one case of fibrolipomatous hamartoma with macrodactyly, the correct diagnosis was made by clinical examination.

Magnetic resonance imaging (MRI) and ultrasound

Out of 64 cases with imaging, 8 (12%) had an MRI or ultrasound diagnosis that supported the histopathological diagnosis; 42/64 cases (66%) had an uncertain diagnosis, but the tumour nerve association was confirmed, and 14/64 cases (22%) had an uncertain diagnosis, with no confirmation that the tumour was located in a nerve trunk. A correct diagnosis was made by imaging of an origin from the nerve sheath or non-neural elements in 50/64

Table VI. — Nerve origin and type of nerve tumours according to ultrasound imaging

Type of tumours with pre-operative ultrasound or MRI (N)	Ultrasound as a sole investigation (N)	Uncertain diagnosis (ultrasound different from histopathological diagnosis) (N)	Uncertain ultrasound diagnosis but nerve related (N)	Correct suggestion of diagnosis (N)
Intraneural lipoma (3)	2	2 (lipomas)		
Intraneural haemangioma (3)	2	2 (vascular tumours)		
Fibrolipomatous hamartoma (4)	1	1 (soft tissue tumour)		
Neurofibroma (6)	1		1 (neural sheath t.)	
Intraneural ganglion cyst (9)	2	1 (entrapment)		1
Schwannoma (39)	11	2 (solid soft tissue tumours)	9 (neural sheath tumours)	
Total (64)	19	8	10	1

Table VII. — Nerve origin and type of nerve tumours according to magnetic resonance imaging (MRI)

Type of tumours with pre-operative ultrasound or MRI (N)	MRI (N)	Uncertain diagnosis (MRI different from histopathological diagnosis) (N)	Uncertain MRI diagnosis but nerve related (N)	Correct suggestion of diagnosis (N)
Intraneural lipoma (3)	1	1 (lipoma)		
Intraneural haemangioma (3)	1			1 (extra-fascicular form)
Fibrolipomatous hamartoma (4)	3			3
Neurofibroma (6)	5		5 (neural sheath tumours)	
Intra-neural ganglion cyst (9)	7	4 (ganglion cysts)		3
Schwannoma (39)	28	1 (solid tissue tumour)	27 (neural sheath tumours)	
Total (64)	45	6	32	7

cases (78%). MRI and ultrasound imaging were both unable to distinguish between Schwannoma and neurofibroma (Table VI and VII).

MRI was used in 45 cases, and the nerve origin of the tumours was confirmed in 39/45 patients (87%) compared with ultrasound, which showed the nerve origin of the tumours in 11/19 cases (58%) ($p=0.02$). The diagnosis of the nerve tumour was provisionally made using ultrasound in 1/19 cases (5%) and with MRI in 7/45 cases (16%), but Fisher's exact test showed no significant differences. MRI and ultrasound confirmed the peripheral nerve sheath origin of the tumours in 32/45 cases (71%) and in 10/19 (53%) of cases, respectively ($p=0.2$). In 5/7 of the ultrasound imaged cases and 5/8 of the MRI cases, tumours that originated from nonneural elements were confused with a soft tissue tumour of the same nature compressing the nerve, with no significant differences between ultrasound and MRI. Ultrasound and MRI predicted resectability of tumours in 1/19 cases (5%) and 7/45 (16%), respectively ($p=0.4$).

In 67/82 cases in this study (82%) a solitary peripheral nerve tumour was provisionally diagnosed clinically and in 63/64 cases, a solitary peripheral nerve tumour was provisionally dia-

gnosed radiologically. Fisher's exact test showed no significant difference whether or not the clinical diagnosis has an impact on the outcome of the US or MRI diagnosis ($P>0.6$).

Surgical treatment and clinical outcome

Table VIII summarises the type of surgical treatment and clinical outcomes with regard to tumour type. Postoperatively, minor clinical complications including paraesthesia or tingling were present in 12/55 (22%) of resectable tumours, with permanent recovery after a few months. In three cases of Schwannoma, neurological deficits were present preoperatively, but no recovery was observed following surgery. Also, no recurrences were observed with resectable tumours, except in one patient with an extrafascicular intraneural haemangioma who experienced two postoperative recurrences.

Postoperative neurological deficits were present in all cases of nonresectable tumours, but after opening the epineurium, clinical symptoms were mainly reduced. In one case of fibrolipomatous hamartoma, a new sensory deficit occurred postoperatively. Three cases of neurofibroma experienced preoperative

Table VIII. — Types of treatment and follow-up

Tumour types (N)	Number and types of surgical procedures			Clinical outcome : number of patient with			
	Enucleation	Epineurotomy	Additional surgical procedures	Full recovery (N)	Persistent neurological deficit (N)	Attenuated Symptoms (N)	Recurrences (N)
Schwannoma (49)	49	0	2 tendon transfers	35	2 SM 1 S	11 (minor and transient)	0
Intra-neural lipoma (4)	4		0	3		1 (minor and transient)	0
Intraneural haemangioma (extraf.) (2)	2	0	0	2	0	0	1 (2 rec.)
Intraneural haemangioma (intraf.) (1)	0	1	0			1	
Neurofibroma (8)	0	8	1 tendon transfer		3 S 1 SM	8	1
Fibrolipomatous hamartomas (5)		5	0		1 S	4	0
Intraneural ganglion cysts (13)		13	0 3 comm.*	13	0	0	2 1 (2 rec.)

SM, sensory-motor ; S, sensory ; rec, recurrences ; f, fascicular ; comm, communication. Grey zone=nonresectable tumours. *With the neighbouring joints (systematically sought).

neurological deficit and no postoperative recovery was observed. A preoperative motor deficit, remained postoperatively for intraneural ganglion cysts with a mean postoperative complete neurological recovery time of ten months (range, 2-18 months). Three recurrences of intraneural ganglion cyst occurred; one patient experienced three recurrences.

Malignant transformation or neurofibromatosis did not occur in any of the cases retrospectively reviewed in this study.

DISCUSSION

In this retrospective study of 82 surgical cases with solitary benign peripheral nerve tumours, histopathological examination identified 55 resectable and 27 nonresectable tumours, with different postoperative clinical outcomes. The most common type of tumour in this study was Schwannoma, occurring in 49/82 (60%) of cases. Benign peripheral nerve tumour was provisionally diagnosed clinically in 82% of the patients, but the correct tumour type was not necessarily identified on clinical examination alone. MRI showed that the tumour was related to a nerve in 39/45 (87%) of cases, which was significantly more sensitive than with ultrasound. MRI could distinguish between a neural sheath origin and neural origin of the tumours in 32 of 45 cases (71%). However, neither MRI nor ultrasound were able to distinguish between Schwannoma and neurofibroma, and these imaging techniques were unable to predict tumour resectability.

Previously published studies have shown that the frequency of peripheral nerve tumours varies between 1-5% of all soft tissue tumours (7,11,12,20). This reported variation in prevalence may be explained by the fact that most authors include multiple as well as isolated nerve tumours in their published series (4,14,15). Therefore, for the clinical presentation of a solitary soft tissue mass, the diagnosis of a primary peripheral nerve tumour may not be in the clinician's provisional differential diagnosis.

Previously published studies have reported a mean time between onset of symptoms and diagnosis of peripheral nerve tumour to have an

average of two years (2,14,23), which is comparable with the findings of the present study, which was 30 months. The initial diagnosis may be difficult to make as the presenting symptoms may be confused with those of nerve entrapment syndrome, or with a soft tissue tumour that compresses a nerve trunk (20), both of which occur much more frequently. In a study by Kang et al. (13), the clinical diagnosis was established pre-operatively in only 6/20 cases (30%) of Schwannoma of the upper extremity. In a study by Nilsson et al. (20), the clinician suspected a peripheral nerve tumour in 13/20 patients (65%). As a possible explanation for the high pre-operative diagnosis in the present study (82%), patients were referred mostly for a second opinion to our specialized peripheral nerve centre. The diagnosis of a primary nerve tumour should be suspected in all cases when there is a mass associated with the brachial plexus, which has a 96% association (14), or when there is pain in the distribution of the nerve, exacerbated by percussion. Although Tinel's sign has been reported to be inconsistent (7), this sign was present in 57% of patients in the present study.

Schwannoma has been reported to be the cause of up to 80% of cases of solitary peripheral nerve tumours (11,12,15,20,21,25) and 90% of all peripheral nerve sheath tumours (11,12,15). In the present retrospective clinical study, intraneural ganglion cyst was included as a nerve tumour, which is different from other series. Although neurofibromas are commonly found in Von Recklinghausen neurofibromatosis (7,15), neurofibromas are rare as solitary peripheral nerve tumours (7,15). No clinical symptoms, presentation, or nerve locations, were pathognomonic for tumour type in this study: Intraneural ganglion cysts did have clinical and imaging findings that were characteristic, occurring in mixed nerves, specifically in the common fibular nerve at the level of the fibular neck, being associated with the presence of motor deficits in the corresponding nerves, and with a short mean time between onset of symptoms and diagnosis, with an average of four months (7,17-20,25,26). Neurofibromas also had clinical and imaging findings that were characteristic, with the preferred location being nerve roots and brachial plexus, and an occurrence in young men (14-16). Fibrolipomatous hamartomas

particularly affect the median nerve and its branches, with macrodactyly being present in 30% of the cases (2,10,27). Intra-neural haemangiomas occur in young, predominantly female adults, with symptoms of pain associated with the increase in tumour volume (17). However, a female predominance was not confirmed by our study.

The present study supported the use of MRI as the most appropriate method to diagnose a peripheral nerve tumour (23,24) (Figure 1); Ultrasound is less sensitive (4), particularly for small superficial nerves (5). The boundary between the tumour and the nerve is sometimes difficult to determine with ultrasound because the nerve may be distended and stretched over the mass (5). These findings are supported by Sandberg et al. (23) and Nilsson et al. (20), who have reported a diagnosis of peripheral nerve tumour in up to 75% of cases. Coronal and sagittal MRI demonstrates

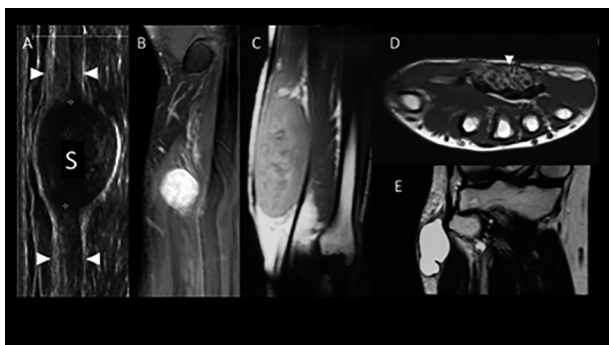


Fig. 1. — Imaging of the solitary peripheral nerve tumours using ultrasound and magnetic resonance imaging (MRI). A) Ulnar nerve Schwannoma at the wrist. Ultrasound shows an isolated globoid mass located along the nerve and eccentric to the nerve axis with a homogeneously hypo-echoic structure without posterior acoustic enhancement. white arrows= nerve. B) Ulnar nerve Schwannoma at the wrist. Coronal T1-weighted fat-saturated MRI following intravenous (IV) contrast, shows an eccentric globular mass with diffuse enhancement, in direct continuity with nerve at its proximal and distal poles. C) Median nerve neurofibroma at the wrist. Coronal T1-weighted fat-saturated MRI following IV contrast shows a fusiform swelling with heterogeneous enhancement. D) Fibrolipomatous hamartoma of the median nerve at the wrist. Axial T1-weighted MRI shows thickened and hypodense nerve fascicles surrounded by hyperintense fibro-adipose tissue giving it a coaxial ‘cable-like’ appearance of the lesion (white arrow). E) Intra-neural ganglion cyst of the common peroneal nerve. Coronal T2-weighted MRI shows the fluid nature of the tumour, and its cystic nature, arising from the superior tibiofibular joint.




Fig. 2. — Macroscopic appearance of an intra-neural ganglion cyst compared with a compressive articular synovial cyst (intra-operative views). A) Intra-neural ganglion cyst of the common fibular nerve shows a single translucent encapsulated mass in the nerve trunk. B) Appearance following epineurotomy shows the nerve fascicles on the outer surface. C) Adjacent compression from a compressive articular synovial cyst of the elbow, and ulnar nerve. D) The appearance of the nerve following nerve release.

the nerve with its fascicular appearance, entering and leaving the tumour (9,20) and can separate soft tissue tumours compressing the nerve from lesions within the nerve. In the presence of a fluid-containing cyst or a fluid-containing tumour, MRI or ultrasound may separate intraneural ganglion cysts from an adjacent compressive articular synovial cyst (25,27) (Figure 2), or an extraneural haemangioma responsible for nerve compression from an intraneural haemangioma. In the presence of a solid tumour with fat: the main differential diagnosis of intraneural lipomas is the extrinsic lipoma compressing the nerve, the most common of the soft-tissue tumours (6). MRI shows a soft-tissue tumour that is clearly defined and has the same signal characteristics as subcutaneous fat in all sequences. No enhancement is observed after contrast injection (3,22). In the case of an intraneural development, the mass appears within the nerve and the nerve fascicles appear draped around the mass (22). MRI or ultrasound imaging of the fibrolipomatous hamartoma is pathognomonic (3,27,28), with a ‘cable-like’ appearance in axial images and a ‘spaghetti-like’ appearance in coronal and sagittal images (3,9). In the presence of a solid non-fat tumour, ultrasound or MRI can easily differentiate a soft-tissue tumour compressing the nerve from a

peripheral nerve sheath tumour. Diagnosis should not be confused with plexiform neurofibroma or neuroma with a suggestive context of a nerve damage. In the present study, the radiologist reports were unable to separate formally a Schwannoma from a neurofibroma, for several reasons: There are no formal imaging criteria to differentiate between a Schwannoma and neurofibroma (3,9,20,23,24), apart from the eccentric character of the Schwannoma (3). There is some confusion in the literature regarding the terminology used for neural tumours. Neurofibromas are frequently present in the context of neurofibromatosis (NF1 or NF2), and their frequency as a solitary tumour is overestimated (20).

In this study, the clinical diagnosis on imaging did not have an impact on the clinical outcome, except for tumours involving the brachial plexus or nerve roots, with no tumour originating from nonneural elements, as previously reported (1,3,14,17). Also, as previously reported, those findings of this study showed that resection of intraneural ganglion cysts was more likely to be associated with persistent postoperative motor deficits (4,14,17-19,26,27). The resectable or nonresectable character of a nerve tumour can be formally identified, while confronting clinical examination and imaging, in cases of fibrolipomatous hamartoma (pathognomonic imaging), intraneural lipoma (solid with fat) and intraneural ganglion cyst (fluid, avascular). For such tumours, the real issue arises following confirmation of the neural origin with MRI. Intraneural haemangiomas can develop intrafascicularly, and only an epineurotomy will reveal whether the lesion invades the nervous fascicles and thus affects resectability. No formal criteria separate Schwannoma (resectable) from neurofibroma (nonresectable) and peripheral nerve sheath tumours represent 90% of peripheral nerve tumours, which explains why, in our series, MRI or ultrasound permitted confirmation of tumour resectability in only 22 cases (18%).

Following enucleation, post-operative neurological deficits are rare (7), but can occur in the case of a large tumour (Figure 3). Recovery depends on the type of nerve damage, with transient paraesthesias being common (7), occurring in 23.6% of cases in the present study. In a previously published study,

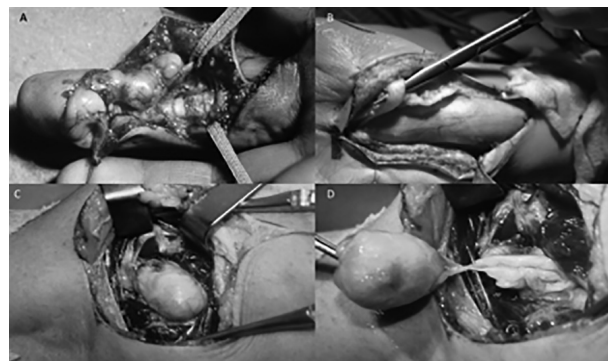


Fig. 3. —Macroscopic appearance of the solitary peripheral nerve tumours (intra-operative views). A) Intra-neural lipoma of the digital nerve is seen as a well-encapsulated tumour that spreads throughout the nerve fibres. B) Fibrolipomatous hamartoma of the median nerve, resulting in hypertrophy of the median nerve, up to 1.6 cm² in calibre, with enlargement of the nerve due to fibro-fatty endoneural, perineural, and epineural infiltration. C) Schwannoma of the common fibular nerve is seen as an encapsulated, rounded, pale yellow tumour, located near the centre and in continuity with the nerve. D.) The appearance following enucleation of the Schwannoma.

73% of patients had complete resolution of their symptoms at the time of follow-up evaluation (15). Therefore, the persistence of clinical symptoms should raise concerns about the existence of tumours in other locations, unnoticed because of their small size. When neurological signs are present preoperatively, their regression or stabilisation is a function of the size and age of the lesion (14). In the absence of degeneration or recurrence, the prognosis of a resectable tumour is usually excellent. During surgical resection, the opening of the epineurium in nonresectable tumours results in decompression of the nerve fascicles (6,7,27). A rapid and recent increase in volume, the onset of pain or neurological deficits should raise suspicion of recurrence and lead to further surgical exploration. In the presence of motor disorders, tendon transfers can be added. In exceptional circumstances, if there is a complete neurological deficit, a single procedure for nerve resection and grafting may be justified (4). No malignant transformation has been previously described, especially in the case of a solitary neurofibroma (23). Concerning intraneural ganglion cysts, if communication with a neighbouring joint is found, they can be treated by simple excision or ligation of

the articular branch and decompression of the cyst (19) ; recovery time is reported to be ten months on average (8). However, in contrast to previously published studies, in the present study, recovery was always complete. The duration of the tumour determines the neurological recovery (8). However, the recurrence rate of intraneural ganglion cysts is variable (18,19,25,26) and seems to have no link with the ligation of articular communication with the neighbouring joint.

The main limitation of this retrospective study, performed at two specialized peripheral nerve centres, was the small number of cases of rare types of tumours. The classification and management guidelines have been recently updated and were not followed during part of the study (11,12). Imaging technology has recently been developed for the diagnosis of soft tissue tumours including peripheral neural tumours, and, for example, CT scans were carried out at a time when ultrasound was not as sensitive or as reliable as at present. MRI technology has developed, and molecular imaging has also been developed recently for use in the diagnosis of soft tissue tumours.

CONCLUSION

The findings of this retrospective study showed that the diagnosis of solitary peripheral nerve tumour relies on the macroscopic appearance and definitive histology after epineurotomy. Also, the study findings showed that using imaging, it was possible to predict which tumours that originated from nonneural elements were resectable. The main differential diagnosis was extrinsic compression with MRI being the most appropriate imaging method to determine the relationship of a solitary tumour to the nerve. The resectability of peripheral nerve sheath tumours was difficult to confirm by imaging in the absence of criteria to differentiate between Schwannoma and neurofibroma. Consistent with previously reported studies, histopathology offer diagnostic certainty, and clinical outcome of surgery for solitary benign neural tumours was associated with their resectability.

REFERENCES

1. **Abreu E, Aubert S, Wavreille G et al.** Peripheral tumor and tumor-like neurogenic lesions. *Eur J Radiol.* 2013 ; 82 : 38-50.
2. **Agarwal S, Haase SC.** Lipofibromatous hamartoma of the median nerve. *J Hand Surg Am.* 2013 ; 38 : 392-397.
3. **Amrami KK, Felmlee JP, Spinner RJ.** MRI of peripheral nerves. *Neurosurg Clin N Am.* 2008 ; 19 : 559-572.
4. **Artico M, Cervoni L, Wierzbicki V et al.** Benign neural sheath tumours of major nerves: characteristics in 119 surgical cases. *Acta Neurochir Wien* 1997 ; 139 : 1108-1116.
5. **Bianchi S.** Ultrasound of the peripheral nerves. *Joint Bone Spine* 2008 ; 75 : 643-649.
6. **Chatillon CE, Guiot MC, Jacques L.** Lipomatous, vascular, and chondromatous benign tumors of the peripheral nerves: representative cases and review of the literature. *Neurosurg Focus* 2007 ; 22 : E18.
7. **Chick G, Alnot JY, Silbermann-Hoffman O.** Tumeurs isolées bénignes des nerfs périphériques. Étude rétrospective de 51 cas. *Rev Chir Orthop.* 2000 ; 86 : 825-835.
8. **Chick G, Alnot JY, Silbermann-Hoffman O.** Intra-neural mucoid pseudocysts. A report of ten cases. *J Bone Joint Surg Br.* 2001 ; 83 : 1020-1022.
9. **Chick G, Hollevoet N, Victor J, Bianchi S.** The role of imaging in isolated benign peripheral nerve tumours. A practical review for surgeons. *Hand Surg Rehabil.* 2016 ; 35 : 320-329.
10. **Cui Q, Chhabra AB, Leo BM, Pannunzio ME.** Lipofibromatous hamartoma of a digital nerve. *Am J Orthop.* 2008 ; 37 : E146-E148.
11. **Fletcher CDM, Bridge JA, Hogendoorn PCW, Mertens F.** World Health Organization Classification of tumours of soft tissue and bone. 4th Ed. IARC Press. Lyon, 2013.
12. **Jo VY, Fletcher CDM.** WHO classification of soft tissue tumours: an update based on the 2013 (4th) edition. *Pathology* 2014 ; 46 : 95.
13. **Kang HJ, Shin SJ, Kang ES.** Schwannomas of the upper extremity. *J Hand Surg Br.* 2000 ; 25 : 604-607.
14. **Kehoe NJ, Reid RP, Semple JP.** Solitary benign peripheral nerve tumours. Review of 32 year's experience. *J Bone Joint Surg Br.* 1995 ; 77 : 497-500.
15. **Kim DH, Murovic JA, Tiel RL, Kline DG.** Operative outcomes of 546 Louisiana State University Health Sciences Center peripheral nerve tumors. *Neurosurg Clin N Am.* 2004 ; 15 : 177-192.
16. **Kubierna H, Entner T, Schmidt M, Frey M.** Peripheral neural sheath tumors (PNST) – what a radiologist should know. *Eur J Radiol.* 2013 ; 82 : 51-55.
17. **Louis DS, Fortin PT.** Perineural hemangiomas of the upper extremity: report of four cases. *J Hand Surg Am.* 1992 ; 17 : 308-311.
18. **Malghem J, Lecouvet FE, Van de Berg BC et al.** Intra-neural mucoid pseudocysts: a report of ten cases. *J Bone Joint Surg Br.* 2003 ; 85 : 776-777.

19. **Naam NH, Carr SB, Massoud AHA.** Intra-neural Ganglions of the Hand and Wrist. *J Hand Surg Am.* 2015 ; 40 : 1625-1630.
20. **Nilsson J, Sandberg K, Nielsen NS, Dahlin LB.** Magnetic resonance imaging of peripheral nerve tumours in the upper extremity. *Scand J Plast Reconstr Surg Hand Surg.* 2009 ; 43 : 153-159.
21. **Oberle J, Kahamba J, Richter HP.** Peripheral nerve Schwannomas an analysis of 16 patients. *Acta Neurochir. (Wien)* 1997; 139 : 949-953.
22. **Okubo T, Saito T, Mitomi H et al.** Intra-neural lipomatous tumor of the median nerve: Three case reports with a review of literature. *Int J Surg Case Rep.* 2012 ; 3 : 407-411.
23. **Sandberg K, Nilsson J, Sørensen N, Dahlin LB.** Tumours of peripheral nerves in the upper extremity: a 22-year epidemiological study. *Scand J Plast Reconstr Surg Hand Surg.* 2009 ; 43 : 43-49.
24. **Singh T, Kliot M.** Imaging of peripheral nerve tumors. *Neurosurg Focus* 2007 ; 22 : E6.
25. **Spinner RJ, Desy NM, Rock MG, Amrami KK.** Peroneal intraneural ganglia. Part I. Techniques for successful diagnosis and treatment. *Neurosurg Focus* 2007 ; 22 : E16.
26. **Spinner RJ, Amrami KK.** What's new in the management of benign peripheral nerve lesions? *Neurosurg Clin N Am.* 2008 ; 19 : 517-531.
27. **Tahiri Y, Xu L, Kanevsky J, Luc M.** Lipofibromatous hamartoma of the median nerve: a comprehensive review and systematic approach to evaluation, diagnosis, and treatment. *J Hand Surg Am.* 2013 ; 38 : 2055-2067.