



## Morton's metatarsalgia : Pathogenesis, aetiology and current management

Hazem HASSOUNA, Dishan SINGH

*From the Royal National Orthopaedic Hospital, Stanmore, United Kingdom*

The aetiology and pathogenesis of Morton's Neuroma remain controversial. It is not true neuroma and therefore, it is better referred to as Morton's metatarsalgia. This article reviews the various thoughts regarding the pathogenesis of this condition. Chronic trauma, ischaemia, bursitis and entrapment neuropathy have been proposed as possible aetiological factors. Careful history and clinical examination is essential to establish the diagnosis. However, if the clinical picture is doubtful, radiological investigation is recommended. Ultrasound, in the hand of an experienced radiologist, is the modality of choice. Conservative measures such as footwear modification and targeted injection of the hot spot are attempted before considering surgical intervention. Patients must be counselled preoperatively. The success of neurectomy rarely exceeds 83%. When surgery is considered, the dorsal approach is associated with less wound complications than the plantar approach. The neuroma is resected as proximally as possible in order to include plantar digital branches. For recurrent neuromas, a plantar approach is appropriate.

**Key words :** Morton's neuroma ; Morton's metatarsalgia ; pathogenesis ; aetiology ; management.

### INTRODUCTION

By Morton's metatarsalgia is meant throbbing, burning pain and tenderness on the plantar surface of the foot, usually over the 3<sup>rd</sup> and 4<sup>th</sup> metatarsophalangeal joints, with pain radiating along the corresponding toes.

### PATHOGENESIS AND AETIOLOGY THEORIES

#### Chronic Trauma Theory

Many authors have implied or suggested that mechanical effects in the forefoot during walking and weight bearing may cause "repeated trauma" or "irritation" to plantar intermetatarsal structures, particularly to the nerve (3, 8, 9, 31, 42). Some of the explanations for a mechanical effect on the nerve have been based on consideration of the functional anatomy in the forefoot (8, 31); others have suggested a mechanism that postulates an abnormality of the metatarsophalangeal joint due to subluxation, or of the tarsometatarsal joints due to degenerative changes (30), whereas the explanation by

---

■ Hazem Z. Hassouna, AFRCSEd, Orthopaedic Registrar  
*Princess Royal Hospital, Haywards Heath, United Kingdom*

■ Dishan Singh, FRCS (Orth), Consultant Orthopaedic Surgeon

*Department of Foot and Ankle Surgery, Royal National Orthopaedic Hospital, Stanmore, HA7 4LP, United Kingdom*

Correspondence : Hazem Z. Hassouna, AFRCSEd, Department of Orthopaedic Surgery, Princess Royal Hospital, Lewis Road, Haywards Heath, West Sussex, RH16 4EX, United Kingdom

E-mail : [hhassouna@gmail.com](mailto:hhassouna@gmail.com)

© 2005, Acta Orthopædica Belgica.

---

Mulder (32) suggests an enlarged intermetatarsal bursa.

The third digital nerve, unlike its neighbours, is of double origin (8), being formed through the anastomosis of branches from both medial and lateral plantar nerves. It is consequently somewhat thicker than the other digital nerves – a fact which in itself might indicate increased vulnerability to trauma. But more importantly, the arc described by its two constituent branches forms a transverse sling across the outer of superficial aspect of the flexor digitorum brevis muscle.

Whereas the other digital nerves, lying in deep grooves between the muscles of the foot, enjoy a certain degree of mobility in a longitudinal direction, the fourth nerve is more or less anchored posteriorly. Stretching of the aforementioned loop occurs during dorsiflexion of the foot and toes, and in walking the degree of stretch is intensified by contraction of the flexor belly.

### The Ischaemic Theory

Nissen suggested that the nerve lesion and the fibrosis seen in Morton's metatarsalgia are the result of ischaemia (33); he observed several degenerative changes in the plantar digital artery: disruption of the arterial wall, thrombosis, and incomplete recanalisation. He suggested that the intraneural vessels develop changes secondary to segmental narrowing of the plantar digital artery from localised degenerative changes in that vessel. Ringertz and Unander-Scharin (42) however, noted that narrowing of this artery is frequently present also in control material, and their observation was confirmed by Meachim in 1970 (28). One must, therefore, presume that the pain in the Morton cases is caused by one or more additional factors.

The theory expounded by Nissen (33), that Morton's disease depends on a primary endarteritis and secondary fibrosis as a consequence of circulatory disturbances, can thus be supported as the endarteritis - fibrosis complex is so common in the interdigital neurovascular trunks of the foot (42), that one wonders whether it may not after all be physiological. Morton's disease, on the other hand, is comparatively rare. It is possible that the high

incidence of intraneural oedema and demyelination characteristic of the Morton cases may provide a clue for further investigation into the true pathogenesis of the disease.

When reviewing these various explanations it should be noted that the "mechanical hypothesis" and the "ischaemic hypothesis" are not mutually exclusive: for example, localised effects on a nerve from compression and stretching are believed to be mediated mainly by a focal ischaemia; also a local mechanical effect may be responsible for the structure changes and segmental narrowing observed in the plantar digital artery, and could thus be an indirect cause of ischaemia in the affected cleft. Sclerosis of the arteries and narrowing of their lumen contribute to ischaemia and further nerve atrophy. The nerves and arteries caught in this reactive scar become more sensitive to pressure and cause characteristic pain (21).

### The Intermetatarsal Bursitis Theory

The intermetatarsal bursa has also been implicated as a causative mechanism of Morton's symptoms. Mulder (32) found a neuroma to be adherent to the intermetatarsal bursa; but he did not directly relate the symptoms to the presence of an adherent bursa. Bossley and Cairney (10) explained the significance of the intermetatarsal bursa. It lies dorsal to the intermetatarsal ligament in the 2<sup>nd</sup> / 3<sup>rd</sup> space; it extends distally to the ligament and turns dorsally, passing around its distal edge in close relation to the bursa. In the 2<sup>nd</sup> and 3<sup>rd</sup> intermetatarsal space the neuro-vascular bundle lies very close to the bursa.

Bossely and Cairney (10) postulated that inflammation of the bursa will adversely affect the nearby nerve, causing fibrosis, leading to the classical symptoms. Excision of the nerve may alleviate the symptoms but it does not necessarily mean that the nerve was the cause of the symptoms. The pain can be reproduced by lateral compression of the metatarsals, squeezing the bursa between metatarsal heads, thus causing the bulging of bursa. Local injection of the bursa improves symptoms, albeit temporarily.

In 1982, Awerbuch *et al.* (2) also suggested a strong correlation between Morton's neuroma, intermetatarsal bursa and rheumatoid arthritis. They concluded that the inflamed bursa alters the interdigital nerves (even more so when enlarged) and exerts direct compressive effect on the adjacent nerve.

### Entrapment Theory

Gauthier (18) believed that Morton's neuroma is primarily a nerve entrapment condition. During the last stage of the stance phase of gait walking, the nerve is repeatedly squeezed between the plantar aspect of the foot and the anterior edge of the intermetatarsal ligament. The force on the nerve may be exaggerated by the failure of the normal function of the first ray. The result is an irritation of the nerve and the subsequent development of a neuroma. His novel surgical technique consists of release of the anterior edge of the intermetatarsal ligament without resection of the neuroma. In 206 patients treated with this technique, 83% reportedly had rapid and stable improvement.

Graham and Graham (19) agreed with the entrapment theory as they found that there was an increased diameter of the affected nerve, an increased number of blood vessels per fascicle and increased fascicle number and diameter. Another observation was that these changes occur at a level corresponding to the distal edge of the intermetatarsal ligament. This led to the belief that Morton's neuroma is a nerve entrapment syndrome involving the transverse intermetatarsal ligament.

### CLINICAL PRESENTATION AND DIAGNOSIS

Patients with Morton's Neuroma are commonly middle aged (78%-95%) females (average age : 50 years). The main complaint is paroxysmal lancinating pain (50, 53) in the forefoot, often radiating to the toes. It is associated with numbness and burning sensation in the involved toes. Occasionally decreased sensation in those toes may be the only symptom.

The symptoms are aggravated by wearing tight shoes with high heels and often relieved by taking shoes off. The high heel, narrow toe-box shoes increase the plantar pressure over the metatarsal heads, causing compression, stretching, tethering of the underlying digital nerves. The pain may also be relieved by massaging forefoot or toes (23).

The pain may be atypically localised to one toe or the plantar aspect of the forefoot.

In other cases, the pain may be diffuse radiating to the ankle and associated with tingling sensation and hyperaesthesia between the clefts (26). It is essential to differentiate pain arising from a neuroma from other causes e.g., synovitis and bursitis (50). Neuroma pain is usually localised to the affected web space, radiating to the corresponding toes.

In synovitis, pain is often localised distal to the metatarsal heads; it should not be mistaken for neuroma as excision of the digital nerve will not alleviate the pain. Attempts to dorsally subluxate the digit by manipulation may produce pain due to tethering of nerve, which is more suggestive of synovitis (16).

Pain due to bursitis may be occasionally difficult to distinguish from that due to a neuroma since the locations are similar.

### RADIOLOGICAL IMAGING

#### Ultrasound

The typical sonographic appearance is that of an ovoid, hypoechoic mass located just proximal to the metatarsal heads in the intermetatarsal space, most often between the second and third or third and fourth metatarsals (39).

Ultrasonography has been successfully used in the diagnosis of primary interdigital neuroma (35, 44). Ultrasonography is easily accessible and relatively inexpensive (36). Other advantages of ultrasonography include :

1. No risk of radiation hazards
2. Faster and better tolerated by patients
3. Allows real time correlation of the scan appearance with any localised tenderness or pain reported by the patients.

The sensitivity of ultrasonography for Morton's neuroma is reported by some investigators to be high, ranging between 94% and 100% (39, 51). However, the scan tends to overestimate the size of the lesion (24). This is thought to be due to signal arising from surrounding mucoid degeneration and intermetatarsal bursa (38).

Shapiro and Shapiro (44) claimed 98% accuracy for pre-operative ultrasonography but they reported no clinical outcome. Redd *et al.* (39) showed that neuromas were prevalent in both symptomatic and asymptomatic patients, but only those lesions > 5 mm caused symptoms.

Although many authors agree that 95% of excised neuromas were at least 5 mm in diameter, the overall data suggests that the previously prescribed threshold may not indicate as clear cut a management guideline as reported (36).

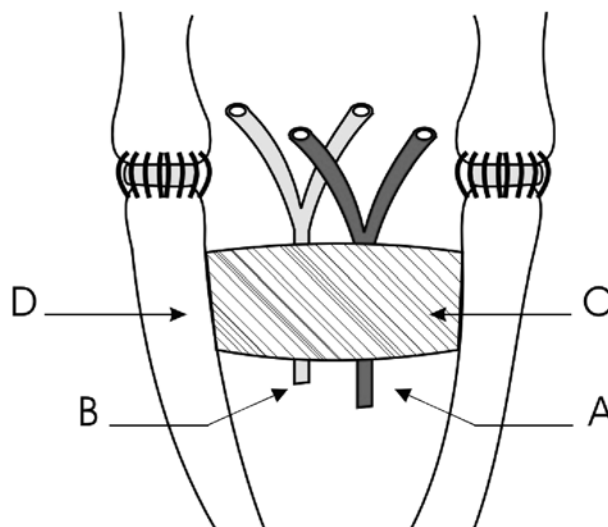
However, Resch *et al* (40) in 1994 reported little or no value in the use of routine ultrasound or MRI for the diagnosis of Morton's Neuroma. Similarly Sharp *et al* (45) found that there is no requirement for ultrasound or MRI in patients who are thought to have a Morton's neuroma. They concluded that small lesions, < 6 mm in size, are equally able to cause symptoms as larger lesions.

Morscher *et al* (29) suggested that most patients with a clinical diagnosis of Morton's neuroma do not have a significantly enlarged nerve and that diagnosis is best made clinically with a local anaesthetic challenge at the site of maximal pain.

Therefore, the sonographic identification of a mass in the appropriate location supports the clinical diagnosis, whereas failing to find a sonographic mass does not exclude the diagnosis (48).

### Magnetic Resonance Imaging (MRI)

There have been some reports of the successful use of magnetic resonance (43, 47). The typical appearance of a neuroma on MRI is a localised soft tissue mass of increased signal intensity. The routine use of MRI is not recommended (50). Unlike ultrasound, MRI is an expensive investigation and is not often readily available. Also, recent evidence by Sharp *et al* (45) and Resch *et al* (40) suggests that this modality is of little or no value in the diagnosis of Morton's Neuroma.



*Fig. 1.* — Schematic dorsal view of the intermetatarsal space. (A) blood vessel ; (B) nerve ; (C) deep intermetatarsal ligament ; (D) metatarsal.

## TREATMENT

### CONSERVATIVE MANAGEMENT

The success of conservative treatment decreases with the length of time that the symptoms have been present, but it should always be tried first (50). Baths of hot and cold water are helpful, and if pain is acute, application of topical anaesthetics may alleviate pain. Foot elevation and massage may also be useful (23). Also, abstaining from activities that produce the pain has been suggested.

### Footwear

This generally consists of modifying footwear to properly accommodate the forefoot and placing metatarsal pads proximal to the inflamed nerve (6, 23). Fashionable high heeled and pointed shoes should be avoided, because they increase lateral compression of metatarsal heads (26).

Wider shoes with lower heels and a round toe box reduce metatarsal head pressure. The forefoot pressure can be reduced by using soft metatarsal pads placed just proximal to the metatarsal head, a metatarsal bar to shift pressure proximally or a rocker bottom sole. A stiff soled shoe may decrease pain due to limitation of MTP extension during toe off phase.

In a study by Bennett *et al.* (6), 41% of patients who were treated with footwear modification and metatarsal pads reported improvement in their pre-treatment symptoms.

### Foot orthoses

Total contact orthoses have been suggested to transfer pressure into the longitudinal and transverse metatarsal arch (26).

In their study, Mann and Reynolds (26) found that the majority of patients have symptomatic relief from conservative measures, but the localised plantar pain has rarely changed. Since most of the patients were females, dissatisfied with shoe modification, 70% of them opted for surgical treatment.

Treatment with anti inflammatory medication has no role in the management of Morton's neuroma (26).

### Local web space injection

The lack of long term therapeutic benefit of injection is disputed by the work of Greenfield *et al* (20). In a study of 67 cases of Morton's neuroma treated with a series of xylocaine-triamcinolone injection, immediate relief was achieved in 30% of patients, while 50% of patients had partial relief. At 2 years, 80% of patients indicated complete relief of pain or only slight pain. This study makes a strong case for at least a trial of local injection.

Rasmussen *et al* (37) focused their study on a single injection of betamethasone and bupivacaine to a single (3<sup>rd</sup>) web space. The results showed that 80% of the cases treated, had pain relief initially. Of these, 46% had relief for greater than 3 months. Only 47% of the patients ultimately had surgery. The majority of the other patients continued to have variable degrees of symptoms. After an average follow-up period of 4 years, lasting significant relief was seen in only 11% (3 of 27) feet. They concluded that a single local injection of corticosteroid can be used as a temporising measure for the symptoms of interdigital neuroma, but does not preclude subsequent surgery.

### OPERATIVE MANAGEMENT

Numerous surgical techniques have been advocated for the treatment of Morton's neuroma,

including nerve resection through plantar or dorsal approach, and release of intermetatarsal ligaments, with or without neurolysis. Each method of treatment has its merits as well as its drawbacks.

### The plantar approach

Advocates of plantar incision for neurectomy (7, 33) maintain that it provides direct approach as the nerve is superficial in this location. However any complication associated with plantar incision can be problematic. This includes painful hypertrophic scar over the weight bearing area of the forefoot.

However, the plantar incision has been widely practised by many authors (9, 11, 25, 41), none of which described major problems with wound healing or formation of painful hypertrophic scar.

Most surgeons currently reserve the use of a plantar approach for the treatment of recurrent neuromas (7, 22).

### The dorsal approach

The dorsal approach was first described by McElvenny (27). It is technically easier, as it allows immediate weight bearing but adequate nerve resection must be performed. A small incision over the web space is not adequate to visualise the entire nerve and branches. This concept was highlighted by Amis *et al* (1) who showed that plantar directed nerve branches are consistently present along the course of the common interdigital nerve. The branches are found immediately proximally to the intermetatarsal ligament.

These findings are clinically significant for two reasons :

First, if neurectomy is performed one to two cm proximal to the nerve bifurcation, as has been suggested by Betts (8) and Mann and Reynolds (26), the plantar nerve branches may prevent the retraction of the transected nerve stump proximally into the intrinsic muscle and therefore off the weight bearing surface of the foot.

Second, if there is intra operative injury to one of these plantar branches, each of which represents a small nerve bundle, traumatic neuroma with the recurrence of symptoms may occur. It is therefore important to identify and resect these nerve branch-

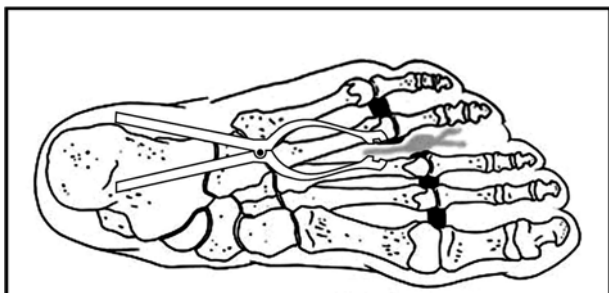


Fig. 2. — Schematic diagram showing laminar spreader used to expose neuroma.

es, a procedure which cannot be performed through a limited distal web space incision (1).

Based on these anatomical findings, Amis *et al* (1) recommend the excision of the common digital nerve at least 3.0 cm proximal to the proximal edge of the transverse metatarsal ligament (fig 2). He hypothesised that this technique may lower the incidence of symptoms recurrence.

In a long term follow-up study, Coughlin *et al* (12) adopted the same approach. Their results showed an overall satisfaction rate of 85% with five years follow-up.

#### Transverse metatarsal ligament release with or without neurolysis

As an alternative to neurectomy, some clinicians have proposed division of the intermetatarsal ligament with or without neurolysis (13, 18, 34), as an effective treatment for Morton's neuroma. After resection of any interdigital nerve, neural regeneration and neuroma formation may occur. If a neuroma forms on the plantar aspect of the foot, particularly distally in the region of the metatarsal heads, it is likely to be symptomatic.

Gauthier (18) was the first to report on this procedure. He treated 206 patients by dividing the intermetatarsal ligament and performing epineural neurolysis. There was resolution of symptoms in 83% of the patients, and improvement but persistence of some pain in 15%.

Diebold *et al* (15), and Dellon (13) reported similar results, although they had smaller patients groups. Because these researchers believe that Morton's Neuroma is a nerve entrapment syndrome

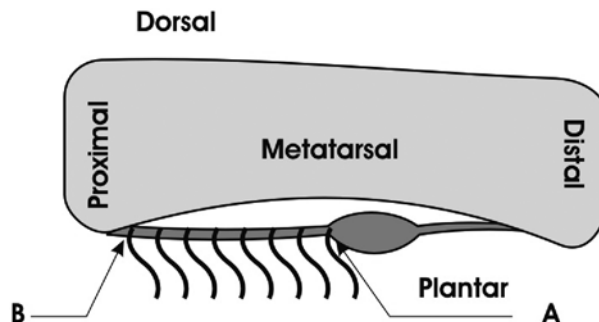


Fig. 3. — Schematic lateral view of plantar branches of the digital nerve. (A) Previously recommended level of neurectomy; (B) currently recommended level of neurectomy (3 cm proximal to ligament) to include plantarly directed nerve branches.

that should be treated like other nerve entrapments – that is, with release of the offending structures – they released the intermetatarsal ligament without neurectomy, but recommended neurolysis in addition to ligament release.

Okafor *et al* (34), reported very high patient satisfaction rate amongst patients treated with neurolysis (98% satisfaction overall). These results, to our knowledge, have not been reproduced.

In other authors' opinion (4, 18), surgical approach to Morton's neuroma is ligament release, not neurectomy, without simultaneous neurolysis. The theoretical advantages of this procedure are that the nerve remains intact, no sensory loss occurs, and there is no potential for recurrent and possibly refractory plantar neuroma formation, which may be more difficult to treat than the original problems. The preliminary results have been good, although long-term follow-up is not yet available. The morbidity of the operation is minimal, and the clinical impression is that patients are able to resume activities more rapidly than after neurectomy. No study has indicated that widening of the forefoot occurs by dividing either one or both of the second and third web-space intermetatarsal ligaments. Strapping the forefoot is therefore not necessary during recovery and rehabilitation.

Other investigators (26) have identified ligamentous tissue that reforms between the metatarsals after re-operation through a dorsal approach for

recurrent neuroma. Although this is fibrous scar, it seems to represent some reconstitution of the intermetatarsal ligament. Mann and Reynolds (26) have contended that the presence of this fibrous scar argues against simple division of the intermetatarsal ligament as the sole treatment for Morton's neuroma. Although this theory is anatomically correct, it is not supported by long-term clinical results, as Morton's neuroma rarely recurs with this technique.

### Neurectomy

Although neurectomy is a simple and popular procedure for the treatment of Morton's Neuroma, the results have been disappointing.

It can be performed via a dorsal web-space, plantar longitudinal or transverse incision. Many authors recommend the dorsal approach with wide soft tissue exposure through a 3-cm longitudinal dorsal incision centred over the involved interspace. The transverse intermetatarsal ligament is placed under tension with a self retaining retractor and is divided. A periosteal elevator is used to delineate the involved nerve both proximally and distally. The digital nerve distal to the bifurcation of the common digital nerve is transacted. The dissection is then carried out proximally into the interspace, isolating the common digital nerve 3 cm proximal to the bifurcation, where it is transacted (12). It is important to sever any adjacent capsular nerve branches as they may prevent retraction of the nerve stump, increasing the possibility of a

recurrent symptomatic neuroma. The patient is allowed to weight bear immediately, as pain permits, post operatively.

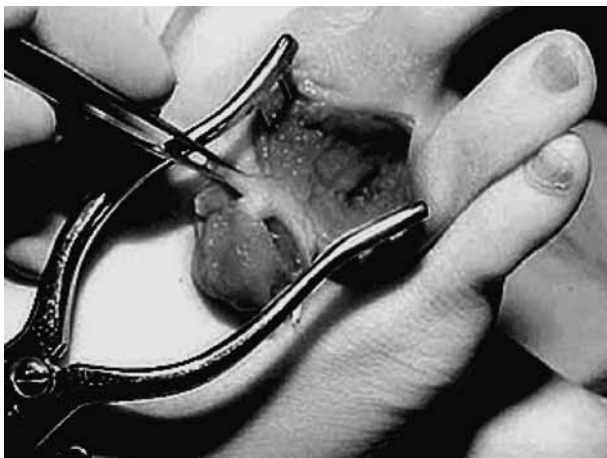Some surgeons advocate a plantar approach for excision of primary interdigital neuroma. Betts (8) and Nissen (33) independently described resection of the digital nerve through a plantar incision without complication. Richardson *et al.* (41) reported a 5% incidence of incision related complications in 172 plantar procedures. The most commonly reported complications are localised scar tenderness, wound drainage and plantar keratosis.

The plantar incision can be made longitudinally or transversely, depending on the location of symptoms and the surgeon's personal preference. The longitudinal plantar incision, which is positioned parallel to the elastic fibres of the plantar skin to decrease tension on the wound, provides nearly unlimited access to the digital nerve. Proponents of the transverse plantar incision cite the excellent exposure and the position of the scar distal to the metatarsal heads which should decrease the incidence of the painful scar (49).

Although the plantar approach facilitates visualisation of the nerve and has been shown to have a low complication rate, incisional complications, when they do occur, can be devastating. It is rare, on the other hand, to experience pain from a symptomatic scar on the dorsum of the foot. Patients may bear weight immediately after surgery with a dorsal incision; in contrast, a plantar approach necessitates a non weight bearing period. Most surgeons are more comfortable with a dorsal incision.

Table I. — Review of surgical treatment results \* D = Dorsal, P = Plantar, TML = Transverse Metatarsal Ligament.

Author	Cohort Follow-up (Months)	Mean used *	Approach of TML ligament	Division	Outcome
Gauthier (18)	206	21	D,P	Yes	83% improved
Mann & Reynolds (26)	56	22	D	Yes	80% improved
Bennett (6)	24	42	D	Yes	96% satisfactory
Benedetti (5)	15	68	D,P	No	84% acceptable
Diebold (15)	40	60	D	No	92% satisfied



**Fig 4.** — A typical Morton's interdigital neuroma. Surgical dissection, through a dorsal incision shows thickened and inflamed common digital nerve.

Table I summarises the results of surgical treatment.

### Complications of neurectomy

The cutaneous innervation of the interdigital skin is variable. However, excision of the interdigital nerve is predictably associated with numbness of the web space and, to some extent, of the plantar aspect of the foot just proximal to the level of the web space. Although most patients tolerate the numbness between the toes, loss of sensation that occurs more proximally on the weight bearing surface of the foot can be quite troublesome. Even after a successful neuroma excision, a patient may still have some difficulty with shoe wear; it is reported that 75% of patients are still limited as to choice of shoe type particularly with reference to high heels (26). The overall satisfaction rate from neurectomy rarely exceeds 80% (17, 26).

### Recurrent neuroma

Persistent pain may be quite problematic after excision of a neuroma and reported symptoms are similar to, if not worse than, those present before neurectomy. To prevent amputation neuroma when the interdigital nerve is cut, some clinicians have recommended using silicon caps, metal ligation clamps, or topical corticosteroid or implanting the

resected nerve stump into an interosseous muscle (14, 54). Treating recurrent Morton's neuroma by a technique that combined resection of the interdigital neuroma through a plantar approach and implantation of the proximal end of the nerve into an intrinsic muscle in the arch of the foot, has yielded excellent results in 80% of cases of recurrent interdigital neuromas (52).

However, an anatomical study by Amis *et al* (1) seems to indicate that adequate proximal dissection of the nerve should decrease the incidence of recurrence. This theory is further supported by Johnson *et al* (22) in 1988 who demonstrated that amputation neuroma and incomplete resection of the initial neuroma results in persistent pain.

In one series the cause of recurrent symptoms was identified as adhesion of a traumatic neuroma to the plantar aspect of the metatarsal head (26). However this finding has not been supported by other studies (1). Although this situation may occur in some patients, in most, the traumatic neuroma is directly in the web space, tethered to the skin through plantar neural branches, as demonstrated by Amis *et al* (1). In some patients the traumatic neuroma adheres to the undersurface of the intermetatarsal ligament. In others it lies proximal to the transverse metatarsal ligament and adheres to the skin.

Most plantar nerve branches are found on the distal portion of the digital nerve, adjacent to the intermetatarsal ligament, which corresponds to the site at which neurectomy is performed. If the neurectomy is performed 1 cm proximal to the bifurcation of the nerve, plantar nerve branches may still be present. Therefore it is unlikely that pulling the nerve distally out of the wound will enable the cut end to retract proximally off the weight bearing area of the forefoot, since nerve branches tether the nerve stump distally. The advocates of neurectomy for primary digital neuroma, therefore recommend that the nerve be resected at least 3 cm proximal to the intermetatarsal ligament to allow retraction of the nerve stump into the intrinsic muscle, preventing recurrent traumatic neuroma formation (12).

In 2004, a study by Stamatis and Myerson (46) examined the result of re-exploration of 60 inter-spaces (49 patients, 49 feet) for recurrence or per-



sistent symptoms after one or more previous procedures for excision of an interdigital neuroma. Evaluation included review of records and radiographs, clinical assessment, and a questionnaire regarding satisfaction, pain, restriction of footwear and activity. In total, 31% of patients were completely satisfied, 27% were satisfied with minor reservations, 20% were satisfied with major reservations and 22% were dissatisfied with the outcome. Over half of the patients had no or mild pain, 59% had moderate or severe restriction of footwear and 16.3% had moderate restriction of activity. It is concluded that persistent or recurrent symptoms after transection of a nerve present a challenging problem for both surgeon and patient. It is essential that there is a thorough pre-operative discussion with the patient, providing the rates of failure and the increased likelihood of restriction of footwear and activity after revision surgery.

### CONCLUSION

Careful history and clinical examination is essential to establish the diagnosis. However, if the clinical picture is doubtful, radiological investigation is recommended. Ultrasound, in the hand of an experienced radiologist, is the modality of choice. Conservative measures such as footwear modification and targeted injection of the hot spot is attempted before considering surgical intervention. Patients must be counselled preoperatively. The success of neurectomy rarely exceeds 83%. When surgery is considered, the dorsal approach is associated with less wound complications than the plantar approach. The neuroma is resected as proximally as possible in order to include plantar digital branches. For recurrent neuromas, a plantar approach is appropriate.

### REFERENCES

1. **Amis JA, Siverhus SW, Liwnicz BH.** An anatomic basis for recurrence after Morton's neuroma excision. *Foot Ankle* 1992 ; 13 : 153-156.
2. **Awerbuch MS, Shephard E, Vernon-Roberts B.** Morton's metatarsalgia due to intermetatarsophalangeal bursitis as an early manifestation of rheumatoid arthritis. *Clin Orthop* 1982 ; 167 : 214-221.
3. **Baker L, Kuhn HH.** Morton's Metatarsalgia. Localised degenerative fibrosis with neuromatous proliferation of the fourth plantar nerve. *South Med J* 1944 ; 37 : 123.
4. **Barrett SL, Pignetti TT.** Endoscopic decompression for intermetatarsal nerve entrapment-the EDIN technique : preliminary study with cadaveric specimens ; early clinical results. *J Foot Ankle Surg* 1994 ; 33 : 503-508.
5. **Benedetti RS, Baxter DE, Davis PF.** Clinical results of simultaneous adjacent interdigital neurectomy in the foot. *Foot Ankle Int* 1996 ; 17 : 264-268.
6. **Bennett GL, Graham CE, Mauldin DM.** Morton's interdigital neuroma : a comprehensive treatment protocol. *Foot Ankle Int* 1995 ; 16 : 760-763.
7. **Beskin JL, Baxter DE.** Recurrent pain following interdigital neurectomy : a plantar approach. *Foot Ankle* 1988 ; 9 : 34-39.
8. **Betts L.** Morton's metatarsalgia neuritis of the fourth digital nerve. *Med J Aust* 1940 ; 1 : 514.
9. **Bickel WH, Dockerty MB.** Plantar neuromas, Morton's toe. *Surg Gynecol Obstet* 1947 ; 84 : 111.
10. **Bossley CJ, Cairney PC.** The intermetatarsophalangeal bursa : its significance in Morton's metatarsalgia. *J Bone Joint Surg* 1980 ; 62-B : 184-187.
11. **Burns AE, Stewart WP.** Morton's neuroma. Preliminary report on neurectomy via transverse plantar incision. *J Am Podiatry Assoc* 1982 ; 72 : 135-141.
12. **Coughlin MJ, Pinsonneault T.** Operative treatment of interdigital neuroma. A long-term follow-up study. *J Bone Joint Surg* 2001 ; 83-A : 1321-1328.
13. **Dellon AL.** Treatment of Morton's neuroma as a nerve compression. The role for neurolysis. *J Am Podiatr Med Assoc* 1992 ; 82 : 399-402.
14. **Dellon AL.** Treatment of recurrent metatarsalgia by neuroma resection and muscle implantation : case report and proposed algorithm of management for Morton's "neuroma". *Microsurgery* 1989 ; 10 : 256-259.
15. **Diebold PF, Daum B, Dang-Vu V, Litchinko M.** True epineural neurolysis in Morton's neuroma : a 5-year follow-up. *Orthopedics* 1996 ; 19 : 397-400.
16. **Fortin PT, Myerson MS.** Second metatarsophalangeal joint instability. *Foot Ankle Int* 1995 ; 16 : 306-313.
17. **Frischia DA, Strom DE, Parr JW et al.** Surgical treatment for primary interdigital neuroma. *Orthopedics* 1991 ; 14 : 669-672.
18. **Gauthier G.** Thomas Morton's disease : a nerve entrapment syndrome. A new surgical technique. *Clin Orthop* 1979 ; 142 : 90-92.
19. **Graham CE, Graham DM.** Morton's neuroma : a microscopic evaluation. *Foot Ankle* 1984 ; 5 : 150-153.
20. **Greenfield J, Rea J Jr, Ilfeld FW.** Morton's interdigital neuroma. Indications for treatment by local injections versus surgery. *Clin Orthop* 1984 ; 185 : 142-144.
21. **Ha'Eri GB, Fornasier VL, Schatzker J.** Morton's neuroma : pathogenesis and ultrastructure. *Clin Orthop* 1979 ; 141 : 256-259.

22. **Johnson JE, Johnson KA, Unni KK.** Persistent pain after excision of an interdigital neuroma. Results of reoperation. *J Bone Joint Surg* 1988 ; 70-A : 651-657.
23. **Jones R, Tubby AH.** Metatarsalgia or Morton's Disease. *Ann Surg* 1897 ; 28 : 297.
24. **Jones S, Bygrave C, Betts R.** Morton's Neuroma : A sonographic-surgical evaluation. *The Foot* 1999 ; 9 : 189-192.
25. **Karges DE.** Plantar excision of primary interdigital neuromas. *Foot Ankle* 1988 ; 9 : 120-124.
26. **Mann RA, Reynolds JC.** Interdigital neuroma – a critical clinical analysis. *Foot Ankle* 1983 ; 3 : 238-243.
27. **McElvenny RT.** The etiology and surgical treatment of intractable pain about the fourth metatarsophalangeal joint (Morton's toe). *J Bone Joint Surg* 1943 ; 25-A : 675.
28. **Meachim G, Abberton MJ.** Histological findings in Morton's Metatarsalgia. *J Pathology* 1970 ; 103 : 209-217.
29. **Morscher E, Ulrich J, Dick W.** Morton's intermetatarsal neuroma : morphology and histological substrate. *Foot Ankle Int* 2000 ; 21 : 558-562.
30. **Morton DJ.** *The Human Foot : Its Evolution, Physiology and Functional Disorders*, 1935 ; 184 and 211. Columbia University Press, New York.
31. **Morton TG.** A peculiar and painful affection of the fourth metatarsophalangeal articulation. *Am J Med Sci* 1876 ; 71 : 37.
32. **Mulder JD.** The causative mechanism in Morton's metatarsalgia. *J Bone Joint Surg* 1951 ; 33-B : 94-95.
33. **Nissen KI.** Plantar digital neuritis (Morton's metatarsalgia). *J Bone Joint Surg* 1948 ; 30-B : 84.
34. **Okafor B, Shergill G, Angel J.** Treatment of Morton's neuroma by neurolysis. *Foot Ankle Int* 1997 ; 18 : 284-287.
35. **Oliver TB, Beggs I.** Ultrasound in the assessment of metatarsalgia : a surgical and histological correlation. *Clin Radiol* 1998 ; 53 : 287-289.
36. **Pollak RA, Bellacosa RA, Dornbluth NC et al.** Sonographic analysis of Morton's neuroma. *J Foot Surg* 1992 ; 31 : 534-537.
37. **Rasmussen MR, Kitaoka HB, Patzer GL.** Nonoperative treatment of plantar interdigital neuroma with a single corticosteroid injection. *Clin Orthop* 1996 ; 326 : 188-193.
38. **Read JW, Noakes JB, Kerr D et al.** Morton's metatarsalgia : sonographic findings and correlated histopathology. *Foot Ankle Int* 1999 ; 20 : 153-161.
39. **Redd RA, Peters VJ, Emery SF et al.** Morton neuroma : sonographic evaluation. *Radiology* 1989 ; 171 : 415-417.
40. **Resch S, Stenstrom A, Jonsson A, Jonsson K.** The diagnostic efficacy of magnetic resonance imaging and ultrasonography in Morton's neuroma : a radiological-surgical correlation. *Foot Ankle Int* 1994 ; 15 : 88-92.
41. **Richardson EG, Brotzman SB, Graves SC.** The plantar incision for procedures involving the forefoot. An evaluation of one hundred and fifty incisions in one hundred and fifteen patients. *J Bone Joint Surg* 1993 ; 75-A : 726-731.
42. **Ringertz N, Unander-Scharin M.** Morton's disease : a clinical and patho-anatomical study. *Acta Orthop Scand* 1950 ; 19 : 327.
43. **Sartoris DJ, Brozinsky S, Resnick D.** Magnetic resonance images. Interdigital or Morton's neuroma. *J Foot Surg* 1989 ; 28 : 78-82.
44. **Shapiro PP, Shapiro SL.** Sonographic evaluation of interdigital neuromas. *Foot Ankle Int* 1995 ; 16 : 604-606.
45. **Sharp RJ, Wade CM, Hennessy MS, Saxby TS.** The role of MRI and ultrasound imaging in Morton's neuroma and the effect of size of lesion on symptoms. *J Bone Joint Surg* 2003 ; 85-B : 999-1005.
46. **Stamatis ED, Myerson MS.** Treatment of recurrence of symptoms after excision of an interdigital neuroma. A retrospective review. *J Bone Joint Surg* 2004 ; 86-B : 48-53.
47. **Terk MR, Kwong PK, Suthar M et al.** Morton neuroma : evaluation with MR imaging performed with contrast enhancement and fat suppression. *Radiology* 1993 ; 189 : 239-241.
48. **Thain LM, Downey DB.** Sonography of peripheral nerves : technique, anatomy, and pathology. *Ultrasound Q* 2002 ; 18 : 225-245.
49. **Viladot A.** Morton's neuroma. *Int Orthop* 1992 ; 16 : 294-296.
50. **Weinfeld SB, Myerson MS.** Interdigital neuritis : Diagnosis and treatment. *J Am Acad Orthop Surg* 1996 ; 4 : 328-335.
51. **Williams JW, Meaney J, Whitehouse GH et al.** MRI in the investigation of Morton's neuroma : which sequences ? *Clin Radiol* 1997 ; 52 : 46-49.
52. **Wolfort SF, Dellon AL.** Treatment of recurrent neuroma of the interdigital nerve by implantation of the proximal nerve into muscle in the arch of the foot. *J Foot Ankle Surg* 2001 ; 40 : 404-410.
53. **Wu KK.** Morton's interdigital neuroma : a clinical review of its etiology, treatment, and results. *J Foot Ankle Surg* 1996 ; 35 : 112-119 ; discussion 187-118.
54. **Young G, Lindsey J.** Etiology of symptomatic recurrent interdigital neuromas. *J Am Podiatr Med Assoc* 1993 ; 83 : 255-258.