

TREATMENT OF ROTATOR CUFF ARTHROPATHY WITH A REVERSED DELTA SHOULDER PROSTHESIS

R. JACOBS, P. DEBEER, L. DE SMET

The treatment of rotator cuff arthropathy is still a matter of debate. Up to now a hemiarthroplasty was usually used. We report the results obtained with a reversed shoulder prosthesis (Delta® prosthesis, De Puy) in seven patients with severe rotator cuff arthropathy. The mean Constant score increased from 17.9/100 preoperatively to 56.7/100 postoperatively. The mean follow-up was 16 months. Loosening was not observed on follow-up xrays.

Keywords : shoulder ; arthroplasty ; reversed prosthesis ; rotator cuff.

Mots-clés : épaule ; arthroplastie ; prothèse inversée ; coiffe des rotateurs.

INTRODUCTION

Rotator cuff arthropathy has been known since the 19th century. Smith in 1853 and Adams in 1873 described severe omarthrititis with massive rotator cuff disruption (1, 2, 11, 19, 20). For several years this pathology was given different names e.g. Milwaukee shoulder (13). Neer introduced the term "rotator cuff arthropathy" to characterize a condition combining severe osteoarthritis of the shoulder and complete rotator cuff disruption (14). Until now the treatment has remained controversial. Several types of shoulder prostheses from hemiarthroplasty to bipolar, total shoulder and reversed prosthesis have been used (4, 7, 10, 11).

The reversed prosthesis was introduced in 1985 by Grammont (9). Similar prostheses had been used earlier by Gerard *et al.* (8). Neer also experimented with a reversed model. In a reversed pros-

thesis, the glenoid is replaced by a convex hemispheric component and a concave cap is placed on the humerus (15). The rotation of the joint is thus translated towards the glenoid instead of the humeral head. The deltoid muscle has a better abduction and elevation moment due to a longer lever arm (9). Baulot *et al.* and De Buttet *et al.* have reported good results with the Delta reversed prosthesis (3, 6). A recent study by Rittmeister and Kerschbaumer also confirmed the good results in patients with rheumatoid arthritis (17). We will present the preliminary results of a Delta reversed prosthesis evaluated pre- and postoperatively with a Constant score (5).

MATERIAL AND METHODS

Between November 1996 and September 1999, 14 Delta reversed prostheses (De Puy®) were implanted. The indications were : dislocation of a hemiarthroplasty (5 patients), rheumatoid arthritis (2 patients) and rotator cuff arthropathy (7 patients). We only studied the results of the last group. The mean age was 72 years and 2 months (range 54 to 80 years). All patients were females, all presenting with rotator cuff deficiency. Ultrasound confirmed the diagnosis in three cases. The rotator cuff disruption was confirmed with an arthro CT-scan in two. All patients had obvious omarthrititis (fig. 1). In one patient rotator cuff repair had been performed two years previously.

Correspondence and reprints : L. De Smet, Department of Orthopaedic Surgery, U.Z. Pellenberg, Weligerveld 1, B-3212 Lubbeek (Pellenberg), Belgium.

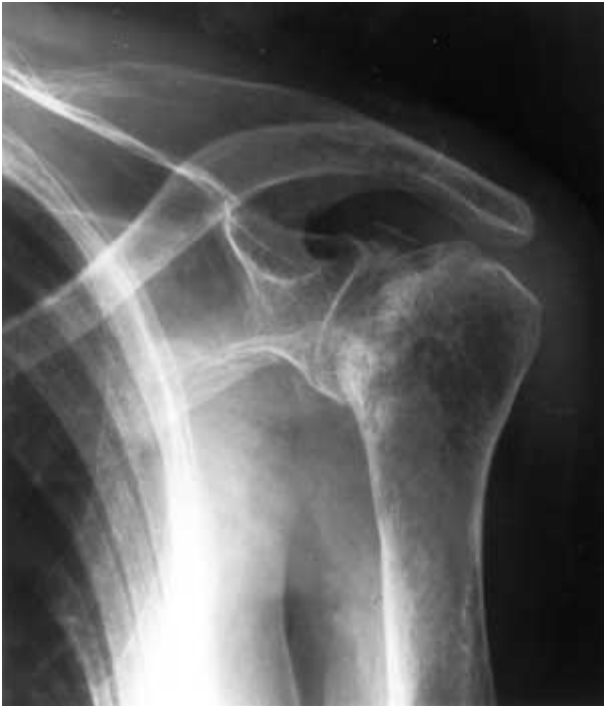

Fig. 1. — Severe omarthritis due to irreparable rotator cuff rupture.

In the preoperative period the mean Constant score was 17.9/100 (range 10/100 to 27/100), standard deviation (SD : 6.01). In all cases pain was the major complaint. It was permanent in five cases with a score of 0/15, and moderate in the other two (5/15).

Activities of daily living were disturbed in six cases with a score less than 4/20 and in one case 6/20. Sleep was disturbed in all patients.

Mobility had a mean score of 11/40, in three cases less than 10/40 and in four less than 20/40. Abduction and elevation were lower than 90° in all cases. Internal rotation was up to the gluteal level in four cases and to the lumbosacral level in three cases.

The force was measured isometrically in 90° of abduction and was less than 4/25 in all cases.

The operation was done in the beach-chair position. A classical deltoid split incision was used. The deltoid muscle was partly detached from the acromion. The center of the glenoid was determined and reamed. The glenoid component was fixed with four screws, one in the distal part of the neck of the scapula, the other three in the more proximal part. Cement was not used. After resection of the humeral head the humeral shaft was reamed. The humeral component was cemented (fig. 2).

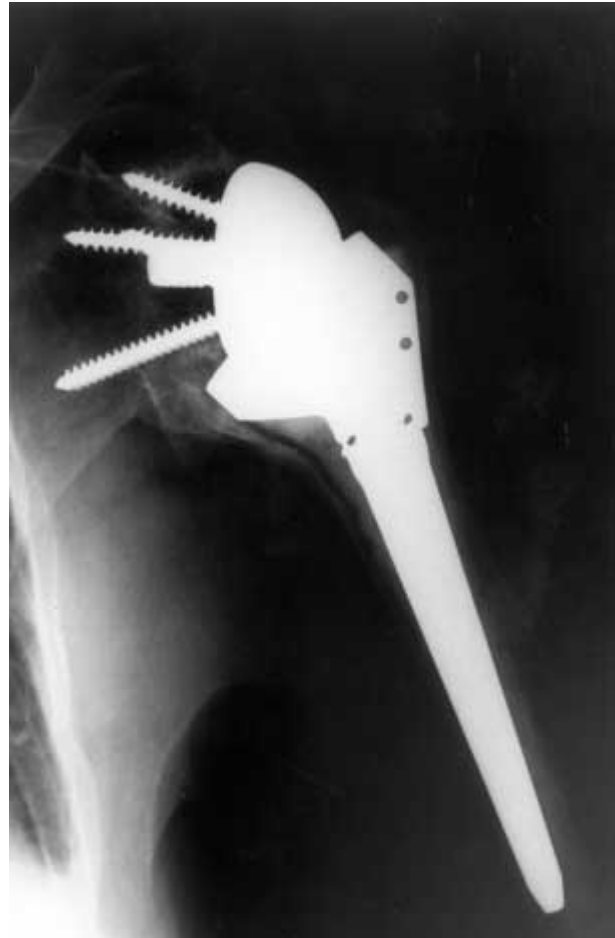


Fig. 2. — Reversed prosthesis in place

After reduction the deltoid was reattached with transosseous stitches to the acromion. All patients were immobilized in an abduction pillow for 2 to 3 weeks, following which active and passive mobilization was allowed, with the help of a physiotherapist.

During the operation the rotator cuff was found to be completely ruptured in five cases and partially in two cases with obvious osteoarthritis in four cases and intra-articular synovitis in two cases. In one patient a fracture of the cortex of the humerus occurred intraoperatively. No other complications were encountered during the immediate postoperative period.

The mean follow-up is 26 months (range : 16 to 37 months). The Constant score was determined. All measurements were done by the same observer not involved in the treatment (RJ).

RESULTS

The mean Constant-score postoperatively was 56.7/100 (range : 46/100 to 70/100), (standard deviation : 10.8338) (table I).

The mean pain score was 12/15. In one patient moderate pain was still present (5/15), minimal pain in two (10/15) and the other four had no pain (15/15).

Activities of daily living were rated 12.3/20. In all patients it was more than 8/20 ; in three of them it was more than 14/20. In five patients sleep was normal.

The mean mobility was 24.6/40. Abduction and elevation was more than 90° in all cases and in five cases more than 120°. Internal rotation was limited to the gluteal region in six patients.

The mean strength was 7.7/25, ranging from 3/25 to 11/25.

The paired Student's t-test demonstrated a significant difference between the pre- and the post-operative Constant score ($p < 0.001$). The xrays did not show any type of loosening.

DISCUSSION

This study presents the preliminary results with the reversed Delta shoulder prosthesis for rotator cuff arthropathy, all evaluated pre- and postoperatively with the Constant score with a mean follow-up over 2 years. The mean Constant score increased from 17.9 to 56.7/100 ; the difference is highly significant. There was a marked reduction in pain ; mobility and strength increased significantly. The results of this survey can be compared to previous ones. Baulot *et al.* found a mean increase from 14/100 to 69/100, in 16 patients with a mean follow-up of 27 months. In 1993 Grammont and Baulot presented the results of 13 patients with functional scoring after a mean follow-up of two years. The mean score increased from 7/20 to 15/20. The largest study is the one by De Buttet *et al.* : they evaluated 70 patients with a mean follow-up of 24.7 months. The mean Constant score increased from 19.4/100 to 59.9/100.

The treatment of rotator cuff arthroplasty is still a matter of debate. American surgeons usually used a hemiarthroplasty. In 1992 Pollock *et al.* described a series of 30 patients with omarthritis and massive rotator cuff disruption (16) : a hemiarthroplasty was performed in 19 and a total shoulder prosthesis in 11. The mean follow-up was 3.4 years. There was no significant difference regarding pain decrease, patients' satisfaction and functional recovery. Only active elevation was significantly better with the hemiarthroplasty (from 52° to 82°), which is also a result of the fact that the rotator cuff could be repaired in hemiarthroplasty. With severe glenoid deformation and irreparable rotator cuff disruption, hemiarthroplasty does not always give the expected pain relief. This was obvious in the studies of Lohr *et al.* (12) and Rockwood and Williams (18). In their hands a total shoulder prosthesis gave better results but a higher revision rate due to frequent loosening of the glenoid component. The reversed Delta prosthesis is a valuable alternative. The center of rotation of the shoulder is displaced medially. The lever arm of the deltoid muscle increases, which gives better abduction and elevation. Up to now no increased loosening risk has been reported (9).

The Delta reversed prosthesis progressively finds its place in the treatment of rotator cuff arthropathy. In older patients with a low activity level it is a valuable alternative compared to total shoulder replacement. The long-term outcome still has to be evaluated.

REFERENCES

1. Adams R. Illustrations of the effects of rheumatic gout or chronic rheumatic arthritis on all the articulations, with descriptive and explanation statements. London, Churchill and Sons, 1873, 2, pp. 91-175.
2. Adams R. Treatise of rheumatic or chronic rheumatic arthritis of all the joints. London, Churchill and Sons, 1873, 2, pp. 91-175.
3. Baulot E., Chabernaud D., Grammont P. M. Treatment of omarthritis associated with massive rotator cuff tear using the Grammont inverted prosthesis. *Acta Orthop. Belg.*, 1995, 61, 112-119.
4. Collins D.N., Harryman D. T. Arthroplasty for arthritis and rotator cuff deficiency. *Orthop. Clin. North Am.*, 1997, 28, 225-239.

5. Constant C. R., Murley A. H. G. A clinical method of functional assessment of the shoulder. *Clin. Orthop.*, 1987, 214, 160-164.
6. De Buttet M., Boucho Y., Capon D., Delfosse J. Grammont shoulder arthroplasty for osteoarthritis with massive rotator cuff tears. Reports of 71 cases. *J. Shoulder Elbow Surg.*, 1997, 6, 197.
7. Di Giovanni J., Marra G., Park J. Y., Bigliani L. U. Hemiarthroplasty for glenohumeral arthritis with massive rotator cuff tears. *Orthop. Clin. North Am.*, 1998, 29, 477-489.
8. Gerard Y., Leblanc J. P., Rousseau B. Une prothèse totale d'épaule. *Chirurgie*, 1973, 99, 655-663.
9. Grammont P. M., Baulot E. Delta shoulder prosthesis for rotator cuff rupture. *Orthopedics*, 1993, 16, 65-68.
10. Green A. Current concepts of shoulder arthroplasty. *AAOS Instruct. Course Lect.*, 1998, 47, 127-133.
11. Jensen K. L., Williams G. R., Russell I. J., Rockwood C. A. Rotator cuff tear arthropathy. *J. Bone Joint Surg.*, 1999, 81-A, 1313-1324.
12. Lohr J. R., Cofield R. H., Uthoff H. K. Glenoid component loosening in cuff tear arthropathy. *J. Bone Joint Surg.*, 1991, 73-B, 106.
13. McCarty D. J., Halverson P. B., Carriera C. F., Brewer B. J., Kozin F. Milwaukee shoulder. Association of microspheroids containing hydroxyapatite crystals, active collagens and neutral protease with rotator cuff defects. *J. Clin. Aspects Arthritis Rheumatol.*, 1981, 24, 464-473.
14. Neer C. S., Craig E. V., Fukuda H. Cuff tear arthropathy. *J. Bone Joint Surg.*, 1983, 65-A, 1232-1244.
15. Neer C. S., Watson K. C., Stanton F. J. Recent experience in total shoulder replacement. *J. Bone Joint Surg.*, 1982, 64-A, 319-337.
16. Pollock R. G., Deliz E. D., McIlveen S. L., Flatow E. L., Bigliani L. U. Prosthetic replacement in rotator cuff-deficient shoulders. *J. Shoulder Elbow Surg.*, 1992, 1, 173-186.
17. Rittmeister M., Kerschbaumer F. Grammont reverse total shoulder arthroplasty in patients with rheumatoid arthritis and nonreconstructible rotator cuff lesions. *J. Shoulder Elbow Surg.*, 2001, 10, 17-22.
18. Rockwood C. A., Williams G. R. Glenohumeral osteoarthritis and severe cuff disease : Management with hemiarthroplasty. *Orthop. Trans.*, 1992, 16, 743.
19. Smith R. Observations upon chronic rheumatic arthritis of the shoulder (part I). *Dublin, Quart. J. Med. Sci.*, 1853, 15, 1-16.
20. Smith R. Observations upon chronic rheumatic arthritis of the soulder (part II). *Dublin, Quart. J. Med. Sci.*, 1853, 15, 343-425.

SAMENVATTING

R. JACOBS, P. DEBEER, L. DE SMET. Behandeling van rotator cuff arthropathie met de "Reversed Delta Prothese".

Over de behandeling van rotator cuff arthropathie bestaat nog veel discussie. Tot op heden wordt er vooral een hemiarthroplastie geplaatst. Deze prothese geeft een goede functie en verbetering van de pijn. Doch bij ernstige glenoïd-aantasting en onherstelbare rotator cuff scheur, is er een betere pijnverlichting met een totale schouder prothese. Het nadeel van een klassieke totale schouder prothese is dat het glenoïd-component vaak los komt. In deze gevallen kan een Delta reversed prothese overwogen worden. Deze prothese geeft de patiënt een duidelijke verbetering van de mobiliteit (in tegenstelling tot andere totale prothesen) en vermindering van de pijnklachten. De kans dat het glenoïd-component los komt blijkt relatief klein. Dit werk geeft de resultaten van de 7 patiënten die een delta reversed prothese kregen omwille van rotator cuff arthropathie. De patiënten werden pre- en postoperatief geëvalueerd aan de hand van de Constant score. De gemiddelde Constant score steeg van 17.86/100 preoperatief naar 56.71/100 postoperatief. De follow-up bedroeg 26 maanden. Bij controle was op de radiografie bij één enkele patiënt een teken van loslating te zien.

De Delta reversed prothese is een aanvaardbaar alternatief voor de behandeling van rotator cuff arthropathie. De resultaten op langere termijn zijn nog af te wachten.

RÉSUMÉ

R. JACOBS, P. DEBEER, L. DE SMET. Traitement de l'arthropathie d'épaule sur rupture de coiffe par la prothèse inversée Delta.

Le traitement de l'arthropathie gléno-humérale sur rupture de coiffe reste un sujet controversé. Dans le passé, on recourait généralement à une hémi-arthroplastie. Les auteurs présentent les résultats qu'ils ont obtenus avec une prothèse d'épaule inversée, la prothèse Delta, de Grammont, chez 7 patients qui présentaient une arthropathie grave sur rupture de coiffe. Le score moyen de Constant est passé de 17,9 sur 100 à 56,7 sur 100 en post-opératoire, avec un follow-up moyen de 16 mois. Aucun descellement radiologique n'a été observé à ce jour.