

REVISION OF SHOULDER REPLACEMENT WITH A REVERSED SHOULDER PROSTHESIS (DELTA III®) : REPORT OF FIVE CASES

L. DE WILDE, M. MOMBERT, P. VAN PETEGEM, R. VERDONK

The authors report on their experience in revision total shoulder arthroplasty using the Delta III® shoulder prosthesis, a reversed constrained prosthesis which is known to give good functional results in the rotator cuff-deficient shoulder. It was implanted in patients with a failed total or hemishoulder prosthesis. The Constant-Murley score was used to assess the functional outcome. The preliminary results achieved in four patients (one bilaterally) are discussed and compared with the results of other treatments. After two years follow-up, the Constant-Murley score has improved from 14/100 preoperatively to 62/100 postoperatively. Although these initially good functional results may be temporary and loosening may occur over the longer term, the authors recommend the Delta III® shoulder prosthesis as an alternative solution for revision shoulder arthroplasty.

Keywords : shoulder ; arthroplasty ; revision.
Mots-clés : épaule ; arthroplastie ; reprise.

INTRODUCTION

Shoulder arthroplasty should improve pain and function. A good functional result requires anatomical restoration of the glenohumeral articulation. To achieve this, recent advances in total shoulder arthroplasty offer the possibility to adjust the medial and posterior offset as well as the varus angulation, allowing a near perfect reconstruction of the proximal humerus. For optimal function of a prosthetic shoulder articulation, an intact and functional rotator cuff is essential.

Despite these promising technical advances some patients have poor subjective and objective functional results. In these cases medical imaging usually shows a severely disturbed glenohumeral entity that cannot be restored to a normal anatomical condition with an anatomical, 'classical Neer-type' prosthesis.

We have used the reversed Delta III® shoulder prosthesis for revision surgery of failed shoulder arthroplasty in such cases where the glenohumeral joint could not be reconstructed. The biomechanical rationale of the prosthesis is based on the reversed geometry of the normal (glenohumeral relationship) glenoid and humeral components, so that the centre of rotation is moved medially and distally to increase the length of the deltoid muscle lever arm. This allows the three parts of the deltoid muscle to compensate for the cuff deficiency by drawing the two articulating surfaces of the shoulder together, stabilizing the joint and allowing as near normal a function as possible (5, 6).

MATERIALS AND METHODS

Material

Revision shoulder arthroplasty with the Delta III® shoulder prosthesis (DePuy International Ltd, Leeds, U.K.) was performed in four patients (one bilaterally).

Department of Orthopedic Surgery, Ghent University Hospital, Ghent, Belgium.

Correspondence and reprints : Lieven De Wilde, University Hospital, De Pintelaan 185, B-9000 Gent, Belgium.

Three male and one female patient (four right and one left shoulder) with ages ranging from 34 to 73 years underwent surgery at Ghent University Hospital.

The original pathology was anteroinferior instability in one patient, a four-part fracture of the proximal humerus in the youngest patient, and rotator cuff tear arthropathy in the female patient and in the bilaterally treated patient.

The interval to revision arthroplasty ranged from 9 to 32 months. The duration of follow-up ranged from 23 to 39 months.

Indications

The indication for using the Delta III® shoulder prosthesis in revision surgery following failed hemi- or total shoulder arthroplasty was made when normal glenohumeral anatomy could not be restored otherwise. The first patient presented superior subluxation with complete disappearance of the greater tuberosity after shoulder hemiarthroplasty for a four-part fracture of the proximal humerus. The supra- and infraspinatus tendons were torn and showed fatty degeneration (Goutallier grade 2) (4). Two patients had an unstable (anteroinferiorly) bipolar hemishoulder arthroplasty. On preoperative CT-scan a torn supra- and infraspinatus and subscapularis tendon with severe fatty degeneration of the muscle belly was noticed (table I). One of them had already undergone 5 previous attempts at stabilization. The bilaterally treated patient presented a rotator cuff-deficient syndrome treated with a rotator cuff-deficient humeral head prosthesis designed by Fenlin *et al.* (3). Both shoulders presented complete absence of the rotator cuff.

All cases presented severe superior subluxation of the humeral prosthesis resulting in superoanterior glenoid erosion and/or osseous wear of the anterior acromion.

During surgery the supraspinatus, infraspinatus and subscapularis tendons were considered as irreparable in all cases, as well as the teres minor muscle in two cases.

Surgical exposure

The anterior clavicular osteotomy to detach the pars clavicularis of the deltoid muscle as described by Redfern *et al.* (13) was used as it provides excellent exposure of the humeral head. In addition to the original surgical technique we reflected the pars clavicularis of the deltoid muscle in the acromioclavicular joint. In order to prevent postoperative acromioclavicular dysfunction the cartilage and meniscal structures were resected.

Closure of the osteotomy with two or three non-absorbable X-sutures allowed immediate active rehabilitation.

Postoperatively the patients were encouraged to start activities of daily living as soon as possible. An adduction sling was worn for a short time to avoid fatigue pain in the upper limb.

The implant

The biomechanical rationale of the Delta III® medial offset total shoulder prosthesis is based on the distalization and medialization of the centre of rotation of the shoulder prosthesis. This lengthens the lever arm of the deltoid muscle, which provides additional power to actively lift the shoulder thus creating a stable and active functional joint (fig. 1, 2). The diaphyseal component of the Delta III® shoulder prosthesis with a maximal length of 18 cm is cemented to provide a secure fixation.

The original humeral length could not always be determined and was approximately restored by implanting the prosthesis under sufficient tension using humeral spacers or a lateralized humeral polyethylene cup.

The glenoid implant is hydroxyapatite-coated to stimulate bone ingrowth. It was used without cement and secured with 4 additional screws.

The smaller glenoid sphere component (36 mm) of the Delta III® shoulder prosthesis was implanted four times, the larger sphere (42 mm) was used in only one case. Lengthening of the deltoid lever arm is mandatory to stabilize the prosthesis and to improve active function and intraoperative stability (14).

Measurements

The Constant-Murley score (2) (table III) was used to evaluate the functional outcome in our patients in an objective manner by the same observer. It rates pain,

Table I. — Fatty degeneration of rotator cuff muscles according to Goutallier *et al.* (4)

fatty degeneration of rotator cuff muscles				
case	supra-spinatus	infra-spinatus	sub-scapularis	teres minor
1	2	2	0	0
2	4	4	4	2
3	1	1	2	0
4	4	4	4	2
5	4	4	4	0

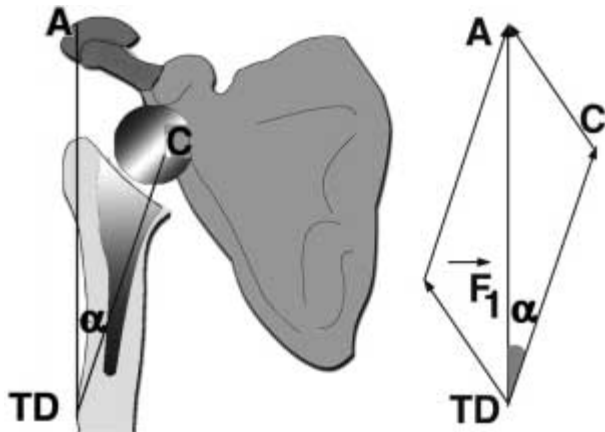


Fig. 1. — Reversed shoulder prosthesis

C = center of rotation ; A = acromion ; TD = deltoid tuberosity ; F = deltoid force.

Because of lowering and medialization of the center of rotation, α is larger than the corresponding angle β (fig. 2) in an anatomic prosthesis, resulting in a larger deltoid abduction force.

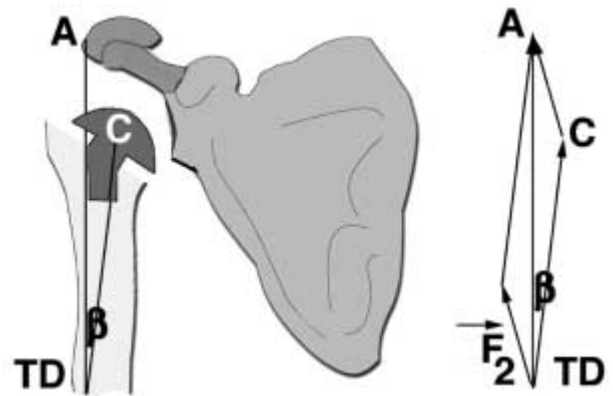


Fig. 2. — Anatomical shoulder prosthesis

Overall, the patients were satisfied and able to perform their daily activities. Three patients, one of whom is a warehouseman, have returned to their previous occupations.

The active range of shoulder motion was fair : elevation and abduction were between 80° and 180° (preoperatively : 30°-60°), internal rotation was between 40° and 80° (preoperatively : 10°-60°) and external rotation was restricted between 0° and 35° (preoperatively : 30°-80°).

A definite improvement in pain was noticed in all patients. The pain ranged from 3 to 15/15. The bilaterally treated patient and the female patient were painfree. One patient made a remarkable recovery of muscle strength. In this case the fatty degeneration of the rotator cuff muscles was only 2 on CT so that an attempt to reattach the external rotator muscles could be made (4). Recovery of the external rotation strength was indeed most difficult to obtain.

daily activities, working conditions, patient comfort during sleep, and the ability to use the arm at a certain level. The range of shoulder motion and the muscle strength are evaluated as well. The Constant-Murley score is adjusted according to the age and sex of the patient.

RESULTS

The results are presented in table II. When adjusted according to sex and age, the Constant-Murley score has improved from 14/100 before revision to 62/100 after revision. A score of 100/100 means that the patient has values similar to the normal age and sex values.

Table II. — Constant-Murley scores of the cases

					Constant score before revision					Constant score after revision					follow-up
					pain	act.	mob.	force	adj.score	pain	act.	mob.	force	adj.score	
case	age	sex	side	dom.	/15	/20	/40	/25	%	/15	/20	/40	/25	%	
1	34	M	R	+	0	4	4	1	9	10	14	34	2	61	39
2	73	F	R	+	0	4	6	1	16	15	16	22	3	81	25
3	52	M	R	+	0	4	12	0	18	3	20	26	25	82	37
4	58	M	R	+	5	0	6	4	17	15	8	10	6	43	23
5	58	M	L	-	5	0	2	4	12	15	8	10	6	43	27

Cases 4 and 5 refer to one patient who underwent bilateral treatment.

Table III. — Constant-Murley Score

Constant-Murley Score		
Pain	/15	none or climatic = 15, mild = 10, moderate = 5, severe = 0
Activity	/20	daily or professional activity limitation : no = 4, severe = 0 sports or recreational activity limitation : no = 4, severe = 0 effect on sleep comfort : no = 2, severe discomfort = 0 level at which arm can be used : belt = 2, xiphoid = 4, neck = 6, top of head = 8, above head = 10
Active Mobility	/40	flexion : 0-30° = 0, 31 - 60° = 2, 61-90° = 4, 91-120° = 6, 121-150° = 8, >150° = 10 abduction : see flexion external rotation : hand behind head, elbow forward = 2, hand behind head, elbow backward = 4, hand on head, elbow forward = 6, hand on head, elbow backward = 8, full elevation from top of head = 10 internal rotation : dorsum of hand to : buttocks = 2, sacrum = 4, L3 = 6, Th12 = 8, Th7-8 = 10
Strength	/25	average in Kg X 2

Peroperative complications

After the wound was closed and the patient awoke, one dislocation of the Delta III® shoulder prosthesis occurred. It was recognized immediately and could be reduced without anesthesia. This patient recovered uneventfully. The postoperative treatment consisted of an abduction pillow for six weeks.

Postoperative complications

In one patient a postoperative hematoma occurred 6 weeks after surgery when the patient underwent an ulnar nerve release under general anesthesia. Manipulation of the shoulder was probably responsible for this complication. Recovery was normal.

One shoulder of the bilaterally treated patient showed low-grade infection, which was treated with antibiotics until normalization of the inflammatory parameters. The clavicular osteotomy site healed primarily, with no acromioclavicular joint dysfunction.

Radiological results

All patients underwent a radiographic examination at follow-up. None showed signs of implant

loosening. The female patient showed fading of the lateral humeral cortex (over a distance of 7 cm), slight metallic wear of the inferior screw and inferior scapular notching.

The patient with the hematoma presented severe periprosthetic ossifications around the osteotomy cerclage (Sneppen grade 3) (7), discrete humeral radiolucent lines, and a notch inferior to the glenoid.

The bilaterally treated patient had severe periprosthetic ossifications scattered on both sides (Sneppen grade 3).

The youngest patient with near-normal mobility showed some notch formation at the inferior pole of the glenoid.

DISCUSSION

Very little has been written about revision shoulder arthroplasty. It has been recognized as technically difficult. Because of extensive scarring, muscle and tendon weakness and bone loss, anatomical reconstruction of the glenohumeral joint is usually impossible (9).

Petersen *et al.* (11) presented a meta-analysis of six studies published between 1982 and 1997 on revision of shoulder arthroplasty with an anatomi-

cal classical Neer-type prosthesis. It included 158 shoulders followed for periods ranging from 34 to 60 months and evaluated using either the HSS (16) or the Neer (10) scoring system. Nineteen percent of the patients had an excellent result, 41% a satisfactory, 28% an unsatisfactory and 12% a poor result. If the glenohumeral anatomy could be restored, results were satisfactory. An unsatisfactory functional result was frequently related to deltoid or rotator cuff insufficiency, with incomplete anatomical reconstruction of the glenohumeral joint. When anatomical reconstruction of the glenohumeral joint was impossible the primary goal of revision arthroplasty was relief of severe pain.

An alternative for patients with massive irreparable rotator cuff tears is the bipolar shoulder prosthesis (Biomet). Petroff *et al* (12) reported on 24 patients with disabling shoulder pain who underwent this treatment. After an average follow-up of 14.5 months the Constant-Murley score improved from 17.62/100 to 46.97/100. Average active flexion improved from 62.4° before to 84.8° after surgery. Active external rotation improved from a mean 3° to 28.8°. Satisfactory pain relief and modest gain in motion resulted in significant functional improvement in this "low -functional demand" population. Lee *et al* (8) reported on 7 patients who underwent a revision shoulder arthroplasty with a bipolar shoulder prosthesis (Zimmer Warsaw, IN). This group had fair pain relief, with an average postoperative active forward flexion, abduction, and external rotation of 39°, 44°, and 12°, respectively.

Shoulder arthrodesis (15) is another alternative treatment for failed shoulder arthroplasty, but is technically difficult due to the important bone loss. This treatment significantly stresses the periscapular musculature. The postoperative loss of shoulder rotation makes it difficult for patients to comb their hair, wash their back and reach for their back pocket. Complete recovery from the operation takes at least 6 to 12 months.

A last treatment option is resection arthroplasty. It can no longer be used as a primary procedure but needs to be considered as a salvage procedure because active abduction will never be more than

90°, and only one-half to two-thirds of patients will experience satisfactory pain relief. Current indications are essentially limited to salvage after an infected shoulder implant or failed total shoulder arthroplasty with extensive bone loss (1).

Because our preliminary results of total shoulder arthroplasty with the Delta III® prosthesis in rotator cuff-deficient omarthroses are very promising we considered this implant to be useful in revision arthroplasty when anatomical reconstruction was not feasible.

Our study includes a small number of patients with a mean follow-up time comparable to that of other studies. They all had rotator cuff-deficient shoulders beyond anatomical repair. The Delta III® reversed shoulder prosthesis (5, 6) was implanted because it bypasses the problem of anatomical destruction of the glenohumeral joint. However, the deltoid muscle must be functional. Our preliminary results of revision arthroplasty with the Delta III® shoulder prosthesis show both pain relief and functional improvement.

In this series the patients with the worst functional outcome were those who experienced perioperative complications.

Whereas normal function of the deltoid muscle is important to optimize functional abduction after revision shoulder arthroplasty, the teres minor and infraspinatus muscles are essential to regain functional external rotation, which was often weak in our patients.

The recovery time after revision surgery with the Delta III® shoulder prosthesis is short. A good functional result is achieved within three to six months postoperatively even without a specific rehabilitation program. We noted that shoulder function continued to improve until two years after revision. Functional rehabilitation should be encouraged during this period.

However, according to the orthopedic literature all constrained prostheses are doomed to loosen. Glenoid loosening has not yet occurred in our patients and function has improved. Based on its good short-term results, we consider the Delta III® shoulder prosthesis a valuable alternative in shoulder prosthesis revision despite the present uncertainty about its long term results.

REFERENCES

1. Cofield R. H. Shoulder arthrodesis and resection arthroplasty. Instr. Course Lect., A.A.O.S., 1985, 34, 268-277.
2. Constant C. R., Murley A. H. G. A clinical method of functional assessment of the shoulder. Clin. Orthop., 1987, 217, 160-164.
3. Fenlin J. M. Jr., Ramsey M. L., Allardyce T. J., Frieman B. G. Modular total shoulder replacement, design rationale, indications and results. Clin. Orthop., 1994, 307, 37-46.
4. Goutallier D., Bernageau J., Patte D. L'évaluation par le scanner de la trophicité des muscles des coiffes des rotateurs ayant une rupture tendineuse. Rev. Chir. Orthop., 1989, 75, 126.
5. Grammont P. M., Baulot E. Delta shoulder prosthesis for rotator cuff ruptures. Orthopedics, 1993, 16, 65-68.
6. Grammont P. M., Baulot E. La prothèse d'épaule dans les ruptures irréparables de la coiffe des rotateurs. In : Pathologie de la coiffe des rotateurs de l'épaule. J. Pelissier, L. Simon, J. Rodineau, ed. Masson Paris, 1993, pp. 336-341.
7. Kjaersgaard-Andersen P., Frich L. K., Sojbjerg J. O., Sneppen O. Heterotopic bone formation following total shoulder arthroplasty. J. Arthroplasty, 1989, 4, 99-104.
8. Lee D. H., Niemann K. M. W. Bipolar shoulder arthroplasty. Clin. Orthop., 1994, 304, 97-107.
9. Neer C. S. II, Kirby R. M. Revision of humeral head and total shoulder arthroplasties. Clin. Orthop., 1982, 170, 189-195.
10. Neer C. S. II, Watson K. C., Stanton F.J. Recent experience in total shoulder replacement. J. Bone Joint Surg., 1982, 64, 319-337.
11. Petersen S. A., Hawkins R. J. Revision of failed total shoulder arthroplasty. Orthop. Clin. North Am., 1998, 29, 519-533.
12. Petroff E., Mestdagh H., Maynou C., Delobelle J.-M. L'arthroplastie à cupule mobile dans l'omarthrose avec rupture de coiffe irréparable : résultats préliminaires et étude radiocinématographique. Rev. Chir. Orthop., 1999, 85, 245-256.
13. Redfern T. R., Wallace W. A., Beddow F. H. Clavicular osteotomy in shoulder arthroplasty. Int. Orthop., 1989, 13, 61-63.
14. Renaud P. Prothèse totale inversée de l'épaule et insuffisance de la coiffe des rotateurs. Thèse, Université d'Angers, France, 1999.
15. Richards R. R., Beaton D., Hudson A. R. Shoulder arthrodesis with plate fixation : Functional outcome analysis. J. Shoulder Elbow Surg., 1993, 2, 225-239.
16. Warren R. F., Ranawat C. S., Inglis A. E. Total shoulder replacement. Indications and results of the Neer non-constrained prosthesis. In : Inglis A. E., ed. AAOS Symposium on Total Joint Replacement of the Upper Extremity. St. Louis, CV Mosby, 1982, p. 56.

SAMENVATTING

L. DE WILDE, M. MOMBERT, P. VAN PETEGEM, R. VERDONK. Revisiechirurgie na totale schouderartroplastiek met een omgekeerde schouderprothese (Delta III®) : verslag van 5 gevallen.

Wij bespreken onze ervaring met de Delta III®-schouderprothese voor de revisie van een gefaalde totale of hemischouderartroplastiek. Deze omgekeerde prothese geeft goede functionele resultaten bij patiënten met een deficiënte rotatorenmanchet. Het functioneel resultaat werd geëvalueerd met de Constant-Murley-score. De resultaten op korte termijn (twee jaar) werden geëvalueerd bij vier patiënten, van wie één bilateraal werd behandeld. De resultaten werden ook vergeleken met deze van andere actueel gangbare behandelingen. De preoperatieve Constant-Murley-score van 14/100 steeg naar 62/100 postoperatief na een follow-up van twee jaar. Alhoewel de functionele verbetering misschien slechts tijdelijk is, onder reserve van een loslating van de Delta III®-schouderprothese op langere termijn, beschouwen wij de revisie van een schouderartroplastiek met deze prothese als een aanvaardbare alternatieve methode.

RÉSUMÉ

L. DE WILDE, M. MOMBERT, P. VAN PETEGEM, R. VERDONK La prothèse Delta III® en chirurgie de reprise après prothèse totale de l'épaule : présentation de 5 cas.

Les auteurs rapportent leur expérience de la reprise d'arthroplastie totale de l'épaule avec la prothèse Delta III®, conçue pour donner des résultats satisfaisants dans l'arthroplastie totale de l'épaule, même en présence d'une coiffe des rotateurs déficiente. Ils décrivent son utilisation dans la chirurgie de reprise d'arthroplastie de l'épaule. Les résultats fonctionnels à court terme (deux ans) ont été évalués par le score de Constant-Murley, chez quatre malades dont un a subi un traitement bilatéral. Ce résultat est comparé aux traitements actuels de la chirurgie de reprise de l'épaule. Après deux ans, le score de Constant-Murley est passé de 14/100 en préopératoire à 62/100. Cette amélioration peut être temporaire, car la prothèse pourrait donner des descellements tardifs. Néanmoins la prothèse d'épaule Delta III® peut être une solution valable pour la chirurgie de révision de l'épaule.