

RELIABILITY OF RADIOLOGICAL PARAMETERS MEASURED ON ANTEROPOSTERIOR PELVIS RADIOGRAPHS OF PATIENTS WITH DEVELOPMENTAL DYSPLASIA OF THE HIP

L. TAN¹, S. AKTAS¹, C. COPUROGLU¹, M. OZCAN¹, M. TURE²

In order to evaluate the reliability of radiological parameters, we retrospectively reviewed the anteroposterior pelvic xrays of 30 hips in 15 patients with developmental dysplasia of the hip. The following parameters were studied : acetabular index, center-edge angle, c/b ratio, Sharp's angle and teardrop figure. Each of the two authors measured the parameters twice on two separate days. Statistical assessment of the interobserver and intraobserver reliability was performed. The measurements of acetabular index and c/b ratio were reliable according to both intra- and interobserver reliability analysis, whereas center-edge angle, teardrop figure and Sharp's angle evaluations were reliable in the intraobserver comparisons but not in the interobserver comparisons. In conclusion, both acetabular index and c/b ratio may be used safely in the evaluation of developmental dysplasia of the hip.

Keywords : dysplasia ; hip ; radiography ; reliability.
Mots-clés : dysplasie ; hanche ; radiographie ; fiabilité.

INTRODUCTION

The diagnosis and treatment of developmental dysplasia of the hip (DDH) has been a challenging problem to orthopedic surgeons since Hippocrates. Several diagnostic tools such as anteroposterior (AP)-pelvis radiography, arthrography, ultrasonography, computed tomography (CT) and magnetic resonance imaging (MRI) are used in the evaluation of DDH besides clinical examination. AP-pelvis radiography is commonly used in the diagnosis and follow-up of DDH. The following para-

meters are evaluated on an AP-pelvis xray : acetabular index, center-edge angle, c/b ratio, Sharp's angle and teardrop figure.

Even though most of the orthopedic surgeons are familiar with the measurement techniques of these parameters, the results may differ from one examiner to another. There are several studies about the reliability of some of these measurement techniques in either normal individuals or patients with DDH. In this study, we aimed to evaluate the reliability of the measurement of these parameters regardless of the hip being normal or affected by DDH.

MATERIAL AND METHODS

We selected 30 AP-pelvis radiographs of 15 patients followed at the orthopedic surgery department of the Trakya University Hospital between 1993 and 1999. All selected xrays were appropriate in terms of the position of the pelvis and exposure quality. The mean age was 26 months, ranging from 3 to 36 months. Nine patients had unilateral and six bilateral DDH. All information written on the xrays was erased, and a number was assigned to each film. In order to standardize the measurements, both examiners used the same ruler, protractor and pencil.

¹ Trakya University Medical School, Department of Orthopedic Surgery and ² Department of Biostatistics, Edirne Turkey.

Correspondence and reprints : Seref Aktas, Trakya University Faculty of Medicine , Department of Orthopedic Surgery, Edirne 22030, Turkey. E-mail: saktas@hotmail.com.

Table I. — Reliability analysis of interobserver and intraobserver measurements

	Acetabular index		Center-edge angle		c/b ratio		Teardrop figure		Sharp's angle	
	ICC	p	ICC	p	ICC	p	ICC	p	ICC	p
Intraobserver Measurements-I	0.94	<0.05	0.96	<0.05	0.85	<0.05	1.00	<0.05	0.85	<0.05
Intraobserver Measurements-II	0.91	<0.05	0.85	<0.05	0.86	<0.05	0.42	<0.05	0.42	<0.05
Interobserver measurements	0.71	<0.05	0.51	0.10	0.78	<0.05	0.21	0.23	0.17	0.27

ICC : Intraclass Correlation Coefficient.

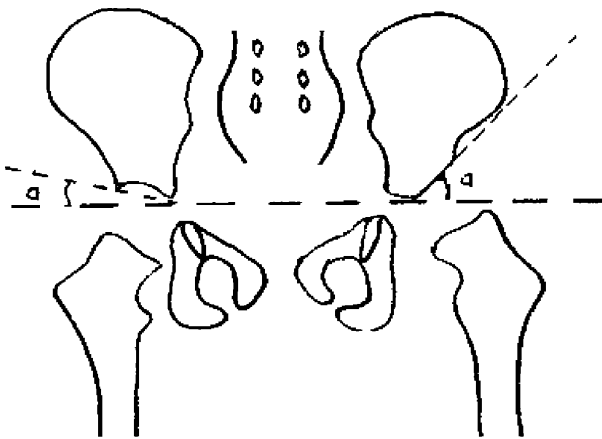


Fig. 1. — Acetabular index

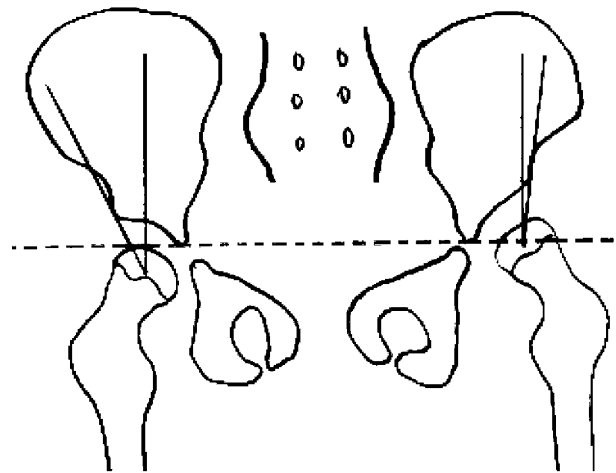


Fig. 2. — Center-edge angle

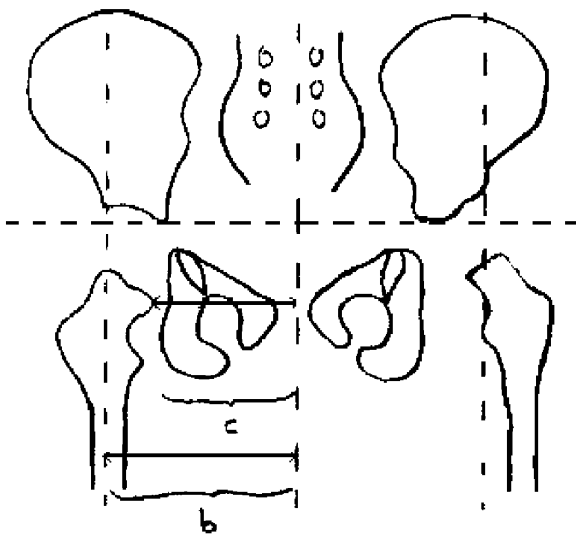


Fig. 3. — c/b ratio

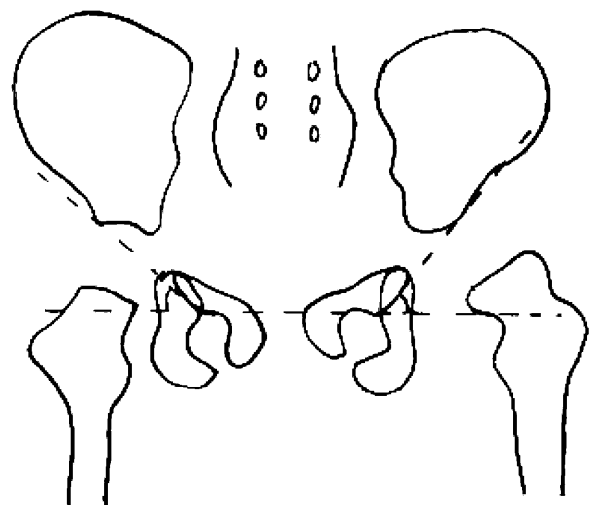


Fig. 4. — Sharp's angle

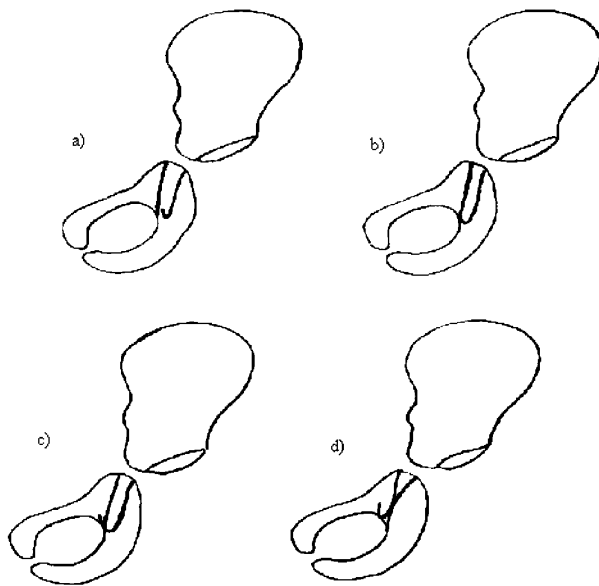


Fig. 5. — Evaluation of teardrop figure

The parameters evaluated were as follows : acetabular index, center-edge angle, c/b ratio, Sharp's angle and teardrop figure. Each of the two examiners (LT and SA) measured the parameters twice on two separate days.

The acetabular index was the angle formed by the acetabular roof line and Hilgenreiner's line.

For the center-edge angle, Hilgenreiner's line joining the triradiate cartilages of the acetabulum was drawn. Following determination of the center of the femoral head two lines were drawn from it : one perpendicular to Hilgenreiner's line and the other towards the lateral edge of the acetabulum. These two lines formed the center-edge angle.

For the c/b ratio, a central vertical line was drawn from the mid point of the sacrum through the pubic symphysis. Perkins' line perpendicular to Hilgenreiner's line starting from the lateral edge of the acetabulum was drawn. The distance from the medial corner of the proximal femoral metaphysis to the central line (c) was divided by the distance from Perkins' line to the central line (b) to calculate the c/b ratio. The latter was not calculated in the dislocated hips.

For Sharp's angle, a line from the inferior rim of the teardrop figure to the most lateral edge of the acetabulum was drawn. This line and Hilgenreiner's line formed Sharp's angle.

The teardrop figure was evaluated as : a) open, b) closed, c) crossed, or d) reverse (7).

Student's t test was used for the statistical analysis in the assessment of the distribution of the study population. Reliability analysis (ICC) was applied to the inter-observer and intraobserver differences.

RESULTS

Intraobserver and interobserver measurement differences were evaluated based on the results obtained from the measurements of each observer. The relationship between the five measured parameters was evaluated individually (table I). In the measurements made by both examiners, there was no significant difference in the evaluation of acetabular index, center-edge angle, c/b ratio, Sharp's angle and teardrop figure according to intraobserver reliability analysis. However, analysis of interobserver reliability revealed that while the evaluation of measurements of acetabular index and c/b ratio showed no significant difference, the evaluation of center-edge angle, teardrop figure and Sharp's angle showed significant differences.

DISCUSSION

Treatment of DDH varies depending on the age of the patient and the degree of dysplasia. There are several diagnostic methods used commensurate with the age of the patients. Pelvis radiography is one of the widely used techniques in the diagnosis and follow-up of patients with DDH. The advantages of AP-pelvis radiography are its low cost, availability and application without anesthesia. There are many parameters that are evaluated on AP-pelvis radiography. Rosen *et al.* (11) mentioned that Tönnis' radiological grading indicated the results of treatment and the prognosis from the initial radiographs. Garvey *et al.* (6) made a follow-up investigation on 13,662 live births. They suggested evaluating AP-pelvis radiography in addition to physical examination after the fourth month.

The first provision in the evaluation of pelvis xrays in children is that the radiograph must have a good exposure quality and the position of the pelvis must not be in rotation. Boniforti (3) emphasized that the xrays must not be taken with the pelvis in rotation. Tönnis (17) determined standards in radiological measurements in his study. When we

reviewed the xrays of the patients with DDH for this study, it appeared that in fact, most of the AP-pelvis xrays were not appropriate for evaluation of all of the five parameters. That was the reason for the small number of radiographs examined in the study. Although we agreed that was a weak point of our study, for the sake of minimising the measurement errors in the evaluation of these five parameters, we did not include any of the xrays with improper positioning of the patients into the study group. For that reason, our findings do not apply to unselected xrays such as most clinicians are likely to obtain when dealing with an individual patient.

The acetabular index is the parameter most often measured. There are many studies about the reliability of the acetabular index in the literature. Broughton *et al.* (4) concluded from a study of 474 pelvis radiographs that the acetabular index was the most valuable variable. Kay *et al.* (8) investigated the value of acetabular index in 24 pelvis xrays. The acetabular index was measured three times by five orthopedic surgeons. They reported that the acetabular index was valid in a single reading. They concluded that the measurement failures resulted from the improper xrays. Kay *et al.* believed that the significant difference found between observers was caused by the orthopedic surgeons, working in different clinics. In our study, there was no significant difference in the measurement of acetabular index in interobserver comparisons between observers working in the same clinic. Spatz *et al.* (16) investigated the interobserver and intraobserver differences in the measurements of xrays of 25 children. Five orthopedic surgeons measured the acetabular index three times on the same film. As a result, they did not find significant inter and intraobserver variations, as in our study. Spatz *et al.* also mentioned that all orthopedic surgeons who were included in their study worked at the same clinic. There was no significant difference in acetabular index measurements in our results either and this could be explained in the same manner. Skaggs *et al.* (15) recognized that the lowest failure ratio was seen in patients with closed reduction, because in open reduction the continuity of the acetabulum was damaged. The acetabular index was the most reliable and the best method in the

follow-up of patients following closed reduction. Ogata *et al.* (10) suggested measuring acetabular index and center-edge angle from the end point of sclerosis in the roof of the acetabulum instead of measuring with the original method of Wiberg. Acetabular coverage was measured more reliably by this method.

The center-edge angle is an angle that is not measured in dislocated hips, but is mostly used in subluxed joints. The major problem in the measurement of this angle is to find the center of the femoral head. It is very difficult to measure this angle in patients whose femoral epiphyseal ossification center cannot be seen. The femoral head has a spherical shape. To find the center point, the femoral head must be considered as a circle. In our measurements we also considered the femoral head as a circle and made our measurements accordingly. Drummond *et al.* (5) suggested measuring the center-edge angle after performing arthrography. The femoral head could thus be imaged perfectly. However, it is invasive and requires anesthesia, which makes this technique impractical. Scoles *et al.* (13) mentioned that the center-edge angle increased with age in their study. It was also recommended that the measurement of the center-edge angle be performed after the age of four (4). In our study, we were able to investigate the evaluation differences only. Because the number of measurable center-edge values was so small, we were not able to correlate age and center-edge angle. We found that the center edge angle was reliable in intraobserver comparisons but unreliable in the interobserver comparisons.

The *c/b* ratio shows lateralization and medialization of the femoral head indirectly during growth. Li *et al.* (9) suggested that the *c/b* ratio could be applied easily and used in the follow-up. Broughton *et al.* (4) also mentioned that the *c/b* ratio was reliable in all age groups. We also had similar results to those reported in literature. We recommend using the *c/b* ratio in the evaluation of DDH, since it is easy to measure. Once again, to obtain reliable measurements, the xrays must not be taken with the pelvis in rotation and the line passing through the center of the sacrum must be drawn meticulously.

The teardrop figure is another parameter used to assess the acetabular development. Albinana *et al.* (2) reported that the teardrop figure was usually "crossed type" in dysplastic hips. Gusic *et al.* (7) reported that 48.7% of teardrop figures were "crossed type" in 300 hips of 150 normal children. The problem in evaluation of the teardrop figure was to perceive the shape wrongly because of xrays with inappropriate exposure quality. Inappropriate xrays may also result in wrong evaluation of the teardrop figure (12). In our study, we found that classifying the teardrop figure was reliable in intraobserver comparisons, but unreliable in inter-observer comparisons.

Sharp's angle is used mainly in patients with closed triradiate cartilages. It can be used in the follow up xrays from the beginning. Sharp (14) suggested that the normal values were between 32° and 47°. In our study, we found Sharp's angle reliable in intraobserver comparisons, but not in inter-observer comparisons. We gather that the difference in results could be explained by the difficulty in determining the most inferior rim of the teardrop figure.

Our literature review revealed that the radiological parameters used in the diagnosis and follow-up of children with DDH were measured and evaluated only in children with DDH (3, 9, 13) or in children with normal hips (1, 16). Since these parameters were used both for diagnosis and follow-up, we investigated the reliability of parameters without grouping the hips as normal or with developmental dysplasia of the hip. Therefore, we assumed that the reliability of these parameters must be evaluated in mixed cases.

However, there is no single acceptable parameter showing prognosis in follow-up. Akpınar *et al.* (1) therefore suggested using more than one parameter in patients whose epiphyseal nuclei were not seen.

Since acetabular index and c/b ratio measurements are reliable in both intraobserver and inter-observer comparisons, we recommend measuring both in the evaluation of DDH.

REFERENCES

1. Akpınar F., Tosun N., Bozkurt M., Üner A. *et al.* A multi-parameter study about the pelvis radiographies of normal children. *Acta Orthop. Traumatol. Turc.*, 1996, 30, 259-268.
2. Albinana J., Morcuende J. A., Weinstein S. L. The teardrop in congenital dislocation of the hip diagnosed late. A quantitative study. *J. Bone Joint Surg.*, 1996, 78-A, 1048-1053.
3. Boniforti F. G., Fujii G., Angliss R. D., Benson M. K. D. The reliability of measurement of pelvic radiographs in infants. *J. Bone Joint Surg.*, 1997, 79-B, 570-575.
4. Broughton N. S., Brougham D. I., Cole W. G., Menelaus M. B. Reliability of radiologic measurement in the assessment of the child's hip. *J. Bone Joint Surg.*, 1989, 71-B, 6-8.
5. Drummond D. S., O'Donnell J., Breed A., Albert M. J., Robertson W. W. Arthrography in the evaluation of congenital dislocation of the hip. *Clin. Orthop.*, 1989, 243, 148-156.
6. Garvey M., Donoghue V. B., Gorman W. A., O'Brien N., Murphy J. P. A. Radiographic screening at four months of infants at risk for congenital hip dislocation. *J. Bone Joint Surg.*, 1992, 74-B, 704-707.
7. Gusic S. E., Babini J. C., Garay S. M., Garcia M. O., Maldonado C. J. A. Evaluation of the measurement methods for protrusio acetabuli in normal children. *Skeletal Radiol.*, 1990, 19, 279-282.
8. Kay R. M., Watts H. G., Dorey F. Variability in the assessment of index. *J. Pediatr. Orthop.*, 1997, 17, 170-173.
9. Li H. Y., Hafeez M., Emery R. J. S., Leong J. C. Y. The c/b ratio in the radiological monitoring of the hip joint in congenital dislocation of the hip. *J. Pediatr. Orthop.*, 1995, 15, 806-811.
10. Ogata S., Moriya H., Tsuchia T., Kamegaya M., Someya M. Acetabular cover in congenital dislocation of the hip. *J. Bone Joint Surg.*, 1990, 72-B, 190-196.
11. Rosen A., Gannle J. G., Vallier H., Bloch D., Smith L., Rinsky L. A. Analysis of radiographic measurements as prognostic indicators of treatment success in patients with developmental dysplasia of the hip. *J. Pediatr. Orthop.*, 1999, 8, 118-121.
12. Samani D. J., Weinstein S. L. The pelvic tear-figure : A three dimensional analysis of the anatomy and effect of rotation. *J. Pediatr. Orthop.*, 1994, 14, 560-569.
13. Scoles P. V., Boyd A., Jones P. K. Roentgenographic parameters of the normal infant hip. *J. Pediatr. Orthop.*, 1987, 7, 656-663.
14. Sharp I. K. Acetabular dysplasia (The acetabular angle). *J. Bone Joint Surg.*, 1961, 43-B, 268-272.
15. Skaggs D. L., Karminsky C., Tolo V. T., Kay R. M., Reynolds R. A. K. Variability in measurement of acetabular index in normal and dysplastic hips, before and after reduction. *J. Pediatr. Orthop.*, 1998, 18, 799-801.
16. Spatz D. K., Reiger M., Klaumann F. M., Stanton R. P., Lipton G. E. Measurement of acetabular index intra-observer and inter-observer variation. *J. Pediatr. Orthop.*, 1997, 17, 174-175.
17. Tönnis D. Normal values of the hip joint for the evaluation of xrays in children and adults. *Clin. Orthop.*, 1976, 119, 39-47.

SAMENVATTING

L. TAN, S. AKTAS, C. COPUROGLU, M. OZCAN, M. TURE. Betrouwbaarheid van radiologische parameters op een Pelvis face bij heupdysplasie.

Retrospectieve studie van 15 radiografische bekken face opnamen van kinderen met congenitale heupdysplasie en evaluatie van de betrouwbaarheid van de gebruikelijke parameters: de acetabulaire index, de center-edge hoek van Wiberg, de c/b ratio, de hoek van Sharp en het uitzicht van het acetabulaire druppel of het U teken. Twee auteurs berekenden deze parameters tweemaal met een interval van verschillende dagen, op beelden die onidentificeerbaar en eenvoudig genummerd waren. De intra- en inter-observer variabiliteit werd bekeken: op beide vlakken bleken de acetabulaire index en de c/b hoek meest betrouwbaar. De inter-observer variabiliteit leek te groot voor drie parameters: de CE hoek, de Sharp hoek en het U-beeld. De auteurs besluiten dat de acetabulaire index en de c/b hoek de meest valable parameters zijn in de evaluatie van congenitale evolutieve heupdysplasie.

RÉSUMÉ

L. TAN, S. AKTAS, C. COPUROGLU, M. OZCAN, M. TURE. Fiabilité des paramètres radiologiques mesurés sur les radiographies de face du bassin chez des patients présentant une dysplasie de la hanche.

Les auteurs ont revu rétrospectivement les radiographies de face du bassin de 15 patients qui présentaient une dysplasie de développement de la hanche, dans le but d'évaluer la fiabilité des paramètres radiologiques. Les paramètres suivants ont été étudiés: l'index acétabulaire, l'angle VCE, le rapport c/b, le U radiologique et l'angle de Sharp. Les paramètres ont été mesurés par chacun des deux auteurs, à deux reprises avec un intervalle de plusieurs jours entre les mesures. Les variations inter- et intraobservateurs ont été calculées. La mesure de l'index acétabulaire et du rapport c/b s'est avérée fiable aussi bien pour les mesures du même observateur qu'entre observateurs; par contre la détermination de l'angle VCE, de l'U radiologique et de l'angle de Sharp n'était fiable que pour les comparaisons intraobservateurs. Les auteurs concluent que l'index acétabulaire et le rapport c/b peuvent être valablement utilisés dans l'évaluation d'une dysplasie de développement de la hanche.