



Operative treatment of chondroblastoma : a study of 11 cases

Onur HAPA, Ahmet KARAKAŞLI, Nihat Demirhan DEMIRKIRAN, Olcay AKDENİZ, Hasan HAVİTÇİOĞLU

From the department of Orthopedic surgery, Dokuz Eylül University, Izmir, Turkey

Aim of the study was to review the radiological, clinical results of 11 chondroblastoma cases treated at our institute between 2003-2013. All patients with chondroblastoma included in this study underwent intralesional curettage +/- bone grafting. Follow up for healing of chondroblastoma lesions and detection of any local recurrence was assessed on clinical and radiological bases. The functional outcome was assessed by the Musculoskeletal Tumour Society scoring system. The mean follow-up period was 6.1 years. There were three recurrences (two femoral head, one proximal tibia). The mean Musculoskeletal Tumour Society functional score was 21. First line aggressive treatment seems appropriate for chondroblastoma especially when localized at lower extremities.

Keywords : chondroblastoma ; operative treatment.

INTRODUCTION

Chondroblastomas are rare benign bone tumours occurring in young patients with a male preponderance (male to female ratio 2:1) and account for only 1% of all benign bone lesions (2,8,20). The tumours usually occur in the long bones and involve the epiphysis or apophysis (10). The accepted treatment method for chondroblastoma is curettage and filling of the bone defect (1). However due to localization of the tumor, there exists complication risks like articular cartilage injury with resultant premature arthritis and growth plate injury with resultant growth disturbance (1,16,17). There is also risk of recurrence

probably due to inadequate resection and/or aggressive behavior of the tumor (12,14,16,18,20,22).

The purpose of this study was to review retrospectively a group of patients who had this rare tumor, and the discussion of possible related risk factors associated with tumor recurrence.

PATIENTS AND METHODS

11 patients with chondroblastoma presenting to our department between 2003-2013 were included at the present study. Diagnosis was made depending on radiological and histological criteria. Radiological staging was made upon the criteria described by Enneking (inactive (intraosseous location with intact reactive sclerotic rim ; absence of pain) ; active (intraosseous location or contained within periosteal neocortical bone ; thin, incomplete sclerotic rim ; pain) ; or aggressive (poorly defined edge, with minimal/ no sclerotic rim, permeating the corticalis and the extraosseous growth not being contained by neocortical bone) (5). Metaphyseal inclusion was also recorded.

-
- Onur Hapa.
 - Ahmet Karakaşlı.
 - Nihat Demirhan Demirkıran.
 - Olcay Akdeniz.
 - Hasan Havıtcıođlu.
Department of Orthopedic surgery, Dokuz Eylül University, Izmir, Turkey.
- Correspondence : Dr Onur Hapa, Department of Orthopedic surgery, Dokuz Eylül University, 35330 Izmir, Turkey.
E-mail : onurhapa@gmail.com
© 2016, Acta Orthopædica Belgica.
-

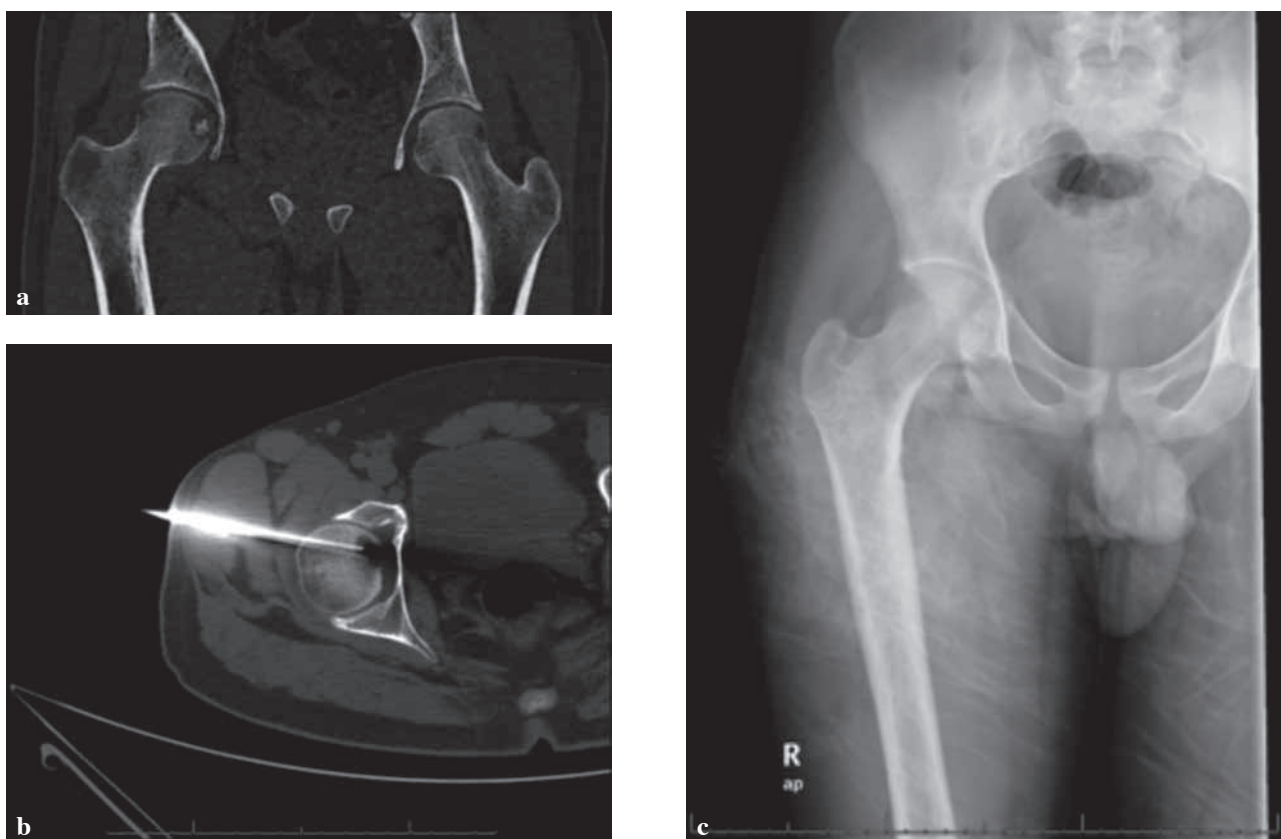


Fig. 1a. — a. CT image of the lesion ; b. CT guided localization of the tumor ; c. Postoperative X ray

Lesion was localized with the computerized tomography first and patient was then taken to the operating room and the lesion was curetted +/- grafted (Fig. 1). Patients 2, 10 received lateral approach and percutaneous curettage of the lesion. Patient 9 was treated with lateral approach with trochanteric osteotomy and safe dislocation of the femoral head and curettage and grafting of the lesion.

Patients 1, 2, 10 received only curettage. Allograft was used at patient number 4. Calcium phosphate cement was used at patient number 9. Rest was grafted with autologous iliac bone.

Patients were followed up for a mean of 6.1 (range 1-11) years. Functional outcome was measured depending on the Musculoskeletal tumor society scoring system (6). Radiographs of the tumours were taken every 3 months for the first 2 years, every 4 months in the third year, and 6-monthly thereafter.

Recurrence was suspected on both recurrence of the symptoms and the abnormalities detected on plain radiographs.

RESULTS

Patient data are summarized at table I. There were 2 female, 9 male patients and mean age was 21 (14-30) years. Main presenting symptom was pain. Mean duration of symptoms was 19 months (1-96 months). At the last follow-up mean Musculoskeletal Tumour Society functional score was 21 (17-26).

There were three recurrences (2 proximal femur, 1 proximal tibia). Patient 2 was re-operated one year after the index operation. Anterior incision and curettage with autologous iliac bone grafting was performed through the window created at anterior part of the femoral head. One year after the second surgery, patient again had recurrence of the symptoms with signs of osteoarthritis at hip x ray and was then consulted to arthroplasty department. Patient 10 had recurrence of the symptoms, 5 years after the

Table I. — Patient data

Patient	Sex/age	Symptoms (months)	Tumor site	Radiographic findings Site/ Stage	Treatment	Recurrence	MSTS Score	Follow-up (years)
1	M/14	2	Distal tibia	Epi/Aggressive	Curettage	–	23	3
2	M/19	6	Femur Head	Epi/Latent	Curettage	+	17	2
3	M/27	24	Proximal tibia	Epi, meta/Latent	Curettage+grafting	–	26	11
4	M/21	12	Proximal humerus	Epi, meta /Aggressive	Curettage+grafting	–	24	9
5	M/25	12	Distal femur	Epi/Active	Curettage+grafting	–	22	7
6	M/19	24	Proximal tibia	Epi, meta /Aggressive	Curettage+grafting	–	23	1
7	F/24	24	Proximal humerus	Epi/Active	Curettage+grafting	–	23	7
8	M/18	2,5	Proximal tibia	Epi, meta /Aggressive	Curettage+grafting	+	15	10
9	M/11	8	Femur head	Epi/Latent	Curettage+grafting	–	17	1
10	M/30	1	Femur head	Epi/Active	Curettage	+?	21	9
11	F/29	96	Proximal humerus	Epi/Latent	Curettage+grafting	–	24	8

surgery and curettage plus iliac bone grafting was performed using lateral approach. Patient 8 had recurrence of the pain one year after first surgery and received curettage and iliac bone grafting once again. Both patients had no further recurrence of the lesion and satisfied with the treatment.

DISCUSSION

Chondroblastoma is a primary, locally aggressive tumour of bone. It is rare with an incidence of 1-2 % of all primary bone tumours (3,18,20). Pain was the presenting symptoms in all patients like reported in other reports (1,22). The two most frequent sites of involvement were the proximal part of the humerus and the proximal part of the tibia (4,9,18,19). Treatment is by curettage, with or without packing with bone graft or cement (7,16,22). Adjuvant cryotherapy and phenolisation have both been described, though it is unclear if these provide a significantly improved outcome. No studies have yet shown the benefit of using any of these adjuvants, nor even of the use of bone graft (15). There is not also any guidance for

usage of autologous versus allogenic cancellous graft (11).

Post treatment recurrence rates of 10%-36% have been reported in the literature (12,14,16,20,22). Associated risk factors include location in the hip and pelvis, young age, aneurysmal bone cyst components, aggressiveness, anatomic site, and inadequate surgery (12,14,16,18,20,22). There was not any aneurysmal bone cyst component at the present study.

At the present study there were three recurrences which were all seen at the lower extremity (two proximal femur, one proximal tibia). Case 2 was a latent lesion. Recurrences seen at proximal femur were secondary to percutaneous curettage which seems to result due to inadequate resection and recurrence. Similary Strong *et al* (21) reported two recurrences at lateral indirect approach while none at direct approach for treatment of femoral head osteoblastoma. Mashhour and Abdel Rahman also advised aggressive curettage at the first time to prevent recurrence and second more aggressive surgery and possible growth plate, articular cartilage injury (13). However we had choosen indirect minimally

invasive approach due to relatively older age group 'physis closed' without possible risk of physis injury. Additionally we did not encounter any angular deformity or shortness in any patients.

There exists some limitations. This is a retrospective study with limited number of cases like reported in the literature (1,10,11,13,21) with short follow-up at particular cases (Cases 6 and 9). However some conclusions can be made depending on midterm follow-up of patients. It seems most important that first line aggressive treatment seems logical to prevent recurrence and secondary surgeries with possible articular cartilage injury especially when localized at lower extremity. Supporting this is that Case number 9, although physis was open, was treated with direct curettage and grafting and there was no recurrence. However it is still difficult to interpret this case as fully healed without any further recurrence since one year follow-up is not enough.

REFERENCES

1. **Atalar H, Basarir K, Yildiz Y, Erekul S, Saglik Y.** Management of chondroblastoma : retrospective review of 28 patients. *J Orthop Sci* 2007 ; 4 : 334-340.
2. **Dahlin DC, Ivins JC.** Benign chondroblastoma. A study of 125 cases. *Cancer* 1972 ; 30 : 401-413.
3. **De Mattos CB, Angsanuntsukh C, Arkader A, Dormans JP.** Chondroblastoma and chondromyxoid fibroma. *J Am Acad Orthop Surg* 2013 ; 4 : 225-233.
4. **De Silva MV, Reid R.** Chondroblastoma : varied histologic appearance, potential diagnostic pitfalls, and clinicopathologic features associated with local recurrence. *Ann Diagn Pathol* 2003 ; 4 : 205-213.
5. **Enneking WF.** A system of staging musculoskeletal neoplasms. *Clin Orthop* 1986 ; 204 : 9-24.
6. **Enneking WF, Dunham W, Gebhardt MC, Malawar M, Pritchard DJ.** A system for the functional evaluation of reconstructive procedures after surgical treatment of tumors of the musculoskeletal system. *Clin Orthop Relat Res* 1993 ; 286 : 241-246.
7. **Fadda M, Manunta A, Rinonapoli G, Zirattu G.** Ultrastructural appearance of chondroblastoma. *Int Orthop* 1994 ; 6 : 389-392.
8. **Huvos AG, Marcove RC.** Chondroblastoma of bone. A critical review. *Clin Orthop Relat Res* 1973 ; 95 : 300-312.
9. **Jaffe HL, Lichtenstein L.** Benign chondroblastoma of bone. *Am J Pathol* 1942 ; 18 : 969-991.
10. **Lalam RK, Cribb GL, Tins BJ et al.** Image guided radiofrequency thermo-ablation therapy of chondroblastomas : should it replace surgery ? *Skeletal Radiol* 2014 ; 4 : 513-522.
11. **Lehner B, Witte D, Weiss S.** Clinical and radiological long-term results after operative treatment of chondroblastoma. *Arch Orthop Trauma Surg* 2011 ; 1 : 45-52.
12. **Lin PP, Thenappan A, Deavers MT, Lewis VO, Yasko AW.** Treatment and prognosis of chondroblastoma. *Clin Orthop Relat Res* 2005 ; 438 : 103-109.
13. **Mashhour MA, Abdel Rahman M.** Lower recurrence rate in chondroblastoma using extended curettage and cryosurgery. *Int Orthop* 2014 ; 5 : 1019-1024.
14. **Masui F, Ushigome S, Kamitani K, Asanuma K, Fujii K.** Chondroblastoma : a study of 11 cases. *Eur J Surg Oncol* 2002 ; 28 : 869-874.
15. **Mermelstein LE, Friedlaender GE, Katz LD.** Cystic chondroblastoma. *Orthopedics* 1997 ; 20 : 69-71.
16. **Ramappa AJ, Lee FY, Tang P, Carlson JR, Gebhardt MC, Mankin HJ.** Chondroblastoma of bone. *J Bone Joint Surg Am* 2000 ; 82 : 1140-1145.
17. **Sailhan F, Chotel F, Parot R.** Chondroblastoma of bone in a pediatric population. *J Bone Joint Surg Am* 2009 ; 9 : 2159-2168.
18. **Schajowicz F, Gallardo H.** Epiphyseal chondroblastoma of bone : a clinico-pathological study of sixty-nine cases. *J Bone Joint Surg Br* 1970 ; 2 : 205-226.
19. **Schaser KD, Bail HJ, Haas NP, Melcher I.** Treatment concepts of benign bone tumors and tumor-like bone lesions. *Chirurg* 2002 ; 12 : 1181-1190.
20. **Springfield DS, Capanna R, Gherlinzoni F, Picci P, Campanacci M.** Chondroblastoma. A review of seventy cases. *J Bone Joint Surg Am* 1985 ; 67 : 748-755.
21. **Strong DP, Grimer RJ, Carter SR, Tillman RM, Abudu A.** Chondroblastoma of the femoral head : management and outcome. *Int Orthop* 2010 ; 3 : 413-417.
22. **Suneja R, Grimer RJ, Belthur M et al.** Chondroblastoma of bone : long term results and functional outcomes. *J Bone Joint Surg Br* 2005 ; 87 : 974-978.