



## Internal fixation of femoral neck stress fractures in young female athletes with a dynamic locking plate

J. A. HUMPHREY, R. JANDOO, M. TOFIGHI, A. WIJK, A. TINDALL

From Queen Elizabeth Hospital, Woolwich, London, UK

**Purpose :** Displaced stress fractures of the femoral neck in young female athletes are a rare but a difficult injury to treat with a favourable outcome, as there is a reported high incidence of avascular necrosis. Traditionally they are internally fixed with either cannulated screws or a sliding hip screw. Our study aims to highlight the Targon Femoral Neck (FN, B-Braun, Aesculap Inc, Germany) implant as a safe alternative for fixation of these injuries.

**Methods :** Three consecutive young female recreational athletes were reviewed from our institution with a displaced stress fracture of the femoral neck treated with the dynamic locking plate.

**Results :** Two patients achieved good results with full union and no complications. One patient had a poor result as she developed avascular necrosis 5 months post-operatively requiring revision to a total hip arthroplasty.

**Conclusion :** Our study highlights the Targon FN implant is a safe alternative for internal fixation of displaced stress fractures of the femoral neck in young female recreational athletes.

**Keywords :** stress fracture ; young athletes ; Targon FN implant.

reparative process of callus formation and remodeling. They occur in normal or metabolically weakened bone ; in contrast to insufficiency fractures that occur under normal stress in pathological bone (7). Stress fractures occur predominately in the lower limb, and the most common locations are the tibia (49.1%), tarsals (25.3%), metatarsals (8.8%), femur (7.2%), fibula (6.6%) and pelvis (1.6%) (16). A stress fracture of the femoral neck is a rare injury seen predominately in military recruits and long-distance runners (13,23). If displaced these fractures are a difficult injury to treat with a favourable outcome. Complications include delayed union, non-union and avascular necrosis (15).

The Targon Femoral Neck (FN, B-Braun, Aesculap Inc, Germany) implant is used for fixation of intracapsular neck of femur fractures, which are more commonly seen in the elderly population after

### INTRODUCTION

Stress fractures are repetitive overuse injuries. Microscopic cracks occur with cyclical loading and the bone fails if the crack propagates faster than the

- 
- J. A. Humphrey, BSc (Hons) MBBS MSc MRCS.
  - R. Jandoo, BA (Hons) BM BCh.
  - M. Tofghi, MBBS MRCS MSc FRCS (Tr & Orth).
  - A. Wiik, MBBS.
  - A. Tindall, MBBS MSc FRCS (Tr & Orth).

Queen Elizabeth Hospital, Woolwich, London, UK.

Correspondence : Joel A. Humphrey, Trauma & Orthopaedic Department, Queen Elizabeth Hospital, Stadium Road, Woolwich, London, UK. E-mail : drjoelhumphrey@aol.com

© 2015, Acta Orthopædica Belgica.

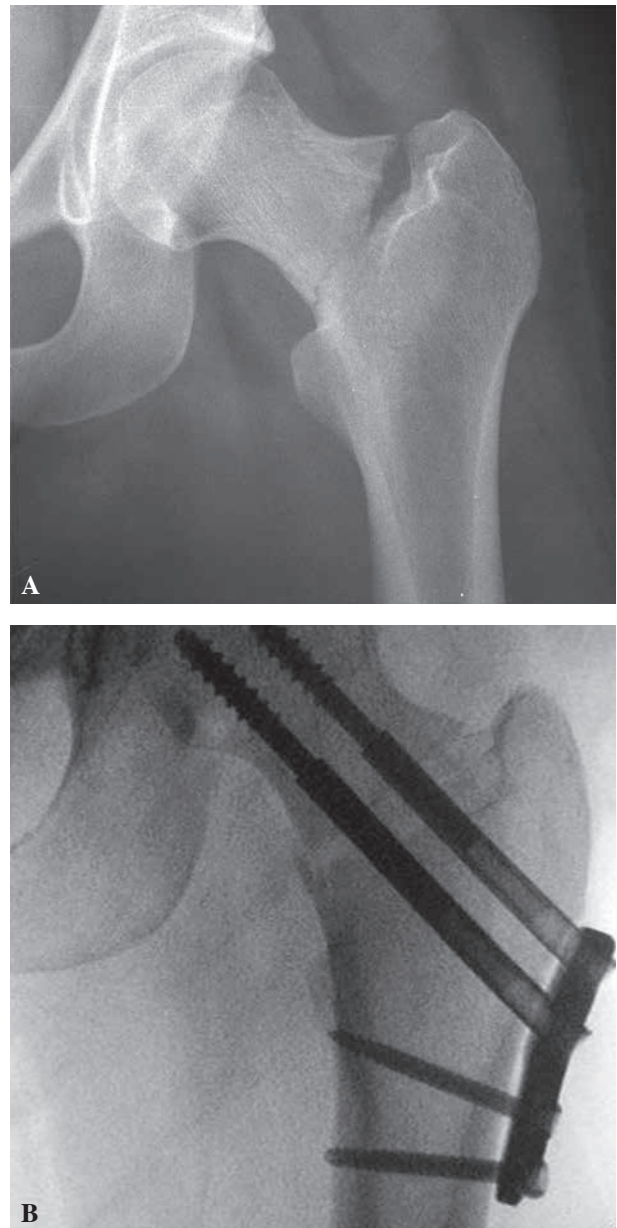
low velocity impact (18,20). The principles of treatment for a displaced femoral neck stress fracture in a young patient is to preserve the femoral head with anatomic reduction and stable internal fixation. Total joint arthroplasty is an option, but is certainly not ideal for the first line of surgical management due to the patients' young age and high activity levels. The Targon FN implant incorporates features of the two most common devices used for fixation of these injuries, which are the sliding hip screw and multiple parallel cancellous screws. Our case series highlights a dynamic locking plate as a successful technique in treating young female athletes with a displaced intracapsular stress fracture of the femoral neck.

### PATIENTS AND METHODS

Stress fractures of the femoral neck in young female athletes, who required surgery, were identified in four consecutive patients admitted to our institution between 2010 and 2013. All underwent internal fixation with a Targon FN implant. Our inclusion criteria for the case series were female recreational athletes < 35 years of age who had sustained a stress fracture of the femoral neck. Patients injured with high velocity trauma were excluded. In total cohort of four patients were identified. One patient was lost to follow-up and could not be contacted, therefore was omitted from the study.

Mean patient age at time of injury was 28.7 (range 25 to 33). All sustained a stress fracture of the femoral neck, which was intracapsular and displaced (Garden classification III/IV) requiring surgical fixation (11). The cohort were all recreational runners, who developed non-specific hip or groin pain preceding the fracture. Mean duration between initial symptoms and fracture was 14 days (range 7 to 21). The fractures subsequently all occurred during normal daily activities.

Fractures involved 2 right hips and 1 left hip. All patients received emergency surgery within 24 hours after hospital admission. Internal fixation was achieved with a Targon FN implant consisting of a small plate with six locking screw holes. Three or four angular stable 6.5 mm telescoping screws cross the fracture site for fixation in the subchondral bone of the femoral head and two distal 4.5mm locking screws in the lateral cortex of the femur (Fig. 1). Details of the intra-operative technique used, has previously been described by the Parker group (19). Mean duration of surgery was 64 minutes (range 60-70).



**Fig. 1.** — Pre-operative AP plain radiograph showing a displaced basicervical stress fracture of the left hip & intra-operative image intensifier showing internal fixation with the Targon FN Implant.

### RESULTS

Mean follow-up period was 3.3 years (range 2 to 5). Results were graded as good, acceptable or poor using the Arnold outcome categories for femoral neck fractures (1). Union was defined by absence of

visible margins on the AP and lateral radiographs. Two patients achieved good results by returning to normal function with full union and no complications. One patient had a poor result as she developed avascular necrosis 5 months post-operatively requiring revision to a total hip arthroplasty.

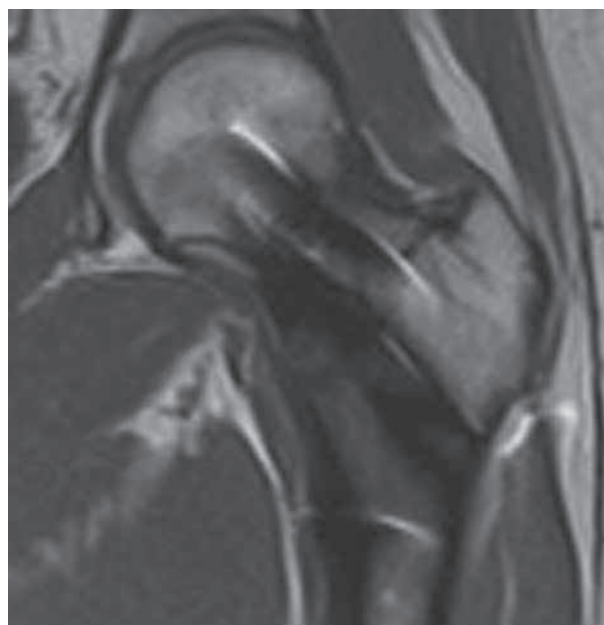The Body Mass Indices were all normal healthy weights (mean 22.2, range 19.6 to 24). One patient had previously suffered from anorexia nervosa with secondary amenorrhea. Post-operative dual energy X-ray absorptiometry (DEXA) scans all showed decreased bone mineral density; T Score mean -2.4, range -2 to -2.7. Vitamin D levels highlighted two cases of insufficiency (50-75 nmol/L) and one deficiency (< 50 nmol/L).

### DISCUSSION

The Targon FN implant is a locking plate and dynamic screw system for internal fixation of intracapsular hip fractures (18). Although predominantly used in the elderly population, clinical results available highlight it can also be used as a safe alternative to multiple parallel screws or a sliding hip screw for fixation of stress fractures of the femoral neck in the young female athlete.

A two-year follow-up of 320 patients with an intracapsular fracture of the hip using a dynamic locking plate suggests a stronger distal fixation combined with rotational stability may lead to a reduced incidence of complications related to the healing fracture when compared to other fixation devices (19). Subsequent comparative studies with the traditional fixation methods are also encouraging; as there is less subsidence of the head fragment, lower cut out rate and a lower conversion to hemiarthroplasty after Targon FN fixation in comparison to a standard sliding hip screw fixation (6). Also recent randomized control trial showed there was no difference in the risk of revision surgery between patients treated for an intracapsular proximal femur fracture with a Targon FN hip screw and those treated with cannulated screw fixation (10).

The device provides several design advantages over the established methods of either multiple parallel screws or a sliding hip screw, which would be beneficial for surgical treatment of stress fractures



**Fig. 2.** — Two-year post-operative MRI scan (T-2 weighted, coronal view, left hip) with Targon FN Implant in-situ showing no evidence of avascular necrosis and full union.

of the femoral neck. Cadaveric biomechanical testing of the three constructs suggests the dynamic locking plate is a more stable fixation (3), permitting potential early post-operative mobilization. Telescoping screws in the femoral head, which are locked into the plate, allow the fracture to consolidate with controlled collapse along the femoral neck without backing out of the screws into the soft tissue, reducing local irritation (18). The small plate can be inserted with minimal surgical exposure of the femur, improving the cosmetic outcome in young females. Also the two distal locking screws in the lateral femoral cortex allow solid fixation in poor bone quality. The implant material of titanium alloy Ti6Al4V is MRI compatible for post-operative imaging, rather than stainless steel implants which produce artifact limiting accurate interpretation of the images (Fig. 2). This is particularly advantageous for long-term surveillance in the young and active population, to identify non-unions or early pre-radiological avascular necrosis.

Diagnosis of stress fractures of the femoral neck can be challenging for the clinician. These injuries frequently occur with high intensity training or a

sudden increase in an athlete's normal training regime. Excessive loading of the bone, repetitive exercise and gluteal medius muscle fatigue reducing its normal shock absorbing capacity are all important contributing factors to stress fracture of the femoral neck (5). Patients can present with an insidious onset of thigh or groin pain associated with activity and eases at rest. Often these symptoms are attributed to a groin strain, as clinical examination is equivocal ; therefore a high index of suspicion is required when initially assessing these patients. Although, the injury is not common, the incidence of displacement following a stress fracture of the femoral neck is high ranging from 12.3%-66.2%, usually due to continuation of rigorous training (8, 15).

If these fractures are detected without displacement and early non-surgical treatment (non or reduced weight bearing) is commenced, favourable outcomes can be expected (22). However, a delay in diagnosis can cause subsequent displacement requiring surgical treatment and also having a significant impact on long-term morbidity of delayed union / non union, avascular necrosis of the femoral head and osteoarthritis (13,23). All our patients had prodromal symptoms, but were only diagnosed after displacement occurred, either due to early misdiagnosis or delayed presentation.

Plain radiographs are the first imaging modality of choice, which are usually negative but repeat radiographs after 2-3 weeks can show reactive changes (21). Compression fractures occur on the inferior aspect of the femoral neck and are generally stable (4). Tension fractures occur on the superior aspect of the femoral neck causing a transverse pattern, which is more likely to displace (4,5). If an occult femoral neck stress fracture is suspected clinically and the initial plain radiographs are normal, the authors would advocate immediate further imaging. An MRI scan is more sensitive than a bone scan and should be used as gold standard in the diagnosis of stress fractures (14).

Intracapsular fractures in young patients are usually secondary to high velocity trauma in men and account for only 3% of all femoral neck fractures (25). They are associated with high rates of avascular necrosis and non-union (24). Although

stress fractures of the femoral neck are low velocity repetitive injuries, larger studies show incidence of avascular necrosis ranging from 23.8%-42% (15,26). The displacement with comminution of the posterior cortex of the femoral neck compromises the circulation of the femoral head (26). There is disruption to the lateral epiphyseal artery and posterior superior retinacular branches of the medial femoral circumflex artery. One of our patients (33%) developed avascular necrosis requiring revision surgery to a total joint replacement. The other two patients had no complications, and experienced a good outcome regaining pain free and normal function.

The Female Athlete Triad is a condition most commonly observed in runners, which consists of low energy availability, functional hypothalamic amenorrhea and osteoporosis (17). Prevalence of the syndrome is low in exercising females (0%-16%), however 50%-60% of certain athlete groups have 1 or 2 of the components (9). The presence of a single risk factor or combined risk factors for the Female Athlete Triad increases the cumulative risk of bone stress injury, including stress reactions and stress fractures (2). In our study, the patients were recreational runners with healthy BMIs. However osteopenia or osteoporosis was diagnosed post-operatively with routine DEXA scans, therefore more susceptible to sustaining a stress fracture. Evidence shows that serum concentrations of Vitamin D < 80 nmol/L are associated with reduced calcium absorption, osteoporosis and increased fracture risk (12). The cohort all had serum levels of Vitamin D showing deficiency or insufficiency.

Our study highlights the Targon FN implant is a safe alternative for internal fixation of displaced stress fractures of the femoral neck in young female recreational athletes. Features of minimally invasive surgery, locking design for poor bone quality, no soft tissue irritation from screws backing out and MRI compatibility also make the implant ideal for this patient group.

## REFERENCES

1. Arnold WD, Lyden JP, Minkoff J. Treatment of intracapsular fractures of the femoral neck. *J Bone Joint Surg [Am]* 1974 ; 56 : 254-262.



2. **Barrack MT, Gibbs JC, De Souza MJ, Williams NI, Nichols JF, Rauh MJ, Nattiv A.** Higher incidence of bone stress injuries with increasing female athlete triad-related risk factors : a prospective multisite study of exercising girls and women. *Am J Sports Med* 2014 Apr ; 42 (4) : 949-58. doi : 10.1177/0363546513520295. Epub 2014 Feb 24.
3. **Brandt E, Verdonschot N, van Vugt A, van Kampen A.** Biomechanical analysis of the sliding hip screw, cannulated screws and Targon FN in intracapsular hip fractures in cadaver femora. *Injury* 2011 ; 42 : 183-187.
4. **Devas MB.** Stress fractures of the femoral neck. *J Bone Joint Surg Br* 1965 ; 47 : 728-738.
5. **Egol KA, Koval KJ, Kummer F, Frankel VH.** Stress fractures of the femoral neck. *Clin Orthop Relat Res* 1998 Mar ; (348) : 72-78.
6. **Eschler A, Brandt S, Gierer P, Mittlmeier T, Gradl G.** Angular stable multiple screw fixation (Targon FN) versus standard SHS for the fixation of femoral neck fractures. *Injury* 2014 Jan ; 45 Suppl 1 : S76-80. doi : 10.1016 / j.injury. 2013.10.026. Epub 2013 Oct 28.
7. **Fayad LM, Kamel IR, Kawamoto S, Bluemke DA, Frassica FJ, Fishman EK.** Distinguishing stress fractures from pathologic fractures : a multimodality approach. *Skeletal Radiol* 2005 ; 34(5) : 245-259.
8. **Fullerton LR, Snowdy HA.** Femoral neck stress fractures. *Am J Sports Med* 1988 ; 16 : 365-377.
9. **Gibbs JC, Williams NI, De Souza MJ.** Prevalence of individual and combined components of the female athlete triad. *Med Sci Sports Exerc* 2012. doi : 10.1249/MSS.0b013e31827e1bdc.
10. **Griffin XL, Parsons N, Achten, Costa M.** The Targon Femoral Neck hip screw versus cannulated screws for internal fixation of intracapsular fractures of the hip. *Bone Joint J* 2014 ; 96-B : 652-7.
11. **Garden RS.** Low-angle fixation in fractures of the femoral neck. *J Bone Joint Surg (Br)* 1961, 43 : 647-663.
12. **Heaney RP.** Functional indices of vitamin D status and ramifications of vitamin D deficiency. *American Journal of Clinical Nutrition* 2004 ; 80 (6 Suppl) : 1706S-1709S.
13. **Johansson C, Ekenman I, Törnkvist H, Eriksson E.** Stress fractures of the femoral neck in athletes. The consequence of a delay in diagnosis. *Am J Sports Med* 1990 Sep-Oct ; 18(5) : 524-528.
14. **Kiuru MJ, Pihlajamäki HK, Hietanen HJ, Ahovuo JA.** MR imaging, bone scintigraphy, and radiography in bone stress injuries of the pelvis and the lower extremity. *Acta Radiol* 2002 Mar ; 43(2) : 207-212.
15. **Lee CH, Huang GS, Chao KH, Jean JL, Wu SS.** Surgical treatment of displaced stress fractures of the femoral neck in military recruits : a report of 42 cases. *Arch Orthop Trauma Surg* 2003 Dec ; 123 (10) : 527-533.
16. **Matheson GO, Clement DB, McKenzie DC, Taunton JE, Lloyd-Smith DR, MacIntyre JG.** Stress fractures in athletes. A study of 320 cases. *Am J Sports Med* 1987 Jan-Feb ; 15 (1) : 46-58.
17. **Nattiv A, Loucks AB, Manore MM, Sanborn CF, Sundgot-Borgen J, Warren MP.** American College of Sports Medicine position stand. The female athlete triad. *Med Sci Sports Exerc* 2007 ; 39 : 1867-1882.
18. **Parker M.** A new locking plate and dynamic screw system for internal fixation of intracapsular hip fractures. *J Bone Joint Surg Br* 2011 vol. 93-B no. SUPP I 33.
19. **Parker M, Cawley S, Palial V.** Internal fixation of intracapsular fractures of the hip using a dynamic locking plate : Two-year follow-up of 320 patients. *Bone Joint J* 2013 Oct ; 95-B(10) : 1402-5. doi : 10.1302/0301620X.95B10.31511.
20. **Parker MJ, Stedfelt H.** Internal fixation of intracapsular hip fractures with a dynamic locking plate ; initial experience and results for 83 patients treated with a new implant. *Injury* 2010 ; 41 : 348-351.
21. **Patel DS, Roth M, Kapil N.** Stress fractures : diagnosis, treatment, and prevention. *Am Fam Physician* 2011 Jan 1 ; 83 (1) : 39-46.
22. **Pihlajamäki HK, Ruohola JP, Weckström M, Kiuru MJ, Visuri TI.** Long-term outcome of undisplaced fatigue fractures of the femoral neck in young male adults. *J Bone Joint Surg Br* 2006 Dec ; 88 (12) : 1574-1579.
23. **Pihlajamäki HK, Ruohola JP, Kiuru MJ, Visuri TI.** Displaced femoral neck fatigue fractures in military recruits. *J Bone Joint Surg Am* 2006 Sep ; 88 (9) : 1989-1997.
24. **Protzman RR, Burkhalter WE.** Femoral-neck fractures in young adults. *J Bone Joint Surg Am* 1976 Jul ; 58 (5) : 689-695.
25. **Robinson CM1, Court-Brown CM, McQueen MM, Christie J.** Hip fractures in adults younger than 50 years of age. Epidemiology and results. *Clin Orthop Relat Res* 1995 Mar ; (312) : 238-46.
26. **Visuri T, Vara A, Meurman KO.** Displaced stress fractures of the femoral neck in young male adults : a report of twelve operative cases. *J Trauma* 1988 Nov ; 28 (11) : 1562-9.