



Correlation between dorsovolar translation and rotation of the radius on the distal radioulnar joint during supination and pronation of forearm

Sang Ki LEE, Young Dong SONG, Won Sik CHOY

From Department of Orthopedic Surgery, Eulji University College of Medicine, Daejeon, Korea

This study aimed to describe the patterns of movements about radius and ulna in individual degrees of forearm rotation. And, we also determined the effect of forearm rotation on translation and rotation of the radius with reference to the ulna, and to measure the relationship between forearm rotation, translation and rotation of the radius. Computed tomography of multiple, individual forearm positions, from 90° pronation to 90° supination, was conducted in 26 healthy volunteers (mean age, 43.9 years) to measure dorsovolar translation and rotation of the radius in the DRUJ in each forearm position. The mean dorsovolar translations were within 1.99 mm at 90° pronation to -2.03 mm at 90° supination.

The rotations of the radius were 71.20° at 90° pronation and -46.63° at 90° supination. There were strong correlations between degrees of forearm rotation and dorsovolar translation ($r = 0.861$, $p < 0.001$) and rotation of the radius ($r = 0.960$, $p < 0.001$), suggesting that the DRUJ, carpal joints, and rotatory laxity of the carpal ligament, especially in supination, contribute to forearm supination and pronation. These findings provide an understanding of wrist kinematics, are may be useful in reconstructive wrist surgery to achieve normal range of motion, and are may be helpful for the design of DRUJ reconstruction using prostheses.

Keywords : distal radioulnar joint ; carpal joints ; computed tomography.

INTRODUCTION

The wrist is a complex, compound joint consisting of the midcarpal joint, radiocarpal joint, and distal radioulnar joint (DRUJ). The radiocarpal and midcarpal joints are primarily responsible for the flexion-extension and radio-ulnar movements of the wrist, while the DRUJ, together with the proximal radioulnar joint (PRUJ), allows pronation-supination of the wrist (20).

Motion of DRUJ is not a simple hinge-like motion, but rather a complex motion ; the difference in curvature between the sigmoid notch and ulnar head leads to joint incongruity that allows both rotational and translational motion (23). DRUJ motion depends on the ligament between the radius and ulna and can be affected by injury or disease, such as DRUJ instability, malunion of the distal radius, or radioulnar synostosis (22). Precise positioning of the DRUJ is

■ Sang Ki Lee, MD, Associate Professor.

■ Young Dong Song, MD, Fellow.

■ Won Sik Choy, MD, Professor.

Department of Orthopedic Surgery, Eulji University College of Medicine, Daejeon, Korea.

Correspondence to : Sang Ki Lee, Department of Orthopedic Surgery, Eulji University, College of Medicine, 65, Dunsanse-ro, Seo-gu, Daejeon 302-799, Korea.

E-mail : sklee@eulji.ac.kr

© 2015, Acta Orthopædica Belgica.

crucial following ligament repair or reconstructive surgery. Understanding the motion characteristics of this complex joint may help to plan treatment, including the design of ligament reconstruction procedures or DRUJ reconstruction using prostheses.

Previous studies have shown that rotation from neutral to approximately 50° pronation or 50° supination is almost rotation of the radius around the ulna only, while at positions > 50° rotation, translational slide of the radius on the ulnar head also occurs (8). The translation of the radius during pronation and supination is characterized by a volar shift of the radius during pronation and dorsal shift during supination, as demonstrated in a cadaveric study (10).

Many recent studies have tried to establish the complex anatomy and biomechanics at the DRUJ using various *in vitro* and *in vivo* methods. *In vivo* studies have used computed tomography (CT) and magnetic resonance imaging (MRI) to examine DRUJ kinematics and quantify DRUJ translation during rotation (1,18,26). A study in which dorsovolar shear force was applied to the neutral distal radius demonstrated a mean translation of the DRUJ of 5.5 mm (15). In another *in vivo* study using kinematic analysis with three-dimensional to two-dimensional (3D to 2D) registration techniques that matched 3D models with radiographic projections, significant differences in translation were reported between 30° supination, neutral position, 30° pronation, and 60° pronation when subjects rotated their wrist from maximum supination to maximum pronation (12). Still another *in vivo* study using a finite helical axis found that the forearm axis extended from the radial head and the PRUJ to the dorsal region of the ulnar head at the DRUJ (25). An MRI-based kinematic analysis demonstrated movement, within a small range, of the rotational center almost through the ulnar head (16).

The normal arc of the wrist during pronation and supination ranges from 150° to 180°. Additional rotation of up to 30° occurs through the carpal joints (6). An *in vitro* study showed that overall wrist range of motion (ROM) decreased after proximal row carpectomy (3). Another *in vivo* analysis chronicled 34° of axial rotation in the carpus, especially in the midcarpal joints, during wrist rotation (7).

Despite this collective knowledge, little is known about the specific correlations between the ulna and the radius or axial rotations. Many DRUJ studies have been limited by small samples and few angle variations during forearm rotation, typically composed of neutral, midpoint, and maximal angles. Moreover, the degree of DRUJ involvement in ROM is unknown.

This study aimed to describe the patterns of movements about radius and ulna in individual degrees of forearm rotation. And, we also determined the numerical effect of forearm rotation on translation and rotation of the radius with reference to the ulna, and to measure the relationship between forearm rotation, translation and rotation of the radius.

MATERIALS AND METHODS

Subjects

After institutional review board approval, 26 healthy volunteers (26 right and 26 left wrists) were enrolled in the study and provided consent. Their mean age was 43.9 (range, 19-63) years, and 23 volunteers were right hand dominant. An experienced senior hand surgeon evaluated the participants to exclude any previous upper limb pathology.

Apparatus and imaging

All 52 wrists were examined using CT and a grip goniometer designed to rotate the wrist to various angles (Fig. 1), consisting of a vertical wooden plate and hand-grip mounted with the goniometer. The wrist support was comprised of a hard spacer attached to the base of the apparatus to help maintain longitudinal alignment of the wrist. Subjects were positioned nearly prone on the device, with the elbow in 45° of flexion and the shoulder in neutral rotation and 90° of forward flexion. An adjustable support cushion under the subject's arm and chest increased the comfort of the subject during imaging and helped maintain their position (Fig. 2). To reduce interference in the wrist motion from changes in ulnar variance related to grip strength, the grip strength in each position was the minimum required to maintain the accurate wrist position.

The 3D CT data were collected from 128 slices, each 0.6 mm thick (Siemens, Forchheim, Germany). In 52 helical CT, acquisition of axial sections of the DRUJ was




Fig. 1. — Custom apparatus designed to rotate the wrist to various angles during computed tomography.

The apparatus consists of a vertical wooden plate and handgrip mounted to a goniometer. For wrist support, a hard spacer is attached to the base of the apparatus to maintain longitudinal alignment of the wrist.

conducted at neutral rotation (0°) and at 20° , 40° , 60° , 70° , 80° , and 90° each of forearm pronation and supination.

Each image was assessed to determine if adequate forearm rotation had been achieved, and subjects with inadequate rotation which showed which had inappropriate direction of rotation or unstable motion during CT scan are excluded from the study. In examinations of the extremities, the principal mechanism of potential radiation injury was skin erythema, a non-stochastic effect. The estimated skin entrance dose was 6.5 R per examination, which was well below the threshold of ≥ 200 R.

Image data analyses

At each wrist position, the image containing the widest sectional area and continuous cortical outline of the ulnar head, including the ulnar styloid, was selected for consistent results. With each selected axial CT image, two parameters were measured using the Marosis M-view 5.3 picture archiving and communication system measurement tools (Marotech, Seoul, Korea) : dorsovolar translation and rotation of the radius.

Before the measurements, reference lines and points were set up. A line (sigmoid connecting line) was drawn connecting the dorsal (point “a” on Fig. 3A) and volar (point “b” on Fig. 3A) margins of the sigmoid notch to reflect radial movements. The center of the ulnar head (point “c” on Fig. 3A) was used as a reference point to minimize the effect of normal translational motion during forearm rotation and was identified with a circle ap-

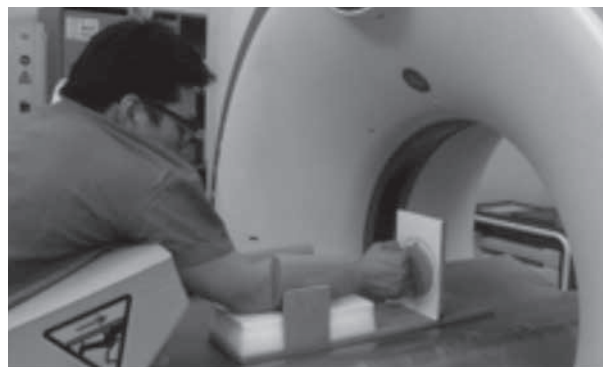


Fig. 2. — Computed tomography was performed with the subject lying pronated, the shoulder in neutral rotation and 90° forward flexion, and the elbow in 45° of flexion.

An adjustable support cushion under the subject’s arm and chest increased the comfort of the subject during imaging and helped maintain the subject’s position.

proximation technique using a transparent computerized template. The arc of the circle that could congruently fit within the rim of the ulnar head was positioned, and the center of this circle was marked as the center of ulnar head. The tangent line of the ulnar styloid (point “d” on Fig. 3A) was used as an index for the rotational alignment of the distal radius because the ulnar head has less rotational movement during pronation and supination than the distal radius due to the constraints of humeroulnar articulation inherent in a simple hinge joint. In the axial image, the ulnar styloid axis and radial axis were defined as the tangent line of the ulnar styloid and a line perpendicular on the sigmoid connecting line, respectively. The angle between the ulnar styloid and radial axes (“ α ” on Fig. 3B) was considered the rotation of the radius.

One vertical line from the midpoint of the sigmoid connecting line to the ulna was drawn, and another vertical line was drawn from the first vertical line to the center of the ulna. We defined dorsovolar translation as the perpendicular distance between the center of the ulnar head and sigmoid connecting line (“ β ” on Fig. 3B), eliminating the reliance on both the radial aspect of the radius and the ulnar styloid.

The differences in dorsovolar translation and rotation of the radius values between the neutral and various angles provided the relative changes in radial motion. For purposes of analysis and data presentation, all pronated rotations and volar translations of the radius were defined as positive, and supinated rotations and dorsal translations of the radius were defined as negative.

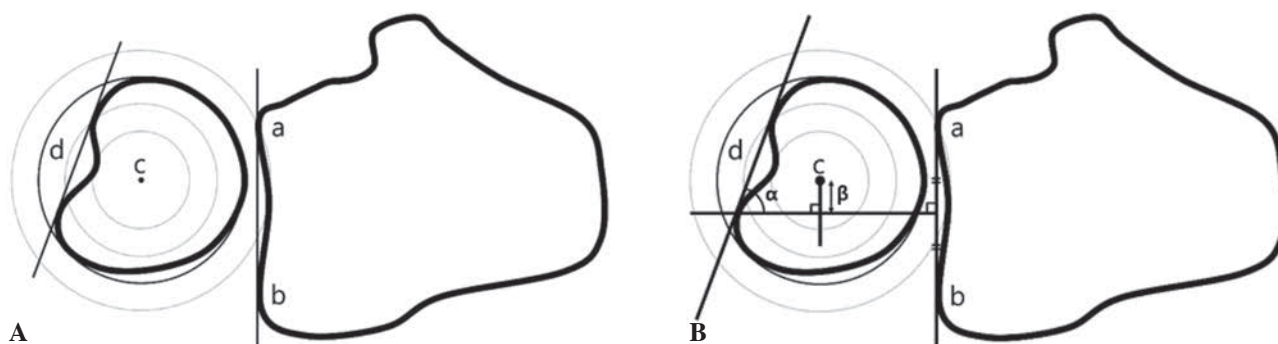


Fig. 3. — Reference points and lines for the computed tomography images and details of each parameter.

(A) A line reflecting radial movement was drawn connecting the dorsal (point a) and volar (point b) margins of the sigmoid notch and defined as the sigmoid connecting line. The center of the ulnar head (point c) was identified using concentric circles. The tangent line of the ulnar styloid (point d) was used as the index for the rotational alignment of the distal radius. (B) The angle between the tangent line of the ulnar styloid and vertical line of the sigmoid notch (α) was measured to indicate the rotation of the radius. One vertical line from the midpoint of the sigmoid connecting line to the ulna was drawn, and another vertical line was drawn from the previous vertical line to the center of the ulna. Dorsovolar translation was defined as the perpendicular distance between the center of the ulnar head and sigmoid connecting line (β). This eliminated reliance on both the radial aspect of the radius and the ulnar styloid.

Validation and reliability

Two examiners (one orthopedic hand surgeon and one general orthopedic surgeon) measured all of the images independently at 1.5 times magnification in a blinded and randomized manner to determine the interobserver reliability of each method. The same observers repeated the measurements 2 weeks later to determine the intraobserver reliability. Intraclass correlation coefficients (ICC) were used to determine the interobserver (two-way random-effects ICC model) and intraobserver (one-way random-effects ICC model) reliability of each method. The interpretation of the ICC values was based on the criteria proposed by Landis and Koch (11). ICC values 0.00-0.20 represented slight agreement, 0.21-0.40 represented fair agreement, 0.41-0.60 represented moderate agreement, 0.61-0.80 represented substantial agreement, and > 0.81 represented almost perfect agreement.

The two observers' measurements for each subject were averaged and considered to be the final value for that subject (mean and standard deviation [SD]).

Statistics

Data are expressed as mean and SD. All statistical analyses were performed using SPSS version 20.0 (IBM Corp., Armonk, NY). A p -value < 0.05 was considered statistically significant. Serial means comparisons were conducted using paired t -tests and Pearson correlations.

The number of subjects required for the reliability study was calculated (27) to ensure that significant agreement would be observed if the correlation was ≥ 0.75 with an alpha of 0.05 and beta of 0.2. The minimum sample size was 43 images for each position.

RESULTS

Reliability

Table I shows the ICC for each parameter. All of the ICC values showed substantial to almost perfect agreement.

Dorsovolar translations

The dorsovolar translations were within 1.99 mm (SD : 1.36) at 90° pronation to -2.03 mm (SD : 0.98) at 90° supination (Table I, Fig. 4A). There were significant differences in the dorsovolar translations ($p < 0.05$) when the forearm rotation was changed to each measurement angle between 70° supination and 70° pronation, while there were no significant differences at $> 70^\circ$ pronation. The dorsovolar translation was not significantly different at 70° - 80° supination but was significantly different at 80° - 90° supination. Except the comparison with supination

Table I. — Summary of results about dorsovolar translations and relative angles of radius

Whole wrist angles	Dorsovolar translation					Relative angles of radius				
	Mean (mm)	SD**	ICC*			Mean (°)	SD**	ICC		
			Intraobserver reliability	Interobserver reliability				Intraobserver reliability	Interobserver reliability	
pronation 90°	1.99	1.36	.881	.970	.980	71.20	13.98	.964	.982	.948
pronation 80°	1.96	1.32	.904	.971	.986	66.22	11.77	.959	.964	.948
pronation 70°	1.88	1.22	.865	.963	.952	60.35	9.40	.944	.974	.946
pronation 60°	1.74	1.15	.924	.982	.967	51.31	9.29	.938	.978	.885
pronation 40°	1.36	0.71	.810	.872	.863	35.06	7.93	.837	.949	.913
pronation 20°	0.74	0.62	.751	.930	.925	14.89	5.30	.861	.862	.810
Supination 20°	-0.76	1.00	.808	.889	.901	-17.92	12.37	.952	.858	.819
Supination 40°	-1.10	1.09	.847	.948	.954	-29.41	14.33	.975	.971	.799
Supination 60°	-1.36	1.21	.768	.956	.931	-37.78	13.57	.968	.988	.967
Supination 70°	-1.56	1.18	.879	.935	.940	-39.59	13.18	.958	.989	.957
Supination 80°	-1.87	0.98	.814	.972	.962	-44.60	12.76	.956	.986	.953
Supination 90°	-2.03	0.98	.783	.938	.942	-46.63	14.30	.958	.989	.961

Negative value indicated a dorsal displacement in dorsovolar translation and a supinated position in relative angles. *Interclass coefficients. **Standard deviation.

and pronation 20°, there were no significant differences the dorsovolar translations when comparing the same degree of rotation in supination and pronation (Table II).

Rotation of the radius

Mean value of the rotations of the radius were 71.20° (SD : 13.98) at 90° pronation and -46.63° (SD : 14.30) at 90° supination (Table I, Fig. 4B). At each stepwise comparison of forearm rotation comparison, the rotation of the radius was significantly different compared with the previous stage ($p < 0.05$). At the same degree of rotation in supination and pronation, there were significant differences in the rotation of the radius, and larger angles were present at every pronation position compared with the supination position, except at 20° (Tables I and II, Fig. 4C).

Pearson correlation analysis

There were strong independent correlations between ROM and the dorsovolar translation ($r = 0.818$, $p < 0.001$, Fig. 5A) and rotation of the

radius ($r = 0.960$, $p < 0.001$, Fig. 5B). There was also a strong correlation between dorsovolar translation and rotation of the radius ($r = 0.861$, $p < 0.001$, Fig. 5C) (Table III).

DISCUSSION

The aim of this study was to investigate the relative differences in dorsovolar translation and rotation of the radius in the DRUJ in forearm supination and pronation. The most important finding of this study was the significant relationship between dorsovolar translation and rotation of the radius relative to the ulna ; greater pronation of the radius correlated with greater dorsal translation of the radius. Another interesting observation was that the mid-range of forearm rotation (60° supination to 60° pronation) had the largest effect on the dorsovolar translation and rotation of the radius. Only 33% and 13% of the total change in dorsovolar translation was accounted for during the late stage of forearm rotation, from 60° supination to 90° supination or 60° pronation to 90° pronation, respectively. The findings that largest changes were occurred from neutral to mid-supination and mid-pronation are

Table II. — Post-hoc pair comparison and comparison between each same degrees

Pair Comparison	p-value (Dorsovolar translation)	p-value (Relative angles of radius)
P*90°-P80°	.586	< 0.001
P80°-P70°	.558	< 0.001
P70°-P60°	.013	< 0.001
P60°-P40°	< .001	< 0.001
P40°-P20°	< .001	< 0.001
P20°-Neutral	< .001	< 0.001
Neutral - S**20°	< .001	< 0.001
S20°-S40°	< .001	< 0.001
S40°-S60°	< .001	< 0.001
S60°-S70°	.005	.001
S70°-S80°	.262	< 0.001
S80°-S90°	.012	< 0.001
P90°-S90°	.227	< 0.001
P80°-S80°	.123	< 0.001
P70°-S70°	.448	< 0.001
P60°-S60°	.601	< 0.001
P40°-S40°	.996	.022
P20°-S20°	.004	.008

*P : Pronation, **S : Supination.

similar to those of a previous study that investigated proximal-distal translation during forearm rotation (19).

The device that we used to determine the kinematics of the distal radius during pronation and supination allowed customized control of the wrist positioning to increase measurement reliability and minimize motion at the proximal joints in addition to providing more specific results, which should be considered strengths of the methodology. Furthermore, the parameters for translation and rotational alignment on the CT images showed good intraobserver and interobserver reliability. Our method to quantify translation of the DRUJ was based on the radioulnar ratio method (13), which provides consistent measurements suitable for research studies. For the present study, the center of the ulnar head was chosen as the index of displacement, as it was a clearly identifiable landmark on CT that was closest to the ulna fovea passing through the postulated axis of the DRUJ (10,16) and was the anatomical point of distal radioulnar ligament insertion (2). Despite the

need to manually locate the center of the ulnar head, the results displayed high ICC. Moreover, the present investigation involved multiple, specific wrist positions within the entire pronation and supination radius trajectory for detailed analysis of motion within a relatively large sample.

Several previous studies have described translations of the DRUJ during forearm rotation (1,17,24), generally reporting that the ulnar head slightly moves in the dorsal direction during pronation and in the volar direction during supination. Considering that these studies utilized an opposite experimental direction than the present study, their results are similar to the present results. Dorsovolar translations were significantly different in the early stages of rotation but not in the late stages, also similar to another recent study (12). One possible physiologic explanation (5) for the lack of differences in the late stages is that the corresponding distal radioulnar ligament becomes taut and restricts translation as the wrist approaches the late stages of rotation. Proximal structures such as the biceps and supinator

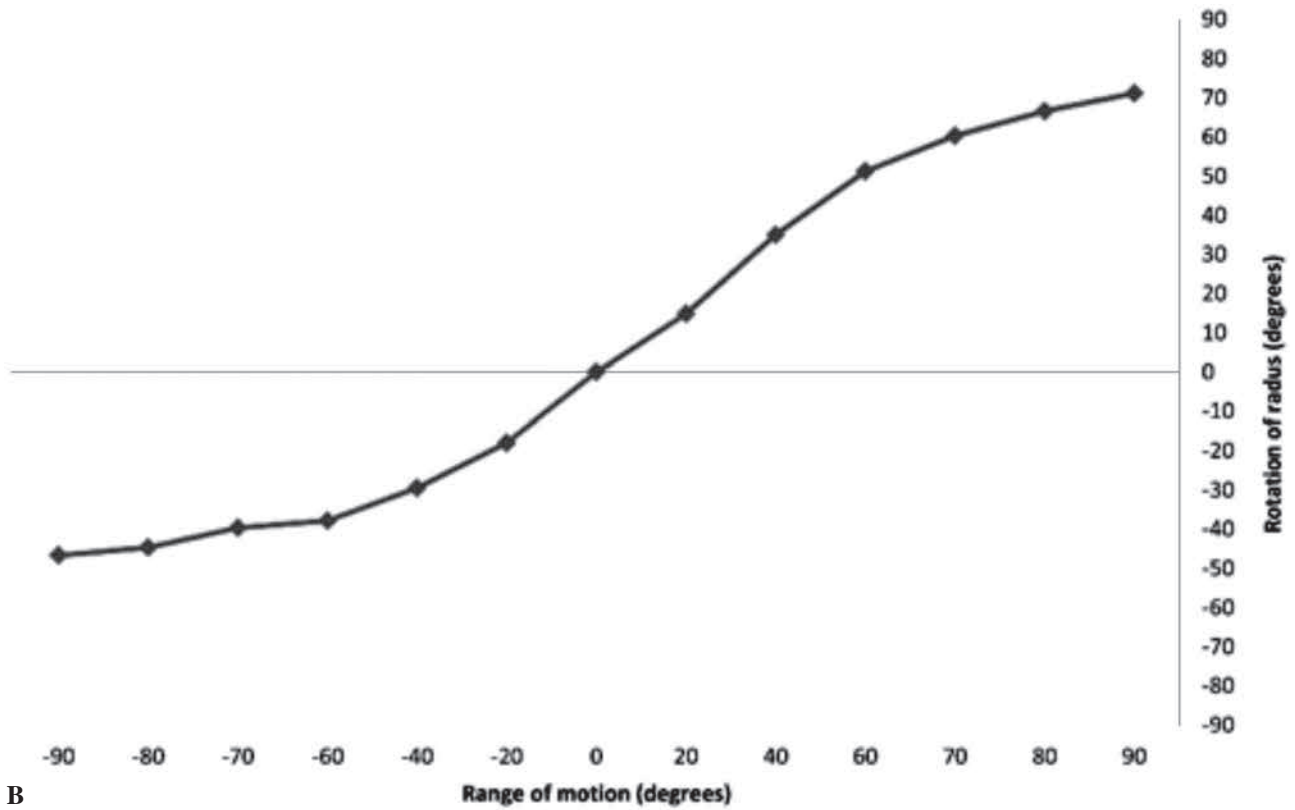
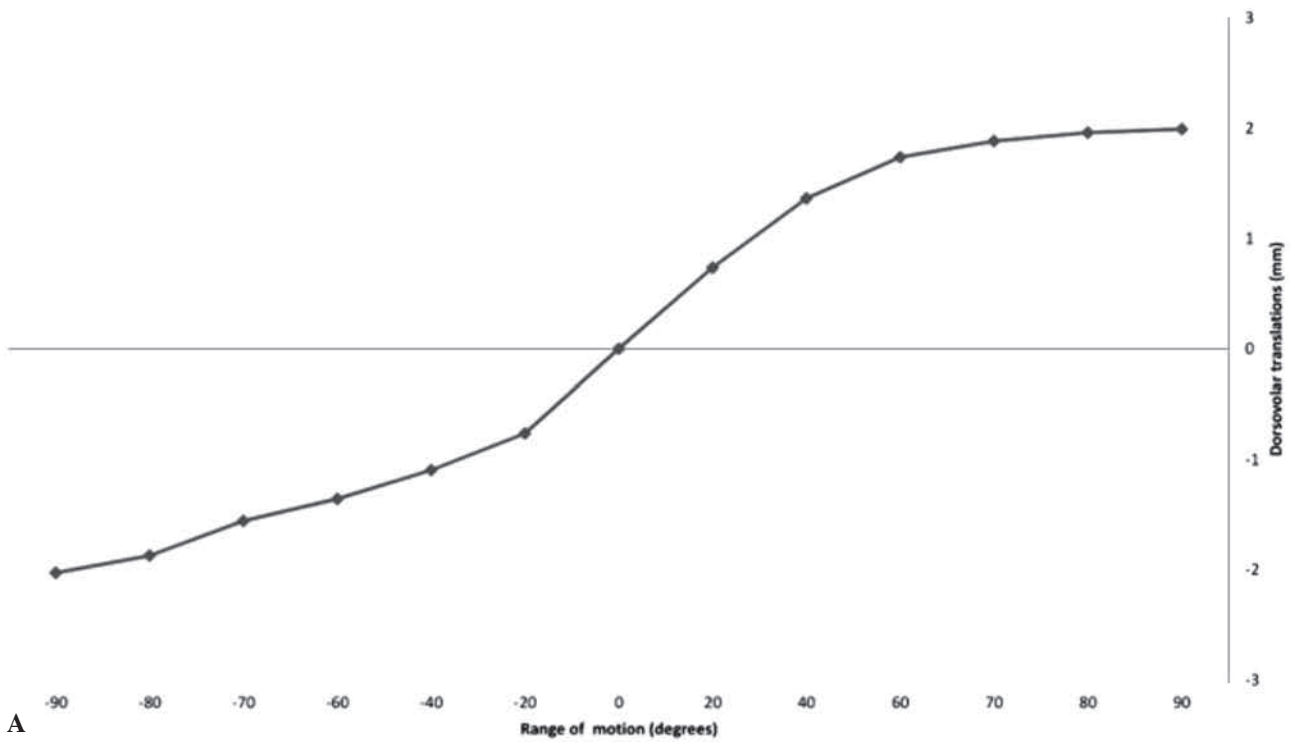


Fig. 4. — Angle analysis during forearm supination and pronation.

Differences in dorsovolar translation (A) and rotation of the radius (B) relative to the ulna during forearm supination and pronation were determined. A negative value indicates dorsal direction of the radius and a supinated position with respect to the ulna. (C) Comparison of the rotation of the radius at the same degree of rotation in the opposite direction.

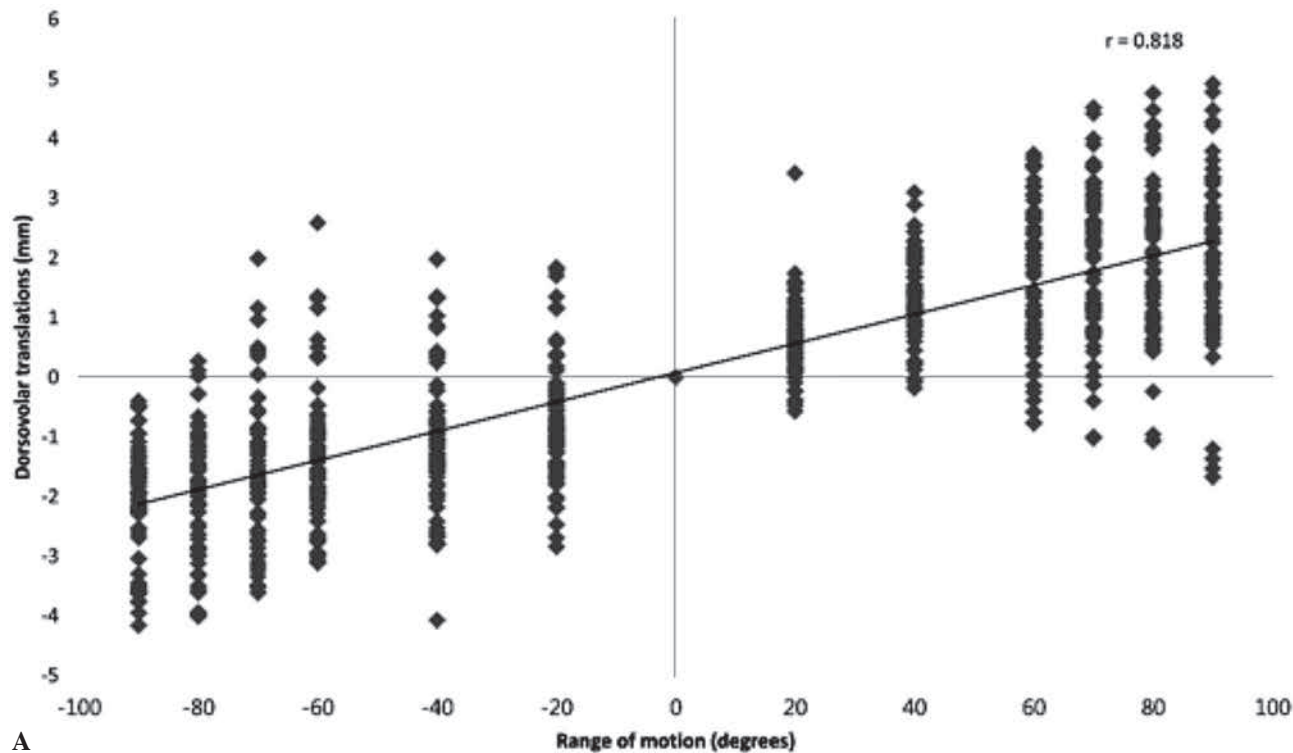
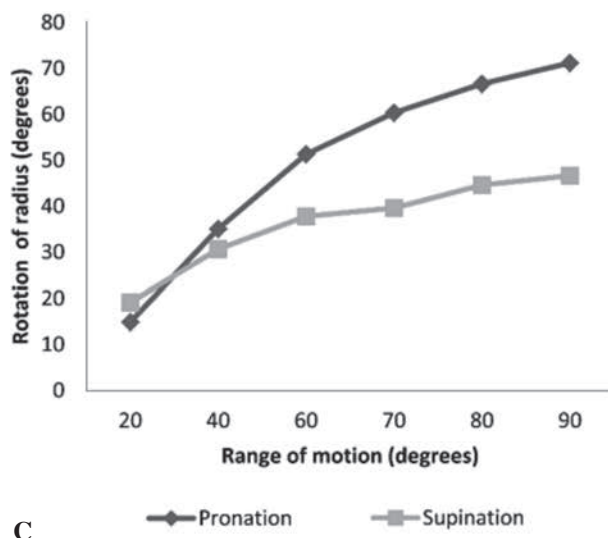
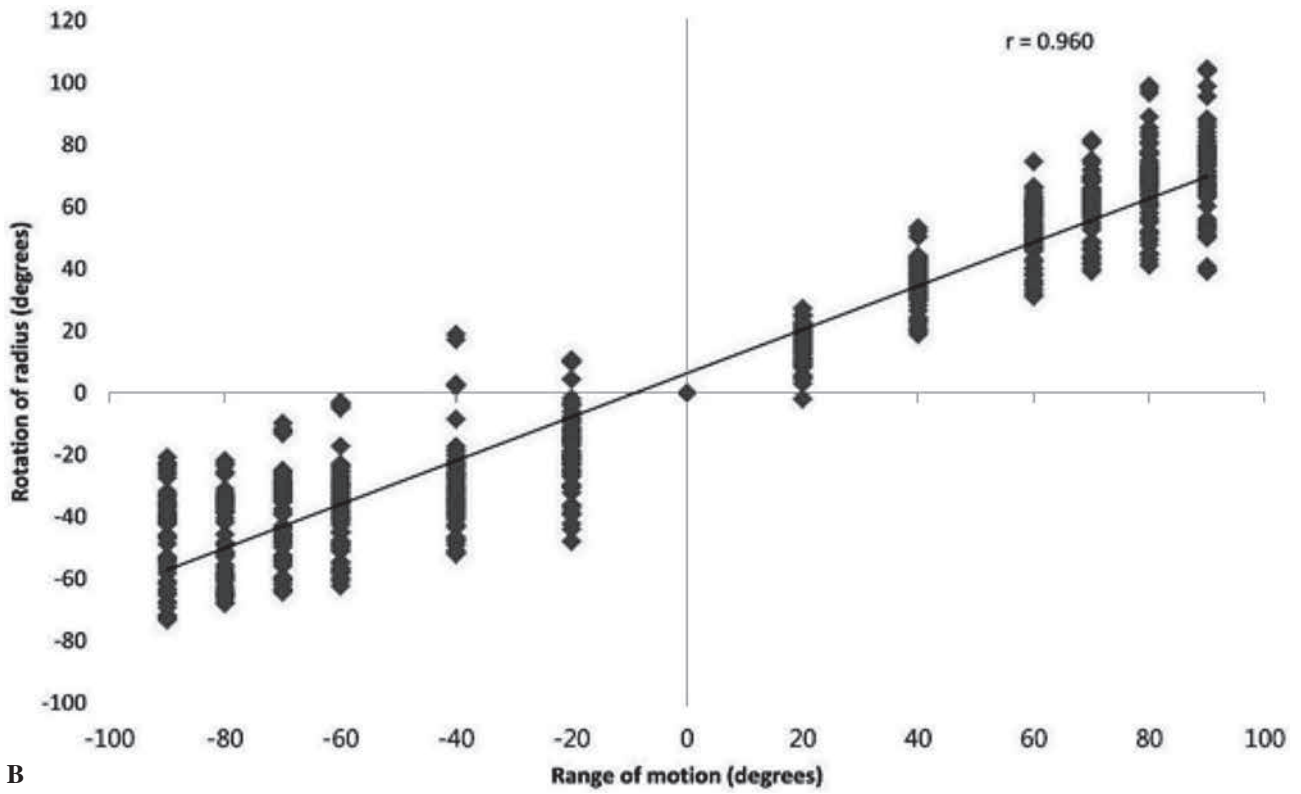
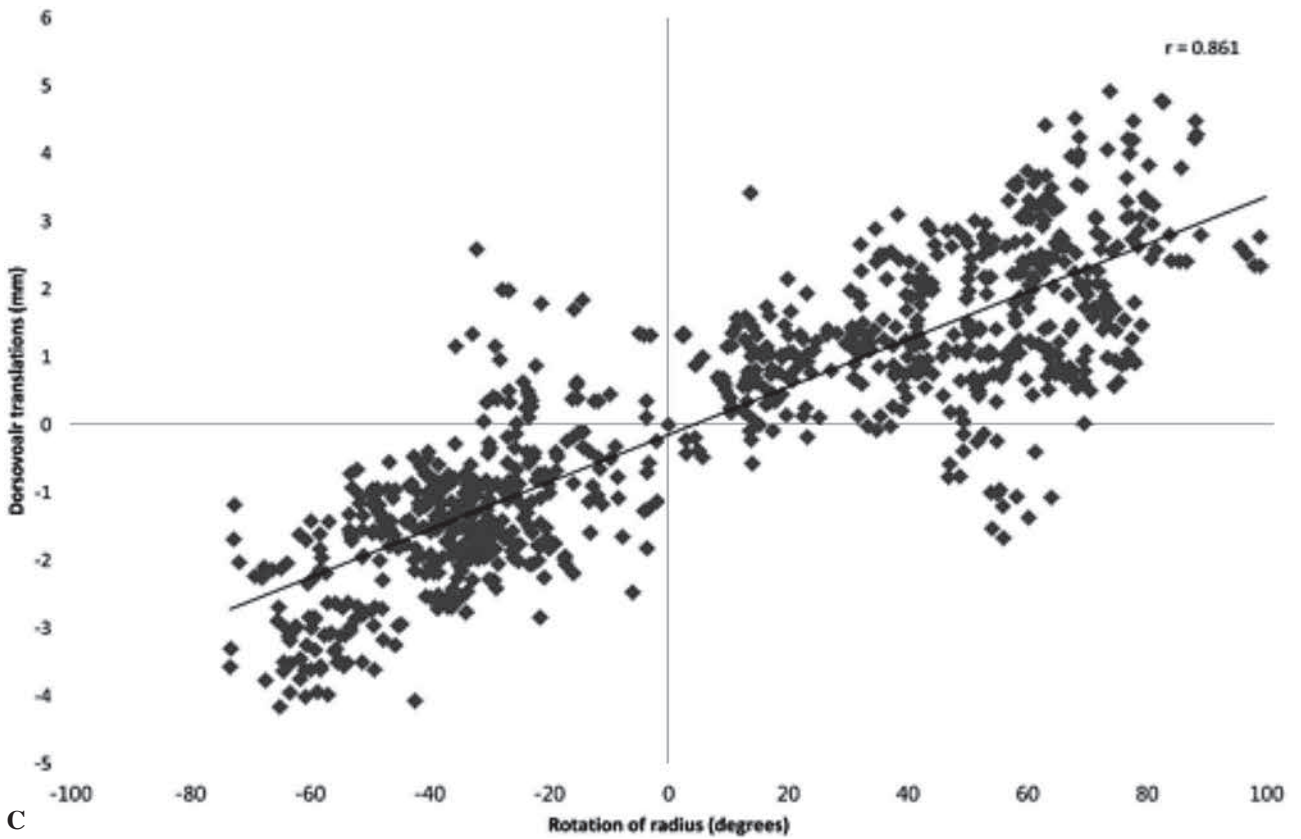


Fig. 5. — Correlation data between wrist range of motion and dorsovolar translation (A) and rotation of the radius (B) and between dorsovolar translation and rotation of the radius (C).

Strong correlations were found between wrist ROM and the dorsovolar translation ($r = 0.818$, $p < 0.001$) and rotation of radius ($r = 0.960$, $p < 0.001$). There was also a strong correlation ($r = 0.861$, $p < 0.001$) between dorsovolar translation and rotation of the radius. A negative value indicates dorsal direction of the radius and a supinated position with respect to the ulna.



B



C

Table III. — Correlations between wrist angles and each parameter

		Wrist angles	DV*	RR**
Wrist angles	r	1	.818	.960
	P value		< .001	< .001
DV*	r	.818	1	.861
	P value	< .001		< .001
RR**	r	.960	.861	1
	P value	< .001	< .001	

*Dorsovolar translations, **Relative angles of radius.

may also limit translation as the forearm approaches terminal supination. During active supination, the supinator muscle plays a more prominent role than the biceps muscle, accounting for the net displacement of the radius to ulna. However, although the total translation during rotation was similar, the previous study reported specific translations of 1.3 mm in maximal supination and 2.6 in maximal pronation, while our results were 2.03 mm in maximal supination and 1.99 mm in maximal pronation. These differences might be explained by the respective sample sizes and experimental settings ; in the previous study, poor measurement accuracy for out-of-plane translations (14) likely occurred owing to the 3D to 2D model registration technique using single-plane fluoroscopy.

More recent *in vivo* studies have used CT to determine DRUJ kinematics (1,25) because CT has been suggested as the imaging modality of choice to evaluate the DRUJ. We chose CT to delineate the cross-sectional anatomy of the DRUJ without overlapping of adjacent structures. In our setting, the wrist alignment was maintained by the customized grip goniometer to standardize the amount of rotation between subjects and to set the experimental angle as accurately as possible. Other studies have applied shear force or resistive rotational torque to DRUJ to assess the normal range of dorsovolar translation as a means of measuring DRUJ stability (15,24) ; as force was perpendicularly applied to the radius, the rotational movements of the radius in the DRUJ were minimized, with 5.26-5.5-mm total translation. The aim was different to that of the

present study, which aimed to analyze axial rotation of the normal wrist joint.

The present study measured pure rotation of the radius against the fixed ulna. The hand and the metacarpals, which normally move with the rotating radius, were held stationary with the help of the custom grip goniometer. The distal radius rotated simultaneously against the metacarpals and also the distal ulna. Our experimental settings minimized the attribution of the shoulder and elbow joints to the wrist joint. As a result, we determined wrist rotation as the sum of the rotation of the DRUJ and the carpal joint, both midcarpal and radiocarpal joint. Our data suggest that the rotation of the radius was significantly different at every stage of pronation and supination, and that pronation movements had a larger absolute value than supination, which support the findings of another recent study (12). However, the total arc of the radius (118°) in the present study was different to that previously reported : 157° (SD : 9°) (5) and 143.4° (SD : 11.7°) (12) of total rotation (maximum supination to maximum pronation) at 45° of elbow flexion, measured without a grip goniometer. The grip goniometer limited the global wrist motion from 90° pronation to 90° supination to reduce bias from the individual differences in the arc of the wrist. Gupta *et al* reported a mean carpal rotation of 17.1° in supination and 17.0° in pronation (7), and other studies (9,20) have reported mean rotations of 42° and 45° during full forearm rotation. If wrist pronation and supination are considered to only be the sum of the radioulnar and carpal joints, the results appear reasonable for prona-

tion but not supination. The capsuloligamentous structures of the wrist reportedly allow approximately 40–45° of passive carpal axial rotation independent from the wrist position (20). Recently, an *in vivo* biomechanical study showed that the carpal ligament changes were greater during forearm supination than pronation, suggesting greater carpal ligament strain during supination (4). Collectively, the results of our study and previous studies indicate that wrist pronation and supination are composed of the DRUJ, carpal joints, and rotational laxity of the carpal ligament, the latter especially in supination.

The present study has certain limitations. First, we did not consider proximal-distal translation of the radius because we could acquire only axial images. Schuind et al. demonstrated a mean change in ulnar variance of 0.5 mm during maximal grasp of a dynamometer (21), which could influence DRUJ kinematics because muscle activity or ligament tension likely differs from that of natural forearm rotation. However, we tried to maintain the consistency of grip power, requiring only minimal grip strength, which maintained stable wrist positions. Second, all of the study subjects were men, and sex comparisons could not be made. Further evaluation considering sex is required. Third, pronation and supination of the forearm occurs as a result of motion within the carpal, radioulnar, ulnohumeral, and glenohumeral joints. Our methodology minimized, but did not eliminate, motion at the proximal joints. To overcome this limitation, motion of the proximal joints was prevented using cushions, which have consistent angles: 90° flexion and neutral rotation for the glenohumeral joints and 45° flexion of the ulnohumeral joint. The subjects were given several practice trials to ensure that they understood the protocol of experiment before measurements were obtained.

In summary, the present study evaluated DRUJ at specific angles of rotation, providing a reproducible approach to quantifying DRUJ kinematics. During full forearm rotation, the dorsovolar translation was 4.01 mm, and the total rotation of radius was 118°. Translation was strongly correlated with rotation of the radius. These findings provide an understanding of wrist kinematics, are useful in reconstructive wrist surgery to achieve normal ROM, and are help-

ful for the design of DRUJ reconstruction using prostheses.

REFERENCES

1. **Baeyens JP, Van Glabbeek F, Goossens M, Gielen J, Van Roy P, Clarys JP.** In vivo 3D arthrokinematics of the proximal and distal radioulnar joints during active pronation and supination. *Clin Biomech (Bristol, Avon)* 2006 ; 21 Suppl 1 : S9-12.
2. **Berger RA.** The anatomy of the ligaments of the wrist and distal radioulnar joints. *Clin Orthop Relat Res* 2001 ; 383 : 32-40.
3. **Blankenhorn BD, Pfaeffle HJ, Tang P, Robertson D, Imbriglia J, Goitz RJ.** Carpal kinematics after proximal row carpectomy. *J Hand Surg Am* 2007 ; 32 : 37-46.
4. **Chen YR, Tang JB.** Changes in contact site of the radiocarpal joint and lengths of the carpal ligaments in forearm rotation : an in vivo study. *J Hand Surg Am* 2013 ; 38 : 712-720.
5. **Fu E, Li G, Souer JS, Lozano-Calderon S, Herndon JH, Jupiter JB, Chen NC.** Elbow position affects distal radioulnar joint kinematics. *J Hand Surg Am* 2009 ; 34 : 1261-1268.
6. **Green DP, Wolfe SW.** *Green's Operative Hand Surgery.* Saunders, Elsevier, 2011.
7. **Gupta A, Moosawi NA.** How much can carpus rotate axially ? An in vivo study. *Clin Biomech (Bristol, Avon)* 2005 ; 20 : 172-176.
8. **Hunt TR, Wiesel SW.** *Operative Techniques in Hand, Wrist, and Forearm Surgery.* Lippincott Williams & Wilkins, 2010.
9. **Kapandji AI, Martin-Bouyer Y, Verdeille S.** Three-dimensional CT study of the carpus under pronation-supination constraints. *Ann Chir Main Memb Super* 1991 ; 10 : 36-47.
10. **King GJ, McMurtry RY, Rubenstein JD, Gertzbein SD.** Kinematics of the distal radioulnar joint. *J Hand Surg Am* 1986 ; 11 : 798-804.
11. **Landis JR, Koch GG.** The measurement of observer agreement for categorical data. *Biometrics* 1977 ; 33 : 159-174.
12. **Matsuki KO, Matsuki K, Mu S, Sasho T, Nakagawa K, Ochiai N, Takahashi K, Banks SA.** In vivo 3D kinematics of normal forearms : analysis of dynamic forearm rotation. *Clin Biomech (Bristol, Avon)* 2010 ; 25 : 979-983.
13. **Lo IK, MacDermid JC, Bennett JD, Bogoch E, King GJ.** The radioulnar ratio : a new method of quantifying distal radioulnar joint subluxation. *J Hand Surg Am* 2001 ; 26 : 236-243, 2001.
14. **Moro-oka TA, Hamai S, Miura H, Shimoto T, Higaki H, Fregly BJ, Iwamoto Y, Banks SA.** Can magnetic resonance imaging-derived bone models be used for accurate motion measurement with single-plane three-

- dimensional shape registration? *J Orthop Res* 2007 ; 25 : 867-872.
15. **Nagata H, Hosny S, Giddins GE.** In-vivo measurement of distal radio-ulnar joint translation. *Hand Surg* 2013 ; 18 : 15-20.
 16. **Nakamura T, Yabe Y, Horiuchi Y, Yamazaki N.** In vivo motion analysis of forearm rotation utilizing magnetic resonance imaging. *Clin Biomech (Bristol, Avon)* 1999 ; 14 : 315-320.
 17. **Palmer AK, Werner FW.** Biomechanics of the distal radioulnar joint. *Clin Orthop Relat Res* 1984 ; 187 : 26-35.
 18. **Park MJ, Kim JP.** Reliability and normal values of various computed tomography methods for quantifying distal radioulnar joint translation. *J Bone Joint Surg Am* 2008 ; 90 : 1451-1453.
 19. **Quigley RJ, Robicheaux GW, Lee TQ.** The proximal and distal position of the radius relative to the ulna through a full range of elbow flexion and forearm rotation. *J Hand Surg Eur Vol* 2013 ; 39 : 535-540.
 20. **Ritt MJ, Stuart PR, Berglund LJ, Linscheid RL, Cooney WP, 3rd, An KN.** Rotational stability of the carpus relative to the forearm. *J Hand Surg Am* 1995 ; 20 : 305-311.
 21. **Schuind FA, Linscheid RL, An KN, Chao EY.** Changes in wrist and forearm configuration with grasp and isometric contraction of elbow flexors. *J Hand Surg Am* 1992 ; 17 : 698-703.
 22. **Schuind F, An KN, Berglund L, Rey R, Cooney WP, 3rd, Linscheid RL, Chao EY.** The distal radioulnar ligaments : a biomechanical study. *J Hand Surg Am* 1991 ; 16 : 1106-1114.
 23. **Tolat AR, Stanley JK, Trail IA.** A cadaveric study of the anatomy and stability of the distal radioulnar joint in the coronal and transverse planes. *J Hand Surg Br* 1996 ; 21 : 587-594.
 24. **Tay SC, Berger RA, Tomita K, Tan ET, Amrami KK, An KN.** In vivo three-dimensional displacement of the distal radioulnar joint during resisted forearm rotation. *J Hand Surg Am* 2007 ; 32 : 450-458.
 25. **Tay SC, van Riet R, Kazunari T, Amrami KK, An KN, Berger RA.** In-vivo kinematic analysis of forearm rotation using helical axis analysis. *Clin Biomech (Bristol, Avon)* 2010 ; 25 : 655-659.
 26. **Tay SC, van Riet R, Kazunari T, Koff MF, Amrami KK, An KN, Berger RA.** A method for in-vivo kinematic analysis of the forearm. *J Biomech* 2008 ; 41 : 56-62.
 27. **Walter SD, Eliasziw M, Donner A.** Sample size and optimal designs for reliability studies. *Stat Med* 1998 ; 17 : 101-110.