

# SHORT AMPUTATION STUMP LENGTHENING WITH THE ILIZAROV METHOD : RISKS VERSUS BENEFITS

P. MERTENS<sup>1</sup>, J. LAMMENS<sup>1</sup>

**The authors point out the indications for lengthening of short amputation stumps. Referring to their own experience they discuss the problems and pitfalls related to this surgical procedure. Sufficient soft tissue coverage is the most important factor for a good outcome whereas limitation of adjacent joint function may have a detrimental effect on the clinical result.**

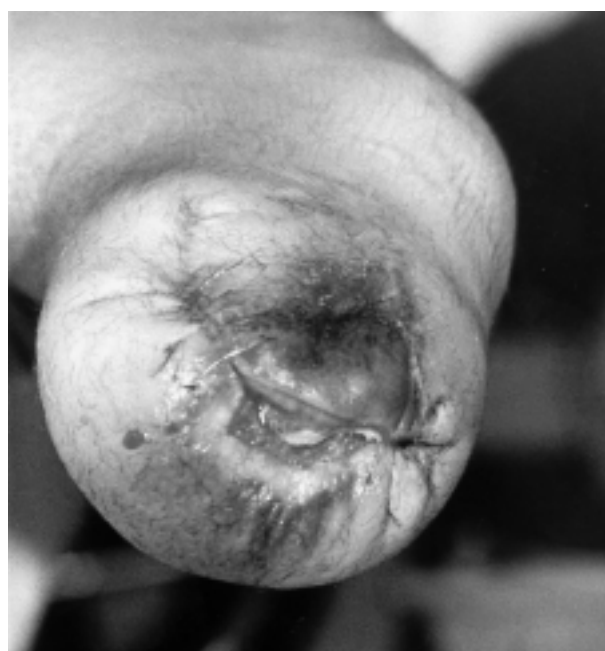**Keywords :** lower limb ; amputation ; lengthening.

**Mots-clés :** membre inférieur ; amputation ; allongement.

## INTRODUCTION

Besides vascular disease, trauma is the most common indication for amputation in patients under the age of fifty. Amputations due to traumatic lacerations have a number of unique characteristics not found in vascular disease. The site of the amputation is determined by the level of the injury. The remaining stump often has an excellent blood supply and the patient is usually young and in good general condition and is expected to regain a high level of function (9) but traumatic amputations frequently have complex deficiencies of skin and bone which may lead to proximal reamputation (3) (fig. 1). In case of an amputation of the lower limb, if the stump has sufficient length, a below-knee amputation has the best gait efficiency and prosthesis fit. If the stump is too short, a lengthening procedure may be beneficial. The Ilizarov external fixator with its ability to perform three-dimensional corrections and its minimal invasive approach to

soft tissue and bone, is often the only device usable in short amputation stump lengthening (2).



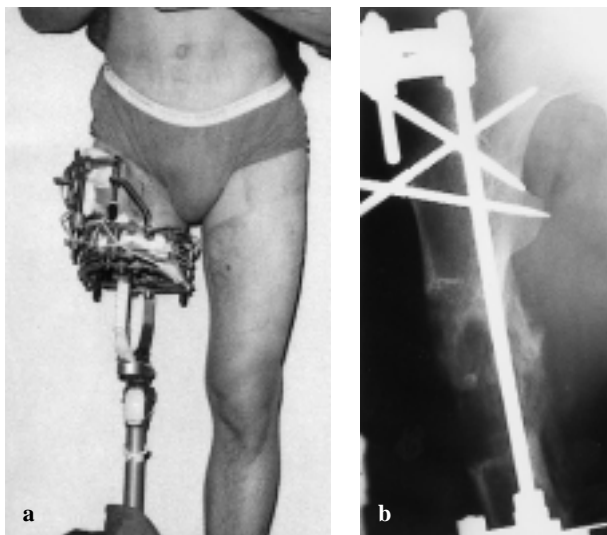
**Fig. 1.** — Recurrent infection and wound problems are the most frequent causes for reamputation, finally resulting in a very short stump.

<sup>1</sup> Department of Orthopaedic Surgery, Catholic University Leuven, University Hospital Pellenberg, Weligerveld 1, B-3212 Lubbeek (Pellenberg), Belgium.

Correspondence and reprints : J. Lammens, Department of Orthopaedic Surgery, U.Z. Pellenberg, Weligerveld 1, B-3212 Lubbeek (Pellenberg), Belgium.

## MATERIAL AND METHODS

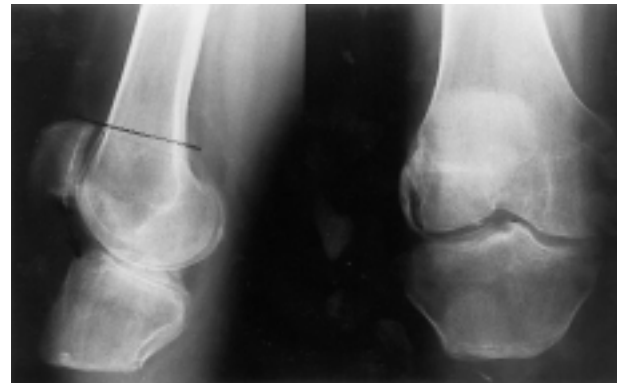Three patients with insufficient lower limb stumps after traumatic amputations were treated in our department. Two of them had a short tibial stump, 4 and 6 centimeters long respectively. The third one had a 9-centimeter femoral stump. In all three an Ilizarov procedure with distraction osteogenesis was performed using two full rings (one proximal and one distal) for the tibia and two full rings plus a semicircular arch for the femur (6, 7, 8). Lengthening was always started at 7 days post-operatively, at a pace of one mm/day. A temporary prosthesis was fitted on the external fixator allowing weightbearing (fig. 2).



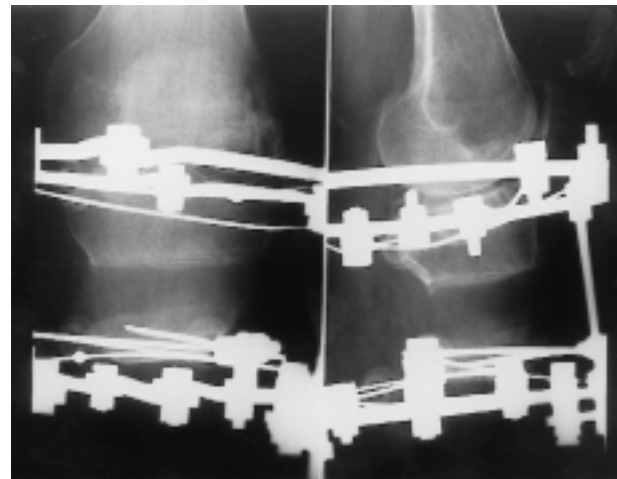
**Fig. 2.** — Femoral stump lengthening.  
*a.* Clinical picture with temporary prosthesis fixed to the Ilizarov frame.  
*b.* Radiograph during the lengthening.

## RESULTS

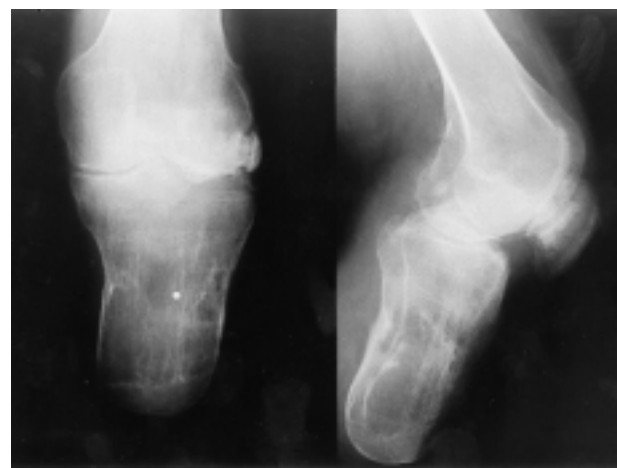All patients had temporary signs of pin tract infections. Moreover two patients needed reoperation both for pin problems and premature fusion, probably because the primary corticotomy was done too cautiously for fear of extending it towards the adjacent joint. The mean length gain was 7 cm (6.5, 7 and 7.5 cm respectively) but the consolidation time was very long (healing index 1.6 month/centimeter) (fig. 3). The final outcome was excellent in two cases (one femoral and one



**a**

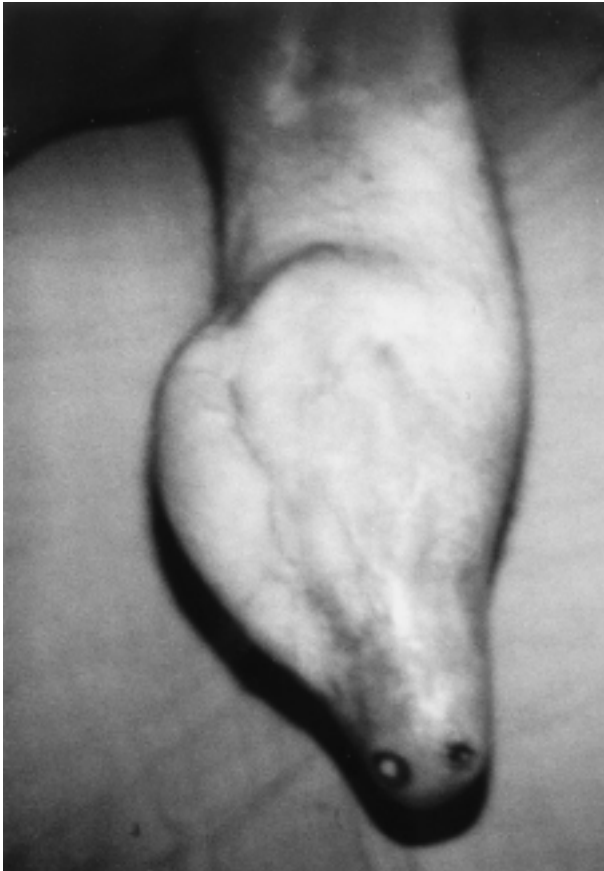

**b**



**c**

**Fig. 3.** — Example of tibial stump lengthening preoperative (a), during lengthening (b) and after removal of fixator (c).



**Fig. 4.** — Wrong indication for tibial stump lengthening : insufficient soft tissue coverage with ulceration, finally necessitating knee desarticulation.

tibial lengthening) but was unsatisfactory in one tibial lengthening due to knee stiffness, repetitive skin breakdown and ulcerations, finally requiring knee desarticulation (fig. 4).

### DISCUSSION

For efficient prosthetic use after amputation, three factors are of paramount importance. First of all the patient must have sufficient power to perform the gait cycle. It is obvious that a longer stump allows a better cantilever function in lifting the prosthesis, requiring less energy. Moreover, a longer amputation stump allows the use of a patella-tendon-bearing suction prosthesis instead of a thigh-bearing prosthesis in case of below-knee amputation, providing better skin protection and a

more efficient gait, while in above-knee amputation an above-knee prosthesis can be used instead of a pelvic walker (3). Secondly there must be a sufficient stump surface area to transmit force without skin breakdown. Thirdly, the patient must have the necessary range of motion because even an optimal length is of no benefit in case of adjacent joint stiffness (3).

In the literature, many promising results for stump lengthening with the Ilizarov frame have been published. Latimer *et al.* and Eldridge *et al.* described four cases of below-knee amputation successfully lengthened with excellent functional outcome (3, 9). An above knee amputation stump lengthening was described by Horesh *et al.* (5) resulting in a better and more stable prosthetic fitting. In the upper limb the use of the Ilizarov frame for amputation stumps has also been reported. Stricker reported a below-elbow stump lengthening with the Ilizarov method and was able to convert the functional level of the patient's amputation from elbow disarticulation to below-elbow status (11). Congenital amputations below the elbow have also been successfully lengthened (1, 10).

Although several excellent results have been described, there are some important limiting factors. Even with an optimal blood supply and a sufficient soft tissue coverage, stump infection is always possible as reported both by Eldridge *et al.* and Horesh *et al.* (3, 5). These infections are not due to direct wound infection at the time of corticotomy but appear as a result of insufficient skin and soft tissue coverage with ulceration and finally bone perforation.

Therefore the main area of concern in amputation stump lengthening is the soft tissue. To prevent these skin problems resulting in new debridements and reamputation, skin and soft tissue should be in optimal condition prior to any lengthening. To this purpose tissue expanders may be used to produce a pocket for bone growth, or vascularized myocutaneous flaps (3). Good outcome in lengthening of congenital amputations as reported by Alekberov *et al.* (1) and the problem free lengthening of a below-elbow stump could be explained by the excellent soft tissue conditions in these patients (3, 10). Good results were also reported in posttraumatic

upper limb stump lengthening as in the case described by Stricker (11). This could be explained by the excellent soft tissue vascularity inherent to the upper limb, maintenance of full elbow motion and bunching up of local mobile skin as distally as possible during pin insertion.

A second important obstacle can be the range of motion of adjacent joints. During lengthening procedures a loss of mobility due to muscle contracture is not uncommon ; it has been reported in one out of five patients in one series (4). Intensive active and passive mobilisation, if necessary combined with splinting is necessary to avoid the development of muscle contracture and to prevent any loss of knee extension or flexion (4, 11). The one patient with an unfavourable outcome in our group had, besides his soft tissue problems, a limited knee function, and this was one of the contributing factors which lead to the final knee desarticulation.

A third problem is the long treatment time. It should be kept in mind that these heavily lacerated limbs, if not amputated immediately, have often undergone several operative procedures, eventually ending in amputation and sometimes in reamputation in case of soft tissue problems or infection. This interference with the local biology, occasionally combined with other problems such as smoking, can result in a very long remodelling time, with social and psychological impact (5). Even though premature consolidation at the start of the lengthening period was seen in two cases, this was not beneficial for the final total healing time. The healing index was still 1.6 month per centimeter.

### CONCLUSION

The Ilizarov method is a reliable method for the correction of severely deformed limbs. The technique of distraction osteogenesis can also be used to improve the quality of life of patients with short amputation stumps by giving them a better mechanical stump that is more effective for prosthetic use, and for the function of the adjacent joint (1, 3, 5, 9, 11). However the treatment can be very demanding both for the patient and for the orthopaedic surgeon. The main area of concern is the quality of the soft tissues. Prior to any length-

ening it is necessary to have redundant soft tissue coverage. If no sufficient skin cover is available a soft tissue reconstruction should be considered to prevent complications with poor final outcome (4). Lengthening of short amputation stumps certainly is not a routine procedure that may be addressed with unconsidered enthusiasm.

### REFERENCES

1. Alekberov C., Karatosun V., Baran O., Gunal I. Lengthening of congenital below-elbow amputation stumps by the Ilizarov technique. *J. Bone Joint Surg.*, 2000, 82-B, 239-241.
2. Aronson J. Limb-lengthening, skeletal reconstruction and bone transport with the Ilizarov method. *J. Bone Joint Surg.*, 1997, 79-A, 1243-1258.
3. Eldridge J., Armstrong P., Krajbich I. Amputation stump lengthening with the Ilizarov technique. *Clin. Orthop.*, 1990, 256, 76-79.
4. Garcia-Cimbrello E., Olsen B., Ruiz-Yague M., Fernandez-Baillo N., Munuera-Martinez L. Ilizarov technique. Results and difficulties. *Clin. Orthop.*, 1992, 283, 116-123.
5. Horesh Z., Levy M., Stein H. Lengthening of an above-knee amputation stump with the Ilizarov technique - a case report. *Acta Orthop. Scand.*, 1998, 69, 322-328.
6. Ilizarov G. A. The principles of the Ilizarov method. *Bull. Hosp. Joint Dis.*, 1988, 48, 1.
7. Ilizarov G. A. Clinical application of the tension stress effect for limb lengthening. *Clin. Orthop.*, 1990, 250, 8-26.
8. Ilizarov G. A. The tension-stress effect on the genesis and growth of tissues Part 1. The influence of stability of fixation and soft tissue preservation. *Clin. Orthop.*, 1989, 238, 249-281.
9. Latimer A.H., Dahnert L., Bynum D. Lengthening of below-the-knee amputation stumps using the Ilizarov technique. *J. Orthop. Trauma*, 1990, 4, 411-414.
10. Seitz W. H. Distraction osteogenesis of a congenital amputation of the elbow. *J. Hand Surg.*, 1985, 14-A, 945-948.
11. Stricker S. Ilizarov lengthening of a posttraumatic below elbow amputation stump. A case report. *Clin. Orthop.*, 1994, 306, 124-127.

### SAMENVATTING

*P. MERTENS, J. LAMMENS. Korte amputatiestomp verlenging met Ilizarov methode : voor- en nadelen.*

De auteurs gaan de indicaties na voor verlenging van korte amputatiestompen.

Gebaseerd op hun eigen ervaring bespreken ze de problemen en moeilijkheden bij deze chirurgische techniek.

Een voldoende weke delen bedekking is de belangrijkste factor voor een goed resultaat. Een beperkte functie van het naburige gewricht kan een compromiterende factor zijn voor het uiteindelijke resultaat.

### RÉSUMÉ

*P. MERTENS, J. LAMMENS. Allongement d'un moignon d'amputation court par la méthode d'Ilizarov : avantages et inconvénients.*

Les auteurs examinent les indications d'allongement d'un moignon d'amputation trop court. Ils discutent sur base d'une expérience personnelle les problèmes et les difficultés d'une telle technique chirurgicale.

Une couverture suffisante de tissus mous est le facteur le plus important pour un bon résultat, mais une limitation de la mobilité de l'articulation adjacente hypothèque aussi le pronostic.