



The effect of the intercondylar notch width index on anterior cruciate ligament injuries : A study on groups with unilateral and bilateral ACL injury

Cemile Ayşe GÖRMELİ, Gökay GÖRMELİ, Burak Yağmur ÖZTÜRK, Zeynep ÖZDEMİR, Ayşegül Sağır KAHRAMAN, Okan YILDIRIM, Harika GÖZÜKARA

From Department of Radiology, Medical Faculty of Inonu University, Malatya, Turkey

Background : To evaluate the relationship of the intercondylar notch width with unilateral and bilateral ACL injury by using MR images.

Materials and Methods : The intercondylar notch width index was measured on the MR images of 18 patients with a bilateral ACL injury, 38 patients with a unilateral ACL injury and 53 healthy subjects with a normal ACL and the results of all groups were compared with each other.

Results : The mean NWI values were 0,227 (\pm 0.008) in bilateral injured ; 0,245 (\pm 0.009) in unilateral injured and 0,272 (\pm 0.01) in control groups and 0,251(\pm 0.01) in unaffected side of the unilateral group. There were statistically significant differences in intercondylar notch width index (NWI) values between all groups and there was a significant difference between the affected and the unaffected sides in group with unilateral ACL injury. A cutoff value of 0.25 for NWI gave an odds ratio of 26.5 for bilateral and 3.23 for unilateral ACL injuries.

Conclusions : The finding that NWI is significantly narrowed in patients with bilateral and unilateral ACL tears compared with the healthy controls suggest a relationship between a narrow NWI and an increased risk of ACL injury. The patients with a narrow NWI should also be screened contralaterally for assessment of ACL injury risk on the other knee. So, specialized training programmes for the people with narrow NWI can be prepared for preventing ACL injuries.

Keywords : knee ; ACL ; anatomy.

INTRODUCTION

Anterior cruciate ligament (ACL) injury is the most common ligament injury of the knee and commonly occurs during sports activities (12). The most common injury pattern is the exertion of varus and internal rotation force on the tibia during knee hyperextension. A detailed history, thorough physical examination (Lachman, anterior drawer and pivot shift tests) and imaging modalities (Magnetic Resonance Imaging) are important steps in diagnosis of ACL injuries.

■ Cemile Ayşe Görmeli.

■ Zeynep Özdemir.

■ Ayşegül Sağır Kahraman.

■ Okan Yıldırım.

Department of Radiology, Medical Faculty of Inonu University, Malatya, Turkey.

■ Gökay Görmeli.

Department of Orthopedic and Trauma Surgery, Medical Faculty of Inonu University, Malatya, Turkey.

■ Burak Yağmur Öztürk.

Department of Orthopedic and Trauma Surgery, Nigde State Hospital, Niğde, Turkey.

■ Harika Gözükara.

Department of Biostatistics, Medical Faculty of Inonu University, Malatya, Turkey.

Correspondence : Cemile Ayşe Görmeli, Department of Radiology, Medical Faculty of Inonu University, Malatya, Turkey. E-mail : ayseyazici@yahoo.com

© 2015, Acta Orthopædica Belgica.

Taking problems such as the treatment cost after ACL injuries, chronic complications like recurrent instability and osteoarthritis, and prolonged periods of return to work following the injury, particularly in athletes, into account, it is important to define the possible predictive factors in preventing ACL injuries (5). Several radiographic parameters such as the posterior tibial slope angle, patellar tendon-tibia shaft angle, ACL elevation angle and intercondylar notch width have been described in the literature in an attempt to define radiological risk factors associated with ACL injury (9). Controversy still exists on the role of intercondylar notch width as some studies advocate a possible relationship between a narrow intercondylar notch width and the risk of ACL injury while the rest suggest that there is no relationship between these two (2).

The purpose of this study was to evaluate the relationship of the intercondylar notch width with unilateral and bilateral ACL injury by using MR images. We hypothesized that there would be a significant relationship between a narrow intercondylar notch width and ACL injury in our patient group.

MATERIALS AND METHODS

This study was approved and performed in accordance with the guidelines of the institutional review board in our hospital. This was a retrospective review of 56 patients diagnosed with traumatic ACL injury. The inclusion criteria were defined as ; (1) the presence of ACL injury and (2) skeletal maturity (age ≥ 18 years). All patients underwent MRI and the diagnosis of ACL tears were confirmed during arthroscopy. Eighteen of these patients also had an accompanying contralateral ACL injury. The patients were excluded from the study if they were skeletally immature (age ≤ 18 years), had a concomitant ligament injury (MCL, PCL or LCL) or had a prior knee surgery. Eighteen patients with a bilateral ACL injury constituted Group I, while 38 patients with a unilateral ACL injury formed Group II. Fifty-three skeletally mature patients without any ligament injury or a history of knee surgery, who had no evidence of osteoarthritis or lower extremity malalignment on radiographic evaluation, were included as the control group (Group III).

All patients had MRI of the knee. The MRI scans were performed supine with the knee extended. The examina-

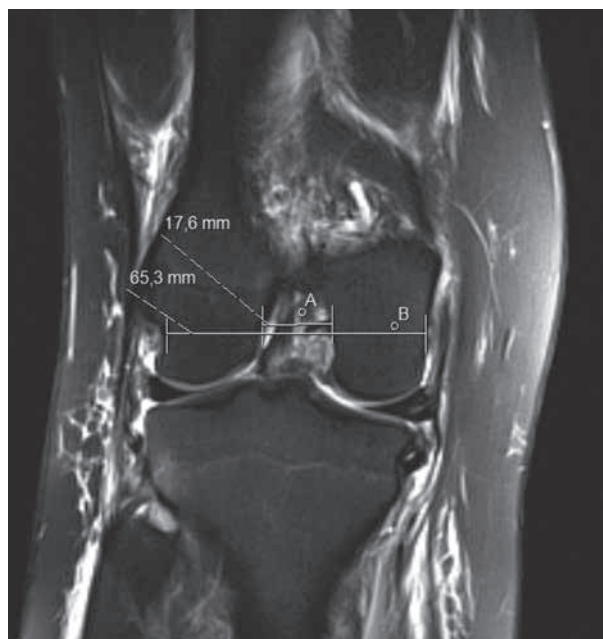

Fig. 1. — NWI is the ratio of the intercondylar notch to the width of the distal femur at the level of the popliteal groove.

tions were performed on GE SIGMA Excite HD 1.5 T (GE Health, Milwaukee, USA) using a quad coil. Axial proton density (PD) weighted, sagittal T1 and T2 weighted and coronal T2 weighted images were taken with 4 millimeters slice thickness to evaluate the extent and confirm the diagnosis of ACL injury.

Notch width (NW) measurements were calculated according to the method reported by Souryal and colleagues (5). The Notch Width Index (NWI) is the ratio of the width of intercondylar notch to the width of distal femoral condyles at the level of the popliteal groove (Fig. 1). The images were evaluated by an experienced radiologist blinded to the information regarding the patient age, gender, history, symptomatology and injury. Two measurements were made for each patient and the average values of these measurements were used for statistical purposes.

Statistical analysis was performed with SPSS 13.0 (SPSS Inc, Chicago, IL, USA). The results between the groups were compared by using one-way ANOVA test. The comparison between the affected and the unaffected side of the patients in group 2 were made by using unpaired-t test. To determine the cutoff value indicating a high risk for ACL injuries receiver operating characteristic (ROC) curves were prepared from the measured data of MRI. The odds ratio was calculated based on cross

Table I. — Demographic comparison of control and study groups

Number of cases	Injured group (n)	Non-injured group (n)	P value
Age (years)	29.9 ± 9.3	31.02 ± 7.9	0.418
Gender			
Female	15	22	0.074
Male	71	53	
Side			
Right	42	46	0.955
Left	27	29	

Statistical significance: $p < 0.05$.

tabulation using the cutoff value. A two-tailed p value < 0.05 was considered to be statistically significant.

RESULTS

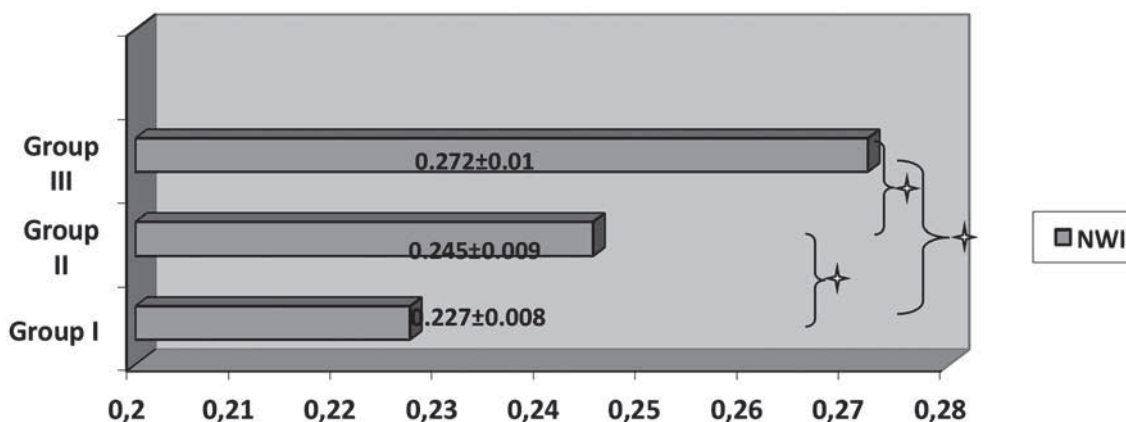
The study population included 109 patients with a mean age of $26,8 \pm 5,8$. Group I (bilateral ACL injury) included 18 patients while group II (unilateral ACL injury) included 38 patients and group III (non-injured) consisted of 53 patients. There is no significant difference between injured (group I and II) and non-injured (group III) group's gender, age and affected side (Table I).

The mean NWI values were $0,227(\pm 0.008)$ in group I; $0,245 (\pm 0.009)$ in group II and $0,272 (\pm 0.01)$ in group III (Table I). There were statisti-

cally significant differences in NWI values between all groups ($p < 0.05$) (Fig. 2).

The mean NWI of the affected side in group II was $0,251(\pm 0.01)$. There was a significant difference between the affected and the unaffected sides in group II ($p < 0.05$).

ROC curves were prepared from NWI data to determine a cutoff value. A NWI of 0.25 gave sensitivities and specificities of 0.94 (%94), 0.88 (%88) for group 1 and ; 0.61 (%61), 0.95 (%95) for group 2. NWI cutoff value was set at 0.25 based on these results. Using a NWI of 0.25 cutoff value gave odds ratio for developing bilateral ACL injuries of 26.5 (95% CI : 6.71-104.95) and 3.23 (95% CI : 2.23-4.68) respectively. These results show that subjects with a ≤ 0.25 NWI have a risk of developing



◇ $p < 0.005$.

Fig. 2. — NWI obtained from T2 weighted coronal MR images

bilateral ACL injury 26.5 times and unilateral ACL injury 3.23 times higher than for subjects with a > 0.25 NWI.

DISCUSSION

Determining the risk factors for ACL injury is an important step in preventing these injuries. Training programs individually tailored by taking these risk factors into account may help decrease the ACL injury rates in the athletes. The factors such as lower extremity malalignment, posterior tibial slope, intrinsic ACL material properties, patellar tendon-tibia shaft angle, ACL elevation angle, hormonal variation, neuromuscular control related biomechanical factors and intercondylar notch size have been suggested as possible intrinsic risk factors for ACL injury in the literature (7).

There exist several studies which investigated the relationship between a narrow intercondylar notch width (NW) and the risk of ACL injury. In 1938, Palmer *et al* first suggested that a narrow NW is associated with an increased risk of ACL injury (14). Later in 1988, Souryal *et al* reported a significant relationship between bilateral ACL tears and a narrow NW in a study using direct radiographs. The authors also described the concept of notch width index (NWI) and suggested its use in preventing ACL injuries (21). In a study on 46 patients with ACL tears, a significant decrease in NWI was found in patients with ACL tears compared to the control group (8). Sonnery-Cotet *et al* proposed that a narrow NWI is an individual risk factor for ACL injury (19). Similarly, LaPrade *et al* concluded that athletes with intercondylar notch stenosis appear to be at increased risk for noncontact anterior cruciate ligament injuries (13). Chung *et al* suggested that the small notch width can be regarded as an anatomic intrinsic risk factor for ACL injuries (6). On the other hand, there is scarce information in the literature regarding the relationship between the narrow NWI and bilateral ACL injuries. In a comparative cohort study with 25 bilateral and 30 unilateral ACL injured knees, the mean NWI was found significantly different between bilateral and healthy groups. The authors also noted a significant difference between bilateral and unilateral groups (11).

Contradictory to the above, the results of several studies deny a significant relationship between a narrow NWI and the risk of ACL injury. In a study on athletes with chronic ACL tears and a healthy control group, Herzog *et al* measured NWI with direct radiographs and MRI. They found no significant relationship between NWI and ACL injury (10). Schinkendantz *et al* calculated NWI on routine notch view radiographs of 31 knees of patients with bilateral, 30 with unilateral injury, and 30 with no ACL injury. They found no significant differences between patients with unilateral or bilateral complete ruptures of the anterior cruciate ligament and concluded that intercondylar notch measurements made from radiographs may not be reliable predictors of ACL injury (17). Alizadeh *et al* found no significant difference in the mean NWI between ACL injured and non-injured groups (1).

Controversy still exists about the imaging modality that should be routinely used in the measurement of NW. Shellbourne *et al* found a correlation between the preoperative radiographic NW measurements and intraoperative measurements (18). Other authors concluded that MRI measurements of intercondylar notch width are more accurate than measurements on plain radiographs (11,10). Although inexpensive and practical, conventional radiographs may not always yield accurate and standardized measurement results due to the variability in patient positioning and compliance, experience of the radiology technician and technical aspects. Because of this reason, we preferred to utilize routine coronal MR images for measurements in this study (3).

We acknowledge that our study has some limitations. This study was conducted on a local population within a certain geographical location and this decreases variability and generalizability of the results. Apart from the narrow NW, several other factors that may possibly have an effect on ACL injury, such as the age, hormonal factors and activity profile (2,16,15) were not taken into account. These factors should ideally be accounted for to accurately determine the relationship between the NW measurements and the ACL injury. Another shortcoming of our study is the lack of a comparison between the width or orientation of ACL and NWI. The results of a recent study showed the notch

morphology has a significant influence on ACL tears, however found no significant relationship between a narrow NW and ACL injury (4). In this study, we could not determine the influence of notch morphology on ACL tears because an evaluation of the notch morphology was not carried out. Further studies focused on this subject are needed to clarify our view on this matter.

CONCLUSION

Our findings of MRI measurements showing that NWI is significantly narrowed in patients with bilateral and unilateral ACL tears compared with the healthy controls suggest that a narrow NWI is associated with an increased risk of ACL injury. The patients with a narrow NWI should also be screened contralaterally to prevent ACL injuries on the other knee. So, specialized training programmes for the people with narrow NWI can be prepared for preventing ACL injuries.

REFERENCES

1. **Alizadeh A, Kiavash V.** Mean intercondylar Notch Width Index in cases with and without anterior cruciate ligament tears. *Iran J Radiol* 2008 ; 5 : 205-8.
2. **Anderson AF, Dome DC, Gautam S, Awh MH, Rennert GW.** Correlation of anthropometric measurements, strength, anterior cruciate ligament size, and intercondylar notch characteristics to sex differences in anterior cruciate ligament tear rates. *Am J Sports Med* 2001 ; 29 : 58-66.
3. **Anderson AF, Lipscomb AB, Liudahl KJ, Addlestone RB.** Analysis of the intercondylar notch by computed tomography. *Am J Sports Med* 1987 ; 15 : 547-52.
4. **Al-Saeed O, Brown M, Athyal R, Sheikh M.** Association of femoral intercondylar notch morphology, width index and the risk of anterior cruciate ligament injury. *Knee Surg Sports Traumatol Arthrosc* 2013 ; 21 : 678-82.
5. **Boden BP, Sheehan FT, Torg JS, Hewitt TE.** Non-contact anterior cruciate ligament injuries : mechanisms and risk factors. *J Am Acad Orthop Surg* 2010 ; 18 : 520-527.
6. **Chung SC, Chan WL, Wong SH.** Lower limb alignment in anterior cruciate ligament-deficient versus -intact knees. *J Orthop Surg (Hong Kong)* 2011 ; 19 : 303-8.
7. **Dai B, Herman D, Liu H, Garrett WE, Yu B.** Prevention of ACL injury, part I : injury characteristics, risk factors, and loading mechanism. *Res Sports Med* 2012 ; 20 : 180-97.
8. **Domzalski M, Grzelak P, Gabos P.** Risk factors for Anterior Cruciate Ligament injury in skeletally immature patients : analysis of intercondylar notch width using Magnetic Resonance Imaging. *Int Orthop* 2010 ; 34 : 703-7.
9. **Griffin LY, Albohm MJ, Arendt EA et al.** Understanding and preventing noncontact anterior cruciate ligament injuries : a review of the Hunt Valley II meeting. *Am J Sports Med* 2006 ; 34 : 1512-1523.
10. **Herzog RJ, Silliman JF, Hutton K et al.** Measurements of the intercondylar notch by plain film radiography and magnetic resonance imaging. *Am J Sports Med* 1994 ; 22 : 204-10.
11. **Hoteya K, Kato Y, Motojima S et al.** Association between intercondylar notch narrowing and bilateral anterior cruciate ligament injuries in athletes. *Arch Orthop Trauma Surg* 2011 ; 131 : 371-6.
12. **Johnson RJ.** The anterior cruciate ligament problem. *Clin Orthop Relat Res* 1983 ; 172 : 14-8.
13. **LaPrade RF, Burnett QM.** Femoral intercondylar notch stenosis and correlation to anterior cruciate ligament injuries. A prospective study. *Am J Sports Med* 1994 ; 22 : 198-202.
14. **Palmer I.** On the injuries to the ligaments of the knee joint : a clinical study. 1938. *Clin Orthop Relat Res* 2007 ; 454 : 17-22 discussion 14.
15. **Quatman CE, Ford KR, Myer GD, Paterno MV, Hewett TE.** The effects of gender and pubertal status on generalized joint laxity in young athletes. *J Sci Med Sport* 2008 ; 11 : 257
16. **Salmon L, Russell V, Musgrove T, Pinczewski L, Refshauge K.** Incidence and risk factors for graft rupture and contralateral rupture after anterior cruciate ligament reconstruction. *Arthroscopy* 2005 ; 21 : 948-57.
17. **Schickendantz MS, Weiker GG.** The predictive value of radiographs in the evaluation of unilateral and bilateral anterior cruciate ligament injuries. *Am J Sports Med* 1993 ; 21 : 110-3.
18. **Shelbourne KD, Facibene WA, Hunt JJ.** Radiographic and intraoperative intercondylar notch width measurements in men and women with unilateral and bilateral anterior cruciate ligament tears. *Knee Surg Sports Traumatol Arthrosc* 1997 ; 5 : 229-33.
19. **Sonnery-Cottet B, Archbold P, Cucurulo T et al.** The influence of the tibial slope and the size of the intercondylar notch on rupture of the anterior cruciate ligament. *J Bone Joint Surg Br* 2011 ; 93 : 1475-8.
20. **Souryal TO, Freeman TR.** Intercondylar notch size and anterior cruciate ligament injuries in athletes : a prospective study. *Am J Sports Med* 1993 ; 21 : 535-539.
21. **Souryal TO, Moore HA, Evans JP.** Bilaterality in anterior cruciate ligament injuries : associated intercondylar notch stenosis. *Am J Sports Med* 1988 ; 16 : 449-54.