



Valgus instability as a cause for recurrent lateral patellar dislocation : A new mechanism for patellofemoral instability ?

Kristof HERMANS, Steven CLAES, Johan BELLEMANS

From the University Hospital Pellenberg (K.U.L.), Lubbeek, Belgium

An association between lateral patellar dislocation (LPD) and medial collateral ligament injury (MCL) has recently been demonstrated on MRI. The same valgus injury that disrupts the femoral MCL insertion can also cause a simultaneous MPFL tear at its femoral insertion, due to the close anatomical relationship of both ligamentous structures. Valgus laxity due to MCL-deficiency increases the Q-angle and further adversely affects patellar stability.

A knee diagnosed with a severe MCL tear, should be evaluated for patellofemoral instability, as a temporary patella dislocation could have been caused by the same injury and an acute LPD indicating a tear of the MPFL can be associated with a concomitant injury of the MCL. In case of recurrent symptoms of patellofemoral instability in a MCL-deficient knee, both the MPFL and MCL should be managed operatively. An isolated MPFL reconstruction in this knee is likely to fail due to a persistent increase of the Q-angle.

Keywords : patellar instability ; risk factors ; medial patellofemoral ligament ; medial collateral ligament ; combined injury.

INTRODUCTION

Lateral patellar dislocation (LPD) accounts for 2% to 3% of all acute knee injuries (1) and can lead to recurrent patellar instability and knee pain. It is the second most frequent cause of knee haemarthrosis (1) and typically happens when the knee under-

goes a twisting maneuver in a slightly flexed position (around 30°).

Through the range of motion of the human knee, patellar stability is mainly controlled by the patellofemoral joint geometry (9,16). Classic “bony” risk factors for patellofemoral instability include trochlear and patellar dysplasia and an increased Q-angle or tibial tubercle-trochlear groove distance (TT-TG). Trochlear dysplasia can be assessed by evaluating the three criteria suggested by Dejour : the depth of the trochlea, the crossing sign and the trochlear prominence or boss (7). The Q-angle is the angle formed by a line drawn from the center of the patella to the tibial tubercle and a second line drawn from the anterior superior iliac spine (ASIS) to the center of the patella. It can be influenced by tibial tuberosity lateralization as in genu valgum (31), external torsion of the tibia, generalized ligamentous laxity, excessive foot pronation (29), tightness of the

- Kristof Hermans, MD, Resident.
- Steven Claes, MD, Resident.
- Johan Bellemans, MD, PhD, Professor and Head of the Department.

Department of Orthopaedic Surgery, University Hospital Pellenberg, (K.U.L.), Lubbeek, Belgium.

Correspondence : Kristof Hermans, Department of Orthopaedic surgery, University Hospital Pellenberg, Weligerveld 1, 3212 Pellenberg, Belgium.

E-mail : Kristof.hermans@student.kuleuven.be

© 2013, Acta Orthopædica Belgica.

iliotibial band (ITB), weakness of the gluteus medius muscle, hip anteversion (21) or patella alta (2).

Soft-tissue restraints are important in stabilizing the patella at full extension and early knee flexion (16). Proven soft-tissue risk factors for LPD include lesions of the MPFL, medial retinacular laxity and lateral tightness (16). Biomechanical studies have identified the MPFL accounts for 53-67% of the total medial restraining force preventing lateral patellar subluxation or dislocation (5). The medial patellomeniscal ligament and associated retinacular fibres in the deep capsular layer of the knee contribute approximately 22%, whereas the patellotibial ligament and the medial parapatellar retinaculum contribute little in the prevention of lateral patellar displacement (5). These findings are confirmed by studies reporting a restoration of the excessive lateral mobility to normal values after reconstruction of the MPFL in the non-dysplastic patellofemoral joint (14).

The medial collateral ligament (MCL) complex is one of the most commonly injured ligamentous structures of the knee joint (22). MCL lesions usually follow a direct valgus injury on the knee, forced tibial external rotation or a combination of both. The MCL complex consists of three closely related components: the superficial MCL (sMCL), the deep MCL (dMCL) and the posterior oblique ligament (POL) (24). Warren and Marshall (38) divided the anatomy of the medial knee structures in three layers, with the sMCL to be part of layer two, the dMCL part of the third and deepest layer, while the POL arises as a conjoined structure from the second and third layer. The sMCL is the most important structure on the medial aspect of the knee, exerting the largest load response to both valgus and external rotation torques. The sMCL, positioned between the superficial sartorial fascia and the dMCL, arises slightly proximal and posterior to the medial epicondyle (22). It has two tibial attachments; a proximal one located just over 1 cm distal to the joint line and a strong distal attachment, located approximately 6 cm distal to the joint line and directly attached to bone. The functionally less important dMCL is a thickening of the joint capsule deep to the sMCL, extending from the femur to the mid-portion of the medial meniscus and inserting just below the tibial

part of the joint line. Thirdly, the POL reveals a significant static restraint to valgus and internal rotation torques, particularly in extension. It arises from the adductor tubercle of the distal femur and runs to three distal attachments forming a tibial, a capsular and an inferior arm (38).

The classification of MCL injuries (22,28) includes three degrees of severity. A first-degree tear is a microscopic disruption of the fibers with localized tenderness without instability. A second-degree tear, considered as a an incomplete tear of the MCL complex, involves more fibers resulting in more generalized tenderness and instability at 30° of flexion, but still no instability at full extension. Finally a third-degree tear is defined as a complete tear of the MCL complex with a decrease in tenderness, massive valgus instability at 30° of flexion and instability at early flexion angles, indicating the concomitant tear of the POL.

ILLUSTRATIVE CASE

A 41-year-old male patient was seen in the outpatient clinic with a chief complaint of “medial knee instability” being present for about 2 years after a twisting injury. He described a sensation of giving-way at the medial side of the left knee during activities causing a valgus force on the affected knee, leading to a near-fall. Pain was definitely no major complaint. There were no complaints of locking or patellar catching. He furthermore reported recurrent, prominent effusions after each episode of “medial giving-way”.

At subsequent clinical examination, obvious valgus instability was found, with significant opening of the medial knee joint during the valgus stress test in 30° of flexion. The patient showed clear signs of apprehension while performing this test, stating that this feeling of medial giving-way formed his chief complaint. In full extension, no medial instability was noted. Further examination revealed slight pain by palpating the region of the femoral medial epicondyle. McMurray’s test for meniscal lesions was negative, as were the Lachman and anterior drawer test for ACL injury. A clearly positive apprehension for patellar instability was found as well, with the patella showing apparent lateral laxity compared to

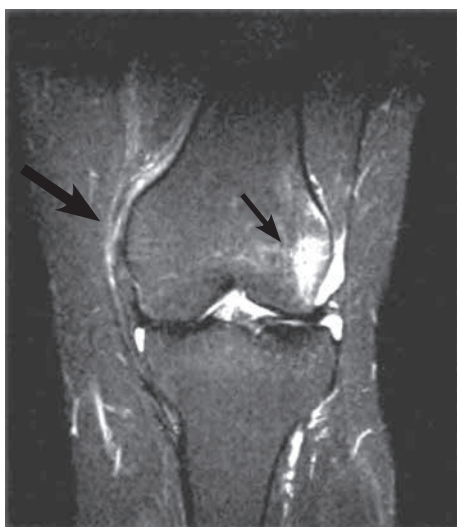

Fig. 1. — MRI study of the left knee reveals complete rupture of the sMCL and dMCL from the femur (large arrow). Bone bruise can be noted on the lateral femoral condyle, suggesting a valgus mechanism (small arrow).

the contralateral knee. Although the patient recalled this sensation as a minor component of his aforementioned episodes of giving-way, he clearly delineated this feature from instability during the valgus stress test.

Magnetic resonance imaging of the affected knee showed a chronic grade III femoral insertion tear of the MCL (Fig. 1). A prominent effusion and a distinct area of bone bruise in both the lateral femoral condyle and the medial patella were observed, corresponding with a recent episode of LPD. MRI poorly visualized the MPFL, and no clear rupture or avulsion of this structure could be shown. No other knee injuries were noted.

Based on the clinical findings of patellofemoral instability we looked for the presence of bony and soft-tissue risk factors for patellar instability on plain radiographs and MRI (Table I). There were no signs of trochlear dysplasia, TT-TG was normal and patellar height was normal.

The diagnosis of a combined valgus laxity and patellofemoral instability was recorded ensuing a chronic injury to the region of the medial femoral epicondyle. An operative approach was offered, with the goal of reconstructing the MPFL with a tendon graft and subsequently addressing chronic MCL laxity by performing an advancement of the MCL complex as proposed by Hughston (17).

Operative treatment

With the patient under general anaesthesia and positioned in the supine position, a valgus stress test was performed, resulting in frank lateral patellar dislocation without applying any force to the patella itself (Fig. 2).

A longitudinal anteromedial incision of the knee was made at mid distance between the medial patellar edge and the medial femoral epicondyle. A midvastus arthrotomy was performed preserving an 8 mm rim of medial retinacular tissue attached to the patella. The patella was slightly everted to confirm the absence of patellar cartilage lesions. To reconstruct the patellar MPFL insertion, two stab incisions in the medial retinacular sleeve directly adjacent to the medial patellar edge were made and a fresh frozen gracilis tendon allograft was looped through. A more medial incision of layer 1 was performed posterior to the medial epicondyle, and both the superficial and deep part of the MCL as well as

Table 1. — Reference values in normal knees and patient values concerning traditional risk factors for LPD

Traditional risk factors	Reference values in normal knees	Patient values
Sulcus angle	132°-144° (6)	137°
Trochlear depth	2.4 mm-10.5 mm (27)	7.5 mm
Trochlear facet asymmetry	> 40% (27)	65.38%
TT - TG distance	< 20 mm (13,33)	17.8 mm
Insall - Salvati ratio	0.8-1.2 (20)	1.08
Caton - Deschamps index	0.6-1.2 (4)	1.15

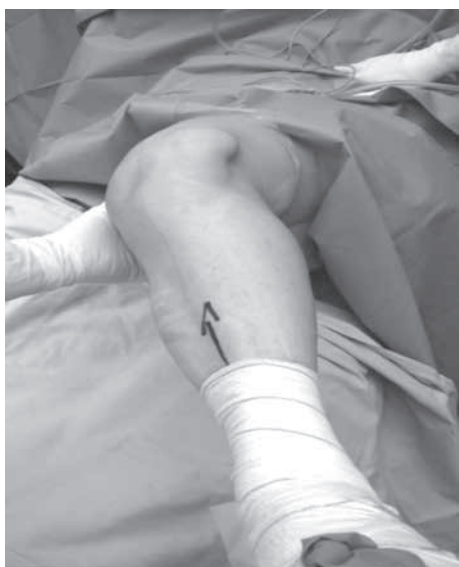

Fig. 2. — Valgus stress test resulting in frank lateral patellar dislocation without applying any force to the patella itself.

the posterior oblique ligament (POL) were clearly identified. Although all three ligamentous structures showed continuous fibers, these ligaments seemed extremely floppy or abundant. According to Hughston (17), the complete medial ligamentous complex was detached from the femur with an L-shaped incision. The femoral end of the MPFL reconstruction was continued by creating a 6 mm bone tunnel starting at the native MPFL femoral insertion which was confirmed by fluoroscopic control according to Schöttle *et al* (32). The free ends of the gracilis allograft were passed between the two layers of the medial patellar retinaculum and inside the femoral tunnel. With the knee flexed at 60°, the free ends were fixed in the femoral tunnel using a PEEK interference screw (Biosure PK 6 × 25 mm screw, Smith&Nephew, Andover, USA), thus finishing the MPFL reconstruction. The sleeve containing the medial ligamentous complex was advanced proximally and anteriorly on the femur, following the technique described by Hughston (17). In this position, the sleeve was fixed to the medial femoral condyle using two suture loaded bone anchors (Twinfix 5.0 anchor, Smith&Nephew, Andover, USA), thus restoring proper tension in the medial ligamentary complex. The MCL plication

was finalized by suturing the advanced POL fibers by 4 stitches (Ethibond Excel 2.0, Ethicon, Somerville, USA) to the sMCL. The redundant tissue proximal to the femoral fixation was sutured to the lower fibers of the vastus medialis obliquus (VMO). Finally, both patellar and valgus laxity were carefully tested and judged as adequate without remaining instability.

After closure of the subcutaneous layers and skin, an immobilizing hinged brace was applied with the knee fixed in 10 degrees of flexion during the first two weeks. The hinged brace was gradually allowed into more flexion the following 4 weeks, after which a cage-type brace was applied for the next 3 months. Full weight bearing was only allowed after 4 weeks. Rehabilitation was uneventful, with the patient reporting to feel well at 3 months after surgery, showing full ROM without residual pain. At final follow-up 1 year after surgery, he had never again experienced either patellar or “medial” knee instability and was fully functional. Clinically, a slight residual valgus laxity of 2 mm in 30° of flexion was found, when compared to the contralateral side. However, apprehension or effusion were completely absent.

DISCUSSION

The clinical picture of valgus laxity associated with patellar dislocation as demonstrated by examination under anaesthesia, led to the assumption of a strong correlation between the two types of instability. We believe that a tear of the MCL complex can adversely affect patellar stability by both a direct and an indirect mechanism (Fig. 3).

The direct mechanism is responsible when the femoral MPFL insertion site is injured simultaneously by the same valgus injury affecting the femoral MCL complex insertion due to the close anatomical proximity of both ligamentous structures (Fig. 4).

It has been shown that the anatomy of the medial knee structures can be divided in three layers, with both the medial patellofemoral ligament (MPFL) and the superficial medial collateral ligament (MCL) to be part of layer two (38). The MPFL is said to arise from the medial femoral epicondyle (14,38) or the

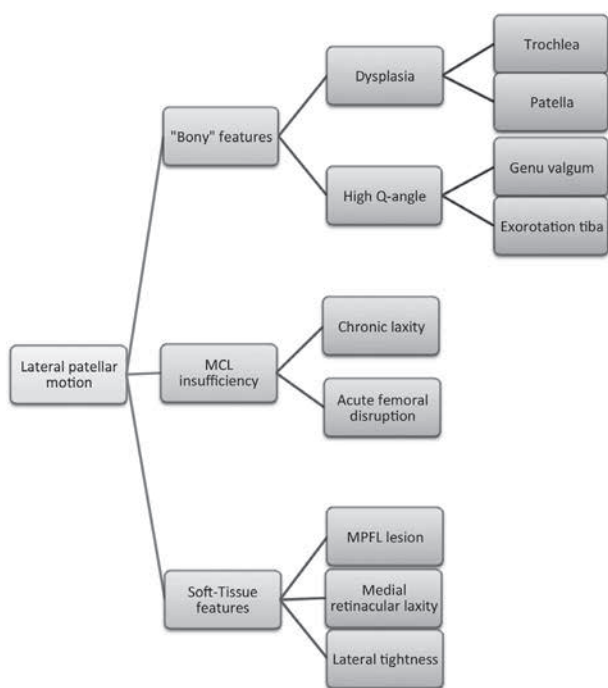


Fig. 3. — Traditional risk factors for LPD completed with the new risk factor : a serious MCL lesion at its femoral insertion.

adductor tubercle (5,36) and extends anteriorly to the superomedial two-thirds of the patella. Disruption of the MPFL most commonly occurs in the fibers attached to the medial femoral epicondyle (35). As the MPFL courses anteriorly, its fibers fuse with the undersurface of the VMO tendon (26). The superficial MCL arises slightly proximal and posterior to the medial epicondyle, almost at the same place as the distal femoral attachment of the VMO. The most common location for MCL injury is the femoral insertion, accounting for 65% of the MCL tears. In the era before the first description of the MPFL as a distinct ligamentous structure, some reports not only mentioned injury to the medial retinaculum after an acute LPD but also the co-existence of lesions to the VMO insertion in these cases. Hunter *et al* (18) noted a femoral lesion of the MCL in 61% of the patients diagnosed with a disruption of the VMO from the adductor tubercle. Since the identification of the MPFL refined the knowledge of the precise anatomy of the medial retinaculum, it can be assumed that these authors noticed the same injury

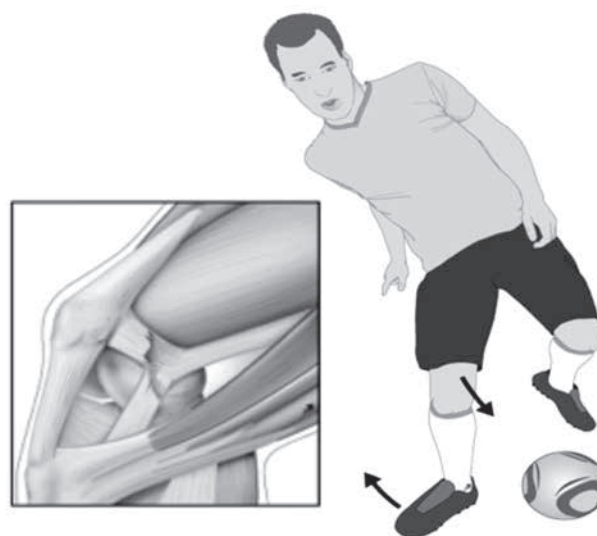


Fig. 4. — The femoral MPFL insertion site can be directly injured by a valgus injury sustained in the area of the femoral MCL complex insertion due to the close anatomical proximity of both ligamentous structures.

mechanism as is demonstrated in this case. More recently, Quinlan *et al* (30) evaluated the integrity of the MCL by MRI in a series of 80 patients who were diagnosed with a transient lateral patellar dislocation. Forty patients (50%) were diagnosed with co-existent MCL injuries, adding to the evidence of an existent relationship between patellar instability and MCL lesions. Based on the common insertion of the sMCL and MPFL, we believe an injury causing a femoral lesion of the sMCL can *vice versa* cause a disruption of the MPFL at its femoral insertion.

The dynamic increase of the Q-angle in the chronic MCL deficient setting, causing valgus laxity constitutes the indirect mechanism and acts as an adjunctive patellar destabilizer. This hypothesis is supported by the results of a 7-year follow-up study, reporting that the MPFL injury location has to be taken into account when planning treatment: whereas MPFL avulsion at the femoral attachment in primary traumatic patellar dislocations predicts patellar instability, a disruption at the mid-substance or at the patella results significantly less often into patellar instability (34).

Initial management of a first time patella dislocation is usually non-operative (3). However recurrence

rates of 15% to 44% have been reported after conservative treatment (25). Operative treatment of both acute and chronic patellar instability through reconstruction of the medial patellofemoral ligament showed significantly less pain and recurrence compared to non-operative treatment (3,12). Initial management of most MCL lesions, including high-grade tears also is conservative. Chronic cases or multi-ligament injuries are considered for surgical approach (24).

In conclusion we believe that the possible simultaneous occurrence of both valgus and patellar instability implicates reconsideration of the diagnostic and therapeutic approach of these injuries :

1. In case of a high-grade femoral tear of the MCL complex, a concomitant MPFL lesion should be excluded. In some cases, MRI can be useful as patellar dislocations can be clinically missed.
2. When confronted with an acute patellar dislocation, a simultaneous injury to the femoral MCL insertion site should be excluded. It is important to be aware of the fact that patellar apprehension can make the valgus stress test unclear.
3. When a femoral lesion of the MPFL combined with a high-grade MCL injury is diagnosed, conservative treatment is advisable if both pathologic conditions and their mutual relationship are recognized and treated accordingly. In cases of recurrent instability not responding to conservative treatment, both ligaments should be treated surgically by either MCL reconstruction or advancement combined with MPFL reconstruction.

REFERENCES

1. **Arendt EA, Fithian DC, Cohen E.** Current concepts of lateral patella dislocation. *Clin Sports Med* 2002 ; 21 : 499-519.
2. **Balcerek P, Jung K, Ammon J et al.** Anatomy of lateral patellar instability. *Am J Sports Med* 2010 ; 38 : 2320-2327.
3. **Bitar AC, Demange MK, D'Elia CO, Camanho GL.** Traumatic patellar dislocation: nonoperative treatment compared with MPFL reconstruction using patellar tendon. *Am J Sports Med* 2012 ; 40 : 114-122.
4. **Caton J, Deschamps G, Chambat P, Lerat JL, Dejour H.** [Patella infera : a study of 128 cases.] (in French). *Rev Chir Orthop Répar Appar Mot.* 1982 ; 68 : 317-325
5. **Conlan T, Garth WP, Lemons JE.** Evaluation of the medial soft-tissue restraints of the extensor mechanism of the knee. *J Bone Joint Surg* 1993 ; 75-A : 682-693.
6. **Davies AP, Costa ML, Donnell ST, Glasgow MM, Shepstone L.** The sulcus angle and malalignment of the extensor mechanism of the knee. *J Bone Joint Surg* 2000 ; 82-B : 1162-1166.
7. **Dejour H, Walch G, Nove-Josserand L, Guier C.** Factors of patellar instability : An anatomic radiographic study. *Knee Surg Sports Traumatol Arthrosc* 1994 ; 2 : 19-26.
8. **Elias DA, White LM, Fithian DC.** Acute lateral patellar dislocation at MR imaging. *Radiology* 2002 ; 225 : 736-743.
9. **Farahmand F, Tahmasbi MN, Amis AA.** Lateral force-displacement behaviour of the human patella and its variation with knee flexion : A biomechanical study in vitro. *J Biomech* 1998 ; 31 : 1147-1152.
10. **Fithian DC, Paxton EW, Stone ML et al.** Epidemiology and natural history of acute patellar dislocation. *Am J Sports Med* 2004 ; 32 : 1114-1121.
11. **Gardiner JC, Weiss JA, Rosenberg TD.** Strain in the human medial collateral ligament during valgus loading of the knee. *Clin Orthop Relat Res* 2001 ; 391 : 266-274.
12. **Gomes JLE, Marczyk LRS, Cesar de Cesar SP, Jungblut CF.** Medial patellofemoral ligament reconstruction with semitendinosus autograft for chronic patellar instability : A follow-up study. *Arthroscopy* 2004 ; 20 : 147-151.
13. **Goutallier D, Bernageau J, Lecudonnet B.** Measurement of the tibial tubercle-trochlear groove distance (TT-TG).] (in French). *Rev Chir Orthop Réparatrice Appar Mot.* 1978 ; 64 : 423-428.
14. **Hautamaa PV, Fithian DC, Kaufman KR et al.** Medial soft-tissue restraints in lateral patellar instability and repair. *Clin Orthop Relat Res* 1998 ; 349 : 174-182.
15. **Hawkins RJ, Bell RH, Garth A.** Acute patellar dislocations : The natural history. *Am J Sports Med* 1986 ; 14 : 117-120.
16. **Heegaard J, Leyvraz PF, Van Kampen A et al.** Influence of soft structures on patellar three-dimensional tracking. *Clin Orthop Relat Res* 1994 ; 299 : 235-243.
17. **Hughston JC.** The importance of the posterior oblique ligament in repairs of acute tears of the medial ligaments in knees with and without an associated rupture of the anterior cruciate ligament. Results of long-term follow-up. *J Bone Joint Surg* 1994 ; 76-A : 1328-1344.
18. **Hunter SC, Marascalco R, Hughston JC.** Disruption of the vastus medialis obliquus with medial knee ligament injuries. *Am J Sports Med* 1983 ; 11 : 427-431.
19. **Insall J, Goldberg V, Salvati E.** Recurrent dislocation and the high-riding patella. *Clin Orthop Relat Res* 1972 ; 88 : 67-69.
20. **Insall J, Salvati E.** Patella position in the normal knee joint. *Radiology* 1971 ; 101 : 101-104.
21. **Kijowski R, Plagens D, Shaeh SJ et al.** The effects of rotational deformities of the femur on contact pressure and

contact area in the patellofemoral joint and on strain in the medial patellofemoral ligament. *Annual Meeting of the International Patellofemoral Study Group 1999 Napa Valley, San Francisco.*

22. **LaPrade RF, Wijdicks CA.** The management of injuries to the medial side of the knee. *J Orthop Sports Phys Ther* 2012 ; 42 : 221-233.
23. **Maldague B, Malghem J.** Significance of the radiograph of the knee profile on the detection of knee patellar instability : Preliminary report. *Rev Chir Orthop Réparatrice Appar Mot* 1985 ; 71 (Suppl 2) : 5-13.
24. **Marchant MH, Jr, Tibor LM, Sekiya JK et al.** Management of medial-sided knee injuries, Part 1 : Medial collateral ligament. *Am J Sports Med* 2011 ; 39 : 1102-1113.
25. **Mehta VM, Inoue M, Nomura E, Fithian DC.** An algorithm guiding the evaluation and treatment of acute primary patellar dislocations. *Sports Med Arthrosc* 2007 ; 15 : 78-81.
26. **Nomura E, Fujikawa T, Takeda et al.** Anatomical study of the medial patellofemoral ligament. *Orthop Surg Suppl* 1992 ; 22 : 2-5.
27. **Pfirrmann CW, Zanetti M, Romero J, Hodler J.** Femoral trochlear dysplasia : MR findings. *Radiology* 2000 ; 216 : 858-864.
28. **Phisitkul P., James SL, Wolf BR, Amendola A.** MCL injuries of the knee : current concepts review. *Iowa Orthop J* 2006 ; 26 : 77-90.
29. **Post WR.** Clinical evaluation of patients with patellofemoral disorders. *Arthroscopy* 1999 ; 15 : 841-851.
30. **Quinlan JF, Farrekky C, Kelly G, Eustace S.** Co-existent medial collateral ligament injury seen following transient patellar dislocation : observations at magnetic resonance imaging. *Br J Sports Med* 2010 ; 44 : 411-414.
31. **Sanchis-Alfonso V, Avila-Carrasco C, Prat-Pastor J, Atenza-Vicente C, Cunat E.** Biomechanical bases for anterior knee pain and patellar instability. *Anterior Knee Pain and Patellar Instability.* 2nd ed, Springer, London, New York ,2011, pp 75-76.
32. **Schöttle PB, Schmeling A, Rosenstiel N, Weiler A.** Radiographic landmarks for femoral tunnel placement in medial patellofemoral ligament reconstruction. *Am J Sports Med* 2007 ; 35 : 801-804.
33. **Schöttle PB, Zanetti M, Seifert B et al.** The tibial tuberosity-trochlear groove distance ; a comparative study between CT and MRI scanning. *Knee* 2006 ; 13 : 26-31.
34. **Sillanpää PJ, Peltola E, Mattila VM, Kiuru M.** Femoral avulsion of the medial patellofemoral ligament after primary traumatic patellar dislocation predicts subsequently instability in men. *Am J Sports Med* 2009 ; 37 : 1513-1521.
35. **Stefancin KK, Parker RD.** First-time traumatic patellar dislocation : a systematic review. *Clin Orthop Relat Res* 2007 ; 455 : 93-101
36. **Terry GC.** The anatomy of the extensor mechanism. *Clin Sports Med* 1989 ; 8 :163-177.
37. **Van Huyssteen AL, Hendrix MR, Barnett AJ, Wakeley CJ, Eldridge JD.** Cartilage-bone mismatch in the dysplastic trochlea : an MRI study. *J Bone Joint Surg* 2006 ; 88-B : 688-691.
38. **Warren LF, Marshall JL.** The supporting structures and layers on the medial side of the knee : Anatomical analysis. *J Bone Joint Surg* 1979 ; 61-A : 56-62.