



## Combined external fixation and intramedullary alignment in correction of limb length discrepancies

Bojan BUKVA, Radivoj BRDAR, Dejan NIKOLIC, Ivana PETRONIC, Sinisa DUCIC, Dusan ABRAMOVIC

*From Belgrade University Children's Hospital, Belgrade, Serbia*

The aim of this study was to evaluate the influence of intramedullary (IM) alignment used in combination with external fixation on the healing index (HI) and lengthening index (LI) in the treatment of congenital and acquired leg length discrepancies (LLD). We compared duration of the external fixator application, LLD, HI and LI between two groups of children : children in Group I underwent limb lengthening by the conventional Ilizarov technique, and children in Group II underwent a combination of Ilizarov technique and intramedullary alignment with Kirschner wires. Two types of LLDs were treated : congenital and acquired. We found significant differences between the two groups for duration of external fixator application and HI. Significant differences were also noted in the duration of the external fixator application, HI and LI, between patients with congenital and acquired LLDs. We also noted significant differences between Group I and Group II regarding duration of external fixator application for patients with congenital LLD and also regarding HI for both congenital and acquired types of LLD.

**Keywords :** leg length discrepancy ; healing index ; intramedullary alignment ; external fixator.

### INTRODUCTION

Various operative techniques have been introduced over the last fifty years to improve anatomic and functional results of limb lengthening in chil-

dren. Among the techniques for progressive lengthening, external fixation is the one most often used, especially with an Ilizarov external fixator. Lengthening techniques based on the principles of Ilizarov (2,6,14) have provided satisfactory results (4, 9,16). They allow for simultaneous lengthening and correction of deformities in three dimensions. Bone lengthening is made possible thanks to the gradual distraction of soft tissues and neurovascular elements. An important modification of this technique combines the Ilizarov external fixator and intramedullary (IM) alignment (5). Intramedullary fixation exists under two forms : with a rigid nail and with a flexible nail (8,15). This combination could potentially reduce the risk of bone deformity occurring

- 
- Bojan Bukva, MD, Paediatric Surgeon.
  - Radivoj Brdar, MD, PhD, University Professor.
  - Sinisa Ducic, MD, MSc, Assistant Professor.
  - Dusan Abramovic, MD, MSc, Paediatric Surgeon.  
*Paediatric Surgery Department, University Children's Hospital, Belgrade, Serbia.*  
*Faculty of Medicine, University of Belgrade, Serbia.*
  - Dejan Nikolic, MD, PhD, Physiatrist.
  - Ivana Petronic, MD, PhD, University Professor.  
*Physical Medicine and Rehabilitation Department, University Children's Hospital, Belgrade, Serbia, Faculty of Medicine, University of Belgrade, Serbia.*
- Correspondence : Bojan Bukva, University Children's Hospital, Tirsova 10, 11000 Belgrade, Serbia.  
E-mail : denikol27@gmail.com  
© 2013, Acta Orthopædica Belgica.
-

during the lengthening period and could also reduce the time to bone healing (12).

The purpose of this study was to evaluate the influence of intramedullary alignment with Kirschner wires combined with an external fixator on the healing index (HI) and lengthening index (LI) in children with congenital and acquired leg length discrepancies (LLD).

## PATIENTS AND METHODS

### Study group

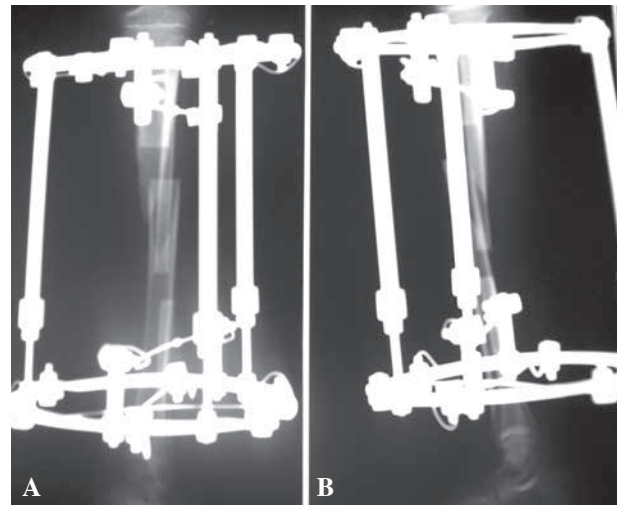
We prospectively studied 56 patients referred to the Belgrade University Children's Hospital (UCH), who underwent lower limb lengthening over a twelve years period, between 2000 and 2011. There were 35 patients with congenital leg length discrepancy, and 21 with acquired leg length discrepancy.

The study was approved by the Institutional Review Board and followed the principles of good clinical practice. Prior to inclusion in the study, parents or legal guardians were informed about the surgical procedure and treatment outcome and informed consent was obtained. The follow-up was done by a paediatric surgeon, a radiologist and a physiatrist. Only patients that were planned for monosegmental lower limb lengthening procedures were included in the study. The exclusion criteria included neurological and metabolic aetiologies and non-reconstructible congenital anomalies. Lengthening was completed with the Ilizarov technique (external fixator) with or without IM alignment with Kirschner wires. We compared two groups of patients: Group I included 35 children in which lengthening was performed with a circular external fixator (Ilizarov) (Fig. 1) and Group II included 21 children in which lengthening was performed using a combination of circular external fixation (Ilizarov) and IM alignment with Kirschner wires (stainless steel, Synthes GmbH, Germany) (Fig. 2).

The following parameters were evaluated: duration of the external fixator application, limb length inequality, HI, LI. Two types of LLD were assessed: congenital and acquired. Healing index represents the duration of the external ring fixation required to obtain 1 cm lengthening (10). It is expressed as days/cm.

### Surgical procedure

The first stage in both groups was the application of the Ilizarov external fixator. In Group II, after application



**Fig. 1.** — External fixator technique. **A)** AP radiograph. **B)** Lateral radiograph.

of the external fixator, Kirschner wires were inserted into the medullary cavity through two holes in the bone, 1.5-2 cm away from the growth plate. The K-wires were 2 or 2.5 mm in diameter; they were bent so as to have a curvature of about 40 degrees, and they were placed so as to have their curvatures opposite to each other. The IM wires were introduced retrograde in the femur, and anterograde in the tibia. Two IM wires, one from the medial side and the other from the lateral side, were carefully introduced and were pushed gently until they reached the opposite metaphysis. The apex of the curves was placed close to the future osteotomy site. The external tips of the IM wires were bent 90 degrees to avoid their sliding into the medullary canal during the distraction period. They were left under the skin. Diaphyseal osteotomy of the bones followed the above mentioned procedure, in both groups, and an initial lengthening of 3-5 mm was achieved.

### Postoperative period

In both groups, the lengthening began on the seventh day after surgery (8). Antibiotic prophylaxis (second generation cephalosporin) was given prior to surgery and for 3 more days. Early joint mobilization was started one week after surgery. Radiographic assessment was done every two weeks in each group. When homogenous bone regeneration was noted and confirmed radiologically, the external fixator was removed in both groups and patients were able to walk with partial or full weight bearing

Table I. — Treatment outcome values of evaluated parameters regarding type of surgery

Parameters N = 56	Categories	Values (MV $\pm$ SD)	Statistical interpretation
Duration of the external fixator use (days)	Group I (N = 35)	220.86 $\pm$ 94.75	$p = 0.0005$
	Group II (N = 21)	141.91 $\pm$ 30.05	
Inequality (cm)	Group I (N = 35)	5.47 $\pm$ 2.35	$p = 0.3745$
	Group II (N = 21)	6.13 $\pm$ 3.14	
HI	Group I (N = 35)	43.72 $\pm$ 17.08	$p = 0.0001$
	Group II (N = 21)	27.09 $\pm$ 7.81	
LI	Group I (N = 35)	0.30 $\pm$ 0.24	$p = 0.7361$
	Group II (N = 21)	0.28 $\pm$ 0.16	

\*students T-test.

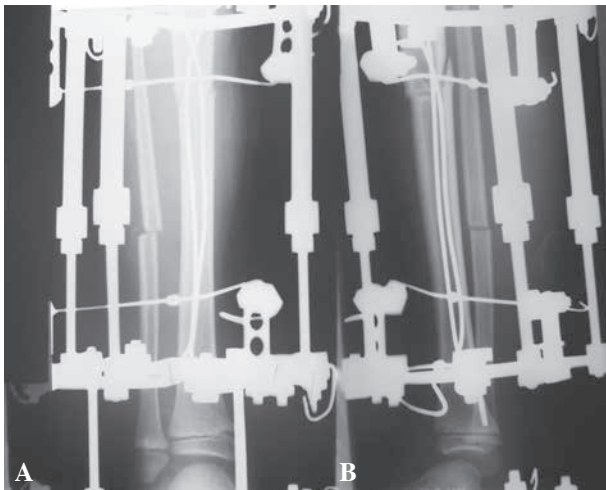


Fig. 2. — Combined technique. A) AP radiograph. B) Lateral radiograph.

without pain. Following removal of the external fixator, a plaster cast was not applied. The IM wires were removed when the radiographic appearance of the regenerate was similar to the normal adjacent bone.

### Statistical analysis

We have presented the evaluated parameters as mean values (MV) with standard deviation (SD). For estimation of statistical difference between groups, we used Student's t-test. Statistical significance was set at  $p < 0.05$ .

## RESULTS

Preoperatively, we found no significant differences in LLD between the two surgical groups (Table I). We found significant differences between Group I and Group II in the duration of external fixator application ( $p < 0.01$ ) and in HI ( $p < 0.01$ ) but not regarding LI (Table I).

In Group I (Ilizarov only) we found no significant differences for all evaluated parameters between the subgroup with congenital LLD and the subgroup with acquired LLD (Table II).

In Group II (combined Ilizarov fixation and IM alignment), we found significant differences in the duration of external fixator application ( $p < 0.05$ ), HI ( $p < 0.05$ ) and LI ( $p < 0.01$ ) between patients with congenital and those with acquired LLD (Table III). Concerning length inequality we found no significant difference between two different types of LLD.

We also noted significant differences between Group I and Group II regarding duration of external fixator application for patients with congenital LLD ( $p < 0.01$ ) and also regarding HI for both congenital ( $p < 0.01$ ) and acquired ( $p < 0.01$ ) types of LLD (Table IV).

## DISCUSSION

In this study we evaluated the effectiveness of two surgical techniques (Ilizarov technique alone and Ilizarov technique with IM alignment with K-wires) in patients with congenital or acquired LLD.

Table II. — External fixation treatment outcome of evaluated parameters regarding LLD type

Parameters N = 35	Categories	Values (MV ± SD)	Statistical interpretation
Duration of the external fixator use (days)	Congenital (N = 23)	210.48 ± 67.43	p = 0.3775
	Acquired (N = 12)	240.75 ± 134.16	
Inequality (cm)	Congenital (N = 23)	5.80 ± 2.14	p = 0.2538
	Acquired (N = 12)	4.83 ± 2.71	
HI	Congenital (N = 23)	40.01 ± 16.92	p = 0.0748
	Acquired (N = 12)	50.83 ± 15.68	
LI	Congenital (N = 23)	0.30 ± 0.25	p = 1.0000
	Acquired (N = 12)	0.30 ± 0.23	

\*Student's t-test.

LLD – leg length discrepancy; HI – healing index; LI – lengthening index.

Table III. — Treatment outcome in patients that underwent external fixation with intramedullary nailing

Parameters N = 21	Categories	Values (MV ± SD)	Statistical interpretation
Duration of the external fixator use (days)	Congenital (N = 12)	133.57 ± 26.44	p < 0.05*
	Acquired (N = 9)	160.40 ± 30.84	
Inequality (cm)	Congenital (N = 12)	6.71 ± 3.94	p > 0.05*
	Acquired (N = 9)	5.30 ± 1.57	
HI	Congenital (N = 12)	24.39 ± 8.21	p < 0.05*
	Acquired (N = 9)	30.88 ± 3.16	
LI	Congenital (N = 12)	0.36 ± 0.16	p < 0.01*
	Acquired (N = 9)	0.18 ± 0.08	

\*Student's t-test.

This combination offers certain advantages, As previously stated, the IM wires do not inhibit the generation of an endostal regenerate and the bone regeneration is stimulated due to biological effects of the blood flow redistribution to periosteal structures (11). Furthermore, the IM alignment prevents translation of the bone ends at the level of the diastasis during lengthening (1).

We presumed that the progressive sliding of the intramedullary wires through the regenerate during the period of distraction could result in the stimulation of regenerative processes. To accomplish this effect, the apex of the wires' curve should be placed as close as possible to the osteotomy site. The wires will thus be placed at the level of the regenerate growth zone by the end of the distraction period,

ultimately stimulating the lengthening process. The presence of the intramedullary wires does not interfere with the correction of deformities associated with LLD ; it even helps in their correction. Finally, there is a possibility to remove the external fixator earlier, as a certain degree of stability will still be provided by the IM wires (1).

The results of our study show that patients with the combined treatment had a significantly shorter duration of external fixator application and significantly better HI, in relation with the above mentioned role of the intramedullary alignment combined with the Ilizarov technique on healing processes (7,13). It was previously demonstrated that the application of an external fixator combined with IM alignment reduces the time for external fixation in patients

Table IV. — Statistical interpretation of different treatments outcome regarding LLD type

Parameters	Categories	Statistical interpretation
Duration of the external fixator use (days)	Congenital (Group I/Group II)	$p = 0.0006$
	Acquired (Group I/Group II)	$p = 0.0960$
Inequality (cm)	Congenital (Group I/Group II)	$p = 0.3794$
	Acquired (Group I/Group II)	$p = 0.6483$
HI	Congenital (Group I/Group II)	$p = 0.0051$
	Acquired (Group I/Group II)	$p = 0.0014$
LI	Congenital (Group I/Group II)	$p = 0.4574$
	Acquired (Group I/Group II)	$p = 0.1524$

\*Student's t-test.

LLD – leg length discrepancy; HI – healing index; LI – lengthening index.

with segmental tibial defects as compared with external fixation alone (3).

With the combined treatment, we found a significant reduction in duration of external fixator application in patients with congenital versus acquired LLD and better Healing and Lengthening Indices for both congenital and acquired LLD. These findings suggest that patients with congenital LLD should be given the benefit of the combined treatment, due to its better outcome.

The main limitation of this study is the small number of participants. Therefore, further studies on larger number of participants are needed. However, the strength of the study is the long time of follow-up, which enabled us to monitor the possible onset of complications that could affect the observed improvements observed in the parameters studies.

It is worth mentioning that IM alignment respects all the basic requirements of distraction osteosynthesis (preservation of the surrounding bone, the periosteum, and intramedullary vascularisation). This method respects all physiological phases during the process of limb lengthening. It preserves function by an early articular mobilisation and

weight bearing, in compliance with important biomechanical rules.

## REFERENCES

1. **Burlakov E, Alatov D, Popkov D, Shutov RB.** [Calculation of the main parameters of spokes for intramedullary reinforcement of tubular bones] (in Russian). *Med Tekh* 2008 ; 3 : 26-28.
2. **Cole JD, Justin D, Kasparis T, DeVlught D, Knobloch C.** The intramedullary skeletal kinetic distractor (ISKD) : first clinical results of a new intramedullary nail for lengthening of the femur and tibia. *Injury* 2001 ; 32 (Suppl 4) : SD129-139.
3. **Eralp L, Kocaoglu M, Polat G et al.** A comparison of external fixation alone or combined with intramedullary nailing in the treatment of segmental tibial defects. *Acta Orthop Belg* 2012 ; 78 : 652-659.
4. **Guichet JM, Deromedis B, Donnan LT et al.** Gradual femoral lengthening with the Albizzia intramedullary nail. *J Bone Joint Surg* 2003 ; 85-A : 838-848.
5. **Ilizarov GA.** *Transosseous Osteosynthesis*. Springer-Verlag, Berlin, 1992.
6. **Iobst CA, Dahl MT.** Limb lengthening with submuscular plate stabilisation : a case series and description of the technique. *J Pediatr Orthop* 2007 ; 27 : 504-509.
7. **Jasiewicz B, Kacki W, Tesiorowski M, Potaczek T.** [Results of femoral lengthening over an intramedullary nail

- and external fixator] (in Polish). *Chir Narzadow Ruchu Ortop Pol* 2008 ; 73 : 177-183.
8. **Kim H, Lee SK, Kim KJ et al.** Tibial lengthening using a reamed type intramedullary nail and an Ilizarov external fixator. *Int Orthop* 2009 ; 33 : 835-841.
  9. **Korzinek K, Tepic S, Perren SM.** Limb lengthening and three-dimensional deformity corrections. A retrospective clinical study. *Arch Orthop Trauma Surg* 1990 ; 109 : 334-340.
  10. **Lammens J, Lin Z, Aerssens J, Dequeker J, Fabry G.** Distraction bone healing versus osteotomy healing : a comparative biochemical analysis. *J Bone Miner Res* 1998 ; 13 : 279-286.
  11. **Lascombes P.** *Flexible Intramedullary Nailing in Children.* Springer-Verlag, Berlin Heidelberg, 2010.
  12. **Pajardi G, Campiglio GL, Candiani P.** Bone lengthening in malformed upper limbs : a four-year experience. *Acta Chir Plast* 1994 ; 36 : 3-6.
  13. **Paley D, Herzenberg JE, Paremian G, Bhave A.** Femoral lengthening over an intramedullary nail. A matched-case comparison with Ilizarov femoral lengthening. *J Bone Joint Surg* 1997 ; 79-A : 1464-1480.
  14. **Popkov D, Lascombes P, Popkov A, Journeau P, Haumont T.** Role of the flexible intramedullary nailing in limb lengthening in children : comparative study based on the series of 294 lengthenings. *Eur Orthop Traumatol* 2012 ; 3 : 17-24.
  15. **Popkov D, Popkov A, Haumont T, Journeau P, Lascombes P.** Flexible intramedullary nail use in limb lengthening. *J Pediatr Orthop* 2010 ; 30 : 910-918.
  16. **Shevtsov VI, Popkov AV.** Limb lengthening in automatic mode. *Orthop Traumatol Rehabil* 2002 ; 30 : 403-412.